

# UC Davis

## UC Davis Previously Published Works

### Title

Locally Advanced Spiroadenocarcinoma in the Regional Axilla of a Breast Cancer Patient: Hallmarks of Definitive Diagnosis and Management.

### Permalink

<https://escholarship.org/uc/item/5q26217w>

### Journal

Rare tumors, 7(3)

### ISSN

2036-3605

### Authors

Gingrich, Alicia A  
Fung, Maxwell A  
Konia, Thomas  
et al.

### Publication Date

2015-09-01

### DOI

10.4081/rt.2015.5912

Peer reviewed

## Locally advanced spiroadenocarcinoma in the regional axilla of a breast cancer patient: hallmarks of definitive diagnosis and management

Alicia A. Gingrich,<sup>1</sup> Maxwell A. Fung,<sup>2</sup> Thomas Konia,<sup>2</sup> Robert J. Canter<sup>1</sup>

<sup>1</sup>Division of Surgical Oncology,

<sup>2</sup>Departments of Dermatology and Pathology, UC Davis School of Medicine, Sacramento, CA, USA

### Abstract

Eccrine spiroadenocarcinoma is an extremely rare malignant eccrine gland tumor which may masquerade as other more common malignancies such as poorly differentiated squamous carcinoma or metastatic breast cancer. We report a case of an ulcerated axillary skin lesion with bulky adenopathy in a 77 year-old female with a prior history of ipsilateral triple negative breast carcinoma. The clear transition of benign spiradenoma to malignant carcinoma was essential to establishing a definitive diagnosis and treatment plan.

### Introduction

Eccrine spiradenoma, or simply spiradenoma, is a relatively common benign tumor arising from the lobular portion of the cutaneous apocrine or eccrine sweat gland, most often seen in young adults. Spiradenoma tends to present as small, slow-growing, painful, nodular cutaneous masses on the trunk, extremities, head and neck and are usually no more than 1-2 cm in size.<sup>1</sup> The dominant treatment approach is typically surgical excision for both diagnostic and therapeutic purposes, although many patients elect not to seek treatment.<sup>1</sup>

Malignant degeneration of spiradenoma, so-called malignant spiradenoma (MS) or spiroadenocarcinoma, is an extremely rare cutaneous adnexal tumor. Although data are limited, the available literature indicates that MS nearly uniformly arises from a benign pre-existing spiradenoma.<sup>2-4</sup> Typically, MS presents as a previously undiagnosed lesion on the trunk or extremities that rapidly enlarges, changes color, ulcerates or becomes painful and tender.<sup>2</sup> The time period for transformation to malignancy has been reported to range from 2 months to 75 years, although overall the mean duration between appearance of a lesion and malignant transformation has been esti-

mated to be 20 years.<sup>5,6</sup>

Here we report a case of an ulcerated MS presenting with bulky adenopathy in the axilla ipsilateral to a metachronous diagnosis of triple negative breast carcinoma. Our case is unique in that we show MS developing over four months in an area anatomically adjacent to a previous cancer, with initial concern for recurrent metastatic breast carcinoma. The clear admixture of benign spiradenoma and adenocarcinoma was essential to establishing a definitive diagnosis and treatment plan for this patient.

### Case Report

The patient is 77 year old female who was diagnosed with metachronous ipsilateral triple negative breast carcinoma. The surgical management of her prior breast cancer included total mastectomy, sentinel lymph node biopsy, and implant reconstruction. She then received adjuvant chemotherapy before beginning a program of cancer surveillance. The patient was then disease free for 14 years with no evidence of recurrent malignancy.

She was in her usual state of health until 4 months prior to presentation when she noted a palpable cutaneous mass in her axilla. The mass was protuberant from her skin and developed ulceration. This was concerning for neoplasm, and hence a shave biopsy was performed. Initial biopsy revealed poorly differentiated carcinoma with differential diagnosis including squamous carcinoma and metastatic breast carcinoma. Given the clinical impression of squamous carcinoma, the patient was referred to dermatology for wide local excision and possible Mohs procedure. Excisional biopsy was then performed. Although a complete excision was not achieved, pathologic evaluation established a diagnosis of spiroadenocarcinoma based on a clear association of a benign spiradenoma precursor lesion with surrounding malignant degeneration.

As shown in Figure 1, histologic evaluation of the specimen was consistent with spiradenocarcinoma with lesional tissue extending to the borders of excision. Microscopically, the excision yielded poorly differentiated spiradenocarcinoma associated with an underlying nodule of spiradenoma as well as a tumor nodule containing mixed spiradenoma and spiradenocarcinoma. Nuclear P53 staining was present in the malignant portion of the neoplasm and variable staining in the transition from benign-appearing spiradenoma to a malignant morphology. Staining for smooth muscle actin highlighted surrounding myoepithelial cells in the spiradenoma, while loss of expression surrounding the malignant portion. Estrogen and progesterone receptor staining

Correspondence: Robert J. Canter, Division of Surgical Oncology, Suite 3010, UC Davis Cancer Center, 4501 X Street, Sacramento, CA 95817, USA.

Tel.: +1.916.734.7044 - Fax: +1.916.703.5267.

E-mail: robert.canter@ucdmc.ucdavis.edu

Key words: Spiroadenocarcinoma; spiradenoma; malignant eccrine spiradenoma.

Contributions: AG, conception and design, literature review, writing the manuscript; MF, TK, analysis and interpretation of data, critical revision of the article; RC, conception and design, analysis and interpretation of data, writing the manuscript, critical revision of the manuscript.

Conflict of interest: the authors declare no potential conflict of interest.

Funding: this work was supported by funding from the National Institutes of Health (UC Davis Paul Calabresi K12 Career Development Award NIH 1K12CA138464-01A2).

Received for publication: 18 March 2015.

Revision received: 28 May 2015.

Accepted for publication: 14 June 2015.

This work is licensed under a Creative Commons Attribution NonCommercial 3.0 License (CC BY-NC 3.0).

©Copyright A. Gingrich et al., 2015

Licensee PAGEPress, Italy

Rare Tumors 2015; 7:5912

doi:10.4081/rt.2015.5912

was negative, but interestingly (and distinct from the patient's prior breast carcinoma), staining for HER2/Neu was 3+ by immunohistochemistry. The carcinoma was considered poorly differentiated because it was composed of sheets of pleomorphic cells, mitotically active, and had associated areas of necrosis. Areas of vascular space invasion were also noted.

The patient was then referred to surgical oncology for definitive surgical management. Given the possibility that the tumor represented a delayed regional recurrence of her original breast carcinoma, pathologic review of her original mastectomy specimen was performed. This revealed an invasive ductal carcinoma with a modified Bloom Richardson grade of 3. Pathologic review also confirmed tumor-free surgical margins in the mastectomy specimen, and there was no evidence of skin involvement by the primary breast cancer. Similarly, there were no features of sebaceous gland differentiation. Taken together, the findings were consistent with the conclusion that these were morphologically distinct tumors.

Surgical oncology evaluation revealed an

open granulating wound in the posterior axillary fold adjacent to the proximal aspect of the right upper extremity. There was no clinical evidence of residual tumor. PET/CT was performed to evaluate her extent of disease (Figure 2). This revealed significant FDG avid hypermetabolic activity in the ipsilateral axilla consistent with regional metastasis. There was no evidence of distant metastatic disease. Given the absence of distant disease, the decision was made to proceed with re-excision of the surgical site and axillary node dissection.

At the time of surgery, the open wound with scar formation was identified in the posterior right axilla, and an elliptical incision was removed to include a 1-2 cm margin around the lesion. Given the concern for regional metastasis, a sentinel lymph node biopsy was completed to stage the regional axilla. Metastatic carcinoma was confirmed in frozen section, and therefore a complete axillary lymph node dissection was performed. The skin defect was repaired with a skin graft.

Nine of thirty lymph nodes were positive for poorly differentiated spiradenocarcinoma with evidence for extracapsular extension. Following an uneventful postoperative recovery with excellent skin graft take, the patient was referred for adjuvant radiotherapy based on epidemiological data showing improved oncologic outcome following adjuvant radiotherapy.<sup>7</sup>

## Discussion

In 1956, Kersting and Helwig first described *eccrine spiradenoma* as a skin adnexal neoplasm with a slow growth pattern.<sup>8</sup> The first reported case of malignant transformation to MS was described by Dabska in 1972.<sup>9</sup> Fortunately, this transformation is rare as malignant sweat gland tumors are estimated to account for only 0.005% of all skin tumors.<sup>10</sup>

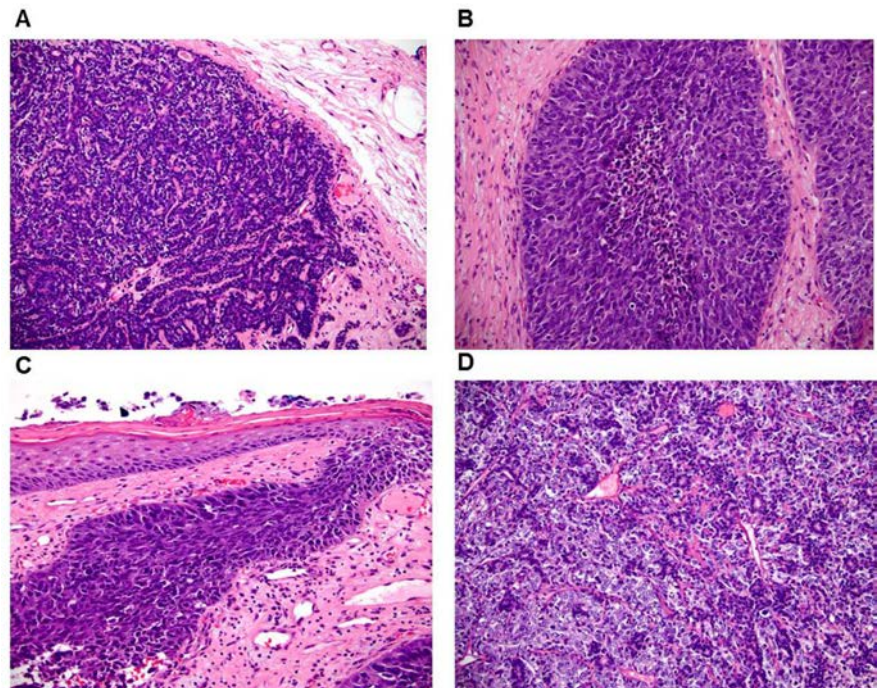
A definitive diagnosis of MS requires histopathological examination. A malignant adnexal neoplasm is arranged in ragged sheets, solid masses with central necrosis, nests, cords, and occasional irregular glandular structures with loss of periodic acid-Schiff-positive basement membrane.<sup>2</sup> Malignancy is further assessed by findings of increased mitotic rate, nuclear atypia, pleomorphism, hyperchromasia, infiltrative border, hemorrhage, and absence of the characteristic two-cell population.<sup>11,12</sup> Most high-grade tumors also display areas of focal abnormal squamous or sarcomatous differentiation.

Immunohistochemically, these tumors display a variety of cytokeratins and antigens. There are also reports of estrogen receptor expression in MS, which may increase diagnostic overlap with other malignancies.<sup>12</sup>

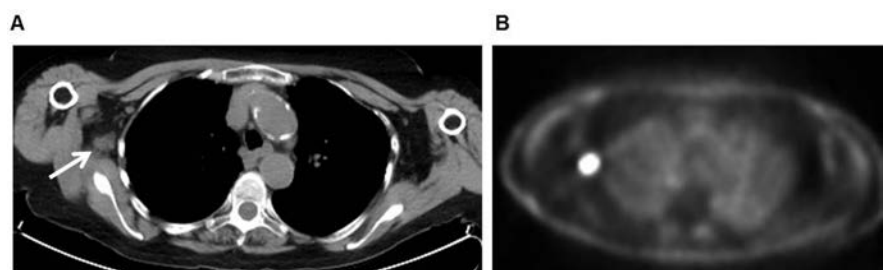
Overexpression of p53 is attributed to malignant transformation, as was observed in our specimen following surgical excision.<sup>3,5</sup>

By definition, MS requires finding a focus of benign spiradenoma within or adjacent to the malignant tumor.<sup>2,3,12</sup> Without an identifiable benign focus, the lesion may be confused with other skin cancers or metastatic disease, as was a concern in our patient. Proper identification of the tumor is paramount, as the management of sweat gland tumors may differ sharply from other similarly presenting neoplasms on the trunk and extremities. While MS

typically arises from *de novo* eccrine spiradenoma, two case reports have documented MS arising over the course of years in an area of previous trauma.<sup>11,13</sup> Additionally, there have been two case reports of rare *de novo* development of MS, not preceded by spiradenoma or trauma. These cases were noted to arise on the forehead and nose, respectively, and the latter was diagnosed synchronous with metastatic colon cancer.<sup>14,15</sup> One previous case of eccrine carcinoma presenting as an ulcerated mass in the breast of a male patient has also been reported.<sup>16</sup> Although there exists one published



**Figure 1.** Histologic features of spiradenocarcinoma arising in association with spiradenoma. A) Pure spiradenoma is characterized by circumscribed nodules composed of slender interanastomosing strands of basaloid epithelial cells with occasional duct formation. B) Pure spiradenocarcinoma composed of solid nodules of atypical basaloid cells. C) Focal connection of spiradenocarcinoma to the epidermis supports a primary cutaneous carcinoma rather than metastatic carcinoma. D) One tumor nodule contained mixed spiradenoma and spiradenocarcinoma. The more basaloid component represents spiradenoma (10×, Hematoxylin & Eosin).



**Figure 2.** Findings on cross-sectional imaging showing bulky adenopathy in the right axilla (A, white arrows) which is highly FDG avid (B).



case report of scalp eccrine carcinoma occurring in a patient with a prior history of radiotherapy for cervical cancer,<sup>17</sup> there are no known cases linking prior radiotherapy to the development of a secondary spiroadenocarcinoma.

Definitive classification of this tumor from other malignancies is crucial in guiding the multimodality treatment recommendations and care for the patient. In verified MS, the mainstay of therapy is surgical excision with 1-3 cm clinical margins that are histologically confirmed as microscopically uninvolved. In the absence of metastatic disease, this approach is considered curative in nature.<sup>2,11</sup>

The limited outcomes data for MS suggest that recurrence is most likely to occur within the first 12-36 months following diagnosis and treatment of the index neoplasm.<sup>12</sup> Regional lymph nodes should be dissected if tumor metastases are diagnosed.<sup>2,7</sup> As was the case in our patient, surgical resection, including axillary lymph node dissection, was indicated in the setting of locally advanced disease including regional metastases.<sup>7</sup> Had this lesion proved to be recurrent metastatic disease from her history of breast carcinoma, multimodality treatments would have included further systemic chemotherapy given the natural history and disease biology of triple negative breast carcinoma. In contrast, there are no data to support the use of adjuvant chemotherapy for malignant adnexal tumors, and the risks of chemotherapy were felt to outweigh the benefits. Overall, disease-specific survival of MS tends to be poor when compared to other malignant cutaneous adnexal tumors. A population-based study revealed the mortality rate of MS to be 21%, which is comparable to a past literature review citing 18%.<sup>7,18</sup> While the overall metastatic rate for malignant cutaneous tumors is estimated at approximately 13%, there are few, if any, data to determine the metastatic rate for MS.<sup>12</sup> The occurrence of metastases has been as high as 39% in one study and as low as 8% in another.<sup>6,12</sup> When MS does metastasize, the dominant sites of failure include the regional lymph nodes, lungs, brain, and liver.<sup>2,7</sup> Local control is crucial, as metastases are rarely reported without preceding local recurrence.<sup>6</sup>

There are limited data regarding the role of adjuvant chemotherapy and radiation in this extremely rare neoplasm. Chemotherapy in

these patients requires further study, with very little evidence available in such a small patient population to support a specific regimen.<sup>3</sup> Tamoxifen therapy has been successfully used in a patient whose cancer was estrogen receptor positive with no evidence of disease recurrence at 41 months of follow-up.<sup>2</sup> Given the inconsistent success of adjuvant therapy, the importance of early treatment and local surgical control cannot be overemphasized.

## Conclusions

One should keep in mind spiradenocarcinoma when presented with rapid morphological changes of a long-standing cutaneous lesion in a patient. Diagnosis must be confirmed histologically, as these tumors are exceedingly rare, and may be originally attributed to metastatic recurrence of a metachronous cancer or other chronic, non-healing wound. Treatment of choice is wide surgical resection with a prolonged period of follow-up due to the variable course of this disease and metastatic potential. Staining for breast carcinoma markers, including HER2/Neu, may reveal potential targets for therapy.

## References

1. Sinha A, Pal S, Phukan JP. Fine needle aspiration cytology of eccrine spiradenoma of back: report of a rare case. *J Lab Physicians* 2014;6:130-2.
2. Mirza I, Kloss R, Sieber SC. Malignant eccrine spiradenoma. *Arch Pathol Lab Med* 2002;126:591-4.
3. Ishikawa M, Nakanishi Y, Yamazaki N, et al. Malignant eccrine spiradenoma: a case report and review of the literature. *Dermatol Surg* 2001;27:67-70.
4. Cooper PH, Frierson HF Jr., Morrison AG. Malignant transformation of eccrine spiradenoma. *Arch Dermatol* 1985;121:1445-8.
5. Ribeiro-Silva A, Shaletich C, Careta RS, et al. Spiradenocarcinoma of the breast arising in a long-standing spiradenoma. *Ann Diagn Pathol* 2004;8:162-6.

6. Tay JS, Tapen EM, Solari PG. Malignant eccrine spiradenoma. Case report and review of the literature. *Am J Clin Oncol* 1997;20:552-7.
7. Martinez SR, Barr KL, Canter RJ. Rare tumors through the looking glass: an examination of malignant cutaneous adnexal tumors. *Arch Dermatol* 2011;147:1058-62.
8. Kersting DW, Helwig EB. Eccrine spiradenoma. *AMA Arch Derm* 1956;73:199-227.
9. Dabska M. Malignant transformation of eccrine spiradenoma. *Pol Med J* 1972;11:388-96.
10. Marendra SA, Otto RA. Adnexal carcinomas of the skin. *Otolaryngol Clin North Am* 1993;26:87-116.
11. Jariwala A, Evans A, McLeod G. Not all stubbed toes are innocuous: a case report of rare malignant eccrine spiradenoma (spiradenocarcinoma) of the toe. *Foot Ankle Surg* 2010;16:e32-3.
12. Granter SR, Seeger K, Calonje E, et al. Malignant eccrine spiradenoma (spiradenocarcinoma): a clinicopathologic study of 12 cases. *Am J Dermatopathol* 2000;22:97-103.
13. Arslan E, Unal S, Cinel L, et al. Malignant eccrine spiradenoma occurring on a traumatized area. *Plast Reconstr Surg* 2002;110:365-7.
14. Hantash BM, Chan JL, Egbert BM, et al. De novo malignant eccrine spiradenoma: a case report and review of the literature. *Dermatol Surg* 2006;32:1189-98.
15. Yildirim S, Akoz T, Akan M, et al. De novo malignant eccrine spiradenoma with an interesting and unusual location. *Dermatol Surg* 2001;27:417-20.
16. McLean SR, Shousha S, Francis N, et al. Metastatic ductal eccrine adenocarcinoma masquerading as an invasive ductal carcinoma of the male breast. *J Cutan Pathol* 2007;34:934-8.
17. Kose R, Coban YK, Ciralik H. Eccrine porocarcinoma arising from preexisting eccrine poroma of the scalp after radiotherapy for cervical cancer. *Dermatol Online J* 2006;12:18.
18. Tanese K, Sato T, Ishiko A. Malignant eccrine spiradenoma: case report and review of the literature, including 15 Japanese cases. *Clin Exp Dermatol* 2010;35:51-5.