

UCLA

UCLA Radiological Sciences Proceedings

Title

Differentiating Hemangioma and Secondary Angiosarcoma of the Breast: Two Case Reports

Permalink

<https://escholarship.org/uc/item/5qp4s78s>

Journal

UCLA Radiological Sciences Proceedings, 4(3)

Authors

Peshkar-Kulkarni, Saloni

Hoyt, Anne

Chow, Lucy

Publication Date

2024

DOI

10.5070/RS44361353

Copyright Information

Copyright 2024 by the author(s). This work is made available under the terms of a Creative Commons Attribution License, available at <https://creativecommons.org/licenses/by/4.0/>

Peer reviewed

Differentiating Hemangioma and Secondary Angiosarcoma of the Breast: Two Case Reports

Peshkar-Kulkarni S, BS¹ | Hoyt AC, MD² | Chow L, MD²

Author Affiliation: ¹ David Geffen School of Medicine at UCLA

² Department of Radiological Sciences, David Geffen School of Medicine at UCLA

Corresponding Authors: S.P-K. (saloni13@ucla.edu)

UCLA Radiol Sci Proc. 2024;4(3):27-32

Abstract: Angiosarcoma (AS) of the breast is a rare malignancy arising from the vascular endothelium. It can develop as a primary tumor or as a secondary tumor, the latter of which is most commonly associated with prior radiation therapy. AS may present in the breast as a palpable mass, unilateral diffuse breast enlargement, skin thickening, erythema, plaque-like violaceous discoloration, or painful nodules. The imaging features of AS vary across imaging modalities. Because AS of the breast is aggressive and prone to early metastasis, prompt detection is crucial to the improvement of generally low five-year survival rates. In this paper, we share one case of AS of the breast and one of a common mimic, hemangioma, with associated imaging and key clinical details that can aid radiologists in the timely identification and diagnosis of AS of the breast.

Keywords: *angiosarcoma, breast cancer, breast imaging, hemangioma*

Introduction

Angiosarcoma (AS) of the breast is a rare and aggressive malignancy that develops from endothelial cells lining the vasculature of the breast. Although AS is rare, the breasts are the most common location.¹ There are two main subtypes of breast AS: primary and secondary, with incidences of 0.0005% and 0.16% respectively.^{2,3} Secondary AS is most commonly associated with radiation treatment and has a mean latency period of 5-7 years post-treatment (range, 1-41 years).⁴ Breast hemangiomas are often difficult to distinguish from breast AS, as the two can have overlapping clinical, imaging, and histological features.⁵ Here, we describe one case of breast AS and one of hemangioma and provide associated imaging and clinical observations that can aid breast radiologists in differentiating these entities.

Key Points

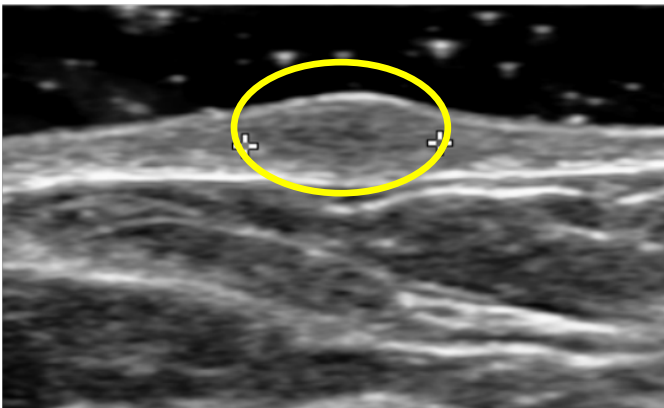
- There are two main types of breast angiosarcoma: one that develops spontaneously (primary) and one that develops years after radiation treatment of the breast (secondary).
- The incidence of secondary breast angiosarcoma is rising due to higher rates of breast conservation therapy for breast cancer, with patients most commonly presenting with new or increased skin thickening on imaging.
- It is important to know how to differentiate between breast angiosarcoma and benign hemangioma, as they often appear similar on imaging and pathology. Size, skin involvement, and certain features on imaging and pathology can be helpful in differentiating the two.

Case 1: Hemangioma

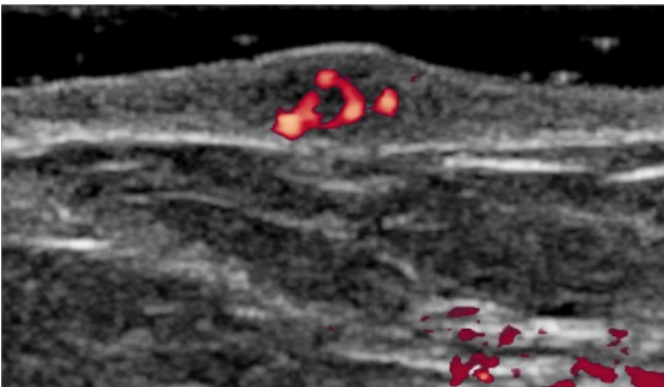
A 69-year-old woman with no prior history of breast cancer presented with a left breast superficial mass. Diagnostic ultrasound (US) showed a 6 mm superficial oval isoechoic intradermal mass with internal vascularity (Figures 1A, 1B). Diagnostic considerations included both hemangioma and primary breast AS. A shave biopsy performed by a dermatologist revealed the mass to be a benign hemangioma that did not necessitate treatment.

Figure 1. Ultrasound of a Mass in Left Breast of a 69-Year-Old Woman (Case 1).

A Diagnostic ultrasound image

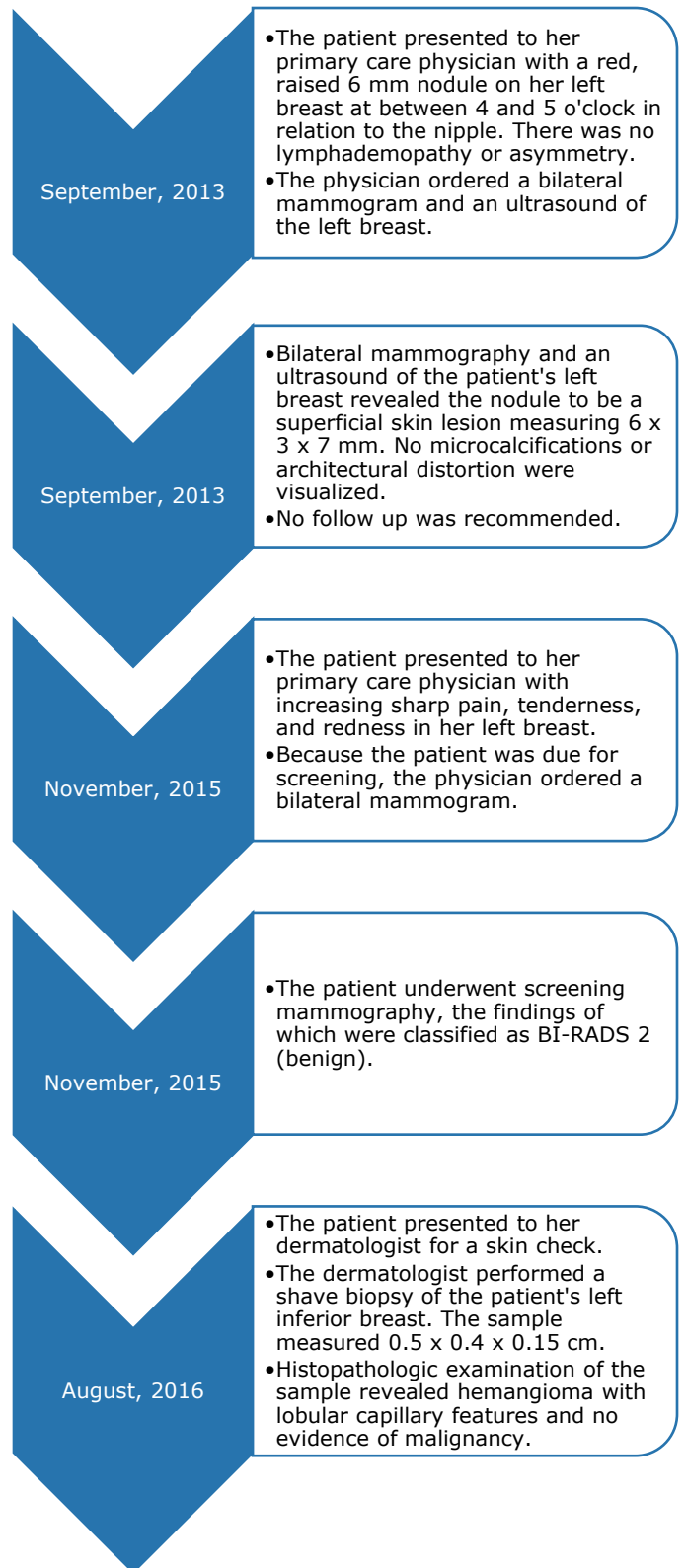


B Power Doppler ultrasound image



(A) Diagnostic US shows a 6 mm superficial oval isoechoic circumscribed intradermal mass (yellow circle). (B) Power Doppler imaging revealed internal vascularity.

Timeline 1. A Timeline of the Diagnosis and Treatment of a Mass in the Left Breast of a 69-Year-Old Woman (Case 1).

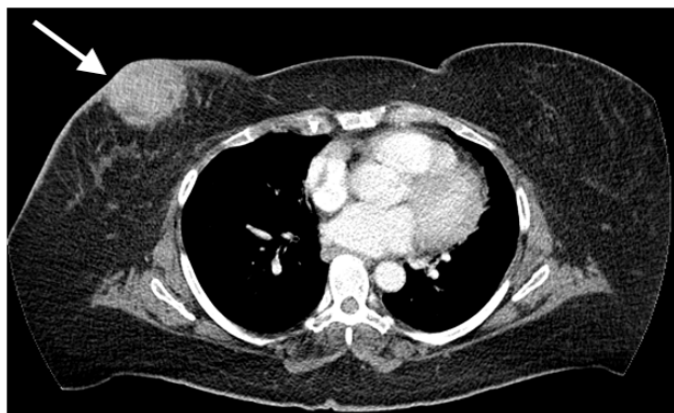

Case 2: Angiosarcoma

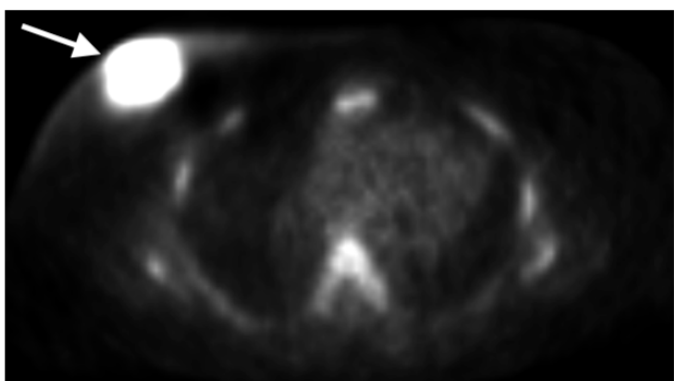
A 71-year-old woman presented with subcutaneous, focal thickening near her right nipple as well as green-colored nipple discharge and periareolar erythema and warmth. She had undergone a right-sided lumpectomy and radiation treatment for invasive ductal carcinoma 10 years prior. In a patient with a history of breast conservation therapy (BCT), skin thickening is normal; however, it is expected to decrease within two years of radiotherapy.⁶ This patient developed skin thickening ten years post-treatment, raising concern for malignancy.⁷

Figure 2. CT and PET of a Mass in the Right Breast of a 71-Year-Old Woman (Case 2).

A Contrast-enhanced CT image



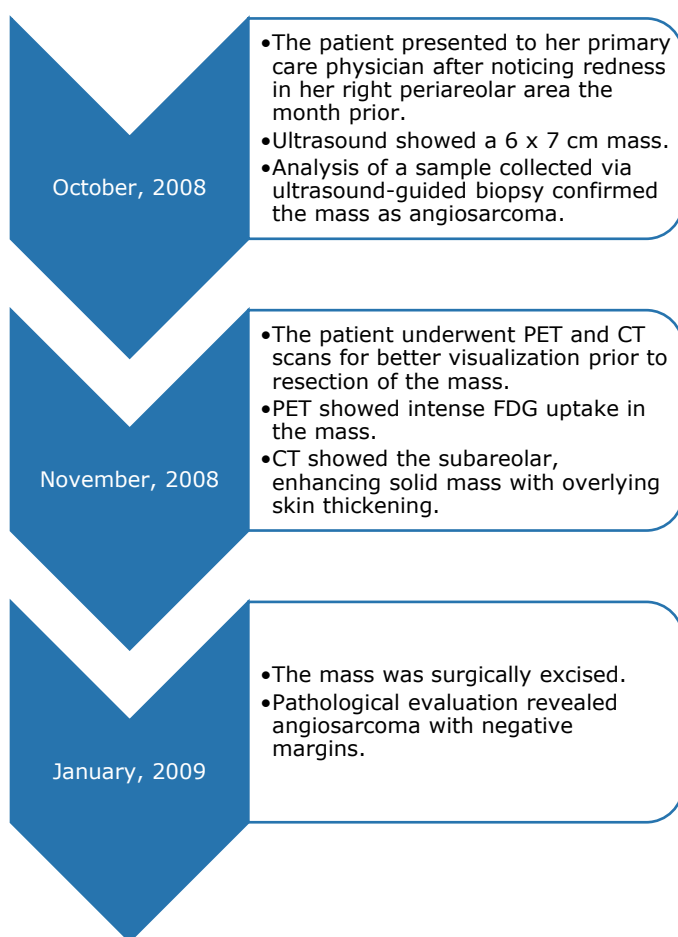
B PET scan image



(A) Axial contrast-enhanced CT of the chest demonstrates a subareolar enhancing solid mass in the right breast with overlying skin thickening. (B) Axial PET scan shows a right breast mass with intense FDG uptake.

Ultrasound of the right breast revealed a 6 x 7 cm mass, and results from histopathologic examination of tissue collected via ultrasound-guided core needle biopsy revealed high-grade angiosarcoma. Contrast-enhanced computed tomography (CT) of the chest and a positron emission tomography (PET) scan were ordered for better visualization prior to surgical resection of the mass. CT (Figure 2A) demonstrated the subareolar enhancing solid mass in the right breast with overlying skin thickening. PET showed the right breast mass with intense FDG uptake (Figure 2B). Though CT and PET are not used broadly to diagnose breast lesions, they can be used for breast cancer staging.⁷ Salminen et al⁸ found that the sensitivities of CT and MRI were 84% and 92%, respectively, in the evaluation of secondary breast AS.

Timeline 2. A Timeline of the Diagnosis and Treatment of a Mass in the Right Breast of a 71-Year-Old Woman (Case 2).



Discussion

Primary AS accounts for 0.04% of malignant breast cancers and has a mean age of onset of 40 years.² The majority of patients with primary AS present with a palpable painless breast mass, but some patients may have unilateral diffuse breast enlargement without a mass.^{2,9} Tumors frequently arise within the breast parenchyma and may involve the skin.⁴

The risk of secondary AS is 0.05% at 10 years post-lumpectomy and radiation, and 0.5% at 30 years.¹⁰ The median age of onset is 70 years.⁴ The incidence of secondary AS is increasing, likely due to increasing use of BCT, which includes lumpectomy followed by radiation therapy.⁴ The

population-based incidence of AS has increased by 4% yearly since 1975.¹⁰

The presentation of secondary AS can include any of the following: new skin thickening, erythema, plaque-like cutaneous violaceous discoloration, a raised painful nodule, and an associated underlying mass.⁴ This presentation can appear benign, especially in the absence of a mass, leading to a delay in diagnosis. Cahan et al¹¹ proposed the following diagnostic criteria for secondary AS: (1) the sarcoma should arise in the area that was treated with radiation, (2) a latent period must exist between radiation and sarcoma development, and (3) the sarcoma should be confirmed histologically.

Table 1. Comparison of Imaging Features of Primary Angiosarcoma and Secondary Angiosarcoma.

Imaging features by imaging modality	Primary angiosarcoma	Secondary angiosarcoma
Appearance on mammography	Non-calcified mass, ranging from 3 to 6 cm in diameter	Diffuse or focal skin thickening and a possible underlying mass
Appearance on ultrasound	Mass of areas of mixed hypo- and hyperechogenicity ³	Nonspecific: may include skin thickening or an irregular mass, which may show increased blood flow on Doppler ultrasound ¹¹
Appearance on MRI	<ul style="list-style-type: none"> Area of low to intermediate signal intensity with T1-weighting Area of high signal intensity with T2-weighting³ 	<ul style="list-style-type: none"> Hyperintense skin thickening on T2-weighting Possible hypo- or hyperintense skin lesions⁷
Appearance on CT	Heterogenous enhancing mass ²	<ul style="list-style-type: none"> Heterogenous enhancing mass² Skin thickening¹²
Appearance on PET	Focal intense uptake of fludeoxyglucose (FDG). ⁶	Focal intense uptake of fludeoxyglucose (FDG). ⁶

Table 2. Comparison of Imaging Features of Angiosarcoma and Hemangioma.

Features	Angiosarcoma	Hemangioma
Diameter	> 2 cm	< 2 cm
Definition	Infiltrative pattern with architectural distortion	Sharply defined
Appearance on ultrasound	Superficial circumscribed mass with or without calcifications	Superficial circumscribed mass with or without calcifications
Appearance on color Doppler ultrasound	Possible hypervascularity	Hypervascularity

The imaging features of primary AS compared to secondary AS are summarized in Table 1. If primary AS is visible on mammography, it is typically a non-calcified mass, ranging from 3 to 6 cm in diameter.¹⁰ One study¹⁰ found that primary AS was mammographically occult in 33% of cases. Mammographic findings associated with secondary AS include diffuse or focal skin thickening and a possible underlying mass (Figure 1). On ultrasound, primary AS may present as a mass of areas of mixed hypo- and hyperechogenicity.³ Secondary AS ultrasound findings are nonspecific and may include skin thickening or an irregular mass, which may show increased blood flow on Doppler ultrasound.⁷ On MRI, primary AS appears as an area of low to intermediate signal intensity with T1-weighting and as an area of high signal intensity with T2-weighting.³ Secondary AS appears as hyperintense skin thickening on T2-weighting and possible hypo- or hyperintense skin lesions.¹² In both primary and secondary breast AS, CT may show a heterogeneous enhancing mass.² In secondary breast AS, CT may also show skin thickening.¹³ Some case reports show that PET studies of primary and secondary breast AS show focal intense uptake of fludeoxyglucose (FDG).⁹ PET studies may be useful in evaluating therapeutic response.¹³

As in the first case reported here, benign hemangioma and breast AS (whether primary or secondary) can be generally difficult to distinguish (summarized in Table 2). Hemangiomas are typically smaller than 2 cm in diameter, compared to AS which is typically larger than 2 cm in diameter.¹² Hemangiomas tend to be more sharply defined, whereas angiosarcoma can have an infiltrative pattern and cause architectural distortion.¹⁰ Both entities can appear on mammography and US as a circumscribed mass that is typically superficial, with or without calcifications, but hemangiomas may be isoechoic and therefore difficult to identify on US.^{5,11} Color Doppler may show hypervascularity in AS, further complicating the entity's distinction from hemangioma.² Because of the variable imaging appearance of AS, special attention should be paid to radiology-pathology concordance when diagnostic considerations include AS and hemangioma.

Because AS has a poor prognosis, a tendency to metastasize early, and a nonspecific clinical presentation, it is crucial that radiologists recognize the warning signs of this rare entity. By learning to recognize the imaging signs of AS and by establishing concordance between radiological and pathological evidence, radiologists can differentiate AS from benign mimics such as hemangioma and improve treatment and outcomes for patients.

Conclusion

Angiosarcoma is a rare entity with a nonspecific presentation and a poor prognosis, making its prompt and accurate diagnosis difficult and crucial. Especially in the breast, AS may be difficult to distinguish from benign entities like hemangioma with imaging alone. With the two cases presented here, we have illustrated the imaging characteristics that can help differentiate AS from benign mimics. In addition to recognizing the appearance of AS on various breast imaging modalities, it is also critical to establish concordance between radiologic and pathologic findings.

Author Contributions

Conceptualization, A.C.H. and L.C.; Acquisition, analysis, and interpretation of data, A.C.H. and L.C.; Writing – original draft preparation, S.P.-K.; Review and editing, A.C.H. and L.C.; Supervision, L.C. All authors agree to be accountable for all aspects of the work in ensuring that questions related to the accuracy or integrity of any part of the work are appropriately investigated and resolved. All authors had full access to all the data in the study and take responsibility for the integrity of the data and the accuracy of the data analysis.

Disclosures

None to report.

References

1. Stout AP. Hemangio-endothelioma: A tumor of blood vessels featuring vascular endothelial cells. *Ann Surg.* 1943;118(3):445-464. doi:[10.1097/0000658-194309000-00014](https://doi.org/10.1097/0000658-194309000-00014)

2. Chesebro AL, Chikarmane SA, Gombos EC, Giardino AA. Radiation-associated angiosarcoma of the breast: what the radiologist needs to know. *AJR Am J Roentgenol*. 2016;207(1):217-225. doi:[10.2214/AJR.15.15888](https://doi.org/10.2214/AJR.15.15888)
3. Liberman L, Dershaw DD, Kaufman RJ, Rosen PP. Angiosarcoma of the breast. *Radiology*. 1992;183(3):649-654. doi:[10.1148/radiology.183.3.1584913](https://doi.org/10.1148/radiology.183.3.1584913)
4. Strobbe LJ, Peterse HL, van Tinteren H, Wijnmaalen A, Rutgers EJ. Angiosarcoma of the breast after conservation therapy for invasive cancer, the incidence and outcome. An unforeseen sequela. *Breast Cancer Res Treat*. 1998;47(2):101-109. doi:[10.1023/a:1005997017102](https://doi.org/10.1023/a:1005997017102)
5. Shin J, Kapoor M, Patel M, Krishnamurthy S, Whitman GJ. Comparing breast hemangiomas to breast angiosarcomas: an imaging based review. *Curr Probl Diagn Radiol*. 2023;52(3):212-219. doi:[10.1067/j.cpradiol.2023.01.002](https://doi.org/10.1067/j.cpradiol.2023.01.002)
6. Peters ME, Fagerholm MI, Scanlan KA, Voegeli DR, Kelcz F. Mammographic evaluation of the postsurgical and irradiated breast. *Radiographics*. 1988;8(5):873-899. doi:[10.1148/radiographics.8.5.3227129](https://doi.org/10.1148/radiographics.8.5.3227129)
7. Conti M, Morciano F, Rossati C, et al. Angiosarcoma of the Breast: Overview of Current Data and Multimodal Imaging Findings. *J Imaging*. 2023;9(5):94. Published 2023 Apr 30. doi:[10.3390/jimaging9050094](https://doi.org/10.3390/jimaging9050094)
8. Salminen SH, Sampo MM, Böhling TO, et al. Radiation-associated angiosarcoma of the breast: analysis of diagnostic tools in a registry-based population. *Acta Radiologica*. 2022;63(1):22-27. doi:[10.1177/0284185120980142](https://doi.org/10.1177/0284185120980142)
9. Yang WT, Hennessy BT, Dryden MJ, Valero V, Hunt KK, Krishnamurthy S. Mammary angiosarcomas: imaging findings in 24 patients. *Radiology*. 2007;242(3):725-734. doi:[10.1148/radiol.2423060163](https://doi.org/10.1148/radiol.2423060163)
10. Mahdi Y, Rouas L, Malihy A, Lamalmi N, Alhamany Z. Diagnostic difficulties of primary angiosarcoma of the breast: a case report. *J Med Case Rep*. 2018;12(1):228. doi:[10.1186/s13256-018-1772-2](https://doi.org/10.1186/s13256-018-1772-2)
11. Glazebrook KN, Magut MJ, Reynolds C. Angiosarcoma of the breast. *AJR Am J Roentgenol*. 2008;190(2):533-538. doi:[10.2214/AJR.07.2909](https://doi.org/10.2214/AJR.07.2909)
12. Shah S, Rosa M. Radiation-associated angiosarcoma of the breast: Clinical and pathologic features. *Arch Pathol Lab Med*. 2016;140(5):477-481. doi:[10.5858/arpa.2014-0581-RS](https://doi.org/10.5858/arpa.2014-0581-RS)
13. Chikarmane SA, Gombos EC, Jagadeesan J, Raut C, Jagannathan JP. MRI findings of radiation-associated angiosarcoma of the breast (RAS). *J Magn Reson Imaging*. 2015;42(3):763-770. doi:[10.1002/jmri.24822](https://doi.org/10.1002/jmri.24822)