

UCSF

UC San Francisco Previously Published Works

Title

Invasive facial fungal infections: Orofacial soft-tissue infiltration in immunocompromised patients

Permalink

<https://escholarship.org/uc/item/5s02g8m6>

Journal

Radiology Case Reports, 8(2)

ISSN

1930-0433

Authors

Jun, Peter
Russell, Matthew
El-Sayed, Ivan
[et al.](#)

Publication Date

2013

DOI

10.2484/rcr.v8i2.813

Peer reviewed

Invasive facial fungal infections: Orofacial soft-tissue infiltration in immunocompromised patients

Peter Jun, MD; Matthew Russell, MD; Ivan El-Sayed, MD; William Dillon, MD; and Christine Glastonbury, MD

Invasive facial fungal infections affect the orofacial soft tissues in immunocompromised patients and can cause significant morbidity and mortality. Primary infection occurs from direct inoculation of the skin surface, while secondary infection occurs from extension from an adjacent sinonasal process. The imaging features of secondary infection are similar to acute fulminant invasive fungal sinusitis with infiltration of the orofacial soft tissues in combination with sinonasal disease. However, primary infection can occur in the absence of sinonasal disease, making diagnosis challenging. We present two cases, one of primary and one of secondary invasive facial fungal infection. Careful scrutiny of the orofacial soft tissues in immunocompromised patients is necessary to detect invasive facial fungal infections so that appropriate surgical and medical therapies can maximize patient outcomes.

Case report 1

A 39-year-old female with refractory AML in blast crisis and an absolute neutrophil count under 500 cells/microliter presented with nasal drainage that was unresponsive to antibiotic treatment. A CT scan showed a new right-nasal-cavity mucosal edema with subtle orofacial soft-tissue infiltration (Fig. 1A), compared to CT performed two weeks earlier for unrelated facial trauma (Fig. 1B). There was no paranasal sinus opacification or evidence of bone erosion. MRI performed the following day demonstrated further orofacial soft-tissue infiltration and nonenhancing right-nasal-cavity mucosa (Figs. 1C, D). Extensive drainage and crusting at the right nares prevented nasal endoscopy, but cultures of the drainage grew *Mucormycosis* species.

Antifungal therapy was initiated, and surgical debridement of the necrotic nasal mucosa, right inferior turbinate, and nasal septum was performed. Given the patient's refractory AML and blast crisis, the patient was placed on palliative care and died from sepsis 7 days later.

Case report 2

A 15-year-old male with newly diagnosed hemophagocytic lymphohistiocytosis and an absolute neutrophil count under 500 cells/microliter developed fever and facial swelling ten days following induction chemotherapy. CT and MRI showed minimal orofacial soft-tissue infiltration without paranasal sinus, nasal cavity, or bone erosion (Figs 2A, B). Nasal endoscopy demonstrated healthy mucosa without sinonasal disease. Given these findings, the facial pain and swelling were ascribed to cellulitis, and the patient was placed on antibiotics.

Over the next four days, the patient experienced progressive facial swelling and pain and developed a right cheek eschar. Repeated nasal endoscopy demonstrated necrotic mucosa involving the nasal septum, floor, and side walls. Biopsies revealed invasive *Mucormycosis* species. Repeated MRI confirmed these findings with worsening orofacial soft-tissue infiltration and new maxillary sinus mucosal edema (Figs. 2C, D).

Given the poor prognosis from the hemophagocytic lymphohistiocytosis, surgical debridement was deferred and medical management was optimized. Chemotherapy was

Citation: Jun P, Russell M, El-Sayed I, Dillon W, Glastonbury C. Invasive facial fungal infections; Orofacial soft-tissue infiltration in immunocompromised patients. *Radiology Case Reports*. (Online) 2013;8:813.

Copyright: © 2013 The Authors. This is an open-access article distributed under the terms of the Creative Commons Attribution-NonCommercial-NoDerivs 2.5 License, which permits reproduction and distribution, provided the original work is properly cited. Commercial use and derivative works are not permitted.

Drs. Jun and Dillon are in the Department of Radiology, Neuroradiology; Drs. Russell and El-Sayed are in the Department of Otolaryngology and Head and Neck Surgery; Dr. Glastonbury has an appointment in both; all are at the University of California, San Francisco CA. Contact Dr. Jun at peter.jun@ucsf.edu.

Competing Interests: The authors have declared that no competing interests exist.

DOI: 10.2484/rcr.v8i2.813

Invasive facial fungal infections: Orofacial soft-tissue infiltration in immunocompromised patients

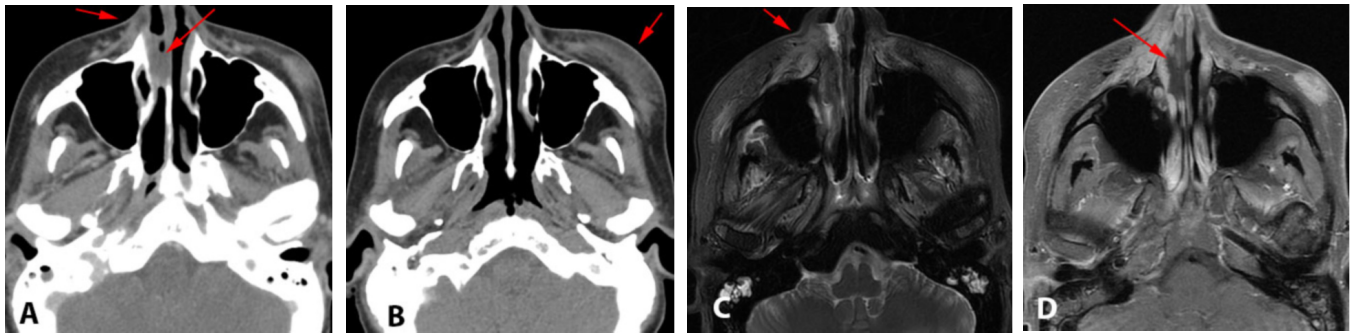


Figure 1. 39-year-old female with refractory AML in blast crisis presented with nasal drainage unresponsive to antibiotic treatment. (A) Noncontrast sinus CT demonstrates an opacified right-nasal-cavity and subtle right-orofacial soft-tissue infiltration (arrow) with adjacent nasal-cavity mucosal edema. (B) Noncontrast facial CT performed for trauma two weeks earlier demonstrates a hematoma (arrow), but normal orofacial soft tissue. (C) T2-weighted and (D) T1-weighted post-gadolinium, fat-saturated MRI performed on Day 2 demonstrates progression, with worsening orofacial soft-tissue infiltration and nonenhancing nasal cavity mucosa (arrows).

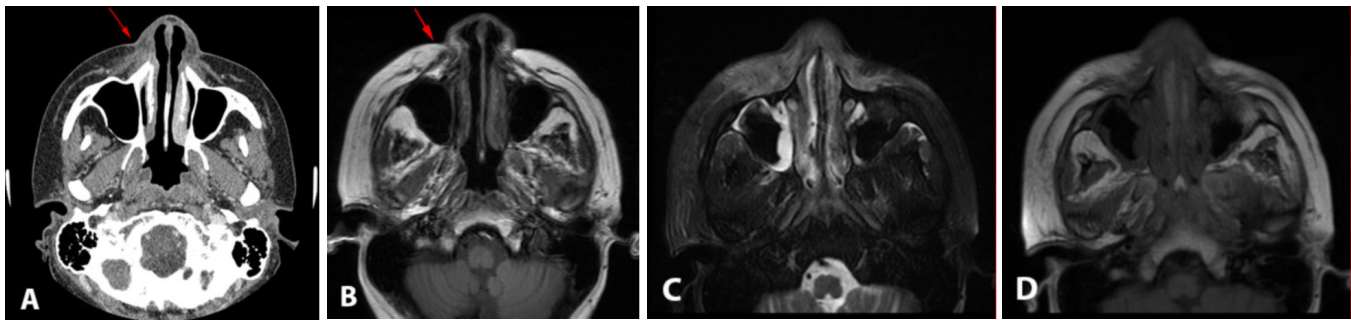


Figure 2. 15-year-old male with hemophagocytic lymphohistiocytosis developed neutropenic fever and facial swelling following induction chemotherapy. (A) Noncontrast sinus CT and (B) T1-weighted MRI demonstrate right orofacial soft-tissue infiltration without sinonasal disease (arrows). T2-weighted (C) and T1-weighted (D) MRI on Day 4 demonstrate significant disease progression, with involvement of the nasal cavity and maxillary sinuses.

held, and multiple antifungal agents, granulocyte-colony stimulating factor, and granulocyte infusions were administered. The patient remained neutropenic and died from sepsis 10 days later.

Discussion

Orofacial soft-tissue infiltration in an immunocompromised patient is an independent radiologic sign of invasive facial fungal infections. The normal orofacial soft tissues are composed of well-defined facial muscles separated by intact planes of fat. This relationship is maintained in nearly all normal patients, even in the presence of inflammatory sinus disease (1). In cases of invasive facial fungal infections, these planes are disrupted when fungal species disseminate intravascularly, causing an infectious vasculitis with consequent soft-tissue hemorrhage, thrombosis, and infarction (2).

Secondary invasive facial fungal infections are an extension of acute fulminant invasive fungal sinusitis and therefore share similar imaging features. Nasal-cavity opacification has been described as the earliest sign of invasive fun-

gal disease; however, this finding can be extremely subtle and can also be seen with benign inflammatory sinusitis (3, 4). The presence of nonenhancing mucosa adds specificity, which pathologically correlates with necrotic mucosa (5, 6). From the nasal cavity, disease spreads to the maxillary sinus and orofacial soft tissues. Bone erosion and intraorbital and intracranial invasion are late findings indicative of advanced disease (7, 8).

Primary invasive facial fungal infections begin in the orofacial soft tissues and are not expected to have sinonasal involvement until later in their course. The pathogenesis of primary invasive facial fungal infections is likely similar to primary disease outside of the head and neck and has been well described in immunocompromised patients, particularly pediatric patients with hematologic malignancies (9). Iatrogenic trauma to the protective dermal layers by adhesives and catheters allows fungus access to the subcutaneous tissues, allowing for dissemination (10, 11). In our case of primary disease, direct inoculation may have occurred from the adhesives used to secure a feeding tube. The absence of clinical or imaging findings of sinonasal disease

Invasive facial fungal infections: Orofacial soft-tissue infiltration in immunocompromised patients

highlights the need to raise the possibility of an invasive fungal infection even when only orofacial soft-tissue infiltration is seen on imaging.

Orofacial soft-tissue infiltration can occur in conditions aside from invasive fungal infections. Trauma, dental disease, bacterial cellulitis, and (more recently) dermal fillers can mimic the imaging appearance of invasive facial fungal infections. Dermal fillers are unique in that they are frequently used to treat retroviral lipodystrophy in HIV patients, a subset at high risk for invasive fungal disease (12). Hyaluronic acid is most commonly used, but other agents include collagen, silicone, and polytetrafluoroethylene. The CT and MRI appearance of these agents vary, but a transient inflammatory reaction is common, with occasional occurrences of a severe chronic inflammatory response with diffuse swelling and enhancement of the orofacial soft tissues (13, 14). Knowledge of the appropriate clinical history is necessary to avoid this potential pitfall.

The treatment of invasive facial fungal infections is similar to that for other invasive fungal diseases and is based on a three-pronged approach: antifungal therapy, surgical debridement, and immune recovery. Antifungal therapy and surgical debridement limit spread and disease burden, but ultimately immune recovery is the best predictor of survival (5). Early recognition of the imaging signs of primary and secondary invasive facial fungal infections allows for appropriate diagnostic testing and treatment, thereby offering the patient the best chances for recovery.

References

1. Silverman CS, Mancuso AA. Periantral soft-tissue infiltration and its relevance to the early detection of invasive fungal sinusitis: CT and MR findings. *AJNR Am J Neuroradiol*. 1998 Feb;19(2):321-5. [PubMed]
2. Gowing NF, Hamlin IM. Tissue reactions to *Aspergillus* in cases of Hodgkin's disease and leukaemia. *J Clin Pathol*. 1960 Sep;13:396-413. [PubMed]
3. DelGaudio JM, Swain RE, Jr., Kingdom TT, Muller S, Hudgins PA. Computed tomographic findings in patients with invasive fungal sinusitis. *Arch Otolaryngol Head Neck Surg*. 2003 Feb;129(2):236-40. [PubMed]
4. Howells RC, Ramadan HH. Usefulness of computed tomography and magnetic resonance in fulminant invasive fungal rhinosinusitis. *Am J Rhinol*. 2001 Jul-Aug;15(4):255-61. [PubMed]
5. Parikh SL, Venkatraman G, DelGaudio JM. Invasive fungal sinusitis: a 15-year review from a single institution. *Am J Rhinol*. 2004 Mar-Apr;18(2):75-81. [PubMed]
6. Saffar S, Carpenter JS, Roberts TD, Bailey N. The "Black Turbinate" sign: An early MR imaging finding of nasal mucormycosis. *AJNR Am J Neuroradiol*. 2010 Apr;31(4):771-4. [PubMed]
7. Aribandi M, McCoy VA, Bazan C, 3rd. Imaging features of invasive and noninvasive fungal sinusitis: a review. *Radiographics*. 2007 Sep-Oct;27(5):1283-96. [PubMed]
8. Som PM, Curtin HD. Chronic inflammatory sinonasal diseases including fungal infections. The role of imaging. *Radiol Clin North Am*. 1993 Jan;31(1):33-44. [PubMed]
9. Burgos A, Zaoutis TE, Dvorak CC, Hoffman JA, Knapp KM, Nania JJ, et al. Pediatric invasive aspergillosis: a multicenter retrospective analysis of 139 contemporary cases. *Pediatrics*. 2008 May;121(5):e1286-94. [PubMed]
10. Baraia J, Munoz P, Bernaldo de Quiros JC, Bouza E. Cutaneous mucormycosis in a heart transplant patient associated with a peripheral catheter. *Eur J Clin Microbiol Infect Dis*. 1995 Sep;14(9):813-5. [PubMed]
11. Mead JH, Lupton GP, Dillavou CL, Odom RB. Cutaneous *Rhizopus* infection. Occurrence as a postoperative complication associated with an elasticized adhesive dressing. *JAMA*. 1979 Jul 20;242(3):272-4. [PubMed]
12. Lafaurie M, Dolivo M, Porcher R, Rudant J, Madeleine I, Molina JM. Treatment of facial lipoatrophy with intradermal injections of poly lactic acid in HIV-infected patients. *J Acquir Immune Defic Syndr*. 2005 Apr 1;38(4):393-8. [PubMed]
13. Ginat DT, Schatz CJ. Imaging features of midface injectable fillers and associated complications. *AJNR Am J Neuroradiol*. 2012 Jul 26. [PubMed]
14. Judodihardjo H, Dykes P. Objective and subjective measurements of cutaneous inflammation after a novel hyaluronic acid injection. *Dermatol Surg*. 2008 Jun;34 Suppl 1:S110-4. [PubMed]