

UC Davis

UC Davis Previously Published Works

Title

Feline mycobacterial disease in northern California: Epidemiology, clinical features, and antimicrobial susceptibility.

Permalink

<https://escholarship.org/uc/item/5st469v7>

Journal

Journal of veterinary internal medicine, 35(1)

ISSN

0891-6640

Authors

Munro, Matthew JL

Byrne, Barbara A

Sykes, Jane E

Publication Date

2021

DOI

10.1111/jvim.16013

Peer reviewed

STANDARD ARTICLE

Feline mycobacterial disease in northern California: Epidemiology, clinical features, and antimicrobial susceptibility

Matthew J. L. Munro^{1,2}  | Barbara A. Byrne³ | Jane E. Sykes^{1,4}

¹Veterinary Medical Teaching Hospital, School of Veterinary Medicine, University of California, Davis, Davis, California

²Department of Veterinary Clinical Sciences, The Melbourne Veterinary School, University of Melbourne, Werribee, Victoria, Australia

³Department of Pathology, Microbiology, and Immunology, School of Veterinary Medicine, University of California, Davis, Davis, California

⁴Department of Medicine and Epidemiology, School of Veterinary Medicine, University of California, Davis, Davis, California

Correspondence

Matthew J. L. Munro, Department of Veterinary Clinical Sciences, The Melbourne Veterinary School, University of Melbourne, 250 Princes Highway, Werribee, VIC 3030, Australia.

Email: matt.munro@unimelb.edu.au

Abstract

Background: Mycobacterial infections in cats are challenging to treat and incompletely described.

Hypothesis/objectives: To describe the features of mycobacterial infections in cats from northern California.

Animals: Nineteen cats, all with nontuberculous mycobacterial (NTM) infections; 4 with *Mycobacterium avium* infection, 15 with rapid-growing mycobacterial (RGM) infection.

Methods: Retrospective study. Cases with positive mycobacterial culture, species identification, and susceptibility testing were included. Descriptive statistics were used. Fisher's exact test and Mann-Whitney *U* test were used for comparisons between *M avium* and RGM infections ($P \leq .05$).

Results: Rapid-growing mycobacterial cases included *Mycobacterium smegmatis* (9), *Mycobacterium fortuitum* (4), *Mycobacterium abscessus* (1), and *Mycobacterium thermoresistibile* (1). *Mycobacterium avium* infections were more likely than RGM infections to be disseminated (3/4 vs 0/15; $P = .004$). Disease of the skin/subcutis (15/15 vs 0/4; $P < .001$) and outdoor access (14/15 vs 0/4; $P = .001$) were primary features of RGM infections. Resistance to fluoroquinolones and aminoglycosides was common among *M avium* isolates. A high prevalence of resistance to third- and fourth-generation cephalosporins was noted in RGM species. Death/euthanasia was noted only in *M avium* cases (3/4). Twelve of 15 cats with RGM infection had available follow-up; 4 of these cats achieved remission.

Conclusions and Clinical Importance: The most prevalent RGM species isolated from cats from northern California are *M smegmatis* and *M fortuitum*. Susceptibility to prescribed antimicrobials does not appear to guarantee treatment success. Combination drug treatment is recommended. Repeat culture and susceptibility testing should be performed when disease is persistent/relapsing.

KEYWORDS

atypical bacteria, antimicrobial, cutaneous, *panniculitis*, systemic, treatment

Abbreviations: FeLV, feline leukemia virus; FIV, feline immunodeficiency virus; LJ, Lowenstein-Jensen slant; MAC, *Mycobacterium avium* complex; MALDI-TOF MS, matrix-assisted laser-desorption ionization time-of-flight mass spectrometry; MIC, minimum inhibitory concentration; NJHML, National Jewish Health Mycobacteriology Laboratory; NTM, nontuberculous mycobacteria; PCR, polymerase chain reaction; RGM, rapid-growing NTM spp.; SGM, slow-growing NTM spp.; TMS, trimethoprim sulfamethoxazole.

This is an open access article under the terms of the Creative Commons Attribution-NonCommercial License, which permits use, distribution and reproduction in any medium, provided the original work is properly cited and is not used for commercial purposes.

© 2020 The Authors. *Journal of Veterinary Internal Medicine* published by Wiley Periodicals LLC, on behalf of the American College of Veterinary Internal Medicine.

1 | INTRODUCTION

Mycobacterial infections constitute a global health challenge in humans and domestic animals.¹ *Mycobacterium* spp. have been classified as belonging to the *Mycobacterium tuberculosis* complex, nontuberculous mycobacteria (NTM) including rapid- and slow-growing species, and lepromatous mycobacteria/feline leprosy syndrome.² Rapid-growing nontuberculous mycobacteria (RGM) include *Mycobacterium fortuitum*, *Mycobacterium abscessus*, and *Mycobacterium smegmatis*.² The *Mycobacterium avium* complex (MAC) constitutes a group of slow-growing nontuberculous mycobacteria (SGM).² These groups differ in their epidemiology, pathogenesis, clinical findings, zoonotic potential, and response to treatment. Although the number of contributions to the veterinary literature that describe mycobacterial infections in cats is growing, a paucity of information remains on this topic.

The prevalence of mycobacterial disease in cats exhibits geographic variation.³⁻¹¹ In the United States, MAC organisms, specifically *M avium*, and RGM infections appear to predominate based on descriptions in limited case series^{10,12} and isolated case reports.¹³⁻¹⁶ Mycobacterial species associated with RGM infections have been described in 6¹⁷ and 11¹⁸ cats from northern California, and 10 cats from Florida.¹¹ Predominant species reported in northern California included *M fortuitum*^{17,18} and *Mycobacterium chelonae-abscessus*¹⁸; *M fortuitum* and *M abscessus* were most prevalent in Florida.¹¹

Of the most common mycobacterial infections in cats in the United States, RGM infections generally manifest clinically as disease of the skin and subcutis with or without peripheral lymph node involvement.^{2,3,6,9,11,17-20} Extra-cutaneous and disseminated disease are more typical of MAC infections,^{3,10,12,14,16} however reports of systemic RGM disease also exist.²¹⁻²³ Although immunocompromise might predispose to *M avium* infection,²⁴⁻²⁶ disease has been documented in apparently immunocompetent cats.¹⁰ Siamese, Abyssinian, and Somali breeds may be predisposed.^{2,10,12} Aside from *M avium*, RGM species are associated with the vast majority of infections and are often associated with a history of trauma (eg, cat fights/bites) in otherwise healthy cats with no known breed predisposition.^{2,3,6,9,11,17-20} Overall, prognosis is variable and, in cases that respond to antimicrobial treatment, treatment is often prolonged with risk of relapse.^{3,9-13,19}

Tenets of treatment for mycobacterial infections include long-term combination antimicrobial treatment to maximize chance of success and limit risk of development of resistance.^{2,19,27} Surgical resection of affected tissues in combination with antimicrobial treatment may contribute to treatment success in some cases.^{9,19} Ideally, treatment should be guided by species identification and susceptibility data. However, as challenges pertain to acquiring these data, an understanding of mycobacterial species prevalence and the variations in their respective susceptibility patterns would be advantageous in order to provide appropriate empiric treatment. Unfortunately, only a few studies providing these data have been published in the veterinary literature, that have been limited in scope to RGM.^{9,11,17,18,28-30}

The aims of this retrospective study were to describe the epidemiology, clinical features, and antimicrobial susceptibility patterns of mycobacterial species isolated from cats examined at a referral hospital in the western United States.

2 | MATERIALS AND METHODS

2.1 | Cases

The electronic medical record system at the University of California, Davis William R. Pritchard Veterinary Medical Teaching Hospital was reviewed to identify specimen submissions to the veterinary microbiology service for mycobacterial culture. The time period searched was 1998 to 2018 using the prefix “mycobact” as a search term; only specimens from cats were included.

For study inclusion, a positive mycobacterial culture from either the University of California, Davis William R. Pritchard Veterinary Medical Teaching Hospital microbiology service or from the National Jewish Health Mycobacteriology Laboratory (NJHML) was required, together with subsequent species identification and NJHML susceptibility data. This precluded inclusion of lepromatous mycobacteria cases.

For included cases, medical records were reviewed and information was collected regarding signalment, environment (ie, outdoor access), feline immunodeficiency virus (FIV)/feline leukemia virus (FeLV) status, concurrent disease/medications, duration of clinical signs before definitive diagnosis, previous antimicrobial treatment, disease manifestation/s, other diagnostic testing performed, treatment (including surgery), response to antimicrobial drug treatment, and outcome (including remission, relapse, and death/euthanasia).

Disease associated with MAC was categorized as localized (single body system) or disseminated. Severity of RGM infection was stratified by extent of disease at first examination at University of California, Davis William R. Pritchard Veterinary Medical Teaching Hospital. Mild disease was defined as single, localized lesions. Severe disease included regionally extensive pathology and multifocal lesions. In RGM cases, partial remission was defined as a >50% improvement in lesions within the first 3 months of treatment but with some degree of persistent signs over the course of follow-up. Complete remission constituted cases with resolved lesions, including those continuing to receive antibiotic treatment. Surgical intervention in RGM cases was described as marginal excision when affected tissue was excised with marrow margins or as resection with wide margins with or without the use of reconstructive techniques.

2.2 | Culture, identification, and susceptibility testing

Mycobacterial cultures for detection of RGM at our institutional veterinary microbiology laboratory were performed by direct inoculation of swab, aspirate material, or macerated tissue specimens on to 5%

sheep blood and rose agars (Hardy Diagnostics, Santa Maria, California). No decontamination step was performed. Media were incubated at 35°C in the presence of 5% CO₂. A blood culture from 1 cat was subcultured to 5% sheep blood agar after 1, 2, and 5 days of incubation at 35°C. Inoculated agars were incubated for 6 days before a determination of no mycobacterial growth was reported. Preliminary identification of isolates as *Mycobacterium* spp. was determined through a positive Ziehl-Neelsen acid-fast stain and catalase reaction. A subset of acid-fast bacilli positive isolates from 2014 to 2018 were further identified using matrix-assisted laser-desorption ionization time-of-flight mass spectrometry (MALDI-TOF MS; Biotyper, Bruker-Daltonics, Billerica, Massachusetts).^{31,32} Identification, if not achieved, and all susceptibility testing was then performed at NJHML.

At NJHML, methods for culture and susceptibility testing were carried out in accordance with Clinical and Laboratory Standards Institute guidelines.³³ Human breakpoints were used for interpretation of susceptibility.

Specimens submitted to the NJHML in Denver, Colorado, were shipped overnight on ice. Decontamination (N-acetyl-L-cysteine with 2% sodium hydroxide³⁴) was performed before inoculation onto 4 media: broth (Middlebrook 7H9), Lowenstein-Jensen (LJ) slant, and biplate (Middlebrook 7H11) (Sensititer plates; Thermo Scientific, Waltham, Massachusetts). All cultures were incubated at room temperature, 32°C, 37°C, and 42°C; the LJ slant and biplate cultures were incubated in the presence of 5% CO₂. Media were assessed for growth at 1, 3, and 6 weeks after inoculation. Negative cultures were reported after 6 weeks of incubation with no growth; LJ slants were incubated for an additional 2 weeks. Identification of MAC isolates was performed using *rpob* gene polymerase chain reaction (PCR) sequencing.³⁵ For RGM isolates, identification methods included *rpob* or 16S rRNA gene PCR sequencing.^{36,37}

Susceptibility testing was performed exclusively at the NJHML. Before April 2015, a broth microdilution assay was used by NJHML to determine minimum inhibitory concentrations (MICs) and susceptibility for MAC isolates; after April 2015, a broth microdilution method was employed. For RGM isolates, a microdilution MIC method was performed after 2008, before which time agar diffusion-based susceptibility testing methods were utilized. All isolates were tested against a second (ciprofloxacin) and third (moxifloxacin) generation fluoroquinolone, aminoglycosides (kanamycin and amikacin), an oxazolidinone (linezolid), a macrolide (clarithromycin), and a phenazine (clofazimine). Antimicrobials specific to MAC isolates included an additional aminoglycoside (streptomycin), rifamycins (rifampin/rifampicin [same drug] and rifabutin), a thioamide (ethionamide), an ethylenediamine (ethambutol), and a second oxazolidinone (cycloserine). The RGM isolates were also assessed for susceptibility to penicillins (amoxicillin-clavulanate); carbapenems (imipenem); second (cefoxitin), third (ceftriaxone, cefotaxime), and fourth (cefepime) generation cephalosporins; a third generation fluoroquinolone (gatifloxacin); additional aminoglycosides (gentamicin and tobramycin); tetracyclines (doxycycline and minocycline); a glycyline (tigecycline); a second macrolide (azithromycin); and trimethoprim sulfamethoxazole (TMS). Combination testing was also performed to assess for antimicrobial

synergy; combination testing included rifampin with ethambutol and clofazimine with amikacin for MAC and RGM isolates, respectively.

2.3 | Statistical analysis

Data are outlined as descriptive statistics with values reported as median with range where appropriate. Categorical data pertaining to MAC and RGM cases were evaluated for a difference in proportion using 2-sided Fisher's exact test. Two-tailed Mann-Whitney *U* test was employed to evaluate for differences in nonparametric continuous data. Statistical analysis was performed using commercially available software (Prism; GraphPad, San Diego, California). For all comparisons, a value of $P \leq .05$ was considered significant.

3 | RESULTS

3.1 | Cats

A total of 33 cats were identified from the hospital information system using the search criteria specified. Of these, 14 cats were excluded because they either had (a) a negative culture and a definitive alternative diagnosis ($n = 7$); (b) a negative culture despite a positive mycobacterial PCR test result ($n = 1$); or (c) a positive mycobacterial culture without species identification and concurrent susceptibility ($n = 6$). Ultimately, 19 cases were included for review.

3.2 | Clinical history, presentation, disease manifestation, and diagnosis

All 19 cats had NTM infections, including 4 cats with MAC infection and 15 cats with RGM infection. Given the described clinical distinctions between MAC and RGM cases, data pertaining to these groups are described separately. Respective data are compared in Table 1.

3.2.1 | Cats with MAC infections

Isolates from all 4 cats were identified as *M avium*.

Disseminated disease was identified in 3 cats manifesting as (a) bacteremia; (b) liver, kidney, and intra-abdominal lymph node infection; and (c) intra-abdominal lymph node disease. These cats were examined because of acute onset anorexia and lethargy; progressive cough; and chronic vomiting and diarrhea, respectively. Neutrophilic inflammation was present on broncho-alveolar lavage cytology in the cat with a cough after detection of a diffuse nodular pattern on radiographs; no additional testing was performed to confirm mycobacterial pulmonary involvement. Localized disease, manifested as left tarsal osteomyelitis that was associated with lameness, was identified in a fourth case. Systemic signs of weight loss, inappetence, and lethargy

TABLE 1 Summary data including clinical presentation for *Mycobacterium avium* and rapid-growing nontuberculous mycobacterial (RGM) infections identified in cats presented to the University of California, Davis William R. Pritchard Veterinary Medical Teaching Hospital between 1998 and 2018. Fisher's exact testing and Mann-Whitney *U* test for difference in proportions between categorical and nonparametric continuous variables, respectively; statistical significance included ($P \leq .05$).

	<i>Mycobacterium avium</i> (n = 4)	RGM (n = 15)	P value
Date of initial UCD exam	2013-2018	1998-2017	—
Distance from UCD	117 km radius	212 km radius	—
Age (median, range) (years)	5 (2-10)	8 (1-15)	—
Sex	MC (4)	MC (7), FS (8)	—
Breed	DSH (3), Somali (1)	DSH (10), DMH (2), DLH (1), Siamese (2)	—
Outdoor access	0	14	.001
Possible immunocompromise (including drug treatment)	3	0 ^a	.018
Travel history	0	1	>.999
History of trauma/surgery	0	6	.255
Duration of clinical signs (median, range) (months)	2.75 (0.5-12)	12 (0.5-84)	.119
Cutaneous involvement	0	15	<.001
Disseminated disease	3	0	.004
Systemically unwell at time of diagnosis	3	3	.071

Abbreviations: DLH, domestic long hair; DMH, domestic long hair; DSH, domestic short hair; FS, female spayed; MC, male castrated; UCD, the University of California, Davis.

^aEight of 15 cats were tested with ELISA for FIV antibody and FeLV antigen.

were only noted in the cats with disseminated infection; 2 of these 3 cats were febrile ($>39.2^{\circ}\text{C}$) at initial examination.

Three cats were deemed to have a possible source of concurrent immunosuppression. Two cats had positive FIV antibody test results (SNAP FIV antibody/FeLV antigen test; IDEXX Laboratories Inc, Westbrook, Maine); follow-up testing was strongly supportive of FIV infection. The cat with bacteremia had a concurrent positive whole blood PCR test for FIV proviral DNA (FIV proviral DNA PCR; Real-time PCR Research and Diagnostics Core Facility, Davis, California). The cat with left tarsal osteomyelitis had a negative whole blood PCR test for FIV proviral DNA but a low CD4:CD8 ratio as determined using flow cytometry (CD4+ count $0.287 \times 10^3/\mu\text{L}$, CD8+ count $0.285 \times 10^3/\mu\text{L}$; ratio 1.008; normal cat ratio reference range 1.2-2.6).³⁸ No follow-up retroviral testing was performed in the 2 other cats that had negative FIV antibody test results. Before evaluation at the authors' institution, the cat with intra-abdominal lymph node involvement had been treated with a tapering course of methylprednisolone (0.8 mg/kg PO q24h for 5 days, then 0.4 mg/kg PO q24h for 10 days, then 0.4 mg/kg PO q48h for 6 weeks) (Medrol; Pfizer, New York, New York) and then cyclosporine for 6 months (6.25 mg/kg PO q24h) (Atopica liquid; Elanco, Greenfield, Indiana) for allergic dermatitis. All 4 cats were FeLV antigen-negative (SNAP, FIV antibody/FeLV antigen test).

Acid-fast bacilli were detected from blood cultures performed at our institute in the cat with bacteremia. In the 3 remaining cases, a presumptive diagnosis of mycobacterial infection was obtained via cytologic examination of fine-needle aspirate samples of affected tissues by our clinical pathology service. The isolate from the blood

culture of the bacteremic cat was provided to the NJHML for identification and susceptibility testing. Aspirates from affected tissues of the 3 other *M avium* infected cats were submitted to the NJHML for culture, identification, and susceptibility testing. Median time to positive culture was 7 days (range, 5-12 days). The identity of isolates as *M avium* was confirmed in all cases through *rpoB* gene PCR sequencing.

3.2.2 | Cats with RGM infections

There were 15 cats with RGM infections. Most infections were associated with *M smegmatis* (n = 9) and *M fortuitum* (n = 4). The remaining 2 cats were infected with *M abscessus* and *M thermoresistibile*, respectively. A full description of the latter case has been published elsewhere.³⁹

All cats (n = 15) were evaluated for dermatologic disease with multifocal lesion distribution being most common (n = 10). All cats with multifocal lesions had involvement of the ventral abdomen or inguinal region. In a cat with history of pellet shot trauma, cutaneous draining tracts communicated with the retroperitoneum and infection had extended to the right kidney. Four cats were febrile ($>39.2^{\circ}\text{C}$); 3 cats with normal body temperatures were reported to have inappetence and lethargy.

Of the 4 cats with history of cat fight wounds (*M smegmatis* n = 2, *M fortuitum* n = 2), development of lesions at the site of previous cat bite injury was only specifically described for 1. In a fifth cat with *M smegmatis* infection (the cat with the history of pellet shot trauma),

lesions were suspected to result from this trauma given their location at the site of penetration, although the timing of this incident in relation to the onset of signs was not known. The 1 exclusively indoor cat developed a *M abscessus* infection at the site of a spay incision performed in Africa before relocation to northern California. No apparent immunocompromise, either concurrent disease or drug treatment, was identified. Routine FIV and FeLV testing (SNAP, FIV antibody/FeLV antigen combination test; IDEXX Laboratories Inc) was negative in 8 of 15 cats in which it was pursued; no further retroviral testing was carried out in these 8 cats.

Specimens submitted for culture were swabs (n = 2), aspirates (n = 4), or biopsies (n = 9) of cutaneous lesions. Acid fast bacilli were observed in 7 of 10 cats from which cytologic preparations were made at our facility. Mycobacterial cultures performed at our institutional microbiology laboratory yielded growth within 6 days in 14 of 15 cats. In the remaining cat, culture at the author's laboratory was negative, but *M thermoresistibile* was isolated at the NJHML after 5 weeks of incubation. *Mycobacterium thermoresistibile* is classified as a RGM; delay in isolation is discussed in the publication dedicated to this case.³⁹ *Mycobacterium abscessus* was identified as 1 isolate at our laboratory using MALDI-TOF MS. All other isolates were identified at NJHML; *M smegmatis* was identified by 16S rRNA gene PCR sequencing (n = 7) and *rpoB* gene PCR sequencing (n = 2); *M fortuitum* was identified by 16S rRNA PCR-gene sequencing (n = 4); and *M thermoresistibile* was identified using *rpoB* gene PCR sequencing.

3.3 | Antimicrobial susceptibility

Antimicrobial susceptibility results for *M avium* cases are shown in Figure 1. Figure 2 displays results for *M smegmatis* and *M fortuitum* isolates. *Mycobacterium abscessus* and *M thermoresistibile* were tested for susceptibility to all antimicrobials (as in Figure 2), with the exception of gatifloxacin. The single *M abscessus* isolate was interpreted as resistant to ceftriaxone, cefepime, augmentin, ciprofloxacin, moxifloxacin, doxycycline, minocycline, TMS, and linezolid; intermediate susceptibility was suggested to tobramycin, amikacin, ceftiofur, and cefotaxime. The single *M thermoresistibile* isolate was interpreted as susceptible to all antimicrobials tested.

Given the time period encompassed by this study, not all isolates were tested for susceptibility to the same antimicrobials and the antimicrobials selected also varied depending on whether the isolate was a *M avium* or RGM species. Two of 4 *M avium* infected cats had not received antimicrobial treatment before susceptibility testing was performed. Conversely, all RGM infected cats had received treatment with a minimum of 1 antimicrobial for a duration of at least 2 weeks.

3.4 | Treatment and outcome

3.4.1 | Antimicrobial treatment

After referral, treatment was attempted in all cases. Initially prescribed antimicrobials, that is, while culture and susceptibility results were

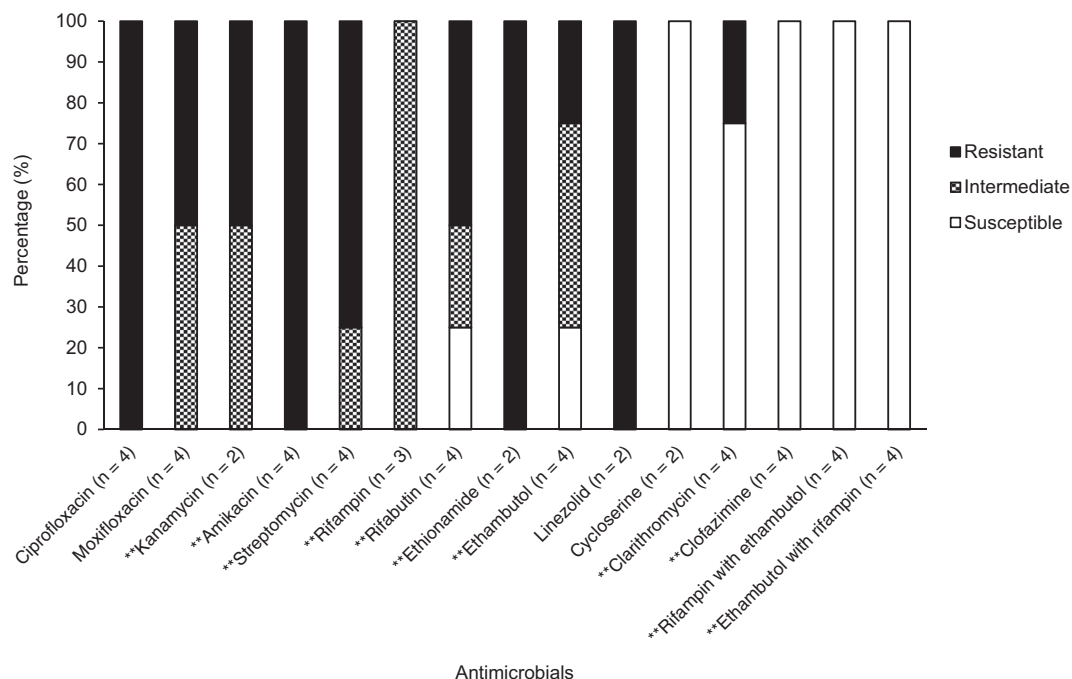


FIGURE 1 Susceptibility patterns for *Mycobacterium avium* isolates identified in cats from northern California expressed as a percentage (susceptible, intermediate, and resistant, as defined by human breakpoints). Number of isolates tested against each antimicrobial is listed on the horizontal axis. ** Usually recommended antimicrobials: antimicrobials with proven *in vivo* efficacy against human *M avium* infections. Other additionally tested antimicrobials have been shown to have *in vitro* efficacy but lack definitively proven *in vivo* efficacy against human *M avium* infections

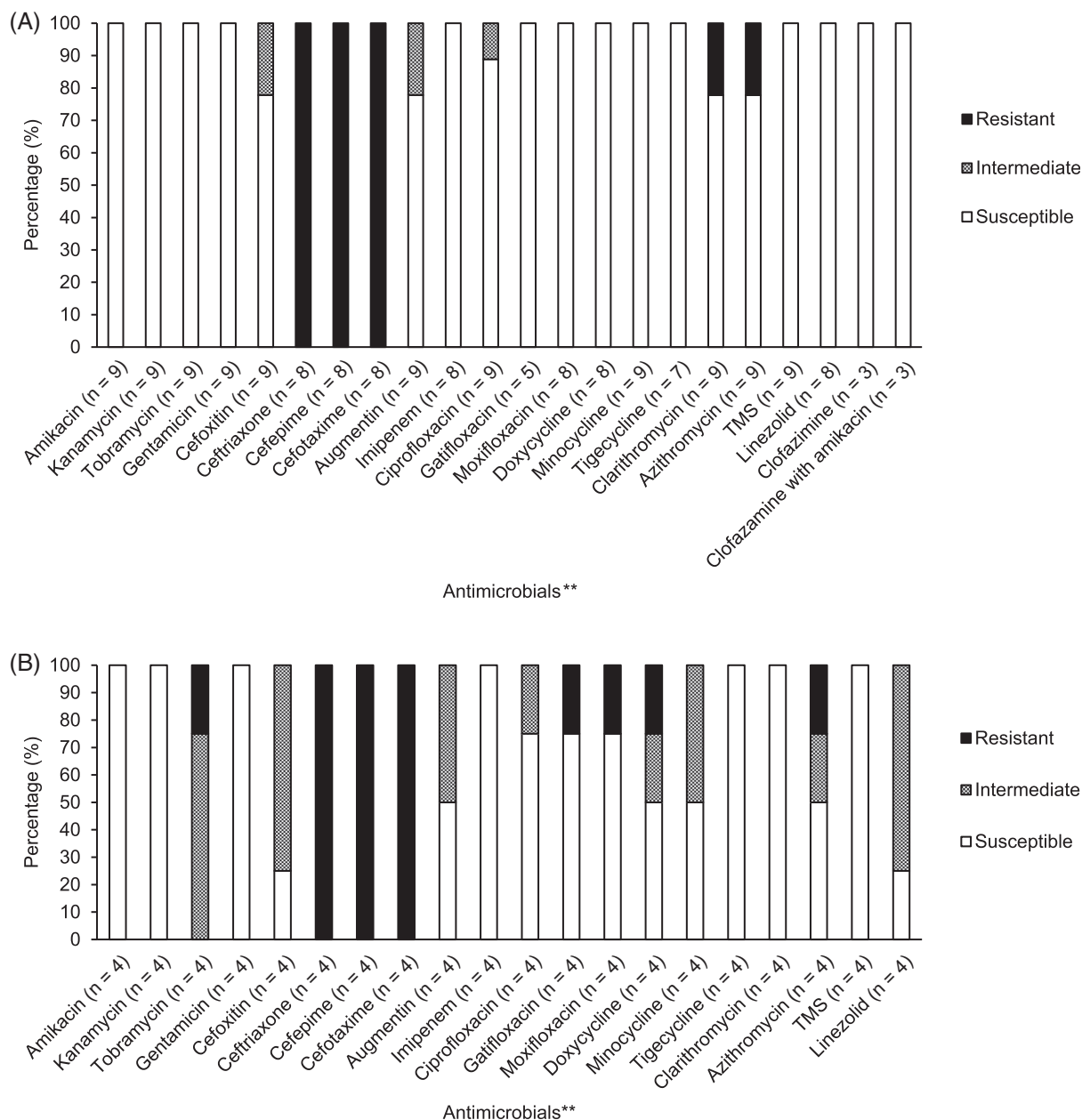


FIGURE 2 Susceptibility patterns for rapid-growing nontuberculous mycobacterial (RGM) isolates identified in cats from northern California expressed as a percentage (susceptible, intermediate, and resistant, as defined by human breakpoints). Number of isolates tested against each antimicrobial is listed on the horizontal axis. TMS, trimethoprim sulfamethoxazole. A, Susceptibility patterns for *Mycobacterium smegmatis* isolates. B, Susceptibility patterns for *Mycobacterium fortuitum* isolates. ** The exact correlation between *in vivo* and *in vitro* efficacy has not been well delineated in human or feline RGM infections

pending, are described in Table 2. Rifampin was not included in the initial treatment protocol in any cat. Ultimately, treatment was guided by susceptibility testing in all cases.

Minimal clinical response was seen in 1 cat with *M avium* infection after treatment with empiric doxycycline, marbofloxacin, and clarithromycin: susceptibility testing suggested resistance to all fluoroquinolones and clarithromycin. Treatment was changed to pradofloxacin with rifampin with stable disease. A second *M avium* infected cat, with left tarsal osteomyelitis, exhibited resolution of lameness with improvement in radiographic lesions: susceptibility

testing suggested susceptibility to the treatment protocol used (azithromycin and pradofloxacin). The remaining 2 *M avium* infected cats were euthanized before culture and susceptibility results became available. Both cats were being treated with combination antimicrobial treatment; for 1 of these cats, susceptibility testing suggested resistance to 1 of the antimicrobials used.

Thirteen of 15 cats with RGM infections were receiving appropriate antimicrobial treatment based on interpretation of initial susceptibility test results. A favorable clinical response was documented in each of these cases and treatment was continued. Susceptibility

TABLE 2 Empiric antimicrobial treatment while awaiting culture and susceptibility testing for infections associated with *Mycobacterium avium* and rapid-growing nontuberculous mycobacteria (RGM) in cats from northern California

Antimicrobial treatment	<i>Mycobacterium avium</i> (n = 4)	RGM (n = 15)			
		MS (n = 9)	MF (n = 4)	MA (n = 1)	MT (n = 1)
Monotherapy					
Tetracycline	—	4	1	—	—
Macrolide	—	1	—	—	—
Fluoroquinolone	—	—	—	1 ^a	1 ^a
Dual treatment					
Tetracycline + fluoroquinolone	1 ^b	1 ^c	1 ^c	—	—
Macrolide + fluoroquinolone	1 ^a	3 ^{a,c,d}	—	—	—
Triple treatment					
Tetracycline + macrolide + fluoroquinolone	2 ^{b,c}	—	1 ^a	—	—
Tetracycline + macrolide + TMS	—	—	1	—	—

Abbreviations: MA, *Mycobacterium abscessus*; MF, *Mycobacterium fortuitum*; MS, *Mycobacterium smegmatis*; MT, *Mycobacterium thermoresistibile*; TMS, trimethoprim-sulfamethoxazole.

^aPradofloxacin.

^bEnrofloxacin.

^cMarbofloxacin.

^dCiprofloxacin.

testing suggested resistance to current monotherapy in 2 cats (*M fortuitum* and *M abscessus*, respectively) in association with a lack of clinical improvement. Treatment was altered based on susceptibility results in these 2 cats with subsequent improvement in clinical signs.

3.4.2 | Description of surgery in the treatment of RGM cases

Surgical debridement/resection was used in addition to antimicrobial treatment in 11 cats with RGM infection (median, 1 surgery per cat; range, 1-6 surgeries per cat).

General practitioners performed surgery on 9 cats for a total of 14 surgeries; 1 cat underwent 5 surgeries over 24 months. In 8/9 cases, surgery was pursued before referral because of persistent lesions of the skin and subcutis that were minimally responsive to empiric antimicrobials; at the time of each of these surgeries, a definitive diagnosis was not known. Marginal excision or debridement of affected tissue was performed in all cases. Disease remained persistent or was recurrent in all cats. Dehiscence was a complication in 8/14 surgeries. Follow-up was not available for the 1 cat that returned to its general practitioner for surgery that had been delayed pending reduction of known mycobacterial disease burden with antimicrobial treatment.

Following referral, 6 cats had surgery performed by or under the guidance of a board-certified veterinary surgeon; 4 of these cats had previously had surgery by a general practitioner. Five cats had 1 surgery and 1 cat had 3 procedures performed. In all cases, surgery was not delayed for initial antimicrobial treatment, and wide surgical excision was performed. In the case with infection tracking into the retroperitoneum suspected to be secondary to pellet shot trauma,

ipsilateral nephrectomy was performed. In the cat infected with *M thermoresistibile*, intervention included open-wound management in addition to later debridement, vacuum-assisted wound closure, and reconstructive procedures over 3 surgeries while the cat was hospitalized and receiving antibiotics administered IV.³⁹ Wound dehiscence was described after 2 surgical procedures. Remission was achieved in 3 cats. No surgical follow-up was available for 1 cat.

3.4.3 | Treatment outcome

Three out of 4 *M avium* infected cats were euthanized because of their disease. The cat with generalized lymph node involvement and the cat with bacteremia were euthanized within 1 month of diagnosis while receiving treatment. Although the cat with liver, kidney, and intra-abdominal lymph node involvement remained clinically stable for 24 months with ongoing antimicrobial treatment, lethargy and persistent fever were then described before the cat eventually deteriorated and was euthanized. After initial resolution of lameness, and despite ongoing treatment, the cat with osteomyelitis presented for hyporexia and weight loss and was found to have developed hepatic involvement 32 months after initial diagnosis. This was associated with the detection of additional antimicrobial resistance in the *M avium* isolate. After a change to treatment based on this updated susceptibility data, the cat's clinical condition stabilized with no clinical signs at the time of loss to follow-up (4 years from diagnosis).

Follow-up was available for 12 of 15 RGM infected cats. Median duration of treatment follow-up was 7 months (range, 3-66 months). Treatment outcome is stratified by disease and treatment variables in Table 3. Repeat culture and susceptibility testing were performed for isolates from 1 *M smegmatis* infected cat and 1 *M fortuitum* infected

TABLE 3 Treatment outcomes for infections associated with rapid-growing nontuberculous mycobacteria (RGM) in cats from northern California. Outcomes presented in relation to mycobacterial species, disease severity, and treatment method. Follow-up was available for 12 of 15 cats

Clinical feature	RGM treatment outcome	
	Partial remission (n = 8)	Complete resolution (n = 4)
Species		
<i>Mycobacterium smegmatis</i> (n = 8)	5	3
<i>Mycobacterium fortuitum</i> (n = 2)	2	—
<i>Mycobacterium abscessus</i> (n = 1)	1	—
<i>Mycobacterium thermoresistibile</i> (n = 1)	—	1
Disease severity		
Mild/localized (n = 4)	3	1
Severe/multifocal (n = 8)	5	3
Treatment ^a		
Antimicrobial treatment alone (n = 7)		
Monotherapy	2	
Dual treatment	2	1
Triple treatment	2	
Antimicrobial treatment + excision with wide margins (n = 5)		
Monotherapy	1	1
Dual treatment	1	2
Triple treatment		

Notes: Partial remission: >50% response to treatment within 3 months but with some level of disease for duration of follow-up. Mild/localized disease: single discrete lesions. Severe disease: regionally extensive or multifocal lesions. Excision with wide margins: can also include use of reconstructive techniques, or assisted wound closure, or both.

^aRefers to treatment after referral to the University of California, Davis William R. Pritchard Veterinary Medical Teaching Hospital. Antimicrobial treatment as based on review of culture and susceptibility testing and clinical response.

cat during treatment. In both cats, these were performed due to persistent or worsening clinical signs in the face of ongoing treatment. Both isolates showed resistance to 1 or more antimicrobials that had been used for initial treatment. No cats died or were euthanized as a result of their disease during the duration of follow-up available.

4 | DISCUSSION

This study describes NTM infections in cats from northern California. All MAC cases were *M avium*; 60% of the RGM species were *M*

smegmatis and 27% were *M fortuitum*. *Mycobacterium avium* infections were associated with possible immunocompromise and disseminated disease without dermatologic involvement. Cats with RGM disease were otherwise healthy, almost exclusively outdoor, and were examined for disease of the skin and subcutis alone. Variable antimicrobial susceptibility profiles were identified among mycobacterial species. Response to treatment was inconsistent. The emergence of resistant isolates was documented in all cats with either *M avium* or RGM infections in which repeat culture was undertaken because of persistent or progressive disease.

The relationship between immunocompromise and predisposition to infection with *M avium* is not clearly defined. A source of possible immunocompromise was identified in 3 cats with *M avium* infection. The proportion of FIV infected cats was not statistically different between *M avium* and RGM groups; however, not all RGM cases underwent retroviral testing. Notwithstanding, FIV infection does not necessarily imply an immunosuppressed state. Development of *M avium* infection after immunocompromise has been described in cats²⁴⁻²⁶; however, just as in human medicine,⁴⁰ many cases in the literature have no obvious underlying immunodeficiency.^{10,12,13,16,41-43} Immunocompromise may not be required for *M avium* infection but should be considered in these cases.

Four different RGM species were isolated in this study. *Mycobacterium smegmatis* was not described in previous reports from northern California^{17,18} nor in cases from Florida.¹¹ The exact cause for the shift in species representation in our region is unclear. *Mycobacterium smegmatis* is an ubiquitously found environmental mycobacterial species and was previously considered a nonpathogenic contaminant in people.⁴⁴ However, infection with this organism has been associated with a variety of manifestations including skin and soft tissue infections, and catheter-associated infection.⁴⁴⁻⁴⁶ Moreover, *M smegmatis* was the most prevalent species identified in cats with mycobacterial disease from the east-coast of Australia.^{9,19,47} As such, it is possible that the isolation of *M smegmatis* as a true pathogen is rather a reflection of the method of infection (ie, inoculation after trauma). Although the clinical expression of disease was consistent with cutaneous mycobacteriosis making contamination unlikely, all RGM were yielded at our institutional laboratory where initial decontamination with N-acetyl-L-cysteine was not performed.

In agreement with previous RGM case reports, we identified no clear signalment predisposition, negative retroviral test results (specifically FIV antibody and FeLV antigen; when performed or reported), and disease exclusively affecting the skin and subcutis in generally systemically healthy cats.^{9,11,17-20,47} Similarly, previous publications have identified inguinal involvement alone or as part of multifocal disease as the most common distribution of lesions.^{11,17,19,20,47} This is thought to reflect the tropism of RGM for adipose tissue.⁹ Trauma is also thought to play a role in disease development with lesions described at the site of trauma in 33% to 100% of described cases in cats.^{11,17,19,20,47} This was not consistently apparent among this cohort.

Interestingly, median interval from inoculation to colony formation for *M avium* isolates was 5 days, with all samples first positive in

broth culture. By definition, *M avium* is typically considered a SGM variant as interval to colony formation by culture on solid media is greater than 7 days.⁴⁸ In both people and production animals, broth culture methods have been shown to significantly increase diagnostic sensitivity and decrease the time to detection of MAC isolates.^{49,50} The absence of previous antimicrobial treatment in 2 cats may also have facilitated more rapid isolation; the size of the inoculum could also play a role.⁵¹

Antimicrobial susceptibility patterns varied across mycobacterial species. Interpretation of these results is challenging because of a lack of published veterinary breakpoints for mycobacterial species. To the authors' knowledge, no previous veterinary studies have reported susceptibility data for *M avium* isolates from cats. Based on standardized guidelines for human disease, *M avium* susceptibility testing is limited to clarithromycin alone as clinical response in people is known only to correlate with macrolide susceptibility.^{52,53} Wild-type human *M avium* isolates are generally considered uniformly susceptible to clarithromycin⁵⁴; as described here, 3 of 4 *M avium* isolates were susceptible to clarithromycin.

Rapid-growing mycobacterial susceptibility profiles were more favorable. Broad susceptibility of *M smegmatis* and *M fortuitum* to fluoroquinolones has been exhibited in studies using archived isolates from cats^{29,30} as well as in clinical case reports.^{9,11} Susceptibility to tetracyclines in only 50% of *M fortuitum* isolates has been similarly described in both cats^{9,28} and people.⁵⁵ In previous reports, the prevalence of clarithromycin resistance in isolates from cats has varied, ranging from 17% to 100% of *M fortuitum* cases^{11,18,28} and 83% of *M smegmatis* infections.²⁸ It is also important to note that RGM isolates carry inducible resistance genes such as the erythromycin methylase gene.^{56,57} All of our *M fortuitum* isolates were susceptible to TMS, whereas 100% were resistant in earlier studies^{9,28}; our results are more consistent with observations for human clinical isolates.⁵⁸ In people, *M abscessus* is typically considered susceptible to clarithromycin, amikacin, and cefoxitin, but is generally resistant to all fluoroquinolones and TMS.^{52,59} Resistance to higher generation cephalosporins was common and aligns with previous reporting in veterinary medicine^{11,28}; these should be avoided in treatment of RGM infections.

Despite treatment being guided by susceptibility testing in all cases, treatment success was not observed uniformly. Treatment of *M avium* infections in humans is complicated by a lack of correlation between *in vitro* and *in vivo* efficacy. In human *M avium* infections, clarithromycin is the only antibiotic for which susceptibility is correlated with clinical response. Guidelines recommend treatment in people with clarithromycin in combination with rifampin and ethambutol, not only as this protocol is most efficacious, but as it reduces the risk of macrolide resistance, an important negative prognostic factor.^{52,60-63} The clinical efficacy of fluoroquinolones remains to be proven in people.^{27,64} Furthermore, the combination of clarithromycin and moxifloxacin as dual treatment may increase risk of clarithromycin resistance.⁶⁴ Correlation between susceptibility test results and outcome for RGM infection in people has also not been rigorously investigated. The development of resistance during treatment, as

documented in 3 cats described in our study, is another consideration for suboptimal treatment outcomes in *M avium* and RGM infected cats.

It is difficult to provide definitive antimicrobial treatment recommendations based on the results of this study. Despite poor outcomes in many *M avium* cases in cats,^{12,14,41,42} favorable results were documented in 7/12 young, immunocompetent cats with disseminated disease in 1 publication.¹⁰ Common to these cases was prolonged combination antimicrobial treatment with clarithromycin in addition to either clofazimine or rifampin and either a fluoroquinolone or doxycycline. Although unable to be statistically assessed in relation to outcome, the antimicrobial protocols described here should be strongly reconsidered and in future placed in line with human recommendations and data from the successfully managed cases in cats, both as stated above¹⁰: combination treatment, specifically a macrolide, a rifamycin compound, and a third drug (clofazimine, pradofloxacin, etc.) is advised for *M avium* isolates. Multiagent antimicrobial treatment also warrants consideration in RGM disease. Repeat culture should be considered in the face of refractory (or recurrent) disease.

Considerations must also be given to the practicalities of antimicrobial administration in cats. Clofazimine was the only antimicrobial for which all *M avium* and RGM isolates were susceptible. Although its routine use should perhaps be more strongly considered, availability and cost can be limiting factors. Thought may need to be given to having clofazimine compounded. Adverse effects of clofazimine administration include inappetence, skin discoloration, and photosensitization.⁶⁵ Although fluoroquinolone efficacy in human *M avium* disease remains to be elucidated, moxifloxacin, a third-generation fluoroquinolone, holds some promise. It is clear that high doses must be given in order to achieve bactericidal effects.⁶⁶ This has important implications in cats given the potential for dose-dependent retinal toxicity associated with fluoroquinolones other than pradofloxacin⁶⁷; pradofloxacin should be considered the fluoroquinolone of choice for mycobacterial disease in cats. Rifamycin compounds are not always well tolerated in cats. Compounding of medications may also need to be considered so that appropriate doses can be administered.

Studies from Australia report uniform success at achieving cure in cats with RGM infections, most commonly utilizing a combination of radical surgical excision and prolonged (3-6 months) single agent antimicrobial treatment including preoperative treatment.^{9,19} Other studies describe variable therapeutic efficacy for cases undergoing surgery but these publications lack detail regarding the surgical approaches taken.^{11,17,20,47} There is a possible indication from these cases that treatment outcomes when surgery is undertaken can be improved by considering wider excision and being prepared to employ reconstructive techniques; such surgeries are likely to require a board-certified surgeon. Knowledge of the diagnosis in advance of surgery improves surgical planning. Although not described in this cohort, consideration could also be given to initial antimicrobial treatment to attenuate lesion extent before surgery.

Limitations of this study relate to its retrospective nature. In particular, low case numbers and a lack of follow-up information prevented more meaningful statistical analysis of clinical differences

between *M avium* and RGM infections, initial and follow-up susceptibility data, and factors impacting disease outcome. Details of previous antimicrobial administration were lacking and may have influenced antimicrobial susceptibility patterns. As regional differences in antimicrobial susceptibility may exist, the results of our study may not apply to other locales, as has been shown in people.⁶⁸

ACKNOWLEDGMENT

No funding was received for this study.

CONFLICT OF INTEREST DECLARATION

Authors declare no conflict of interest.

OFF-LABEL ANTIMICROBIAL DECLARATION

Doxycycline, marbofloxacin, pradofloxacin, azithromycin, clarithromycin, TMS, rifampin and amikacin used off-label.

INSTITUTIONAL ANIMAL CARE AND USE COMMITTEE (IACUC) OR OTHER APPROVAL DECLARATION

Authors declare no IACUC or other approval was needed.

HUMAN ETHICS APPROVAL DECLARATION

Authors declare human ethics approval was not needed for this study.

ORCID

Matthew J. L. Munro  <https://orcid.org/0000-0003-3899-5915>

REFERENCES

- LoBue PA, Enarson DA, Thoen CO. Tuberculosis in humans and animals: an overview. *Int J Tuberc Lung Dis.* 2010;14:1075-1078.
- Gunn-Moore DA. Feline mycobacterial infections. *Vet J.* 2014;201:230-238.
- Gunn-Moore DA, McFarland SE, Brewer JI, et al. Mycobacterial disease in cats in Great Britain: I. Culture results, geographical distribution, and clinical presentation of 339 cases. *J Feline Med Surg.* 2011;13:934-944.
- Gunn-Moore DA, Jenkins PA, Lucke VM. Feline tuberculosis: a literature review and discussion of 19 causes by an unusual mycobacterial variant. *Vet Rec.* 1996;138:53-58.
- Delahay RJ, Smith GC, Barlow AM, et al. Bovine tuberculosis infection in wild animals in the south-west region of England: a survey of prevalence and semi-quantitative assessment of the relative risks to cattle. *Vet J.* 2007;173:287-301.
- Malik R, Smits B, Reppas G, Laprie C, O'Brien C, Fyfe J. Ulcerated and nonulcerated nontuberculous cutaneous mycobacterial granulomas in cats and dogs. *Vet Dermatol.* 2013;24:146-153.
- O'Brien CR, Malik R, Globan M, Reppas G, McCowan C, Fyfe JA. Feline leprosy due to *Mycobacterium lepraemurium*. *J Feline Med Surg.* 2017;19:737-746.
- Malik R, Hughes MS, James G, et al. Feline leprosy: two different clinical syndromes. *J Feline Med Surg.* 2002;4:43-59.
- Malik R, Wigney DI, Dawson D, Martin P, Hunt GB, Love DN. Infection of the subcutis and skin of cats with rapidly growing mycobacteria: a review of microbiological and clinical findings. *J Feline Med Surg.* 2000;2:35-48.
- Baral RM, Metcalfe SS, Krockenberger MB, et al. Disseminated *Mycobacterium avium* infection in young cats: an overrepresentation of Abyssinian cats. *J Feline Med Surg.* 2006;8:23-44.
- Horne KS, Kunkle GA. Clinical outcome of cutaneous rapidly growing mycobacterial infections in cats in the south-eastern United States: a review of 10 cases (1996-2006). *J Feline Med Surg.* 2009;11:627-632.
- Jordan HL, Cohn LA, Armstrong PJ. Disseminated *Mycobacterium avium* complex infection in three Siamese cats. *J Am Vet Med Assoc.* 1994;204:90-93.
- Kaufman AC, Greene CE, Rakich PM, et al. Treatment of localized *Mycobacterium avium* complex infection with clofazimine and doxycycline in a cat. *J Am Vet Med Assoc.* 1995;207:457-459.
- Latimer KS, Crowell WA, Duncan JR, Currin KP, Jameson PH. Disseminated *Mycobacterium avium* complex infection in a cat: presumptive diagnosis by blood smear examination. *Vet Clin Pathol.* 1997;26:85-89.
- Miller MA, Fales WH, McCracken WS, et al. Inflammatory pseudotumor in a cat with cutaneous mycobacteriosis. *Vet Pathol.* 1999;36:161-163.
- Morfitt DC, Matthews JA, Thoen CO, Kluge JP. Disseminated *Mycobacterium avium* serotype 1 infection in a seven-month-old cat. *J Vet Diagn Invest.* 1989;1:354-356.
- White SD, Ihrke PJ, Stannard AA, et al. Cutaneous atypical mycobacteriosis in cats. *J Am Vet Med Assoc.* 1983;182:1218-1222.
- Jang SS, Hirsch DC. Rapidly growing members of the genus *Mycobacterium* affecting dogs and cats. *J Am Anim Hosp Assoc.* 2002;38:217-220.
- Malik R, Hunt GB, Goldsmid SE, Martin P, Wigney DI, Love DN. Diagnosis and treatment of pyogranulomatous panniculitis due to *Mycobacterium smegmatis* in cats. *J Small Anim Pract.* 1994;35:524-530.
- Kunkle GA, Gulbas NK, Fakok V, et al. Rapidly growing mycobacteria as a cause of cutaneous granuloma: report of five cases. *J Am Anim Hosp Assoc.* 1983;19:513-521.
- Couto SS, Artacho CA. *Mycobacterium fortuitum* pneumonia in a cat and the role of lipid in the pathogenesis of atypical mycobacterial infections. *Vet Pathol.* 2007;44:543-546.
- Dietrich U, Arnold P, Guscetti F, Pfyffer GE, Spiess B. Ocular manifestation of disseminated *Mycobacterium simiae* infection in a cat. *J Small Anim Pract.* 2003;44:121-125.
- Foster SF, Martin P, Davis W, Allan GS, Mitchell DH, Malik R. Chronic pneumonia caused by *Mycobacterium thermoresistibile* in a cat. *J Small Anim Pract.* 1999;40:433-438.
- Griffin A, Newton AL, Aronson LR, Brown DC, Hess RS. Disseminated *Mycobacterium avium* complex infection following renal transplantation in a cat. *J Am Vet Med Assoc.* 2003;222:1097-1101.
- Kadar E, Sykes JE, Kass PH, Bernsteen L, Gregory CR, Kyles AE. Evaluation of the prevalence of infections in cats after renal transplantation: 169 cases (1987-2003). *J Am Vet Med Assoc.* 2005;227:948-953.
- Malik R, Gabor L, Martin P, et al. Subcutaneous granuloma caused by *Mycobacterium avium* complex infection in a cat. *Aust Vet J.* 1998;76:604-607.
- Brown-Elliott BA, Nash KA, Wallace RJ Jr. Antimicrobial susceptibility testing, drug resistance mechanisms, and therapy of infections with nontuberculous mycobacteria. *Clin Microbiol Rev.* 2012;25:545-582. Erratum in: *Clin Microbiol Rev.* 2012;25:721.
- Bennie CJM, To JLK, Martin PA, et al. *In vitro* interaction of some drug combinations to inhibit rapidly growing mycobacterial isolates from cats and dogs and these isolates' susceptibility to cefovecin and clofazimine. *Aus Vet J.* 2015;93:40-45.
- Govendir M, Hansen T, Kimble B, et al. Susceptibility of rapidly growing mycobacteria isolated from dogs and cats, to ciprofloxacin, enrofloxacin, and moxifloxacin. *Vet Microbiol.* 2011;147:113-118.
- Govendir M, Norris JM, Hansen T, et al. Susceptibility of rapidly growing mycobacteria and *Nocardia* isolates from cats and dogs to pradofloxacin. *Vet Microbiol.* 2011;153:240-245.
- Mediavilla-Gradolph MC, De Toro-Peinado I, Bermudez-Ruiz MP, et al. Use of MALDI-TOF MS for identification of nontuberculous

- mycobacterium species isolated from clinical specimens. *Biomed Res Int.* 2015;2015:854078.
32. Kodana M, Tarumoto N, Kawamura T, et al. Utility of the MALDI-TOD MS method to identify nontuberculous mycobacteria. *J Infect Chemother.* 2016;22:32-35.
 33. Clinical and Laboratory Standards Institute. *CLSI Guideline M48: Laboratory Detection and Identification of Mycobacteria.* 2nd ed. Wayne, PA: Clinical and Laboratory Standards Institute; 2018.
 34. Forbes BA, Hall GS, Miller MB, et al. Practical guidelines for clinical microbiology laboratories: mycobacteria. *Clin Microbiol Rev.* 2018;31:e00038-17.
 35. Salah IB, Adekambi T, Raoult D, et al. *rpoB* sequence-based identification of *Mycobacterium avium* complex species. *Microbiol.* 2008;154:3715-3723.
 36. Kirschner P, Böttger EC. Species identification of mycobacteria using rDNA sequencing. *Methods Mol Biol.* 1998;101:349-361.
 37. Holberg-Petersen M, Steinbakk M, Figschau KJ, et al. Identification of clinical isolates of *Mycobacterium* spp. by sequence analysis of the 16S ribosomal gene. Experience from a clinical laboratory. *APMIS.* 1999;107:231-239.
 38. Dean GA, Quackenbush SL, Ackley CD, Cooper MD, Hoover EA. Flow cytometric analysis of T-lymphocyte subsets in cats. *Vet Immunol Immunopathol.* 1991;28:327-335.
 39. Vishkautsan P, Reagan KL, Keel MK, et al. Mycobacterial panniculitis caused by *Mycobacterium thermoresistibile* in a cat. *J Feline Med Surg Open Rep.* 2016;2:2055116916672786.
 40. Wagner D, Young LS. Nontuberculous mycobacterial infections: a clinical review. *Infection.* 2004;32:257-270.
 41. Drolet R. Disseminated tuberculosis caused by *Mycobacterium avium* in a cat. *J Am Vet Med Assoc.* 1986;189:1336-1337.
 42. Riviere D, Pingret JL, Etievant M, et al. Disseminated *Mycobacterium avium* subspecies infection in a cat. *J Feline Med Surg.* 2011;13:125-158.
 43. Sieber-Ruckstuhl NS, Sessions JK, Sanchez S, Latimer KS, Greene CE. Long-term cure of *Mycobacterium avium* infection in a cat. *Vet Rec.* 2007;160:131-132.
 44. Wallace RJ Jr, Nash DR, Tsukamura M, et al. Human disease due to *Mycobacterium smegmatis*. *J Infect Dis.* 1988;158:52-59.
 45. Xu Z, Lu D, Zhang X, et al. *Mycobacterium smegmatis* in skin biopsy specimens from patients with suppurative granulomatous inflammation. *J Clin Microbiol.* 2013;51:1028-1030.
 46. Chang CY, Tsay RW, Lin LC, et al. Venous catheter-associated bacteremia caused by rapidly growing mycobacteria at a medical center in Central Taiwan. *J Microbiol Immunol Infect.* 2009;42:343-350.
 47. Studdert VP, Hughes KL. Treatment of opportunistic mycobacterial infections with enrofloxacin in cats. *J Am Vet Med Assoc.* 1992;201:1388-1390.
 48. Runyon EH. Typical mycobacteria: their classification. *Am Rev Respir Dis.* 1965;91:288-289.
 49. Flournoy D, Twilley J. Modified middlebrook 7H9 broth for rapid detection of mycobacteria. *Clin Lab Sci.* 2001;14:85-88.
 50. Motiwala AS, Strother M, Theus NE, et al. Rapid detection and typing of strains of *Mycobacterium avium* subsp. *paratuberculosis* from broth cultures. *J Clin Microbiol.* 2005;43:2111-2117.
 51. Reddacliff LA, Nicholls PJ, Vadali A, Whittington RJ. Use of growth indices from radiometric culture for quantification of sheep strains of *Mycobacterium avium* subsp. *paratuberculosis*. *Appl Environ Microbiol.* 2003;69:3510-3516.
 52. Griffith DE, Aksamit T, Brown-Elliott BA, et al. An official ATS/IDSA statement: diagnosis, treatment, and prevention of nontuberculous mycobacterial diseases. *Am J Respir Crit Care Med.* 2007;175:367-416.
 53. Kobashi Y, Yoshida K, Miyashita N, Niki Y, Oka M. Relationship between clinical efficacy of treatment of pulmonary *Mycobacterium avium* complex disease and drug-sensitivity testing of *Mycobacterium avium* complex isolates. *J Infect Chemother.* 2006;12:195-202.
 54. Maurer FP, Pohle P, Kernbach M, et al. Differential drug susceptibility patterns of *Mycobacterium chimaera* and other members of the *Mycobacterium avium-intracellulare* complex. *Clin Microbiol Infect.* 2019;25(3):379e1-379.e7.
 55. Hatakeyama S, Ohama Y, Okazaki M, et al. Antimicrobial susceptibility testing of rapidly growing mycobacteria isolated in Japan. *BMC Infect Dis.* 2017;17(1):197.
 56. Nash KA, Brown-Elliott BA, Wallace RJ Jr. A novel gene, *erm(41)*, confers inducible macrolide resistance to clinical isolates of *Mycobacterium abscessus* but is absent from *Mycobacterium chelonae*. *Antimicrob Agents Chemother.* 2009;53:1367-1376.
 57. Kim SY, Moon SM, Jhun BW, et al. Species distribution and macrolide susceptibility of *Mycobacterium fortuitum* complex clinical isolates. *Antimicrob Agents Chemother.* 2019;63(6):e02331-18.
 58. Wallace RJ Jr, Wiss K, Bushby MB, et al. *In vitro* activity of trimethoprim and sulfamethoxazole against the nontuberculous mycobacteria. *Rev Infect Dis.* 1982;4:326-331.
 59. Shen Y, Wang X, Jin J, et al. *In vitro* susceptibility of *Mycobacterium abscessus* and *Mycobacterium fortuitum* isolates to 30 antibiotics. *Biomed Res Int.* 2018;2018:4902941.
 60. Schwartz M, Fisher S, Story-Roller E, Lamichhane G, Parrish N. Activities of dual combinations of antibiotics against multidrug-resistant nontuberculous mycobacteria recovered from patients with cystic fibrosis. *Microb Drug Resist.* 2018;24:1191-1197.
 61. Wallace RJ, Brown BA, Griffith DE, et al. Initial clarithromycin monotherapy for *Mycobacterium avium-intracellulare* complex lung disease. *Am J Respir Crit Care Med.* 1994;149:1335-1341.
 62. Griffith DE, Brown-Elliott BA, Langsjoen B, et al. Clinical and molecular analysis of macrolide resistance in *Mycobacterium avium* complex lung disease. *Am J Respir Crit Care Med.* 2006;174:928-934.
 63. Yajko D, Kirihara J, Sanders C, et al. Antimicrobial synergism against *Mycobacterium avium* complex strains isolates from patients with acquired immune deficiency syndrome. *Antimicrob Agents Chemother.* 1988;32:1392-1395.
 64. Kohno Y, Ohno H, Miyazaki Y, et al. *In vitro* and *in vivo* activities of novel fluoroquinolones alone and in combination with clarithromycin against clinically isolated *Mycobacterium avium* strains in Japan. *Antimicrob Agents Chemother.* 2007;51:4071-4076.
 65. Bennett SI. Photosensitization induced by clofazimine in a cat. *Aust Vet J.* 2007;85:375-380.
 66. Deshpande D, Srivastava S, Meek C, et al. Moxifloxacin pharmacokinetics/pharmacodynamics and optimal dose and susceptibility breakpoint identification for treatment of disseminated *Mycobacterium avium* infection. *Antimicrob Agents Chemother.* 2010;54:2534-2539.
 67. Messias A, Gekeler F, Wegener A, Dietz K, Kohler K, Zrenner E. Retinal safety of a new fluoroquinolone, pradofloxacin, in cats: assessment with electroretinography. *Doc Ophthalmol.* 2008;116:177-191.
 68. Wiens K, Woyczynski LP, Ledesma JR, et al. Global variation in bacterial strains that cause tuberculosis disease: a systematic review and meta-analysis. *BMC Med.* 2018;16(1):196.

How to cite this article: Munro MJL, Byrne BA, Sykes JE. Feline mycobacterial disease in northern California: Epidemiology, clinical features, and antimicrobial susceptibility. *J Vet Intern Med.* 2021;35:273-283. <https://doi.org/10.1111/jvim.16013>