

Stem Cell Transplantation in Primary Myelofibrosis of Childhood

Bryan Mitton, MD, PhD,* Satiro de Oliveira, MD,* Sheeja T. Pullarkat, MD,†
and Theodore B. Moore, MD*

Summary: Fewer than 40 cases of primary myelofibrosis have been reported in children; hematopoietic stem cell transplantation is the only available curative therapy for this disease. Here, we describe the case of a female infant diagnosed with primary myelofibrosis at the age of 6 months; she underwent successful matched unrelated bone marrow transplantation with complete resolution of disease. We discuss some unique characteristics of primary myelofibrosis in children and review outcome data for children with this disease.

Key Words: bone marrow transplant, myelofibrosis, pediatrics

(*J Pediatr Hematol Oncol* 2013;35:e120–e122)

CASE DESCRIPTION

The patient is a 6-month-old white girl who presented to her primary physician with lethargy and pallor. The patient was a full-term infant born without complications and had no significant medical issues leading up to presentation. There was no pertinent hematologic or oncologic family medical history, there was no consanguinity, and she had received all of her vaccinations as scheduled. On examination, she was noted to have pallor and splenomegaly, but had normal growth parameters. A complete blood count was carried out, which revealed a white blood cell count of $18,200/\mu\text{L}$ with the presence of 11% blasts on differential. The hemoglobin was 5 g/dL, and platelets were $34.4 \times 10^9/\text{L}$.

For the initial concern of leukemia, a bone marrow biopsy and aspiration was performed. Histologically, the bone marrow biopsy showed >90% cellularity and marked fibrosis. The normal hematopoietic elements were difficult to ascertain because of the extensive fibrosis; however, there were scattered foci with a myeloid preponderance and left-shifted maturation. The erythroid series was markedly decreased. Megakaryocytes were not readily identified, and those present were small, hypolobated with hyperchromatic nuclei with scattered micromegakaryocytes by light microscopy. Increased eosinophils were also present (Figs. 1A, B). A reticulin stain was positive for marked fibrosis (Fig. 1C). Blasts were not increased as shown by CD34 and CD117 immunostains, although with this degree of fibrosis, immunostaining and morphologic examinations are typically limited in definitively ruling out the presence of blasts. Staining with Masson-Trichrome stain was also performed, which showed only scattered, coarse collagen fibers; thus, on a semiquantitative grading of marrow fibrosis, her biopsy was given a score of MF-2 on a scale of 0 to 3. Flow cytometry also demonstrated no increased blasts. Cytogenetic studies performed showed a normal female karyotype with no

clonal abnormalities. The patient was reevaluated with 2 subsequent marrow biopsies in the preceding months, both of which showed significant fibrosis on reticulin staining. Analysis performed for the *BCR-ABL*, *MPL* and *JAK2* gene mutations were negative. There was no evidence of JMML on GM-CFU assay.

The patient was managed conservatively over the course of the next 5 months. However, her splenomegaly increased to a span of 7 cm, palpable below the costal margin, and she became transfusion dependent for both red blood cells and platelets. After discussion with her family, the decision was made to proceed with hematopoietic stem cell transplantation. Genotyping revealed no HLA-matched individuals in her immediate family, and so an unrelated female bone marrow donor matching at 10 of 10 loci (HLA-A, HLA-B, HLA-C, HLA-DR and HLA-DQ) was selected for transplantation. The recipient blood type was O + , the donor was A + . The patient was conditioned with 16 doses of busulfan (1 mg/kg/dose every 6 h), followed by 4 doses of cytoxan (50 mg/kg/dose once per d). After 2 days of rest, the patient received the donor cells at a cell dose of 6.4×10^8 total nucleated cells/kg. The prophylaxis selected for graft versus host disease was solumedrol (1 mg/kg divided every 12 h) for 1 week, which was tapered until cessation in the following 2 weeks, and cyclosporine. Cyclosporine was continued until recovery of the immune cell count and functionality. White cell engraftment was successful, with an absolute neutrophil count stable over 1000 achieved on day 26 posttransplant. Platelet transfusions were given to keep the platelet count above $20 \times 10^9/\text{L}$ during conditioning and through this patient's transplant course; the transfusions were needed approximately twice per week. Platelet transfusions were required until day 35, at which point endogenous production yielded platelet counts above $20 \times 10^9/\text{L}$. Platelet counts remained stable above $50 \times 10^9/\text{L}$ by day 49. By this point, her spleen was palpable to 4 cm below the costal margin.

This patient's posttransplant course was benign, with no signs of acute skin, gut, or liver graft versus host disease; there was mild elevation of liver transaminases (alanine transaminase and aspartate aminotransferase) that was felt to be more consistent with liver fatty change, which was followed carefully by ultrasonography. Her spleen decreased in size to a palpable span of 1.5 cm below the costal margin 2 months after transplantation. Ten months after transplantation, a mitogen proliferation assay showed normal lymphocyte function, with normal T-cell and B-cell counts. Cyclosporine was discontinued. A bone marrow biopsy performed 1 year after transplantation showed a normocellular marrow with 95% cellularity and normal multilineage hematopoiesis (Figs. 1D, E). There was no evidence of increased fibrosis as confirmed by reticulin staining (Fig. 1F).

DISCUSSION

Primary myelofibrosis is a clonal hematopoietic stem cell neoplasm characterized by clonal myeloproliferation and resultant cytopenias, reactive bone marrow fibrosis, and extramedullary hematopoiesis. It is classified as a myeloproliferative neoplasm according to the 2008 World Health Organization classification system, along with polycythemia vera, essential thrombocytosis and a variety of chronic leukemias.¹ In adults, this disease has an incidence

Received for publication April 19, 2012; accepted January 15, 2013.
From the *Department of Pediatrics, Division of Hematology-Oncology, Mattel Children's Hospital at UCLA; and †Department of Pathology, UCLA David Geffen School of Medicine, Los Angeles, CA.

The authors declare no conflict of interest.

Reprints: Theodore B. Moore, MD, UCLA Pediatric Hematology/Oncology, UCLA Jonsson Comprehensive Cancer Center, Mattel Children's Hospital at UCLA, UCLA David Geffen School of Medicine, 10833 Le Conte Avenue, Los Angeles, CA 90095 (e-mail: tmoore@mednet.ucla.edu).

Copyright © 2013 by Lippincott Williams & Wilkins

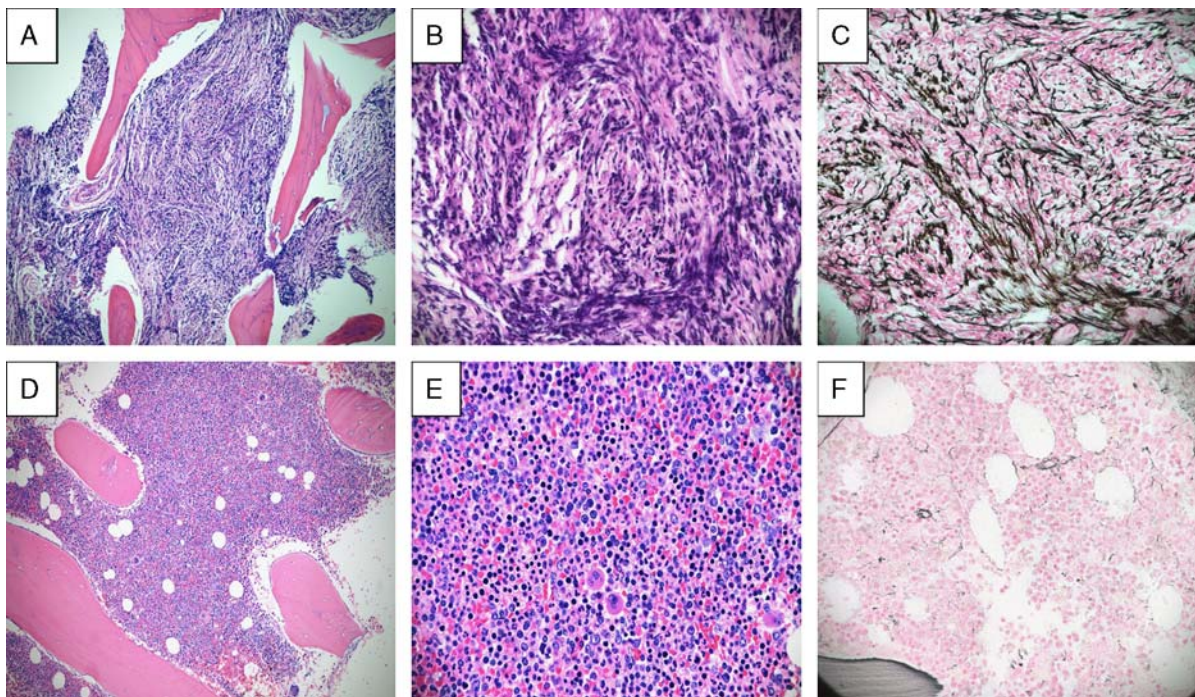


FIGURE 1. A composite of bone marrow biopsy histology and stains before (A–C) and after (D–F) matched unrelated bone marrow transplant. A, Bone marrow biopsy section ($\times 100$) depicts increased eosinophils and left-shifted myeloid maturation. B, A $\times 400$ view reveals extensive fibrosis with normal hematopoietic elements difficult to assess. C, A reticulin stain showing dense fibrous infiltration throughout the biopsy. D, Posttransplant bone marrow biopsy section ($\times 100$) showing 95% cellularity with normal multilineage hematopoiesis. E, A $\times 400$ view details normal trilineage hematopoiesis, normal progressive maturation in the myeloid and erythroid series, and megakaryocytes with normal morphology. F, A reticulin stain ($\times 400$) depicts no fibrosis.

of approximately 1 case per 100,000, and is even rarer in children, with <40 cases reported.² This disease is characterized by somatic mutations in *JAK2*, a member of the Janus Kinase tyrosine protein kinase family, present in approximately 50% of adults diagnosed with primary myelofibrosis.^{3–4} The full effector function of the mutated *JAK2* kinase (*JAK2-V617F*) remains unclear, although it is proposed that this mutant remains constitutively active and elicits activation of the thrombopoietin, erythropoietin, and granulocyte colony-stimulating factor receptors in the absence of their respective ligands.^{5–6} Although the *JAK2* mutation is the commonest mutation detected in adults, mutations have been described in a diverse array of proteins that play important roles in DNA methylation, apoptosis, protein ubiquitination, and transcriptional regulation.⁷

Notably, in none of the pediatric cases of primary myelofibrosis reported to date has a previously described mutation such as *JAK2-V617F* been identified, including the current case.^{8–18} There are a number of clues in the literature, however, that suggest that primary myelofibrosis in children may be a heritable disease, passed down in an autosomal recessive manner; this concept stands in contrast to adults diagnosed with this disease, in whom it appears to be a disease acquired by somatic mutation. Mallouh and Sa'di (1992) first raised this possibility on the basis of the observation of disease in 3 siblings in one family and 4 siblings in another.^{9,16} In the largest case series published to date, consanguinity was noted in 3 families of affected children, again suggesting that homozygosity is an important factor in the development of this disease.¹⁴ Other phenotypic differences appear to exist in children diagnosed

with primary myelofibrosis compared with adults, such as the frequent presence of marrow eosinophilia as seen in the current case, a reduced degree of marrow collagen fibrosis, and the absence of significant osteosclerosis. Moreover, as is evident in the current case, the megakaryocytic dysplasia seen in pediatric cases include hypolobated megakaryocytes with hyperchromatic nuclei and micromegakaryocytes unlike the hyperchromatic, smudgy, bulbous “cloud-like” nuclei typically described in adults.¹⁴

The International Prognostic Scoring System was developed in 2009; this enables patient risk stratification and thus guides therapy.¹⁹ The independent predictors of poor prognosis at the time of presentation include age above 65 years, hemoglobin <10 g/dL, white blood cell count >25,000, circulating blasts >1%, and the presence of constitutional symptoms. These guidelines were developed in a study that included children in the risk stratification analysis, making their application appropriate to this case. Our patient presented with 3 criteria, placing her in the “high risk” category; the associated median survival for this category is 2.3 years according to the International Prognostic Scoring System. Owing to the progressing clinical disease and this patient’s poor prognosis, the decision was made to proceed with hematopoietic stem cell transplantation. To date, reports are available for 17 children who have undergone hematopoietic stem cell transplantation.^{12–18} In these cases, all but 3 children underwent myeloablative conditioning, and only another 3 were selected for umbilical cord stem cell transplantations. Five deaths have been reported in these children, all secondary to infectious complications of transplantation, except for

1 child who died from complications of venoocclusive disease and pulmonary hypertension. All other children demonstrated resolution of disease after transplantation. In the present case, we demonstrate complete resolution of primary myelofibrosis after matched unrelated bone marrow transplantation. The histology demonstrates resolution of fibrosis, and immune system counts remain normal and stable. This patient has done quite well, and aside from a mild elevation of transaminases and radiologic changes consistent with fatty liver, she has experienced no transplant-related adverse effects.

The rarity of this disease in children renders the characterization of the pathologic processes that lead to or predispose to this disorder difficult. The hypothesis that primary myelofibrosis may stem from a heritable allele is intriguing; perhaps a previously unrecognized polymorphism in the *JAK2* gene or in a specific set of genes causes this disease. The phenotype and etiology of this disease suggest a difference in pathophysiology in children compared with that in adults. Regardless, transplantation remains the only available curative therapy. Future research may investigate the underlying signaling aberrations that lead to this myeloproliferative neoplasm in children; these inquiries may also shed light on adult disease and on other myeloproliferative neoplasms such as essential thrombocytosis and polycythemia vera.

REFERENCES

- Vardiman JW, Thiele J, Arber DA, et al. The 2008 revision of the World Health Organization (WHO) classification of myeloid neoplasms and acute leukemia: rationale and important changes. *Blood*. 2009;114:937–951.
- Mesa R, Silverstein M, Jacobson SJ, et al. Population-based incidence and survival figures in essential thrombocythemia and agnogenic myeloid metaplasia: an Olmsted County Study, 1976–1995. *Am J Hematol*. 1999;61:10–5.
- Kralovics R, Passamonti F, Buser AS, et al. A gain-of-function mutation of *JAK2* in myeloproliferative disorders. *N Engl J Med*. 2005;352:1779–1790.
- Levine RL, Wadleigh M, Cools J, et al. Activating mutation in the tyrosine kinase *JAK2* in polycythemia vera, essential thrombocythemia, and myeloid metaplasia with myelofibrosis. *Cancer Cell*. 2005;7:387–397.
- Lindauer K, Loerting T, Liedl KR, et al. Prediction of the structure of human Janus kinase 2 (*JAK2*) comprising the two carboxyterminal domains reveals a mechanism for autoregulation. *Protein Eng*. 2001;14:27–37.
- Luo H, Rose P, Barber D, et al. Mutation in the Jak kinase JH2 domain hyperactivates Drosophila and mammalian Jak-Stat pathways. *Mol Cell Biol*. 1997;17:1562–1571.
- Tefferi A. Primary myelofibrosis: 2012 update on diagnosis, risk stratification, and management. *Am J Hematol*. 2011;86:1017–1026.
- Boxer LA, Camitta BM, Berenberg W, et al. Myelofibrosis-myeloid metaplasia in childhood. *Pediatrics*. 1975;55:861–865.
- Mallouh AA, Sa'di AR. Agnogenic myeloid metaplasia in children. *Am J Dis Child*. 1992;146:965–967.
- Altura RA, Head DR, Wang WC. Long-term survival of infants with idiopathic myelofibrosis. *Br J Haematol*. 2000;109:459–462.
- Walia MR, Mehta R, Paul P. Idiopathic myelofibrosis with generalized periostitis in a 4-year-old girl. *J Pediatr Hematol Oncol*. 2005;27:278–282.
- Sekhar M, Prentice HG, Popat U, et al. Idiopathic myelofibrosis in children. *Br J Haematol*. 1996;93:394–397.
- Dommm J, Calder C, Manes B, et al. Unrelated stem cell transplant for infantile idiopathic myelofibrosis. *Pediatr Blood Cancer*. 2009;52:893–895.
- DeLario MR, Sheehan AM, Ataya R, et al. Clinical, histopathologic, and genetic features of pediatric primary myelofibrosis - an entity different from adults. *Am J Hematol*. 2012;87:461–464.
- Shaikh F, Naithani R, Kirby-Allen M, et al. Allogeneic cord hematopoietic stem cell transplantation in an infant with primary myelofibrosis. *J Pediatr Hematol Oncol*. 2012;34:e199–e201.
- Roszbach HC. Familial infantile myelofibrosis as an autosomal recessive disorder: preponderance among children from Saudi Arabia. *Pediatr Hematol Oncol*. 2006;23:453–454.
- Cahn JY, Plouvier E, Flesch M, et al. T cell-depleted allogeneic bone marrow transplantation in a case of childhood idiopathic myelofibrosis. *Bone Marrow Transplant*. 1987;2:209–211.
- Shankar S, Choi JK, Dermody TS, et al. Pulmonary hypertension complicating bone marrow transplantation for idiopathic myelofibrosis. *J Pediatr Hematol Oncol*. 2004;26:393–397.
- Cervantes F, Dupriez B, Pereira A, et al. New prognostic scoring system for primary myelofibrosis based on a study of the International Working Group for Myelofibrosis Research and Treatment. *Blood*. 2009;113:2895–2901.