

# UC Davis

## UC Davis Previously Published Works

### Title

External iliac vein compression secondary to osteolysis-induced hematoma in total hip arthroplasty

### Permalink

<https://escholarship.org/uc/item/5tq8z3nm>

### Journal

Arthroplasty Today, 5(3)

### ISSN

2352-3441

### Authors

Shieh, Alvin K  
Lum, Zachary C  
Singh, Avreetta K  
et al.


### Publication Date

2019-09-01

### DOI

10.1016/j.artd.2019.04.006

Peer reviewed



## Case report

## External iliac vein compression secondary to osteolysis-induced hematoma in total hip arthroplasty

Alvin K. Shieh, MD, MS<sup>\*</sup>, Zachary C. Lum, DO, Avreetta K. Singh, MD, Gavin C. Pereira, MD

Department of Orthopaedic Surgery, University of California Davis Medical Center, Sacramento, CA, USA

## ARTICLE INFO

## Article history:

Received 11 October 2018

Received in revised form

26 March 2019

Accepted 16 April 2019

Available online 19 June 2019

## Keywords:

Osteolysis

Iliac vein compression

Total hip arthroplasty

Leg swelling

Leg edema

## ABSTRACT

A 62-year-old man with a history of right total hip arthroplasty, who was managed conservatively for moderate osteolysis, presented with acute-onset, painless, significant, and diffuse right lower extremity edema. Initial laboratory markers were negative for infection. Advanced imaging demonstrated a complex extrapelvic fluid mass along the psoas sheath causing compression of the external iliac vein. Intraoperatively, significant hematoma was removed from the iliopsoas sheath, followed by metal head and liner exchange as well as bone grafting of the osteolytic defects adjacent to the hip implant. Post-operative imaging showed adequate decompression, no deep vein thrombosis, and a patent external iliac vein. At 2 weeks, postoperative swelling completely resolved. At 3 months, the patient recovered to normal baseline level and underwent contralateral total hip arthroplasty for symptomatic osteoarthritis. © 2019 Published by Elsevier Inc. on behalf of The American Association of Hip and Knee Surgeons. This is an open access article under the CC BY-NC-ND license (<http://creativecommons.org/licenses/by-nc-nd/4.0/>).

## Introduction

Several authors have reported on intrapelvic or extrapelvic masses leading to unilateral vascular abnormalities of the lower extremities. [1–6] In the setting of total hip arthroplasty, sources of such masses include adverse local tissue reaction associated with particulate debris, mechanically assisted crevice corrosion (MACC), failed metal-on-metal (MoM) bearing surface, and iliopsoas inflammatory bursitis. Here, we present a case of a failed total hip replacement presenting with osteolysis and MACC ultimately associated with an extrapelvic hematoma and venous obstruction with symptomatic unilateral leg edema.

## Case history

A 62-year-old man had previously undergone an uncomplicated right total hip arthroplasty 15 years ago in 2002 using an

uncemented Zimmer Trilogy cup, with 60-mm outer diameter, lipped ultra-high-density polyethylene liner, 28-mm internal diameter, metal femoral head, and anatomic porous coated stem (Zimmer Biomet, Warsaw, IN). He was first referred to our clinic in 2013 for radiographic findings suggestive of osteolysis and presented with negative infectious laboratory markers and negative hip aspirate. At the time, he reported having mild hip pain with hip flexion, which greatly improved with physical therapy. Computed tomography (CT) and magnetic resonance imaging (MRI) at the time demonstrated osteolytic lesions in the acetabulum and proximal femur, a bony pedestal distal to the femoral stem, and a 4.7 × 1.8-cm loculated extrapelvic cystic fluid collection just anterior to the hip joint (Fig. 1a and b). Given near-complete resolution of his symptoms, the decision was made to monitor for any progression.

The patient did not follow up for the next several years as he had returned to full activities including skiing without any issues. In January 2017, he developed an episode of bronchitis treated with oral antibiotics and also developed uncontrolled atrial fibrillation for which he was placed on digoxin and dabigatran and then later transitioned to amlodipine. Two weeks later, he woke up with severe right hip pain exacerbated by hip flexion. He presented to a nearby emergency department (ED) where workup showed normal white blood cell count (10,100 per  $\mu\text{L}$ , normal 4000 to 11,000 per  $\mu\text{L}$ ) but elevated inflammatory markers (erythrocyte sedimentation rate, ESR 82 mm/h [normal, 0–20 mm/h]; C-reactive protein, CRP 4.5 mg/L [normal <3.0 mg/L]; interleukin-6, IL-6 22.4 pg/mL

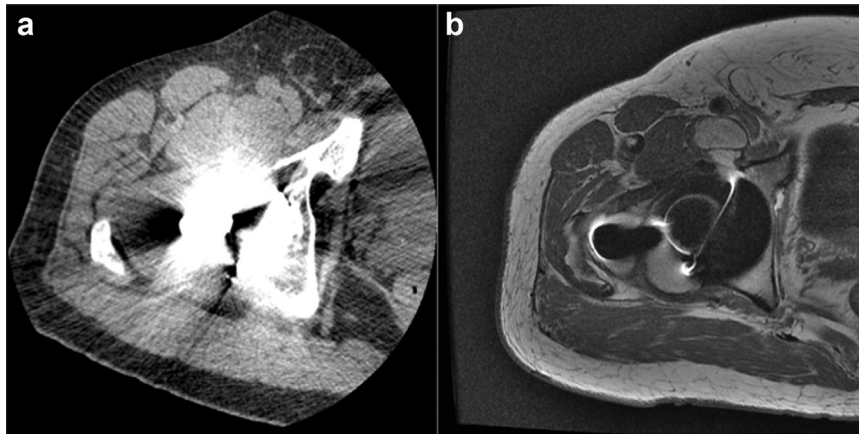
One or more of the authors of this paper have disclosed potential or pertinent conflicts of interest, which may include receipt of payment, either direct or indirect, institutional support, or association with an entity in the biomedical field which may be perceived to have potential conflict of interest with this work. For full disclosure statements refer to <https://doi.org/10.1016/j.artd.2019.04.006>.

<sup>\*</sup> Corresponding author. Department of Orthopaedic Surgery, University of California Davis Medical Center, 4860 Y Street, Suite 3800, Sacramento, CA 95817, USA. Tel.: +1 916 734 2182.

E-mail address: [akshieh@ucdavis.edu](mailto:akshieh@ucdavis.edu)

<https://doi.org/10.1016/j.artd.2019.04.006>

2352-3441/© 2019 Published by Elsevier Inc. on behalf of The American Association of Hip and Knee Surgeons. This is an open access article under the CC BY-NC-ND license (<http://creativecommons.org/licenses/by-nc-nd/4.0/>).



**Figure 1.** CT scan (a) and MRI (b) performed 5 years ago showing a smaller cystic lesion anterior to the acetabular component but without any vascular compression.

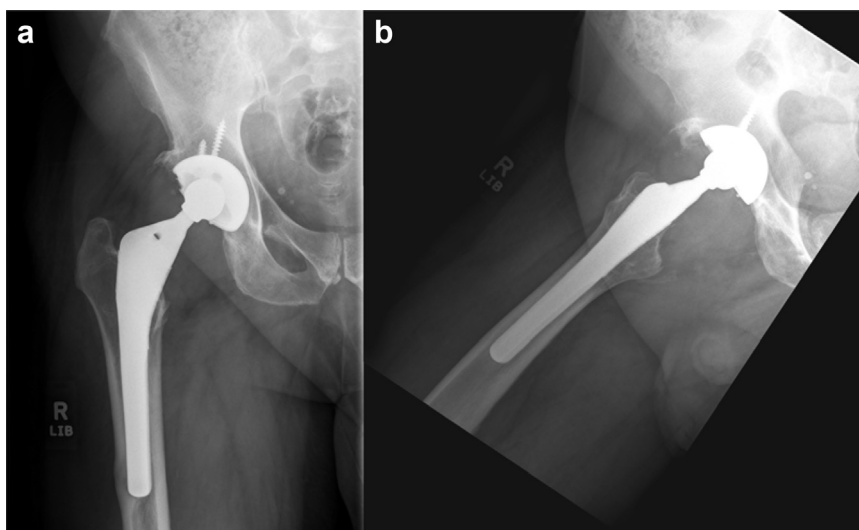
[normal, 5–15 pg/mL]) and CT suggestive of appendicitis. He was treated with a 2-week course of an oral antibiotic, and his pain resolved over the next couple of weeks.

In July 2017, he called our clinic complaining of acute-onset right hip pain while working on his house. The pain self-resolved within one day, but he had persistent diffuse right lower extremity edema and was therefore referred to our ED. Plain radiographs showed no appreciable change in the known osteolytic lesions (Fig. 2). Doppler ultrasound was negative for any deep vein thrombosis (DVT), but there was noted to be an 11.5 × 5.5 × 5.9-cm hypoechoic mass in the inguinal region. CT pelvis demonstrated a consolidated mass in the region of the iliopsoas bursa causing compression of the external iliac vein (Fig. 3a). Aspiration was attempted by the interventional radiology team, but less than 1 cc hematoma was withdrawn. His neurovascular examination was negative for any pertinent findings, but his entire right lower extremity remained moderately edematous. A preoperative MRI was performed and characterized the large multiloculated, cystic fluid collection around the iliopsoas sheath with extension past the pelvic brim and concomitant compression of the external iliac vein (Fig. 3a and b). Electrocardiogram demonstrated normal sinus rhythm, so no anticoagulation was given.

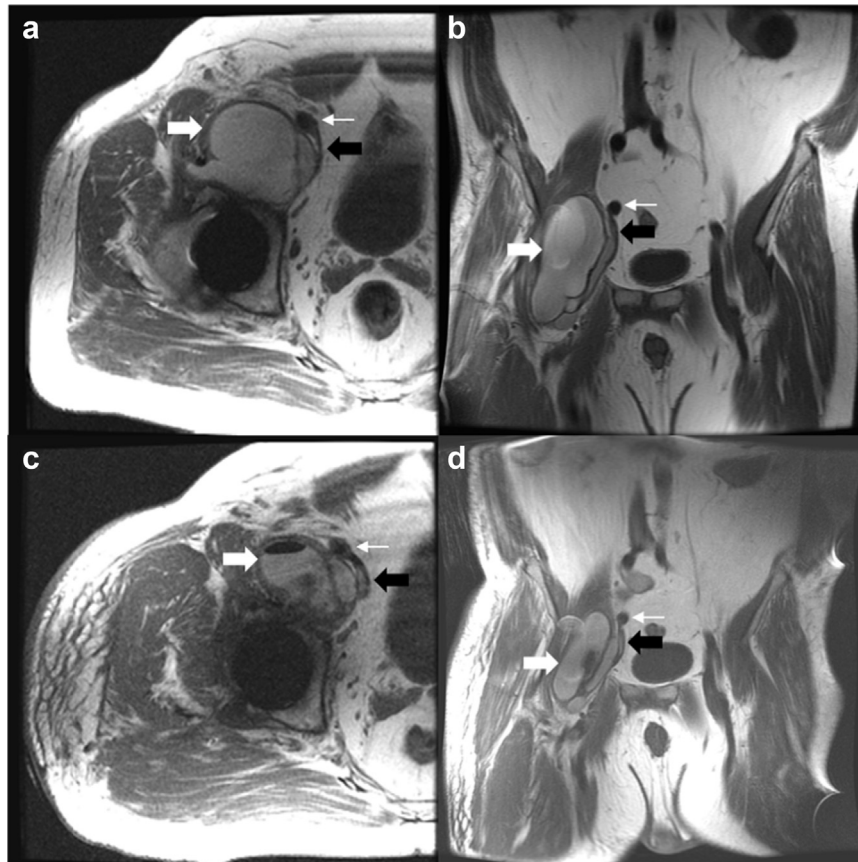
A few days after ED presentation, he underwent revision total hip arthroplasty with decompression of the intrapelvic mass. The patient's prior standard posterolateral hip incision was used.

Hematoma around the femoral head and neck junction was noted. The anterior capsule was incised, and a large amount of gelatinous hematogenous material (more than 250 cc) was encountered and evacuated (Fig. 4). After dislocation, the femoral head was removed and examined closely. The head-neck junction was notable for corrosion of the trunnion with a Goldberg score of 2 (Fig. 5). The polyethylene liner was removed and noted to be mildly worn. Curettage was carried out within a cystic defect at the root of the superior pubic ramus. Further curettage was performed along the greater trochanter just lateral to the stem, followed by pulse irrigation of the defects. The acetabular cup and femoral stem were noted to be stable and were therefore retained. The cystic defects were then filled with Cerament (Zimmer Biomet, Warsaw, IN) bone graft substitute at the superior pubic ramus defect and at the greater trochanter. A Zimmer Trilogy Longevity 36-mm highly cross-linked polyethylene liner and Zimmer Trilogy 36-mm metal head were placed, and the wound was then closed in layers. No drain was placed.

The patient was ambulating by postoperative day 1. A repeat MRI was performed which demonstrated significant decrease in the fluid collection around the iliopsoas bursa and decompression of the external iliac vein (Fig. 3c and d). Postoperative vascular duplex studies demonstrated no DVT in the right lower extremity. He was placed on enoxaparin for DVT chemoprophylaxis for 4 weeks, which is our preference for patients undergoing revision

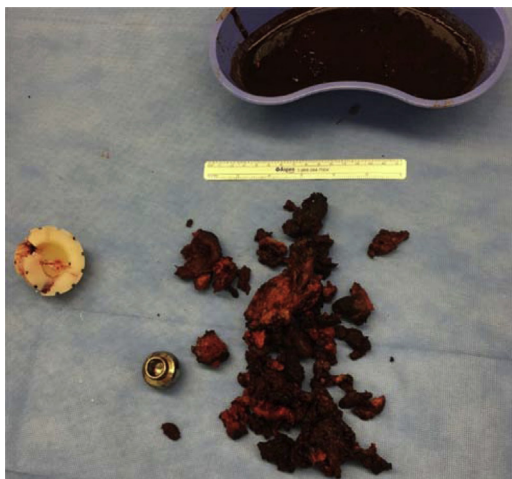


**Figure 2.** Anteroposterior (AP) (a) and lateral hip (b) radiographs demonstrating osteolytic lesions along the superior pubic ramus and greater trochanter.



**Figure 3.** Preoperative axial (a) and coronal (b) MRI demonstrating enlarged cystic lesion (thick white arrow) compressing the external iliac vein (thick black arrow) adjacent to the external iliac artery (thin white arrow). Postoperative axial (c) and coronal (d) MRI demonstrating decompression of the cystic lesion and right external iliac vein.

arthroplasty procedures. The patient was discharged home by postoperative day 4. Five intraoperative microbiology cultures showed a negative gram stain, no acute inflammation was seen on the frozen section, and no growth was observed on cultures, which finalized at 2 weeks. He returned to clinic at 2 weeks postoperatively for routine follow-up and was noted to be doing very well with near-complete resolution of his leg edema. By 4 weeks postoperatively, he felt his legs were symmetric, and he was interested in pursuing total hip arthroplasty on the contralateral side (Fig. 6).



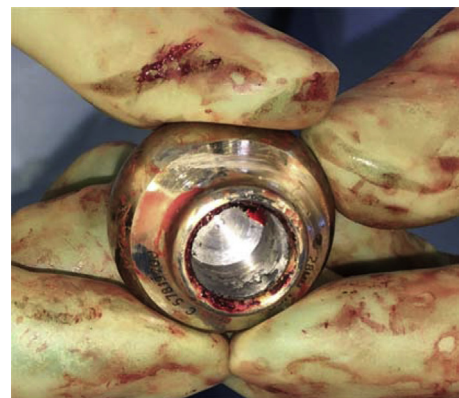**Figure 4.** Consolidated hematoma removed from patient.

Samples of the hematoma were sent to pathology for further analysis. No signs of aseptic lymphocyte-dominant vasculitis-associated lesion (ALVAL) were seen on the slides, although there were fragments of foreign material with indeterminate etiology.

This article was prepared with full consent provided by the patient.

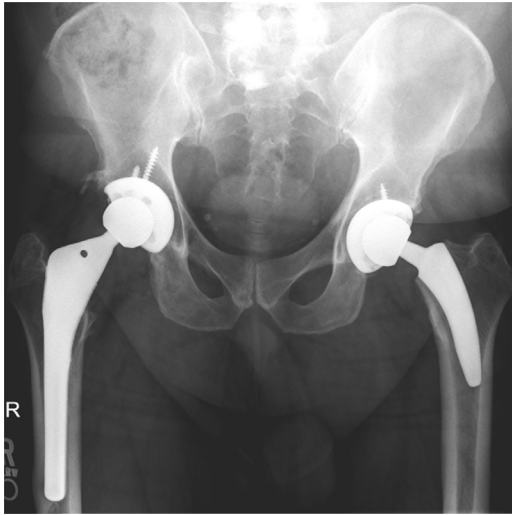
### Discussion

The causes of unilateral leg edema are relatively limited compared to bilateral edema. The differential diagnosis generally includes compressive and obstructive lesions affecting the venous or lymphatic outflow of the extremity, such as DVT or



**Figure 5.** Metal head with fretting corrosion seen within the bore.





**Figure 6.** Anteroposterior pelvis radiograph obtained 9 months after revision of the right side and 3 months after the primary left total hip arthroplasty.

tumor—either associated with an intrapelvic organ or derived from surrounding tissue. Additional case reports of systemic inflammatory conditions such as thyroiditis and non-Hodgkin's lymphoma have been implicated as the cause of unilateral edema [7-9]. Less commonly, an iliopsoas bursa may cause extravascular compression even without a metal implant [10].

The workup of unilateral leg edema in patients with a total hip arthroplasty should include Doppler ultrasound to assess for DVT and inflammatory laboratory tests including complete blood count, ESR, and CRP to evaluate for prosthetic joint infection. In the setting of an MoM prosthesis, a commonly reported cause is pseudotumor secondary to an adverse reaction due to metal debris, and therefore, serum metal ion levels should be obtained. More recently, MACC has been shown to be associated with adverse local tissue reaction in some patients with metal-on-polyethylene total hip replacement [11]. Finally, advanced imaging in the form of CT or MRI should be performed to clearly visualize any compressive lesions.

Previous authors have reported on extravascular venous compression near a total hip arthroplasty secondary to polyethylene wear debris [2,5], adverse local tissue reaction to surface metal ions in a failed MoM implant [1,12], and iliopsoas bursitis [6]. A brief review of the literature confirms that external vascular compression secondary to an enlarged iliopsoas bursa is a rare complication of total hip arthroplasty. The particulate wear debris seen in aseptic loosening and non-cross-linked polyethylene wear stimulate an inflammatory reaction resulting in increased synovial fluid production. The increased synovial fluid within the hip joint can communicate via an extension to the adjacent iliopsoas bursa, which is described in as many as 40% of patients [13].

In similar case reports to ours, patients presented anywhere from 4 to 20 years after the index procedure with a primary complaint of unilateral leg edema, but generally a benign hip examination [6,14-16]. Inflammatory laboratory tests for the most part were within normal limits in all cases, and Doppler studies were negative for DVT. Radiographs were not always diagnostic for osteolysis, and typically, the diagnosis was made via a combination of ultrasound, arthrography, or MRI. In all the listed reports, a hip aspiration was performed, which yielded no gross purulence, and all cultures remained negative.

In our patient, we highlight that there was known asymptomatic osteolysis followed up radiographically for several years. Aspiration of the lesion yielded limited hematogenous material with no discrete fluid collection, whereas other case reports typically have yellowish or

serosanguinous fluid aspirates that often result in at least temporary improvement in venous flow and symptomatic edema [2,4-6,13]. Instead, our intraoperative findings yielded coagulated hematoma without evidence of a fluctuant mass suggestive of a cyst lesion. In addition, there was macroscopic evidence of mild corrosion on the trunnion of the stem and bore of the removed metal head seen during revision hip arthroplasty. Unfortunately, no metal ion serum markers were drawn in the perioperative period to support the diagnosis of MACC. Furthermore, the pathologist reviewing the intraoperative specimens identified fibrinous debris, hemosiderin, foreign body giant cell reaction, and no evidence of metal particles or ALVAL. We therefore cannot definitively state the clinical relevance of the corrosion seen on the metal implants, although our suspicion is that this was relatively insignificant compared with the known osteolysis adjacent to the prosthesis. Altogether, we suspect that the osteolytic debris led to erosion of a small vessel nearby and causing a large hematoma compressing the external iliac vein and ultimately resulting in unilateral leg edema. Alternatively, the patient's osteolysis, which is atypical in patients with cross-linked polyethylene, may have been an early manifestation of MACC; the extrapelvic hematoma was a later finding.

For future cases, we recommend obtaining metal ion levels when evaluating osteolysis with cross-linked polyethylene bearing surfaces. Consideration of a non-cobalt alloy femoral head, such as a ceramic head with revision titanium sleeve, should also be made to avoid ongoing cobalt-related adverse local tissue reaction [17]. Finally, longer term follow-up is necessary to determine if our intervention was curative in this case.

## Summary

In conclusion, we have presented a case of asymptomatic osteolysis in a patient who years later developed an extrapelvic hematoma causing extravascular compression of the external iliac vein resulting in diffuse ipsilateral lower extremity edema. Both CT and MRI were able to visualize the compressive lesion and aided in our ability to treat this with surgical decompression. The underlying etiology of this compression was mostly attributed to a granulomatous response to wear debris from a polyethylene liner along with a reaction to fretting corrosion seen along the bore of the metal femoral head. After decompression and bone grafting of the defects, the patient's unilateral leg edema resolved within 4 weeks and without complications.

## References

- [1] Algarni AD, Huk OL, Pelmus M. Metallosis-induced iliopsoas bursal cyst causing venous obstruction and lower-limb swelling after metal-on-metal THA. *Orthopedics* 2012;35:e1811.
- [2] Beksac B, Tozun R, Baktiroglu S, Sener N, Gonzalez Della Valle A. Extravascular compression of the femoral vein due to wear debris-induced iliopsoas bursitis: a rare cause of leg swelling after total hip arthroplasty. *J Arthroplasty* 2007;22:453.
- [3] Clark FD, Fong HM. Extrinsic compression of the external iliac vein following total hip arthroplasty. *Eur J Vasc Endovasc Surg* 1995;10:128.
- [4] Lax Perez R, Salinas Gilabert JE, Lajara Marco F, et al. [Femoral superficial vein thrombosis due to a large iliopsoas bursitis secondary to polyethylene wear debris in total hip arthroplasty]. *Rev Esp Cir Ortop Traumatol* 2012;56:54.
- [5] Wang JW, Lin CC. Pelvic mass caused by polyethylene wear after uncemented total hip arthroplasty. *J Arthroplasty* 1996;11:626.
- [6] Yang SS, Bronson MJ. Cystic enlargement of the iliopsoas bursa causing venous obstruction as a complication of total hip arthroplasty. A case report. *J Arthroplasty* 1993;8:657.
- [7] Volke V, Matjus S. Unilateral pitting edema of the leg as a manifestation of Graves' disease: a case report. *J Med Case Rep* 2012;6:258.
- [8] Elgandy IY, Lo MC. Unilateral lower extremity swelling as a rare presentation of non-Hodgkin's lymphoma. *BMJ Case Rep* 2014;2014. bcr2013202424.
- [9] Sajid T, Intisar ul H, Haq I, Chaudhary AK. An obscure cause of leg edema, non-Hodgkin's lymphoma. *J Coll Physicians Surg Pak* 2009;19:254.

- [10] Natsume K, Yamamoto K, Tanaka K, Hiraiwa T, Tanaka K. A case of external compression of femoral vein by the enlarged iliopsoas bursa with long term edema. *Ann Vasc Dis* 2015;8:100.
- [11] Hussey DK, McGrory BJ. Ten-year cross-sectional study of mechanically assisted crevice corrosion in 1352 consecutive patients with metal-on-polyethylene total hip arthroplasty. *J Arthroplasty* 2017;32:2546.
- [12] Kawakita K, Shibamura N, Tei K, Nishiyama T, Kuroda R, Kurosaka M. Leg edema due to a mass in the pelvis after a large-diameter metal-on-metal total hip arthroplasty. *J Arthroplasty* 2013;28:197.e1.
- [13] DeFrang RD, Guyer WD, Porter JM, Duwelius PJ. Synovial cyst formation complicating total hip arthroplasty: a case report. *Clin Orthop Relat Res* 1996:163.
- [14] Matsumoto K, Hukuda S, Nishioka J, Fujita T. Iliopsoas bursal distension caused by acetabular loosening after total hip arthroplasty. A rare complication of total hip arthroplasty. *Clin Orthop Relat Res* 1992:144.
- [15] Mak KH, Wong TK, Poddar NC. Wear debris from total hip arthroplasty presenting as an intrapelvic mass. *J Arthroplasty* 2001;16:674.
- [16] Butler RA, Barrack RL. Total hip wear debris presenting as lower extremity swelling. A report of two cases. *J Bone Joint Surg Am* 2004;86-A:142.
- [17] McGrory BJ, McKenney BR. Revision for taper corrosion at the head-neck junction: pearls and pitfalls. *Curr Rev Musculoskelet Med* 2016;9:97.