

UC San Diego

UC San Diego Previously Published Works

Title

Peroral Endoscopic Myotomy for the Treatment of Esophageal Diverticula

Permalink

<https://escholarship.org/uc/item/5v41z8jk>

Journal

Journal of Clinical Gastroenterology, 56(10)

ISSN

0192-0790

Authors

Facciorusso, Antonio

Ramai, Daryl

Ichkhanian, Yervant

et al.

Publication Date

2022-11-01

DOI

10.1097/mcg.0000000000001622

Peer reviewed



Published in final edited form as:

J Clin Gastroenterol. 2022 ; 56(10): 853–862. doi:10.1097/MCG.0000000000001622.

Peroral Endoscopic Myotomy for the Treatment of Esophageal Diverticula: A Systematic Review and Meta-analysis

Antonio Facciorusso, MD, PhD¹, Daryl Ramai, MD, MSc², Yervant Ichkhanian, MD³, Rena Yadlapati, MD⁴, Vito Annese, MD⁵, Sachin Wani, MD⁶, Mouen A. Khashab, MD³

¹Gastroenterology Unit, University of Foggia, Foggia, Italy

²Department of Medicine, The Brooklyn Hospital Center, Brooklyn, New York.

³Division of Gastroenterology and Hepatology, John Hopkins University Hospital, Baltimore

⁴Division of Gastroenterology, University of California San Diego, La Jolla, California

⁵Valiant Clinic & American Hospital, Dubai, United Arab Emirates

⁶University of Colorado Anschutz Medical Campus, Aurora, Colorado, U.S.A.

Abstract

Background: There is limited evidence on the efficacy of per-oral endoscopic myotomy (POEM) in patients with esophageal diverticula.

Aims: This meta-analysis aimed to assess the efficacy and safety profile of POEM in patients with Zenker's (ZD) and epiphrenic diverticula.

Methods: With a literature search through August 2020, we identified 12 studies (300 patients) assessing POEM in patients with esophageal diverticula. Primary outcome was treatment success. Results were expressed as pooled rates and 95% confidence intervals (CI).

Results: Pooled rate of technical success was 95.9% (93.4%–98.3%) in ZD patients and 95.1% (88.8%–100%) in patients with epiphrenic diverticula. Pooled rate of treatment success was similar for ZD (90.6%, 87.1%–94.1%) and epiphrenic diverticula (94.2%, 87.3%–100%). Rates of treatment success were maintained at 1 year (90%, 86.4%–97.4%) and 2 years (89.6%, 82.2%–96.9%) in ZD patients. Pooled rate of symptom recurrence was 2.6% (0.9%–4.4%) in ZD patients and 0% in patients with epiphrenic diverticula. Pooled rates of adverse events and severe adverse events were 10.6% (4.6%–16.6%) and 3.5% (0%–7.4%) in ZD and 8.4% (0%–16.8%) and 8.4% (0%–16.8%) in epiphrenic diverticula, respectively.

Correspondence: Daryl Ramai, MD., MScBR, Department of Internal Medicine, The Brooklyn Hospital Center, Brooklyn, New York. 11201, dramai@tbh.org.

Author Contributions:

- Study concept and design: AF, YI, MAK
- Acquisition of data: AF, YI, DR
- Analysis and interpretation of data: AF, MAK, RY
- Drafting of the manuscript: AF, YI., DR, VA, RY, MAK
- Critical revision of the manuscript for important intellectual content: RY, MAK, VA, SW
- Approval of the final manuscript: All of the authors

Conclusions: POEM represents an effective and safe therapy for the treatment of esophageal diverticula.

Keywords

POEM; Septotomy; Endoscopy; Zenker

INTRODUCTION

Esophageal diverticula are rare structural abnormalities which account for <5% of all patients with dysphagia¹. Zenker's diverticulum (ZD) is the most common type of esophageal diverticula, with a reported prevalence ranging from 0.01 % to 0.11 %², whereas diverticula located in the distal esophagus, called epiphrenic diverticula, are frequently associated with esophageal motility disorders and have an estimated prevalence of 0.015%³. Treatment is recommended for symptomatic patients as esophageal diverticula can lead to complications, such as aspiration and severe dysphagia. Surgical diverticulectomy with myotomy represents the standard surgical treatment, able to provide excellent results (symptom relief 85–100%)^{2,3}, but with long operation times and high rates of adverse events, including leaks, pulmonary complications, and 0–7% risk of mortality^{2,3}.

Direct flexible endoscopic septotomy has been routinely practiced but carries a relatively high recurrence rate due to incomplete division of the septum⁴. On the other hand, submucosal tunneling septotomy by diverticular peroral endoscopic myotomy (D-POEM) was introduced several years ago. It is performed using a submucosal tunneling approach and, thus, allows complete septum division⁵. Recently this technique was used effectively for septotomy in patients with Zenker's^{6,7} (where it is called Z-POEM) and epiphrenic diverticula⁸. D-POEM has the potential advantage of allowing a complete septotomy to be performed in a single session and thus potentially reducing recurrence rates.

Given the increasing number of studies testing POEM in patients with esophageal diverticula, there is a pressing need to systematically revise the available body of evidence in this field; hence, we performed a meta-analysis to provide a pooled estimate of the efficacy and safety profile of D-POEM. As a secondary analysis, we examined the comparative efficacy of D-POEM with respect to standard flexible endoscopic treatments.

METHODS

Selection Criteria

The literature search strategy was based on the following inclusion criteria: (1) observational or cohort studies assessing POEM in adult patients with esophageal diverticula; (2) studies published in English; (3) articles reporting treatment success. Small case series <5 patients, non-endoscopic studies, review articles, animal models, and studies not reporting separately subgroup data according to diverticulum location were excluded.

Search Strategy

Literature search was conducted on PubMed, EMBASE, Cochrane Library, and Google Scholar including all studies fulfilling the inclusion criteria published through August 2020, based on the string “Search ((POEM) AND Zenker) OR Esophageal diverticula”.

Relevant reviews and meta-analyses in the field were examined for potential additional suitable studies. Authors of included studies and conference abstracts were contacted to obtain full text or further information when needed. Manual search on the proceedings of the main international endoscopic and gastroenterological conferences was also performed.

Data extraction was performed by 2 authors (AF and YI) and the quality of included studies was rated by 2 reviewers independently (AF and YI) based on the Newcastle-Ottawa scale for non-randomized studies⁹. Disagreements were solved by discussion and after a third opinion (MAK).

Outcomes Assessed

The primary efficacy outcome was treatment success, defined based on decrease of Eckardt score (which measures symptom severity for dysphagia, regurgitation, retrosternal pain and weight loss)¹⁰ to 3 in 3 studies^{11,12,22}, decrease of Dakkak and Bennett score (0, no dysphagia; 1, dysphagia to solids; 2, dysphagia to semisolids; 3, dysphagia to liquids; 4, complete dysphagia)¹³ to 0 or 1 in 5 studies¹⁴⁻¹⁹, improvement of dysphagia in 1 study⁸, not specified in other 2 series^{20,21}. Secondary outcomes included technical success, recurrence, procedural times, length of hospital stay, and safety profile.

Statistical Analysis

Study outcomes were pooled separately according to diverticulum location (Zenker’s versus epiphrenic) through a random-effects model based on DerSimonian and Laird test, and results were expressed as rates and 95% confidence interval (CI).

The presence of heterogeneity was calculated through I^2 tests with $I^2 < 20\%$ and interpreted as low-level and I^2 between 20% to 50% as moderate heterogeneity. Any potential publication bias was verified through visual assessment of funnel plots. Sensitivity analysis was conducted in the subset of ZD patients restricted to (1) high quality studies, (2) prospective studies, and (3) according to study location (East versus West). A further sensitivity analysis was performed restricted only to studies with standard Z-POEM.

Subgroup analysis of the primary outcome (treatment success) concerning ZD patients was performed based on timing of response assessment (3 months versus 1 year versus >1 year). In order to explore the impact of diverticulum size, timing of response assessment, and prior treatments on the primary endpoint, a meta-regression model was built based on a stepwise backward approach²³.

All pooled analyses were conducted using OpenMeta[Analyst] software whereas R 3.0.2 (R Foundation for Statistical Computing, Vienna, Austria), *metafor* package²⁴ was used for meta-regression. For all calculations a 2-tailed P value of less than 0.05 was considered statistically significant.

RESULTS

Studies

As shown in Figure 1, of 3380 studies initially identified, after exclusion of articles not fulfilling the inclusion criteria, 12 studies^{8,11,12,14–22} with 300 patients treated with POEM were included in the meta-analysis. Of 12 included studies, 4 were retrospective case-control studies comparing POEM to flexible endoscopic treatment^{14,19–21}, 7 were retrospective single-cohort series^{8,11,12,15,16,18,22} and one was a prospective series¹⁷.

The main characteristics of the included studies were reported in Table 1. The recruitment period ranged from 2013 to 2020. Four studies were conducted in Asia^{12,20–22} and the 4 comparative studies^{14,19–21} presented 2 well-balanced cohorts in terms of baseline patients characteristics. Three studies were published as conference abstracts^{14,20,21}. Seven studies tested POEM in patients with Zenker's diverticula^{14,16–21}, 4 studies in epiphrenic diverticula^{8,11,12,22}, a single study included patients with different diverticulum locations¹⁵. The majority of treated patients were male and mean diverticulum size ranged from 1.75 to 6.07 cm.

Among the studies conducted in patients with epiphrenic diverticula, three studies used POEM with septum division^{8,12,15} and two studies used POEM alone (hence with diverticulum left intact)^{11,22}. On the other hand, patients with Zenker's diverticula were treated with Z-POEM (septotomy of Zenker's diverticula by diverticular peroral endoscopic myotomy) in all of the included studies except the series by Repici *et al*¹⁷ where a variant of Z-POEM with short mucosotomy (peroral endoscopic septotomy [POES]) was performed.

Six studies included only patients not previously treated for esophageal diverticula [12,14,17,19–21], five studies included 4% to 28% of patients with prior treatments^{8,11,15,16,22}, and 1 cohort included only patients with previous treatments¹⁸. Most of the patients with epiphrenic diverticula were affected by achalasia.

Quality was deemed moderate to high in 9 studies^{8,11,12,15–19,22} whereas 3 studies^{14,20,21} were rated as low-quality articles mainly due to incomplete outcome reporting.

Details on the quality assessment of the included articles are shown in Supplementary Table 1.

Treatment success in ZD patients

As depicted in Figure 2, pooled rate of treatment success with POEM in patients with Zenker's diverticula was 90.6% (87.1%–94.1%), with no evidence of heterogeneity ($I^2=0\%$). Rates of treatment success observed at 3 months (130 patients, 90.6%, 85.7%–95.5%) were maintained at 1 year (72 patients, 90%, 86.4%–97.4%) and 2 years (101 patients, 89.6%, 82.2%–96.9%; Table 2).

The aforementioned findings were confirmed in sensitivity analysis restricted to high quality studies, prospective series, and according to study location (Supplementary Table 2). Furthermore, sensitivity analysis restricted to studies using standard Z-POEM (hence by

excluding the study by Repici *et al*¹⁷ where POES was used) also confirmed the results of the main analysis (pooled success rate 89.8%, 85.9%–93.8%; Supplementary Table 2).

The kinetics of symptomatic scores in treated patients is reported in the Supplementary Figure 1. In patients with ZD, mean Dakkak and Bennett score decreased from 2.18 (1.78–2.57) at baseline to 0.04 (0–0.14) at 6 months and 0.26 (0.15–0.36) at 1 year (Supplementary Figure 1a).

Meta-regression aiming to correlate several baseline variables to the primary outcome did not find any significant impact of prior treatments, timing of response assessment, and diverticulum size on treatment success (Supplementary Table 3).

In particular, as reported in the Supplementary Figure 2, there was no correlation between the proportion of patient with previous treatments (Supplementary Figure 2a) and mean diverticular size (Supplementary Figure 2b) with treatment success. No evidence of publication bias was observed through visual inspection of the funnel plot (Supplementary Figure 3a).

Treatment success in patients with epiphrenic diverticula

As reported in Figure 3 and Table 2, pooled rate of treatment success with POEM in patients with epiphrenic diverticula was 94.2% (87.3%–100%), again with no evidence of heterogeneity ($I^2=0\%$). Subgroup analysis showed 91.8% (80.2%–100%) pooled success in patients treated with POEM with septum division and 95.5% (86.9%–100%) efficacy in patients treated with POEM alone. Mean Eckardt score in patients with epiphrenic diverticula and achalasia decreased from 8.38 (2.17–14.6) at baseline to 2.54 (0–7.54) at 6 months and 1.51 (0–3.82) at 1 year (Supplementary Figure 1b).

As above reported in ZD patients, also in patients with epiphrenic diverticula meta-regression aiming to correlate several baseline variables to the primary outcome did not find any significant correlation of baseline variables with treatment success (Supplementary Table 3).

No evidence of publication bias was observed through visual inspection of the funnel plot (Supplementary Figure 3b).

Secondary outcomes

Secondary efficacy outcomes are reported in Table 3.

Technical success: Pooled rate of technical success was 95.9%, (93.4%–98.3%) in ZD patients and 95.1% (88.8%–100%) in patients with epiphrenic diverticula.

Symptoms recurrence: Mean follow-up length was 15 ± 3 months in ZD patients and 10.5 ± 5 months in patients with epiphrenic diverticula. Pooled rate of symptom recurrence was 2.6% (0.9%–4.4%) in ZD patients and 0% in patients with epiphrenic diverticula.

Procedure time: Procedure time in patients with epiphrenic diverticula was 61.7 minutes (38.4–84.9) whereas it was 44.7 minutes (30–59.4) in ZD patients.

Length of hospital stay: Length of hospital stay was 5.6 days (4.8–6.4) in patients with epiphrenic diverticula and 1.2 days (1–1.1) in ZD patients.

Safety profile: Pooled rate of adverse events was 7.6% (4.1%–11.1%) in the overall cohort, in particular it was 10.6% (4.6%–16.6%) in ZD patients and 8.4% (0%–16.8%) in patients with epiphrenic diverticula. Overall pooled rate of serious adverse events was 3.5% (0%–7.4%) in ZD patients and 8.4% (0%–16.8%) in patients with epiphrenic diverticula. The adverse events observed in the included studies are detailed in Supplementary Table 4. Perforation represented the most frequent complication, followed by bleeding. Two studies did not specify the adverse events registered^{14,21}.

DISCUSSION

Surgery and standard flexible endoscopic treatment represent the most frequent therapeutic strategies in patients with esophageal diverticula. In recent years, POEM, a minimally invasive procedure used to treat esophageal disorders such as achalasia²⁵, has emerged as an endoscopic therapy for esophageal diverticula, termed D-POEM.

Previous meta-analyses explored this important issue but with several limitations, such as very low number of studies (particularly focused on ZD patients), lack of long-term outcomes, and limited assessment of the impact of potentially confounding factors on treatment outcomes through adequate statistical methods^{26,27}.

Through a meta-analysis of 12 studies, we made several key observations about the clinical role of POEM in patients with esophageal diverticula. First, POEM resulted in very high rates of treatment success (beyond 90%) both in patient with Zenker's and epiphrenic diverticula. These favorable outcomes were maintained over time even at 2 years from treatment and rate of symptom recurrence was very low (2.6% in ZD patients and 0% in subjects with epiphrenic diverticula). In meta-regression analysis, treatment outcomes were maintained regardless of diverticulum size and prior treatments. Further, the rate of technical success was over 95% for both Zenker's and epiphrenic diverticula. Second, POEM showed a promising safety profile, with only 7.6% and 3.3% of overall and serious adverse events, respectively. Thus, findings of this meta-analysis support that POEM is a valuable alternative treatment option for esophageal diverticula, and seems to provide equal if not better outcomes with supposed shorter hospital stay and lower rates of complications compared to standard endoscopic techniques.

ZD is commonly treated through flexible endoscopy diverticulotomy. In a recent meta-analysis, flexible endoscopic treatment had a favorable pooled success rate of 91% in ZD patients²⁸. However, recurrence rate following flexible endoscopic diverticulotomy was 11.3% and adverse event rate was 11%, both higher than that reported with Z-POEM²⁸. Results of our meta-analysis seem considerably more favorable in particular in terms of

decreased recurrence rates while adverse events, although with a similar rate as in standard procedures, were mainly mild with no serious impact on patient outcomes.

Several approaches and techniques have been suggested for POEM. The endoluminal functional lumen imaging probe (EndoFLIP) was devised as a method for evaluating the pathogenesis and distensibility of the EGJ. EGJ distensibility can be expressed as the distensibility index (DI) and represents the degree of impaired LES relaxation.²⁹ During POEM, some endoscopist uses EndoFLIP as a means to acquiring information on the efficacy of the intervention.³⁰ Yoo et al. reported that posttreatment DI by EndoFLIP was useful for predicting POEM clinical outcomes in patients with achalasia.³¹ However, while Endoflip technology shows promise, there remains debate on the most appropriate timing for using Endoflip (i.e. follow-up) as well as the selection of appropriate patients; as a result more research is needed.^{29,30} Less is known regarding the use of EndoFLIP in patients with esophageal diverticula.

Optical coherence tomography (OCT) is another emerging technique used by endoscopists during POEM. Desai et al. evaluated the utility of OCT in providing pre-POEM esophageal information such as the degree of vascularity and thickness of the circular muscular layer.³² Using this data, an approach such as anterior or posterior myotomy could be undertaken. To this end, the authors enrolled 84 patients of which 51 patients underwent pre-POEM OCT. Using OCT esophageal data, 24 (47 %) of patients underwent anterior POEM while 27 (53 %) underwent posterior POEM. Technical success was achieved in 96 % of patients. The authors also noted that there were significantly less bleeding in patients who had OCT vs those who did not [4 (8 %) vs. 14 (43 %), $p = 0.0001$]. Procedure was also significantly less in the OCT group compared with controls (85.8 vs. 121.7 min, $p = 0.000097$). While OCT shows promising results, this technology is less available to endoscopists and studies are very sparse to make any concrete recommendations.

POEM consists of 4 consecutive steps: (1) mucosal incision for entry into the submucosa, (2) submucosal tunneling, (3) myotomy, and (4) closure of the mucosal entry. Prior to the procedure, a high-definition gastroscope is commonly fitted with a cap to aid in scarping off residual and adherent tissue on the esophageal mucosa. Anecdotal reports suggest securing the cap on the endoscope tip with tape to avoid dislodging the cap within the submucosal tunnel.³³

While myotomy remains the core procedure for POEM, there are debatable concerns regarding the optimal orientation, depth, and length in performing a myotomy. For achalasia types I or II, a 6–8-cm-long myotomy is generally recommended, while a longer myotomy is recommended for type III achalasia.³⁴ Previously, Wang et al. reported 46 achalasia patients who received short myotomy (mean, 5.4 cm) which showed excellent short-term (3 months) outcomes.³⁵ Recently, Nabi et al reported a randomized trial comparing outcomes of short (3 cm, $n = 34$) versus long (6 cm and above, $n = 37$) esophageal myotomy in patients undergoing POEM for type I and II achalasia.³⁶ Clinical success was comparable in both groups at 1 year. The mean operative time was shorter in the short myotomy group than in the long myotomy group (44.03 ± 13.78 and 72.43 ± 27.28 minutes, respectively; $P < 0.001$). No difference in adverse events was observed between both groups. Overall, the

results indicate that a long esophageal myotomy was not superior to short myotomy for type I and II achalasia patients.

This technique has been adopted for treating esophageal diverticula which is essentially a septotomy of the diverticulum using the POEM technique. The technique reveals the septal wall following submucosal tunneling which is completely dissected to the base of the diverticula while the myotomy is extended about 1 cm proximally.³⁷ In cases of esophageal outflow obstruction, the myotomy is extended about 2 to 3 cm beyond the gastroesophageal junction to allow complete dissection of the lower esophageal sphincter.³⁷ Finally, clips are applied to close the mucosal entry site.

Different cutting devices are available and used by endoscopists depending on their training and experience such as needle-knife, hook-knife, monopolar forceps, argon plasma coagulation.³⁸ The most frequently used device is the hook knife and the needle knife (Olympus medical, Tokyo, Japan).³⁸ While variations exist among endoscopic technique, there are no randomized control trials.

The POEM procedure can be performed via a so-called “anterior” approach or “posterior” approach. Anterior myotomy involves performing POEM at the 1- to 2-o’clock position with patients in the supine position; posterior myotomy is performed at the 5- to 6-o’clock position.^{39,40} Theoretically, anterior myotomy may reduce the risk of damage to the angle of His and the sling muscle fibers located over the greater curvature, which support the natural antireflux mechanism.^{39,40} The posterior approach, on the other hand, may allow for superior alignment of the endoscopic tools used to perform the myotomy, as the working channel for most endoscopes is located over the 5- or 7-o’clock position.^{39,40} The posterior myotomy approach may risk damage to the sling muscles that are located around the 8-o’clock area and thereby disrupt the natural antireflux mechanism.^{39,40} A recent meta-analysis of 1247 patients from 18 studies (623 patients (11 cohorts) treated via anterior myotomy and 624 patients (12 cohorts) treated via posterior myotomy) demonstrated comparable outcomes in terms of clinical success, GERD, and adverse events.⁴¹ However, total procedure time with posterior myotomy is shorter than with anterior myotomy.

Selective circular myotomy or full-thickness myotomy could also be performed during the procedure.⁴² For selective myotomy, it is more technically difficult than full-thickness myotomy with longer learning curves.⁴³ The increase in operation time for patients with selective myotomy also leads to increased risk in severe gas-related complications.⁴³ Li et al. retrospectively reported a series of 234 patients who underwent full thickness myotomy (n=103) and selective inner circular myotomy (n=131).⁴⁴ No significant difference was noted in regards to clinical reflux, treatment scores or LES pressures between both groups. Full thickness myotomy was associated with a shorter procedure time. Similar findings have been noted in other reports.⁴⁵ Additionally, based on an international survey of endoscopist who perform POEM, some operators are still in favor of selective myotomy.⁴⁶

Epiphrenic diverticula are traditionally repaired through a laparoscopic thoracotomy approach. Prior meta-analysis reports an efficacy rate of 88.5% of surgical treatment of epiphrenic diverticula, which is lower than the pooled efficacy rate of 94.2% in this meta-

analysis of POEM for epiphrenic diverticula.⁴⁷ Moreover, the prior meta-analysis reported a staggering 21% morbidity rate following surgical treatment of epiphrenic diverticula.⁴⁷ Therefore, surgical epiphrenic diverticulectomy is a challenging procedure with long operation time and high postoperative complication rates; in this context, an effective and safe endoscopic approach such as POEM could represent a valuable option in this setting although head-to-head series directly comparing surgical versus endoscopic treatment are lacking and it would be probably very difficult to conduct such a study in the clinical scenario.

Post-op care for POEM varies according to institutional practice. Post-operatively patients are usually given fluids and progress to soft foods within 24 hours. Some centers perform a contrast swallow study but this test is not often performed unless concerns for mucosal breach are present.⁴⁸ However, other endoscopists recommend a swallow study with fluoroscopy in spite of any clinical symptoms.⁴⁹ Diet is advanced to soft following 48 hours and continued for 10 to 14 days before regular foods can be consumed.⁴⁹

Additionally, some operators recommend a course of intravenous antibiotics which is stopped on post-op day 3 while oral antibiotics is continue for a total of 7 days.⁴⁹ However, Maselli et al. conducted a very recent randomized clinical trial comparing single dose versus short course of antibiotics in patients undergoing POEM.⁵⁰ The study reported that a single dose of a cefazolin-based prophylaxis without the need for prolonged antibiotic exposure was sufficient for patients undergoing POEM procedures due to a very low residual infectivity risk.

There are certain limitations to this study. First, the low number of included studies and enrolled patients requires particular caution in interpreting our findings, in particular concerning patients with epiphrenic diverticula. However, we deliberately decided to restrict inclusion criteria to series with at least 5 patients, thus excluding small case reports, to provide more robust and homogenous outcome estimates. Second, the very limited number of comparative studies and the lack of randomized trials did not enable us to conduct a direct comparison between POEM and flexible endoscopic techniques.

Third, evaluation of long-term (beyond 2 years) outcomes and the assessment of other potential complications of POEM, such as the incidence of gastro-esophageal reflux disease (GERD) in the case of epiphrenic diverticula, were not feasible due to the lack of available data. Fourth, techniques used in the included studies were not homogeneous with some differences (Z-POEM versus POES in Zenker's diverticula patients and POEM + septotomy versus POEM alone in epiphrenic diverticula patients). However, multiple sensitivity analyses considering these technical features were performed, confirming the results of the main analysis. Finally, economic considerations and assumptions on the impact of POEM were beyond the scope of the study. These limitations highlight the opportunity for future work in this field including well designed head-to-head trials to compare POEM to standard techniques.

Furthermore, we fully acknowledge the recent publication of two meta-analyses in this field.^{51,52} However, these studies had significant limitations which we overcame, thus

making our analysis novel and of interest. The meta-analysis by Kamal et al included only 7 studies (of which only 5 published as full text papers) whereas our analysis includes 12 studies with nearly double the number of patients.⁵¹ Moreover, Kamal et al did not perform an analysis at different time points so the kinetics and magnitude of patient response over time could not be assessed. Additionally, meta-regression analysis of main potential confounders was not performed. We think that these aspects were adequately considered in our manuscript (including meta-regression) and constitute important sources of novelty. The other meta-analysis by Ren et al. although being conducted with a more rigorous approach, also did not report specific time points or subclassification according to type of diverticula.⁵² These are two important limitations completely expanded in our analysis.

In conclusion, this meta-analysis highlights that POEM is a safe and effective technique in patients with esophageal diverticula, including both ZD and epiphrenic diverticula. These data seem similarly effective to standard surgical and flexible endoscopic techniques, but with lower complication rates with POEM. Therefore, patients with esophageal diverticula should be offered a POEM approach among standard techniques, if the appropriate expertise is available.

Supplementary Material

Refer to Web version on PubMed Central for supplementary material.

Acknowledgments

Disclosures:

AF, YI, VA: None

MAK: Consultant for BSCI, Medtronic, Olympus and GI Supply.

RY: Consultant: Medtronic, Ironwood Pharmaceuticals, Diversatek; Research support: Ironwood Pharmaceuticals; Advisory Board: Phatom Pharmaceuticals

SW: Consultant for Boston Scientific, Medtronic, Interpace, Cernostics. Supported by the Department of Medicine Outstanding Early Scholars Program

References:

1. Sato H, Takeuchi M, Hashimoto S, et al. Esophageal diverticulum: New perspectives in the era of minimally invasive endoscopic treatment. *World J Gastroenterol.* 2019;25(12):1457–64. [PubMed: 30948909]
2. Herbella FA, Patti MG. Modern pathophysiology and treatment of esophageal diverticula. *Langenbeck Arch Surg* 2012; 397: 29–35
3. Zaninotto G, Portale G, Costantini M, et al. Therapeutic strategies for epiphrenic diverticula: systematic review. *World J Surg* 2011;35(7):1447–53 [PubMed: 21541802]
4. Sakai P Endoscopic myotomy of Zenker's diverticulum: lessons from 3 decades of experience. *Gastrointest Endosc* 2016; 83: 774–5 [PubMed: 26975283]
5. Li QL, Chen WF, Zhang XC, et al. Submucosal tunneling endoscopic septum division: A novel technique for treating Zenker's diverticulum. *Gastroenterology* 2016; 151: 1071–4 [PubMed: 27664512]

6. Hernandez Mondragon OV, Solorzano Pineda MO, Blancas Valencia JM. Zenker's diverticulum: Submucosal tunneling endoscopic septum division (Z-POEM). *Dig Endosc* 2018; 30:124 [PubMed: 28875504]
7. Costamagna G, Iacopini F, Bizzotto A, et al. Prognostic variables for the clinical success of flexible endoscopic septotomy of Zenker's diverticulum. *Gastrointest Endosc* 2016; 83: 765–73 [PubMed: 26344886]
8. Basile P, Gonzalez JM, Le Mouel JP, et al. Per-oral endoscopic myotomy with septotomy for the treatment of distal esophageal diverticula (D-POEM). *Surg Endosc.* 2020;34(5):2321–5. [PubMed: 32144556]
9. Wells GA, Shea B, O'Connell D, et al. The Newcastle – Ottawa Scale (NOS) for assessing the quality of nonrandomised studies in meta-analyses; available from: http://www.ohri.ca/programs/clinical_epidemiology/oxford.htm, accessed on August 2020.
10. Eckardt VF. Clinical presentations and complications of achalasia. *Gastrointest Endosc Clin N Am.* 2001;11(2):281–vi. [PubMed: 11319062]
11. Demeter M, Uri ek M, Vor ák M, et al. S-POEM in treatment of achalasia and esophageal epiphrenic diverticula - single center experience. *Scand J Gastroenterol.* 2020;55(4):509–14. [PubMed: 32251609]
12. Li X, Zhang W, Yang J, et al. Safety and efficacy of submucosal tunneling endoscopic septum division for epiphrenic diverticula. *Endoscopy.* 2019;51(12):1141–5. [PubMed: 31634922]
13. Dakkak M, Bennett JR. A new dysphagia score with objective validation. *J Clin Gastroenterol* 1992; 14: 99–100 [PubMed: 1556441]
14. Al Ghamdi SS, Farha J, Meybodi MA, et al. International multicenter study comparing Z-POEM and flexible/rigid endoscopic Zenker's diverticulotomy. *Gastrointest Endosc* 2020;91(6):AB3–4.
15. Yang J, Zeng X, Yuan X, et al. An international study on the use of peroral endoscopic myotomy (POEM) in the management of esophageal diverticula: the first multicenter D-POEM experience. *Endoscopy.* 2019;51(4):346–9. [PubMed: 30453378]
16. Yang J, Novak S, Ujiki M, et al. An international study on the use of peroral endoscopic myotomy in the management of Zenker's diverticulum. *Gastrointest Endosc.* 2020;91(1):163–8. [PubMed: 31082393]
17. Repici A, Spadaccini M, Belletrutti PJ, et al. Peroral endoscopic septotomy for short-septum Zenker's diverticulum. *Endoscopy.* 2020;52(7):563–8. [PubMed: 32185781]
18. Sanaei O, Ichkhanian Y, Hernandez Mondragon OV, et al. Impact of Prior treatment on Feasibility and Outcomes of Zenker's PerOral Endoscopic Myotomy (Z-POEM). *Endoscopy* 2020, in press.
19. Klingler MJ, Landreneau JP, Strong AT, et al. Endoscopic mucosal incision and muscle interruption (MIMI) for the treatment of Zenker's diverticulum. *Surg Endosc* 2020, in press.
20. Aslan F, Yilmaz O, Sengun B, et al. A new technique in treatment of Zenker diverticulum: submucosal tunnelling endoscopic septum division (Z-POEM) versus classic endoscopic septomyotomy techniques. *Gastrointest Endosc* 2019;89(6S):AB629.
21. Desai PN, Kabrawala MV. Submucosal tunnelling endoscopic septum division for Zenker's diverticulum (Z POEM): a new emerging technique compared to conventional endoscopic septotomy. *Gastrointest Endosc* 2019;89(6S):AB450.
22. Kinoshita M, Tanaka S, Kawara F, et al. Peroral endoscopic myotomy alone is effective for esophageal motility disorders and esophageal epiphrenic diverticulum: a retrospective single-center study. *Surg Endosc* 2020, in press.
23. Facciorusso A, Di Maso M, Muscatiello N. Drug-eluting beads versus conventional chemoembolization for the treatment of unresectable hepatocellular carcinoma: A meta-analysis. *Dig Liver Dis.* 2016;48(6):571–7. [PubMed: 26965785]
24. <http://cran.r-project.org/web/packages/metafor/index.html> [accessed August 2020].
25. Facciorusso A, Singh S, Abbas Fehmi SM, et al. Comparative efficacy of first-line therapeutic interventions for achalasia: a systematic review and network meta-analysis. *Surg Endosc.* 2020, in press.
26. Kamal F, Khan MA, Lee-Smith W, et al. Peroral Endoscopic Myotomy Is a Safe and Feasible Option in Management of Esophageal Diverticula: Systematic Review and Meta-Analysis. *Dig Dis Sci.* 2020, in press.

27. Ren L, Xie W, Mulmi Shrestha S, et al. Peroral ceroral endoscopic myotomy treatment for symptomatic esophageal diverticulum: a systematic review and meta-analysis. *Eur J Gastroenterol Hepatol.* 2020, in press.
28. Ishaq S, Hassan C, Antonello A, et al. Flexible endoscopic treatment for Zenker's diverticulum: a systematic review and meta-analysis. *Gastrointest Endosc.* 2016;83(6):1076–89. [PubMed: 26802196]
29. Kim GH. Is EndoFLIP Useful for Predicting Clinical Outcomes after Peroral Endoscopic Myotomy in Patients with Achalasia?. *Gut liver.* 2019;13(1):3. [PubMed: 30665277]
30. Weusten BL, Barret M, Bredenoord AJ, et al. Endoscopic management of gastrointestinal motility disorders—part 1: European Society of Gastrointestinal Endoscopy (ESGE) Guideline. *Endoscopy.* 2020;52(06):498–515. [PubMed: 32375192]
31. Yoo IK, Choi SA, Kim WH, et al. Assessment of clinical outcomes after peroral endoscopic myotomy via esophageal distensibility measurements with the endoluminal functional lumen imaging probe. *Gut Liver.* 2019;13:32–39 [PubMed: 30400727]
32. Desai AP, Tyberg A, Kedia P, et al. Optical coherence tomography (OCT) prior to peroral endoscopic myotomy (POEM) reduces procedural time and bleeding: a multicenter international collaborative study. *Surg Endosc.* 2016;30(11):5126–33. [PubMed: 27059973]
33. Kumbhari V, Khashab MA. Peroral endoscopic myotomy. *World J Gastrointest Endosc.* 2015;7(5):496–509. [PubMed: 25992188]
34. Kane ED, Budhbra V, Desilets DJ, Romanelli JR. Myotomy length informed by high-resolution esophageal manometry (HREM) results in improved per-oral endoscopic myotomy (POEM) outcomes for type III achalasia. *Surg Endosc.* 2019;33:886–894 [PubMed: 30054739]
35. Wang J, Tan N, Xiao Y, et al. Safety and efficacy of the modified peroral endoscopic myotomy with shorter myotomy for achalasia patients: a prospective study. *Dis Esophagus.* 2015;28:720–727 [PubMed: 25214469]
36. Nabi Z, Ramchandani M, Sayyed M, et al. Comparison of short versus long esophageal myotomy in cases with idiopathic achalasia: a randomized controlled trial. *J Neurogastroenterol Motil.* 2021;27:63–70. [PubMed: 32675389]
37. Miutescu BP, Khan S, Mony S, Khashab MA. Role of Peroral Endoscopic Myotomy (POEM) in the Management of Esophageal Diverticula. *Clin Endosc.* 2020;53(6):646–651. [PubMed: 33238358]
38. Maselli R, Spadaccini M, Cappello A, et al. Flexible endoscopic treatment for Zenker's diverticulum: from the lumen to the third space. *Ann Gastroenterol.* 2021;34(2):149. [PubMed: 33654352]
39. Inoue H, Minami H, Kobayashi Y et al. Peroral endoscopic myotomy (POEM) for esophageal achalasia. *Endoscopy* 2010; 42: 265–271 [PubMed: 20354937]
40. Ren Z, Zhong Y, Zhou P et al. Perioperative management and treatment for complications during and after peroral endoscopic myotomy (POEM) for esophageal achalasia (EA) (data from 119 cases). *Surg Endosc* 2012; 26: 3267–3272 [PubMed: 22609984]
41. Mohan BP, Ofosu A, Chandan S, et al. Anterior versus posterior approach in peroral endoscopic myotomy (POEM): a systematic review and meta-analysis. *Endoscopy.* 2020;52(04):251–8. [PubMed: 31958861]
42. Bechara R, Ikeda H, Inoue H. Peroral endoscopic myotomy: an evolving treatment for achalasia. *Nat Rev Gastroenterol Hepatol.* 2015;12(7):410–26. [PubMed: 26035678]
43. Liu X, Yao L, Cheng J, et al. Landscape of Adverse Events Related to Peroral Endoscopic Myotomy in 3135 Patients and a Risk-Scoring System to Predict Major Adverse Events. *Clin Gastroenterol Hepatol.* 2021;S1542–3565(21)00467–5
44. Li QL, Chen WF, Zhou PH, et al. Peroral endoscopic myotomy for the treatment of achalasia: a clinical comparative study of endoscopic full-thickness and circular muscle myotomy. *J Am Coll Surg* 2013;217(3):442–51. [PubMed: 23891074]
45. Li C, Gong A, Zhang J, et al. Clinical outcomes and safety of partial full-thickness myotomy versus circular muscle myotomy in peroral endoscopic myotomy for achalasia patients *Gastroenterol Res Prac.* 2017;2017:2676513

46. Stavropoulos SN, Modayil RJ, Friedel D, Savides T. The international per oral endoscopic myotomy survey (IPOEMS): a snapshot of the global POEM experience. *Surg Endosc.* 2013;27(9):3322–38. [PubMed: 23549760]
47. Chan DSY, Foliaki A, Lewis WG, et al. Systematic Review and Meta-analysis of Surgical Treatment of Non-Zenker's Oesophageal Diverticula. *J Gastrointest Surg.* 2017;21(6):1067–1075. [PubMed: 28108931]
48. Crosthwaite GL, Sejka M. Per-oral endoscopic myotomy (POEM): overview and experience of 100 cases by a single surgeon in Australia. *Ann Esophagus* 2020;3:12.
49. Ahmed Y, Othman MO. Peroral endoscopic myotomy (POEM) for achalasia. *J Thorac Dis.* 2019 Aug;11(Suppl 12):S1618–S1628. [PubMed: 31489229]
50. Maselli R, Oliva A, Badalamenti M, Galtieri PA, et al. Single-dose versus short-course prophylactic antibiotics for peroral endoscopic myotomy: a randomized controlled trial. *Gastrointest Endosc.* 2021 Jun 10:S0016–5107(21)01418–8. doi: 10.1016/j.gie.2021.05.045. Epub ahead of print.
51. Kamal F, Khan MA, Lee-Smith W, et al. Peroral Endoscopic Myotomy Is a Safe and Feasible Option in Management of Esophageal Diverticula: Systematic Review and Meta-Analysis. *Dig Dis Sci.* 2020, doi: 10.1007/s10620-020-06678-5. Epub ahead of print.
52. Ren L, Xie W, Mulmi Shrestha S, et al. Peroral ceroral endoscopic myotomy treatment for symptomatic esophageal diverticulum: a systematic review and meta-analysis. *Eur J Gastroenterol Hepatol.* 2020, doi: 10.1097/MEG.0000000000002001. Epub ahead of print

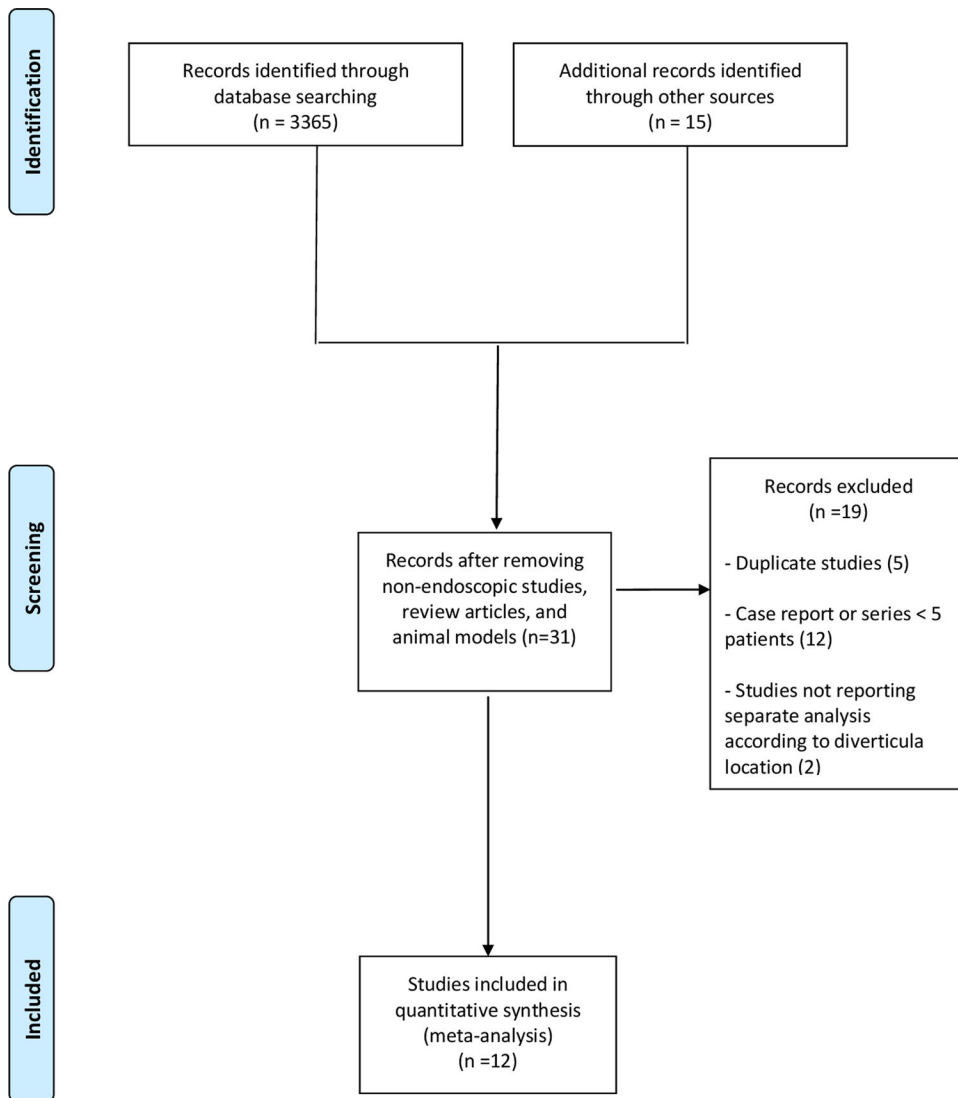


Figure 1.
Flow chart of the included studies

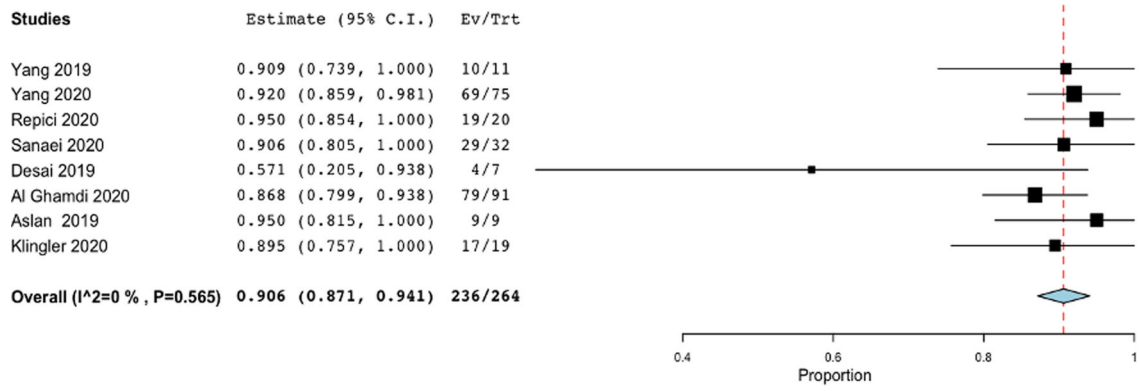


Figure 2. Pooled analysis of treatment success with POEM in patients with Zenker’s diverticula. Pooled rate of treatment success with POEM in patients with Zenker’s diverticula was 90.6% (87.1%–94.1%), with no evidence of heterogeneity ($I^2=0\%$).

Author Manuscript

Author Manuscript

Author Manuscript

Author Manuscript

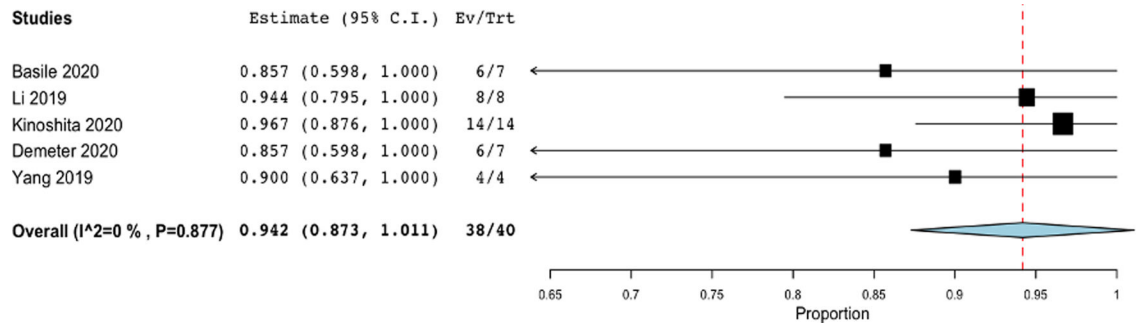


Figure 3. Pooled analysis of treatment success with POEM in patients with epiphrenic diverticula.

Pooled rate of treatment success with POEM in patients with epiphrenic diverticula was 94.2% (87.3%–100%), with no evidence of heterogeneity ($I^2=0\%$).

Table 1.

Characteristics of included studies

Study	Country; study period	Sample size; Diverticulum location	Control group (sample size)	Age years	Gender male	Diverticular size (cm)	Symptoms; baseline score	Prior treatments	Technique; sedation	Definition of treatment success; timing of assessment
Al Ghamdi 2020 ^{14,d}	USA/France/Romania/Mexico; 2016–2019	91; Zenker	Flexible and rigid endoscopic septomyotomy (67)	71	86 (54.4%)	3	Dysphagia in 63% regurgitation in 34%; Dakkak and Bennett: 1.7±0.9	No	Z-POEM; NR	Dakkak and Bennett 1; 3 months
Aslan 2019 ^{20,d}	Turkey; 2015–2018	9; Zenker	Flexible endoscopic septomyotomy (20)	NR	NR	NR	NR	No	Z-POEM; NR	NR
Basile 2020 ⁸	France; 2017–2018	7; Epiphrenic	No	From 62 to 90	3 (42.8%)	NR	all pts dysphagia, 3 pts retrosternal pain, 4 regurgitation, 1 dyspnea, 5 weight loss; NR	2 pts (28.5%) POEM; 1 pt (14.2%) botulin injection	POEM + diverticular septotomy; general anaesthesia	Complete or partial regression of dysphagia; 3 months
Demeter 2020 ¹	Slovakia; 2015–2018	7; Epiphrenic	No	67 (43–77)	3 (42.8%)	6.07±2	Regurgitation the most common, dysphagia and pain; Eckardt: 6.6 (5–9)	PD in 1 patient, surgical diverticulectomy in 1 patient	POEM; general anaesthesia	Eckardt score <3; 3 months and 2 years
Desai 2019 ^{21,d}	India; 2013–2018	7; Zenker	Flexible endoscopic septomyotomy (8)	71.4 (67–81)	9 (60%)	NR	Dysphagia in 78.6%; NR	No	Z-POEM; NR	NR; 18 months
Kinoshita 2020 ²²	Japan; 2015–2018	14; Epiphrenic	No	72.5 (46–85)	8 (57.1%)	2.65 (0.9–9)	NR; Eckardt: 5 (3–11)	PD in 3 pts (21.4%)	POEM; general anaesthesia	NR; 3 months and 1 year
Klingler 2020 ¹⁹	USA; 2015–2020	19; Zenker	Flexible endoscopic septomyotomy (7)	75 (72.5–82)	13 (68.4%)	2.6 (2–3.85)	Dysphagia in 100%, Regurgitation in 52.9%, Aspiration in 21%; Dakkak and Bennett 1.74±0.87	No	Z-POEM; general anaesthesia	Dakkak and Bennett 1; 2 years
Li 2019 ¹²	China; 2016–2017	8; Epiphrenic	No	66.25±7.17	5 (62.5%)	From 2.5 to 6.9	NR; Eckardt: 6.88±3.04	No	POEM + diverticular septotomy; deep sedation	Eckardt score <3; 1 year

Study	Country; study period	Sample size; Diverticulum location	Control group (sample size)	Age years	Gender male	Diverticular size (cm)	Symptoms; baseline score	Prior treatments	Technique; sedation	Definition of treatment success; timing of assessment
Yang 2019 ¹⁵	USA/China; 2014–2017	11; 7 pts Zenker; 1 mid and 3 epiphrenic	No	76.2±11.7	4 (36.3%)	3.45±1.65	dysphagia in 9 pts (81.8%), regurgitation in 2 pts (18.2%); Dakkak and Bennet: 2.7	Surgery in 1 pt (9%) with Zenker's diverticulum	Z-POEM in patients with Zenker's diverticula and POEM+diverticular septotomy in patients with epiphrenic diverticular; general anaesthesia	Dakkak and Bennet 1; 3 months
Yang 2020 ¹⁶	Multicenter; 2014–2018	75; Zenker	No	73.3±1.2	42 (56%)	3.13±0.16	dysphagia in all pts, regurgitation in 37 pts (49.3%); Dakkak and Bennet: 1.96±0.68	Surgery in 5 pts (6.7%), endoscopic septotomy in 6 pts (8%)	Z-POEM; general anaesthesia	Dakkak and Bennet 1; 2 years
Repici 2020 ^{17*}	Italy; 2017–2019	20; short-septum Zenker	No	67.9±14.3	12 (60%)	1.75	dysphagia in all pts, regurgitation in 12 pts (60%); Dakkak and Bennet: 2.7±0.5	No	POES; deep sedation	Dakkak and Bennet 1; 1 year
Sanaei 2020 ¹⁸	USA/India; Romania; Mexico; 2015–2019	32; Zenker	No	72±11.4	19 (59.4%)	2.94 (1–6.5)	dysphagia in all pts, regurgitation in 17 pts (53.1%); Dakkak and Bennet: 2 (1–2)	100%: surgery in 10 pts (31.3%), rigid endoscopy in 9 pts (28.1%), flexible endoscopy in 13 pts (40.6%), Z-POEM in 3 pts (9.4%), botulin injection in 1 pt (3.1%)	Z-POEM in 28 pts (87.5%); hybrid in 2 pts (6.25%); standard septotomy in 2 pts who failed Z-POEM; general anaesthesia	Dakkak and Bennet 1; 6 months

Data are reported as absolute numbers (percentages) or mean (± standard deviation or with range)

^aStudy published as conference abstract

* Prospective study

Abbreviations: NR, Not Reported; PD, Pneumatic Dilation; POEM, Per-Oral Endoscopic Myotomy; POES, Per-Oral Endoscopic Septotomy.

Subgroup analysis of treatment success in patients with Zenker’s diverticula. Subgroup analysis was performed based on timing of response assessment (3 months versus 1 year versus 2 years).

Table 2.

Variable	Subgroup	No. of Cohorts	No. of patients	Summary Estimate (95% CI)	Within-group heterogeneity (I ²)
Treatment success					
Timing of assessment	3 months	5	130	90.6% (85.7%–95.5%)	0%
	1 year	4	72	90% (86.4%–97.4%)	0%
	2 years	3	101	89.6% (82.2%–96.9%)	15.7%

Abbreviation: CI, Confidence Interval.

Other outcomes reported stratified according to diverticulum location (Zenker's versus epiphrenic)

Table 3.

Outcome	Subgroup	No. of Cohorts	No. of patients	Summary Estimate (95% CI)	Within-group heterogeneity (I ²)
Technical success	Zenker's	8	260	95.9% (93.4%–98.3%)	0%
	Epiphrenic	5	40	95.1% (88.8%–100%)	0%
Symptoms recurrence	Zenker's	8	260	2.6% (0.9%–4.4%)	0%
	Epiphrenic	5	40	0%	0%
Adverse events	Zenker's	8	260	10.6% (4.6%–16.6%)	47.2%
	Epiphrenic	5	40	8.4% (0%–16.8%)	0%
Severe adverse events	Zenker's	8	260	3.5% (0%–7.4%)	62.3%
	Epiphrenic	5	40	8.4% (0.1%–16.8%)	0%
Procedure time	Zenker's	7	233	44.7 min (30.03–59.4)	45%
	Epiphrenic	2	33	61.7 min (38.4–84.9)	41%
Length of hospital stay	Zenker's	7	233	1.23 days (1–1.4)	48%
	Epiphrenic	2	33	5.6 days (4.8–6.4)	44.3%

Abbreviation: CI, Confidence Interval.