

UC Davis
Orthopaedic Surgery

Title

Retrospective Comparison of Two Posterior Spinal Decompression Procedures for Cervical Spondylotic Myelopathy

Permalink

<https://escholarship.org/uc/item/5wq3s3h8>

Authors

Baker, Sammy
Roberto, Rolando

Publication Date

2021

Data Availability

The data associated with this publication are not available for this reason: N/A

Retrospective Comparison of Two Posterior Spinal Decompression Procedures for Cervical Spondylotic Myelopathy

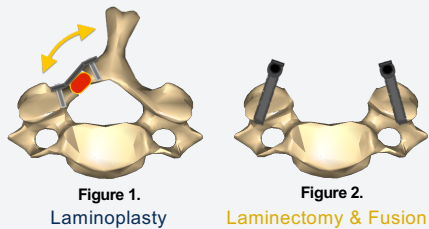
Department of Orthopaedic Surgery

Sammy Baker, M.S.
Rolando F. Roberto, M.D.

Background | Methods

Are laminoplasty and laminectomy & fusion equally effective treatments for CSM?

Does laminoplasty lead to increased axial neck pain?



144 Total Procedures

Follow-up length: 12-16 months (average)

80 Laminoplasty

64 Laminectomy & Fusion

Surgical Invasiveness
Hospital Stay Mobility Discharge
Complications
Opioid Requirements
Patient-Reported Scales Function, Pain (presented here)
Radiographic Measurements
Costs Analysis

Results

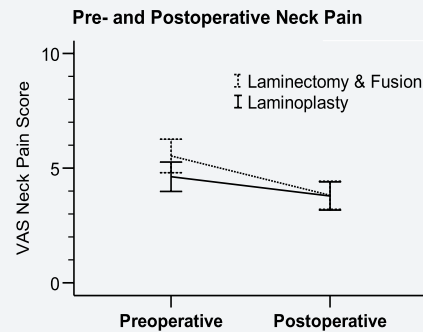


Figure 3. Patients reported neck pain using a 0-10 Visual Analog Scale (VAS). Error bars represent 95% confidence intervals.

- The average neck pain reported during the postoperative period (12-16 months) was significantly below preoperative levels in both groups (paired t-tests).
- Laminectomy & fusion group: pain decreased from 5.53 ± 0.37 to 3.82 ± 0.31 , Cohen's $d = 0.745$
- Laminoplasty group: pain decreased from 4.63 ± 0.32 to 3.78 ± 0.31 , $p = .003$, Cohen's $d = 0.345$.

Effect of Surgery Size on Change to Neck Pain

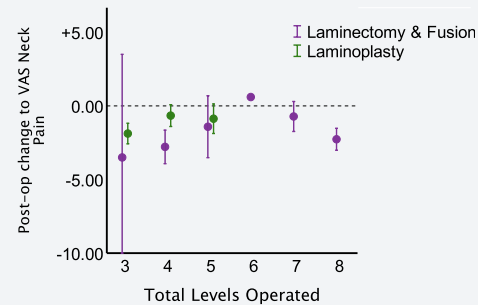


Figure 4. The mean change in reported neck pain following surgery was plotted as a function of the total operative (vertebral) levels. Error bars represent 95% confidence intervals. No laminoplasty procedures were performed at 6 or more levels.

- There was no statistical difference in change to neck pain between treatment groups when 3, 4, or 5 vertebral levels were involved (unpaired t-tests, $p > .05$).

Conclusions

Both surgeries significantly improved neck pain.

For procedures involving 3-5 levels, both techniques improve pain similarly.

When C7 is involved, laminectomy and fusion may be more beneficial for reducing pain.

Laminoplasty is not associated with a greater incidence rate of new onset neck pain.

Radiographic, opioid data may help identify other differences relating to pain.

Abstract



References

Figures 1 and 2. Images of cervical vertebrae adapted and altered by Sammy Baker from www.anatomography.com under CC BY-SA 2.1 JP.