

# UCSF

## UC San Francisco Previously Published Works

### Title

Atypical Valsalva retinopathy from habitual ear popping

### Permalink

<https://escholarship.org/uc/item/5x12b666>

### Authors

Liu, Yingna

Haq, Zeeshan

Stewart, Jay M


### Publication Date

2020-09-01

### DOI

10.1016/j.ajoc.2020.100785

Peer reviewed



# Atypical Valsalva retinopathy from habitual ear popping

Yingna Liu, Zeeshan Haq, Jay M. Stewart \*

Department of Ophthalmology, University of California San Francisco, San Francisco, CA, USA

## ARTICLE INFO

### Keywords:

Valsalva retinopathy  
Retinal hemorrhages  
Ear popping  
Eustachian tube dysfunction

## ABSTRACT

**Purpose:** To report a unique case of Valsalva retinopathy associated with ear popping behavior.

**Observations:** A 57-year-old woman with a history of well-controlled hypertension presented with episodes of seeing “spots” in her left eye for many years. Her most recent episode failed to resolve spontaneously. Fundus examination revealed scattered retinal hemorrhages in the left eye, and optical coherence tomography demonstrated sub-internal limiting membrane location of these hemorrhages. Fluorescein angiography did not reveal any vascular abnormalities. Based on these findings and an in-depth review of systems, a diagnosis of Valsalva retinopathy was made associated with patient’s ear popping habit.

**Conclusions and importance:** Habitual ear popping can be a potential etiology of symptomatic Valsalva retinopathy. This under-appreciated association may be clinically relevant for patients with a history of suspected Eustachian tube narrowing or dysfunction.

## 1. Introduction

Valsalva retinopathy is a well-known yet uncommon condition that presents with acute onset unilateral, or less commonly bilateral, superficial retinal hemorrhages in individuals with a plausible trigger. While the diagnosis is frequently apparent in cases with a dramatic presentation, the fundus appearance can mimic many other diagnoses in milder cases. Herein, we report an unusual case of Valsalva retinopathy that presented with diffuse unilateral retinal hemorrhages presumably secondary to ear popping behavior in the setting of suspected Eustachian tube dysfunction.

## 2. Case report

A 57-year-old woman was referred to the retina clinic for evaluation of new retinal hemorrhages in the left eye. She was previously evaluated at an outside hospital 1 week prior for acute onset “spots” in her left eye. These episodic “spots” had occurred for many years and typically resolved in a matter of hours. However, her most recent episode did not resolve spontaneously, so she presented to the emergency department. Due to concern for a stroke, she was admitted and underwent a full workup including neuroimaging, carotid doppler ultrasound, and cardiac echocardiogram, all of which were unremarkable. The patient was discharged from the emergency department with a plan to follow up with her regular optometrist, who, after examination, diagnosed her

with central retinal vein occlusion and referred her to the retina service for further management. The patient’s medical history was notable for hypertension and hyperlipidemia, both of which were well-controlled on oral medications. She had no history of diabetes mellitus, smoking, obesity or other cardiovascular comorbidities.

On ophthalmic examination, Snellen visual acuity was 20/20 bilaterally. She had normal pupillary responses, intraocular pressures, and extraocular motility. Her anterior segment examination was unremarkable in both eyes. On dilated fundus examination, there were multiple flame-shaped and round retinal hemorrhages in the posterior pole of the left eye (Fig. 1A). Fluorescein angiography demonstrated normal transit times, focal areas of blockage by hemorrhages, and otherwise normal vasculature in both eyes (Fig. 1B). Optical coherence tomography (OCT) was unremarkable in the right eye and demonstrated hyperreflectivity beneath the internal limiting membrane (ILM) layer corresponding to hemorrhages on the near-infrared image in the left eye (Fig. 2).

After obtaining a more in-depth review of systems, the patient disclosed that she “pops” her ears on a regular basis. During these episodes of ear popping, she bears down for a short period of time until she feels a release of pressure in her ears accompanied by a “pop” noise. In addition, she recalled engaging in this habit prior to the onset of her most recent episode of “spots.” Based on this historical information and OCT localization of the retinal hemorrhages to the sub-internal limiting membrane space, a diagnosis of Valsalva retinopathy was made.

\* Corresponding author. University of California, San Francisco, Retina Service 10 Koret Way, San Francisco, CA, 94131, USA.

E-mail address: [Jay.Stewart@ucsf.edu](mailto:Jay.Stewart@ucsf.edu) (J.M. Stewart).

<https://doi.org/10.1016/j.ajoc.2020.100785>

Received 11 April 2020; Received in revised form 2 June 2020; Accepted 5 June 2020

Available online 17 June 2020

2451-9936/© 2020 The Authors.

Published by Elsevier Inc.

This is an open access article under the CC BY-NC-ND license

(<http://creativecommons.org/licenses/by-nc-nd/4.0/>).

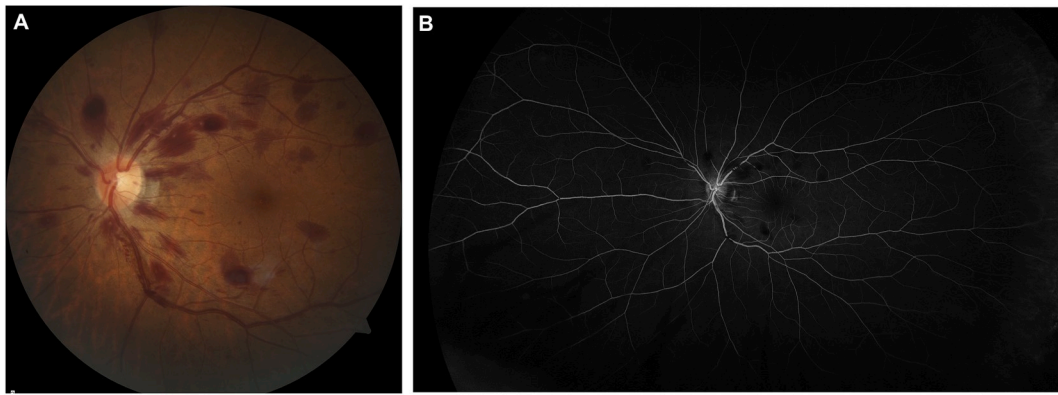


Fig. 1. A. Fundus photograph of the left eye demonstrates multiple flame-shaped and round hemorrhages in the posterior pole. B. Late-phase fluorescein angiogram of the left eye demonstrates blockage by hemorrhages and otherwise normal vasculature in both eyes.

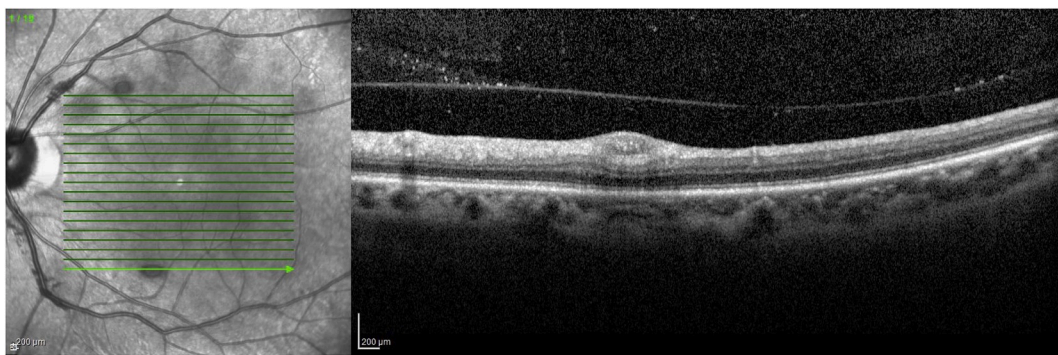


Fig. 2. Optical coherence tomography of the left macula demonstrates hyperreflective lesions immediately deep to the internal limiting membrane layer corresponding to the location of retinal hemorrhages on the near-infrared image.

The patient was informed of her suspected diagnosis and advised to refrain from engaging in her ear popping habit. No other interventions were deemed necessary. At her follow-up visit 3 months later, the patient reported good vision with no “spots.” On examination, there was interval resorption of most of her retinal hemorrhages.

### 3. Discussion

Valsalva retinopathy was first described by Dr. Duane in 1973.<sup>1</sup> It occurs in otherwise healthy individuals due to a rapid rise in intrathoracic or intraabdominal pressure achieved by attempted expiration against a closed upper airway, during strenuous physical activity or the physiologic equivalent of a Valsalva maneuver.<sup>1</sup> It is thought that due to a lack of valves in the venous system, a rapid increase in the systemic venous pressure can be transmitted to the eye with resultant rupture of superficial retinal capillaries. It has been reported following vigorous exercise,<sup>2-4</sup> sexual activity,<sup>5,6</sup> forceful vomiting during pregnancy,<sup>7</sup> balloon blowing,<sup>8</sup> breath-holding during procedures,<sup>9</sup> and other activities that involve bearing down or straining. To our knowledge, this is the first report of Valsalva retinopathy secondary to habitual ear popping behavior in the setting of suspected Eustachian tube dysfunction.

Interestingly, the Valsalva maneuver was first described by Antonio Maria Valsalva as a way of checking the patency of the Eustachian tube through diagnostic “ear popping.”<sup>10,11</sup> In fact, this maneuver is still utilized by some otolaryngologists to evaluate Eustachian tube function at the bedside.<sup>12,13</sup> During the evaluation, patients are asked to bear down while the clinician observes movement of the tympanic membrane as an indication of the patency of Eustachian tube, reminiscent of our patient’s ear popping habit. Therefore, Valsalva retinopathy should be

on the differential diagnosis for patients with a history of suspected Eustachian tube narrowing or dysfunction who present with acute visual complaints.

Retinal hemorrhages in Valsalva retinopathy can occur in any or all retinal layers,<sup>9</sup> but classically localize to the sub-ILM space and, in severe cases, can cause dramatic hemorrhagic detachment of the ILM.<sup>1,2,8</sup> Cases with severe pre-retinal hemorrhages are easily recognized and a diagnosis can often be made clinically in the appropriate clinical context.<sup>3,7,14</sup> On the other hand, milder presentations of this condition exist,<sup>2,8</sup> and are more likely to be under-reported in the literature and possibly under-recognized clinically given vague or mild visual symptoms and spontaneous resolution without visual sequelae, such as in our patient. Indeed, two providers prior to our encounter with the patient failed to reach the diagnosis of Valsalva retinopathy. A correct diagnosis in this setting requires an in-depth review of systems, a thorough ophthalmologic workup to rule out other etiologies, and a systemic workup when appropriate.

The differential diagnosis for unilateral retinal hemorrhages includes many etiologies. The appearance of diffuse retinal hemorrhages in multiple quadrants is reminiscent of CRVO. However, in our patient, the history of multiple self-resolving episodes in the past, lack of vascular tortuosity, and relatively superficial location of the hemorrhages on OCT render this diagnosis less likely. In addition, fluorescein angiography later showed normal transit time and effectively ruled this entity out. Hypertension and diabetes mellitus are more common etiologies for retinal hemorrhages due to microvascular injury and ischemia. However, manifestations of these retinopathies—such as vascular attenuation, intraretinal hemorrhages, cotton wool spots, venous beading, and others—would be expected to be present in both eyes in most cases. In our patient, her fundus examination and fluorescein angiogram did not

demonstrate abnormalities (e.g. microaneurysms, capillary non-perfusion) consistent with these diagnoses. Other less common diagnoses such as leukemic retinopathy and radiation retinopathy should also be considered in the relevant clinical context.

The reason that Valsalva retinopathy is more likely to be unilateral than bilateral is unknown. There is also not a clear preference for the left eye versus the right eye.<sup>8</sup> The involvement of one eye in face of a systemic venous pressure rise could be due to a difference in the vulnerability of retinal capillaries to rupture between the two eyes. As in the case of our patient, the capillary bed of the left eye appeared to be more vulnerable to rupture from pressure rise compared to the right, and it was repeatedly the involved eye. Furthermore, in Valsalva retinopathy, the retinal hemorrhages have a predilection for the posterior pole; this is likely related to a lack of firm attachments of the ILM to the retina immediately peripheral to the fovea.<sup>15</sup> Depending on the exact location and extent of bleeding, visual acuity can range from 20/20 to worse than 20/400. While the majority of patients regain vision after the blood has been spontaneously resorbed, those who have a dense sub-ILM hemorrhage in the central macula or bilateral involvement may benefit from laser<sup>16,17</sup> or surgical interventions<sup>6,18,19</sup> to expedite visual recovery and prevent long-term vision loss. However, these additional interventions are not yet well-studied, and their implementation should be made on a case-by-case basis.

#### 4. Conclusions

In summary, we report a case of Valsalva retinopathy in the setting of habitual ear popping behavior. This under-recognized association may be clinically relevant for patients with a history of Eustachian tube dysfunction. In addition, this case illustrates that, in milder forms of Valsalva retinopathy, a correct diagnosis may be dependent upon a thorough review of systems.

#### Previous presentations

None.

#### Declaration of competing interest

All authors have no disclosures to report.

#### Acknowledgements

The authors would like to acknowledge financial support from

Research to Prevent Blindness and That Man May See, Inc.

#### References

- Duane TD. Valsalva hemorrhagic retinopathy. *Trans Am Ophthalmol Soc.* 1972;70:298–313.
- Pitta CG, Steinert RF, Gragoudas ES, Regan CD. Small unilateral foveal hemorrhages in young adults. *Am J Ophthalmol.* 1980;89(1):96–102. [https://doi.org/10.1016/0002-9394\(80\)90235-4](https://doi.org/10.1016/0002-9394(80)90235-4).
- Hassan M, Tajunisah I. Valsalva haemorrhagic retinopathy after push-ups. *Lancet.* 2011;377(9764):504. [https://doi.org/10.1016/S0140-6736\(10\)60677-0](https://doi.org/10.1016/S0140-6736(10)60677-0).
- Xie Z, Yu S, Chen X, Zhu J, Chen F. Macular hole secondary to Valsalva retinopathy after doing push-up exercise. *BMC Ophthalmol.* 2014;14:98. <https://doi.org/10.1186/1471-2415-14-98>.
- Friberg TR, Braunstein RA, Bressler NM. Sudden visual loss associated with sexual activity. *Arch Ophthalmol Chic Ill.* 1960;113(6):738–742. <https://doi.org/10.1001/archophth.1995.01100060064033>, 1995.
- Al Rubaie K, Arevalo JF. Valsalva retinopathy associated with sexual activity. *Case Rep Med.* 2014;2014:524286. <https://doi.org/10.1155/2014/524286>.
- Choudhry N, Rao RC. Images in clinical medicine. Valsalva retinopathy. *N Engl J Med.* 2014;370(8):e13. <https://doi.org/10.1056/NEJMim1304102>.
- Georgiou T, Pearce IA, Taylor RH. Valsalva retinopathy associated with blowing balloons. *Eye Lond Engl.* 1999;13(Pt 5):686–687. <https://doi.org/10.1038/eye.1999.193>.
- Krepler K, Wedrich A, Schranz R. Intraocular hemorrhage associated with dental implant surgery. *Am J Ophthalmol.* 1996;122(5):745–746. [https://doi.org/10.1016/S0002-9394\(14\)70504-5](https://doi.org/10.1016/S0002-9394(14)70504-5).
- Jacobs N, Bossy M, Patel A. The life and work of Antonio Maria Valsalva (1666-1723) - popping ears and tingling tongues. *J Intensive Care Soc.* 2018;19(2):161–163. <https://doi.org/10.1177/1751143717731229>.
- Jellinek EH. The Valsalva manoeuvre and Antonio Valsalva (1666-1723). *J R Soc Med.* 2006;99(9):448–451. <https://doi.org/10.1258/jrsm.99.9.448>.
- Bluestone CD, Cantekin EI. Current clinical methods, indications and interpretation of eustachian tube function tests. *Ann Otol Rhinol Laryngol.* 1981;90(6 Pt 1):552–562. <https://doi.org/10.1177/000348948109000608>.
- Ruan K, Li J, Tan S, Liu L, Tang A. Comparison of sonotubometry, impedance, tubotympano-aerography, and tubomanometry to test eustachian tube function. *Am J Otolaryngol.* 2020;41(2):102384. <https://doi.org/10.1016/j.amjoto.2019.102384>.
- Li N, Zhu Z, Yi G, Li S, Han X. Valsalva retinopathy in twin-pregnancy: a case report and literature review. *Am J Case Rep.* 2018;19:5–9. <https://doi.org/10.12659/ajcr.905738>.
- Foos RY. Vitreoretinal juncture; topographical variations. *Invest Ophthalmol.* 1972;11(10):801–808.
- Liu Z, Pan X, Bi H. Treatment of Valsalva retinopathy. *Optom Vis Sci Off Publ Am Acad Optom.* 2014;91(11):e278–281. <https://doi.org/10.1097/OPX.0000000000000400>.
- Vaz-Pereira S, Barata AD. Multimodal imaging of subhyaloid hemorrhage in Valsalva retinopathy treated with Nd:YAG laser. *Ophthalmol Retina.* 2018;2(1):73. <https://doi.org/10.1016/j.oret.2017.09.006>.
- García Fernández M, Navarro JC, Castaño CG. Long-term evolution of Valsalva retinopathy: a case series. *J Med Case Rep.* 2012;6:346. <https://doi.org/10.1186/1752-1947-6-346>.
- Mutha V, Narde HK, Chandra P, Kumar A. Valsalva retinopathy following normal vaginal delivery: “bilateral a rarity.”. *BMJ Case Rep.* 2018;2018. <https://doi.org/10.1136/bcr-2018-224781>.