

# UCSF

## UC San Francisco Previously Published Works

### Title

Refractory Ulcerative Colitis With Associated Synovitis, Acne, Pustulosis, Hyperostosis, Osteitis Syndrome Successfully Treated With Tofacitinib.

### Permalink

<https://escholarship.org/uc/item/5zf996m1>

### Journal

ACG Case Reports Journal, 11(4)

### ISSN

2326-3253

### Authors

Kim, Bryan

Thiemann, Anna

Dietz, Brett

et al.

### Publication Date

2024-04-01

### DOI

10.14309/crj.0000000000001342

Peer reviewed



# Refractory Ulcerative Colitis With Associated Synovitis, Acne, Pustulosis, Hyperostosis, Osteitis Syndrome Successfully Treated With Tofacitinib

Bryan J. Kim, MD<sup>1</sup>, Anna Thiemann, MD<sup>2</sup>, Brett Dietz, MD, MS<sup>3</sup>, and Kendall Beck, MD<sup>4</sup>

<sup>1</sup>Department of Medicine, University of California, San Francisco, CA

<sup>2</sup>Department of Medicine, California Pacific Medical Center, CA

<sup>3</sup>Department of Rheumatology, University of California, San Francisco, CA

<sup>4</sup>Department of Gastroenterology and Hepatology, University of California, San Francisco, CA

## ABSTRACT

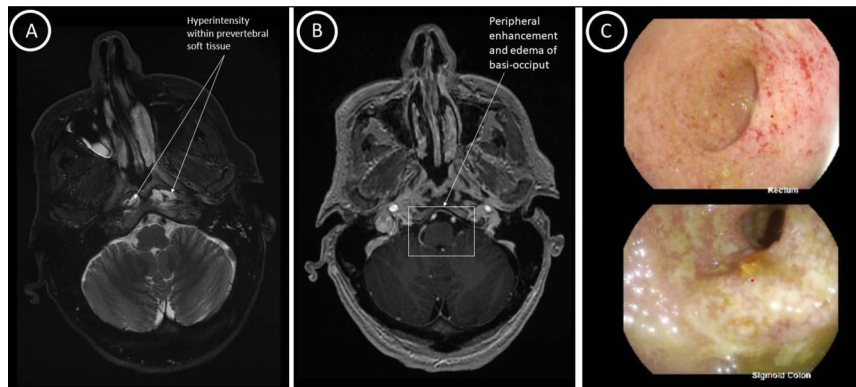
Synovitis, acne, pustulosis, hyperostosis, osteitis (SAPHO) syndrome is a rare inflammatory condition associated with inflammatory bowel disease. Limited data exist on standardized management. We report a case of refractory SAPHO syndrome and ulcerative colitis (UC) treated successfully with tofacitinib. A 54-year-old man with UC presented with an intractable headache. A diagnosis of SAPHO syndrome was made based on the finding of sterile osteitis in the skull base and persistent severe UC. Symptoms, imaging, and endoscopy revealed persistent UC and osteitis despite multiple therapies. Tofacitinib was initiated and clinical remission was achieved. Tofacitinib is an effective treatment of refractory inflammatory bowel disease and SAPHO syndrome.

## INTRODUCTION

Synovitis, acne, pustulosis, hyperostosis, osteitis (SAPHO) syndrome is a rare inflammatory condition of the bone, joint, and skin. Pathogenesis of this disease is not well understood but suspected to have components of genetic, infectious, and immune dysregulation that contribute to the disease process. While the hallmark manifestations of SAPHO syndrome include osteoarticular and dermatologic manifestations, there is a strong association with inflammatory bowel disease (IBD). There are limited data on the management of SAPHO syndrome both individually and in the context of IBD. We report a case of a patient with ulcerative colitis (UC) with intractable headaches diagnosed as SAPHO syndrome who failed multiple agents and was successfully treated with tofacitinib.

## CASE REPORT

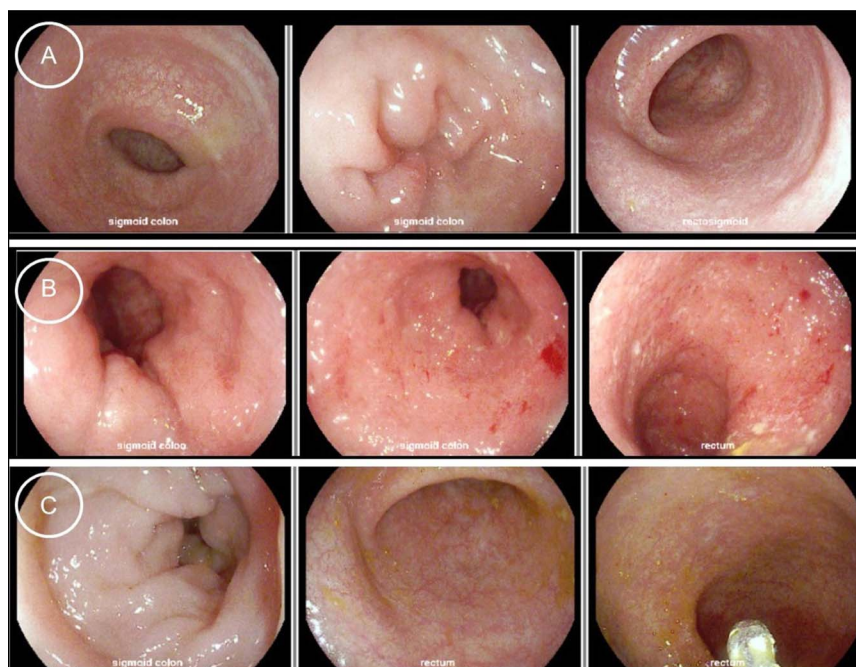
A 54-year-old man with a 1-year history of UC on mesalamine was admitted for bloody diarrhea, intractable headache, ptosis, photophobia, and conjunctivitis. Initial laboratory tests revealed white blood cell count  $9.0 \times 10^9/L$ , hemoglobin 10.7 g/dL, platelets  $678 \times 10^9/L$ , ferritin 74  $\mu\text{g/L}$ , C-reactive protein 42.9 U/L, erythrocyte sedimentation rate 98 mm/hr, PR3-ANCA 197.7 IU/mL, and fecal calprotectin  $> 8,000 \mu\text{g/g}$ . Initial infectious workup, including stool studies and lumbar puncture, was unremarkable. Brain magnetic resonance imaging (MRI) revealed peripherally enhancing pockets of fluid in the central skull base anterior to the clivus with retropharyngeal adenopathy, concerning for an inflammatory process or infectious osteomyelitis. Needle biopsy of the skull base revealed *Cutibacterium acnes*, which was likely a contaminant, but the patient was given a 3-month course of ertapenem. Flexible sigmoidoscopy showed Mayo 2 colitis (Figure 1). The patient was discharged on oral and rectal budesonide with a plan for outpatient biologic initiation.



**Figure 1.** (A) Axial T2 brain MRI from initial presentation showing evidence of T2-hyperintense collection adjacent to the longus colli and capitis muscles. (B) Axial T1 brain MRI from initial presentation showing peripheral enhancement and marrow edema of the basi-occiput. (C) Flexible sigmoidoscopy from initial presentation showing diffuse, circumferential abnormal mucosa in the sigmoid colon and rectum consistent with Mayo 2 colitis. MRI, magnetic resonance imaging.

Before biologic initiation, the patient was readmitted with worsening diarrhea and persistent headache. Osteitis of the clivus was redemonstrated on MRI, with new Fluid-attenuated inversion recovery (FLAIR) hyperintensity in both temporomandibular joints (TMJs). Repeat biopsies revealed persistent osteitis without infection. Immunodeficiency and genetic testing were negative. Whole-body radionuclide bone scan showed no other involved sites. Although the patient lacked classic skin manifestations, given his osteoarticular manifestations with no alternative etiologies in the setting of his UC, the patient was given a diagnosis of SAPHO. The patient was discharged on infliximab, but after 2 months, he developed autoantibodies and was transitioned to adalimumab with methotrexate. Symptoms persisted, and repeat colonoscopy again revealed Mayo 2 colitis.

Biologic therapy was transitioned to ustekinumab with 6-mercaptopurine. MRI showed mild improvement in clival enhancement and flexible sigmoidoscopy showed Mayo 1 colitis. After 1 year, the patient's headaches began to worsen, and repeat MRI revealed increased left clival enhancement. Six-mercaptopurine was changed to methotrexate to target this manifestation. Despite escalated ustekinumab dosing over 6 months, the patient was readmitted for headaches and UC flare. He was then started on tofacitinib 10 mg twice daily with a near-complete clinical response. His most recent flexible sigmoidoscopy revealed normal colonic mucosa. Brain MRI demonstrated resolved inflammation of the skull base and TMJ. The patient is currently headache-free and in sustained endoscopic remission from UC for 16 months (Figure 2).



**Figure 2.** (A) Flexible sigmoidoscopy after initiation of ustekinumab and 6-mercaptopurine showing clinical and endoscopic remission. (B) Flexible sigmoidoscopy after a year of ustekinumab and 6-mercaptopurine showing recurrent inflammation and recurrent Mayo 2 colitis. (C) Flexible sigmoidoscopy after initiation of tofacitinib revealing normal colonic mucosa.

## DISCUSSION

SAPHO syndrome is difficult to diagnose because of its clinical heterogeneity and lack of widely accepted diagnostic or classification criteria. If characteristic cutaneous symptoms are absent, alternative etiologies for osteoarticular symptoms such as osteomyelitis, primary or metastatic tumors of bone, and spondyloarthropathies must be excluded before a clinical diagnosis can be made. SAPHO syndrome has an association with IBD, but it more commonly occurs in Crohn's colitis.<sup>1</sup> One systematic review found that 4.8% of patients with SAPHO syndrome were also diagnosed with IBD, whereas only 0.2% of patients in the IBD cohort also had SAPHO syndrome.<sup>1</sup>

This patient did not have cutaneous manifestations of SAPHO syndrome, but his isolated sterile osteitis and inflammatory TMJ arthritis in the context of IBD made this the most likely diagnosis.<sup>2</sup> Skin lesions are absent in one-third of patients and may occur 2 years after diagnosis.<sup>3</sup> Notably, this patient had an elevation of Proteinase (PR)-3 antineutrophil cytoplasmic antibodies (ANCA), which is present in 30%–50% of patients with UC, and unlikely to be evidence of granulomatosis with polyangiitis given lack of pulmonary, renal, or sinonasal involvement.<sup>4,5</sup> Hyperostosis and osteitis are the most common osteoarticular findings of SAPHO syndrome, and bacterial cultures are typically negative. However, it is hypothesized that low-virulence microbes such as *Cutibacterium acnes* may contribute to the pathogenesis of SAPHO syndrome by abnormal activation of innate and cellular immunity.<sup>6,7</sup>

Owing to its rarity, treatment modalities for SAPHO syndrome are based on observational data. Osteoarticular manifestations are initially treated with nonsteroidal anti-inflammatory drugs.<sup>7</sup> Methotrexate or tumor necrosis factor (TNF) inhibitors may be used in individuals with inadequate response to or intolerance of nonsteroidal anti-inflammatory drug therapy, with methotrexate primarily used for peripheral joint involvement only. IL-17 inhibition, interleukin (IL) 12/23 inhibition, and bisphosphonates are used in refractory cases of osteoarticular disease. Tetracyclines and oral retinoids may be helpful for cutaneous manifestations. This patient had no sustained remission of UC or SAPHO syndrome, despite escalation of standard therapy, but did respond well to tofacitinib, a Janus kinase inhibitor.

The exact pathogenesis of SAPHO syndrome is unclear, but studies have shown that cytokine dysregulation may play a role. Immune instability is thought to be caused by several factors, including elevation of TNF- $\alpha$ , IL-1, IL-8, IL-17, IL-18, and IL-23; increased prevalence of autoantibodies; and increased production of receptor activator of nuclear factor kappa beta ligand (RANKL).<sup>8</sup> Janus kinase inhibitors are a promising therapy that provides a blockade of upstream actions of many cytokines. Tofacitinib is used in UC and autoimmune arthritis,

but is increasingly being used off-label for systemic inflammatory conditions including SAPHO syndrome.<sup>9</sup> In addition, tofacitinib has been shown to suppress osteoclast-mediated structural damage through the RANKL pathway, a beneficial effect for the sterile osteitis found in this patient.<sup>10</sup> Limited data exist on tofacitinib for SAPHO syndrome, but in one pilot study of 12 female patients, tofacitinib induced remission of lesions found on the skin and on MRI, reduced systemic inflammation, and improved quality of life.<sup>11</sup> Case reports have noted the effectiveness of tofacitinib for refractory SAPHO syndrome associated with other inflammatory disorders such as Takayasu arteritis and ankylosing spondylitis, but this case describes the first associated with UC with good response to tofacitinib.<sup>12,13</sup> Further research is needed to refine treatment guidelines and better characterize patients who may benefit from tofacitinib.

## DISCLOSURES

Author contributions: B. Kim and A. Thiemann: wrote the initial draft of the manuscript, reviewed the case and data, completed final revisions; B. Dietz and K. Beck: contributed to all parts of the manuscript, approved the final draft and ensured accuracy and integrity of the work. K. Beck is the article guarantor.

Financial disclosure: None to report.

Previous presentation: American College of Gastroenterology 2023 Meeting and Postgraduate Course; October 20–25, 2023; Vancouver, British Columbia, Canada.

Informed consent was obtained for this case report.

Received January 3, 2024; Accepted March 19, 2024

## REFERENCES

1. Naves JE, Cabré E, Mañosa M, Grados D, Olivé A, Domènech E. A systematic review of SAPHO syndrome and inflammatory bowel disease association. *Dig Dis Sci*. 2013;58(8):2138–47.
2. Nguyen MT, Borchers A, Selmi C, Naguwa SM, Cheema G, Gershwin ME. The SAPHO syndrome. *Semin Arthritis Rheum*. 2012;42(3):254–65.
3. Hayem G, Bouchaud-Chabot A, Benali K, et al. SAPHO syndrome: A long-term follow-up study of 120 cases. *Semin Arthritis Rheum*. 1999;29(3):159–71.
4. Takedatsu H, Mitsuyama K, Fukunaga S, et al. Diagnostic and clinical role of serum proteinase 3 antineutrophil cytoplasmic antibodies in inflammatory bowel disease. *J Gastroenterol Hepatol*. 2018;33(9):1603–7.
5. Arias-Loste MT, Bonilla G, Moraleja I, et al. Presence of anti-proteinase 3 antineutrophil cytoplasmic antibodies (anti-PR3 ANCA) as serologic markers in inflammatory bowel disease. *Clin Rev Allergy Immunol*. 2013;45(1):109–16.
6. Berthelot JM, Corvec S, Hayem G. SAPHO, autophagy, IL-1, FoxO1, and propionibacterium (*Cutibacterium*) *acnes*. *Joint Bone Spine*. 2018;85(2):171–6.
7. Corbisiero MF, Batta N, Kylo H, Smyth A, Allen L, Franco-Paredes C. Clinical spectrum of *Cutibacterium acnes* infections: The SAPHO syndrome. *IDCases*. 2023;32:e01784.
8. Cheng W, Li F, Tian J, et al. New insights in the treatment of SAPHO syndrome and medication recommendations. *J Inflamm Res*. 2022;15:2365–80.

9. Zhao Z, Ye C, Dong L. The off-label uses profile of tofacitinib in systemic rheumatic diseases. *Int Immunopharmacol.* 2020;83:106480.
10. LaBranche TP, Jesson MI, Radi ZA, et al. JAK inhibition with tofacitinib suppresses arthritic joint structural damage through decreased RANKL production. *Arthritis Rheum.* 2012;64(11):3531–42.
11. Li C, Li Z, Cao Y, et al. Tofacitinib for the treatment of nail lesions and palmoplantar pustulosis in synovitis, acne, pustulosis, hyperostosis, and osteitis syndrome. *JAMA Dermatol.* 2021;157(1):74–8.
12. Yuan F, Luo J, Yang Q. SAPHO syndrome complicated by ankylosing spondylitis successfully treated with tofacitinib: A case report. *Front Immunol.* 2022;13:911922.
13. Ru C, Qian T, Liu X, et al. SAPHO syndrome with Takayasu arteritis successfully treated with tofacitinib. *Int J Rheum Dis.* 2023;26(7):1381–3.

---

**Copyright:** © 2024 The Author(s). Published by Wolters Kluwer Health, Inc. on behalf of The American College of Gastroenterology. This is an open access article distributed under the terms of the Creative Commons Attribution-Non Commercial-No Derivatives License 4.0 (CCBY-NC-ND), where it is permissible to download and share the work provided it is properly cited. The work cannot be changed in any way or used commercially without permission from the journal.