

UC Davis

UC Davis Previously Published Works

Title

Conspicuity of suspicious breast lesions on contrast enhanced breast CT compared to digital breast tomosynthesis and mammography

Permalink

<https://escholarship.org/uc/item/60g8s0sp>

Journal

British Journal of Radiology, 92(1097)

ISSN

0007-1285

Authors

Aminololama-Shakeri, Shadi
Abbey, Craig K
López, Javier E
et al.

Publication Date

2019-05-01

DOI

10.1259/bjr.20181034

Peer reviewed

Cite this article as:

Aminololama-Shakeri S, Abbey CK, López JE, Hernandez AM, Gazi P, Boone JM, et al. Conspicuity of suspicious breast lesions on contrast enhanced breast CT compared to digital breast tomosynthesis and mammography. *Br J Radiol* 2019; **92**: 20181034.

FULL PAPER

Conspicuity of suspicious breast lesions on contrast enhanced breast CT compared to digital breast tomosynthesis and mammography

¹SHADI AMINOLOLAMA-SHAKERI, MD, ²CRAIG K. ABBEY, PhD, ³JAVIER E LÓPEZ, MD, ¹ANDREW M HERNANDEZ, ¹PEYMON GAZI, PhD, ¹JOHN M BOONE, PhD and ¹KAREN K LINDFORS, MD

¹Department of Radiology, University of California Davis Medical Center, California, USA

²Department of Psychological and Brain Sciences, University of California Santa Barbara, California, USA

³Internal Medicine Department, Cardiovascular Division, University of California Davis Medical Center, California, USA

Address correspondence to: Dr Shadi Aminololama-Shakeri
E-mail: sshakeri@ucdavis.edu

Objective: Compare conspicuity of suspicious breast lesions on contrast-enhanced dedicated breast CT (CEbCT), tomosynthesis (DBT) and digital mammography (DM).

Methods: 100 females with BI-RADS 4/5 lesions underwent CEbCT and/or DBT prior to biopsy in this IRB approved, HIPAA compliant study. Two breast radiologists adjudicated lesion conspicuity scores (CS) for each modality independently. Data are shown as mean CS \pm standard deviation. Two-sided *t*-test was used to determine significance between two modalities within each subgroup. Multiple comparisons were controlled by the false-discovery rate set to 5%.

Results: 50% of studied lesions were biopsy-confirmed malignancies. Malignant masses were more conspicuous on CEbCT than on DBT or DM (9.7 ± 0.5 , $n = 25$; 6.8 ± 3.1 , $n = 15$; 6.7 ± 3.0 , $n = 27$; $p < 0.05$). Malignant calcifications were equally conspicuous on all three modalities (CEbCT 8.7 ± 0.8 , $n = 18$; DBT 8.5 ± 0.6 , $n = 15$; DM 8.8 ± 0.7 , $n = 23$; $p = \text{NS}$). Benign masses were

equally conspicuous on CEbCT (6.6 ± 4.1 , $n = 22$); DBT (6.4 ± 3.8 , $n = 17$); DM (5.9 ± 3.6 , $n = 24$; $p = \text{NS}$). Benign calcifications CS were similar between DBT (8.5 ± 1.0 , $n = 17$) and DM (8.8 ± 0.8 , $n = 26$; $p = \text{NS}$) but less conspicuous on CEbCT (4.0 ± 2.9 , $n = 25$, $p < 0.001$). 55 females were imaged with all modalities. Results paralleled the entire cohort. 69% ($n = 62$) of females imaged by CEbCT had dense breasts. Benign/malignant lesion CSs in dense/non-dense categories were 4.8 ± 3.7 , $n = 33$, vs 6.0 ± 3.9 , $n = 14$, $p = 0.35$; 9.2 ± 0.9 , $n = 29$ vs. 9.4 ± 0.7 , $n = 14$; $p = 0.29$, respectively.

Conclusion: Malignant masses are more conspicuous on CEbCT than DM or DBT. Malignant microcalcifications are equally conspicuous on all three modalities. Benign calcifications remain better visualized by DM and DBT than with CEbCT. We observed no differences in benign masses on all modalities. CS of both benign and malignant lesions were independent of breast density.

Advances in knowledge: CEbCT is a promising diagnostic imaging modality for suspicious breast lesions.

INTRODUCTION

Unlike conventional two-dimensional (2D) digital mammography (DM) and digital breast tomosynthesis (DBT), dedicated breast CT (bCT), an emerging technology, provides fully three-dimensional isotropic image data sets without the need for breast compression. Unenhanced dedicated bCT has been shown in prior studies to be superior to mammography for the detection of masses but not microcalcifications.¹ More recently, contrast-enhanced dedicated bCT (CEbCT) was reported as a potential method for differentiating malignant from benign microcalcifications.² Differences in enhancement measured in Hounsfield units (HU), were shown to discriminate benign from malignant calcifications. These results suggest

that CEbCT is a potentially quantitative and qualitative modality for differentiating breast cancer from benign lesions including calcifications. As such, CEbCT may improve breast cancer detection as well as reduce the number of false-positive exams that frequently require an invasive procedure for making a definitive diagnosis.

DBT uses a modification of digital mammographic technique to reduce the effects of parenchymal superimposition. Large population studies^{3,4} have confirmed initial observations of reduced recall rates^{5,6} and improved radiologist performance^{7,8} as well as increased cancer detection with the addition of DBT to DM compared to DM alone. Several studies support the utility of tomosynthesis as a diagnostic

tool to potentially replace conventional 2D mammographic workups using additional projections and spot compression views⁹⁻¹¹ particularly for non-calcified lesions. DBT has been shown to characterize soft tissue lesions more accurately than 2D mammographic views.¹² In the diagnostic evaluation of calcifications, DM and DBT perform similarly.^{12,13}

Despite its advantages, tomosynthesis shares limitations with DM. DBT is a planar imaging modality where superimposition artifacts and masking of soft tissue lesions can occur in extremely dense tissues. More importantly, recall rates and cancer detection rates are not improved by the addition of tomosynthesis to DM in females with extremely dense breasts.¹⁴ In the diagnostic setting, multiple tomosynthesis projections, magnification views for calcified lesions and often ultrasound continue to be required for complete lesion characterization. It is yet unknown whether the use of DBT can decrease false-positive biopsies.

We report a cohort of patients with lesions recommended for biopsy after evaluation by conventional clinical diagnostic examination with mammography and targeted ultrasound. These patients were imaged with tomosynthesis and/or breast CT prior to biopsy. We hypothesize that CEbCT improves diagnostic evaluation of suspicious breast lesions when compared to tomosynthesis and 2D mammography. Our goal was to evaluate and compare the conspicuity of suspicious breast lesions on CEbCT, DBT and mammography.

METHODS AND MATERIALS

Females with BI-RADS category four or five lesions as determined by conventional clinical diagnostic work-up including full field digital 2D mammography (Selenia, Hologic®, Bedford, MA) or ultrasound were recruited and prospectively enrolled in our Institutional Review Board-approved and Health Insurance Portability and Accountability Act-compliant study. Written informed consent was obtained from all participants prior to the study. Patients with contraindications to the use of intravenous contrast material were excluded from the study. Alternating patients received craniocaudal (CC) and mediolateral oblique (MLO) tomosynthesis (Selenia Dimensions, Hologic®, Bedford, MA) or CEbCT. All tomosynthesis images were reviewed using SecureView workstations (Hologic®, Bedford, MA). All analyzed DM and DBT images were acquired directly without the use of synthetic 2D imaging. A subset of the participants had both tomosynthesis and CEbCT examinations. Consecutive patients in that subset cohort had alternating order of modalities. Patients whose lesions were matched on all three modalities were asked to complete a short questionnaire to rate their level of comfort on each of the modalities. The rating scale was from 1 to 10 with 1 defined as least comfortable and 10 as most comfortable. All subjects underwent core biopsy under ultrasound or stereotactic guidance for histopathological diagnosis of the clinically suspicious lesion. Only lesions with known histopathology were included in the study. Breast density was defined at mammography according to fourth (2003) edition of the BI-RADS manual.¹⁵

Image acquisition

The subjects of this study were imaged using a dedicated breast CT system previously reported.^{16,17} Briefly, images were acquired using a tube voltage of 80 kV. The tube current was adjusted according to breast size and mammographic breast density while keeping the mean glandular radiation dose approximately equivalent to that of two-view screening mammography. Images were acquired with patients in prone position after one breast at a time was placed through an opening in the scanner. The scan duration was 17 s during which the subject was instructed to hold her breath. Patients were instructed to remain still upon completion of the non-contrast scan of the affected breast, while 100 mL of intravenous iodixanol (Visipaque 320; GE Healthcare, Waukesha, WI) was administered at a rate of 4 mL/s using a power injector. The breast was rescanned approximately 90 s after the start of the injection.

Radiation dosimetry

A direct comparison of the mean glandular dose (MGD) from mammography and bCT was performed over 243 patients involved in breast CT studies. These patients received both two-view mammograms (CC & MLO) and a breast CT scan. Breast dosimetry for mammography and breast CT has been studied extensively in our laboratory^{18,19} and it is widely assumed that the dose in DBT is within 5% of the dose of mammography.²⁰ Thus, the comparison here is between two-view mammography, two-view tomosynthesis, and one breast CT examination.

Lesion analysis

To compare all three modalities (DM, DBT and CEbCT), a for each histologically proven lesion was assigned per modality by two independent observers. Lesion type and descriptors such as size, mass shape and margin were recorded. CC and MLO mammographic views, DBT and CEbCT were independently reviewed in sequential order by two breast imaging radiologists, each with at least 3 years of experience with dedicated breast CT. DBT or CEbCT images were reviewed first followed by review of the mammogram. All CEbCT images were reviewed on specialized software in coronal, axial and sagittal planes.²¹

The conspicuity of each lesion was scored on a continuous scale from 0 to 10, where 0 represented non-visualization and 10 indicated excellent conspicuity on each modality.

Statistical analysis

For a given lesion in an imaging modality, conspicuity scores from two radiologists were averaged into a single combined score. For the total of 255 lesion/modality combinations for which scores were available, a small number (6; 1.2%) were missing a score from one of the radiologists. In these cases, the single available conspicuity score served as the "combined" score. The cases were classified as mass or microcalcification lesions based on the dominant finding on the patient's clinical diagnostic presentation. Lesions were further subdivided based on histological outcomes of benign or malignant pathology.

The primary comparisons of this work consisted of differences in conspicuity of findings on CEbCT, DBT and DM. Comparisons

were made in each of the 4 subgroups of data (benign mass, malignant mass, benign microcalcifications, and malignant microcalcifications) for a total of 12 primary comparisons.

Univariate statistical summaries were performed with calculation of average conspicuity scores of each lesion for each modality. These data are shown as mean \pm standard deviation of conspicuity scores. Two-sided *t*-tests were used to compare conspicuity between two modalities within each subgroup. When significant unpaired data were available (five or more scores in each unpaired group) an optimal pooled *t*-test was used to assess significance.²² Otherwise unpaired data were ignored, and a standard paired *t*-test was used. Multiple comparisons were controlled using the method of Benjamini and Hochberg,²³ with the familywise false-discovery rate set to 5%.

RESULTS

102 patients with 103 BIRADS four or five lesions were prospectively enrolled. Two of the participants, one of whom had two lesions, were excluded due to incompleteness of the protocol. Of the remaining 100 patients, 90 had CEbCT and 65 were imaged with DBT. All had DM as part of their clinical diagnostic workup. A smaller cohort of these patients (55 out of 100) was imaged with all three modalities. All patients were females with an average age of 55 years (age range 36–77 years). One patient in the earlier phase of the recruitment process had a screen film mammogram. All others underwent DM. 54 patients had heterogeneously dense or dense fibroglandular tissues on their mammograms.

Histopathology distribution

Of 100 breast lesions, 50 (50%) were malignant and 50 (50%) were benign. The histopathological findings for these lesions are listed in Table 1. Out of the 50 malignant lesions, 27 (54%) were masses and 23 (46%) were calcifications. Of 50 benign lesions, 24 (48%) were masses and 26 (52%) were calcifications. 14 patients reported palpable findings, of which all but one were masses.

Lesion conspicuity

Malignant

Malignant masses were significantly more conspicuous on CEbCT than on DBT or DM (9.7 ± 0.5 $n = 25$, 6.8 ± 3.1 $n = 15$, 6.7 ± 3.0 $n = 27$ respectively $p < 0.05$) (Figure 1). Malignant mass sizes ranged from 6 to 22 mm with an average of 13 mm. Three cancers were occult on 2D mammography but highly conspicuous on CEbCT. One of these was also occult on tomosynthesis (Figure 2).

Malignant calcification lesions were equally conspicuous on all three modalities (CEbCT 8.7 ± 0.8 $n = 18$, DBT 8.5 ± 0.6 $n = 15$ DM 8.8 ± 0.7 $n = 23$; $p = \text{NS}$) (Figure 3). The average size of the malignant calcification lesions was 9 mm with lesion sizes ranging from 2 to 26 mm (Figure 4).

Benign

Benign masses were equally conspicuous on CEbCT (6.6 ± 4.1 $n = 22$), DBT (6.4 ± 3.8 $n = 17$) and DM (5.9 ± 3.6 $n = 24$) ($p = \text{NS}$) (Figure 1). Conspicuity scores of benign calcifications were

Table 1. Histopathology of lesions

	Lesions ($N = 100$)	
	N	%
Malignant Lesions	50	
Invasive ductal carcinoma	23	46%
Grade 1	8	
Grade 2	12	
Grade 3	3	
Invasive lobular carcinoma	3	6%
Grade 1	2	
Grade 2	1	
Grade 3	0	
DCIS	24	48%
Grade 1	3	
Grade 2	9	
Grade 3	12	
Benign lesions	50	
Adenosis	3	
Atypical ductal hyperplasia	6	
Apocrine metaplasia	2	
Benign, NOS	7	
Columnar cell change	4	
Cyst	1	
Fat necrosis	1	
Fibroadenoma	11	
Fibroadipose tissue	1	
Fibrocystic changes	10	
Flat epithelial atypia	1	
Papilloma	2	
Stromal fibrosis	1	

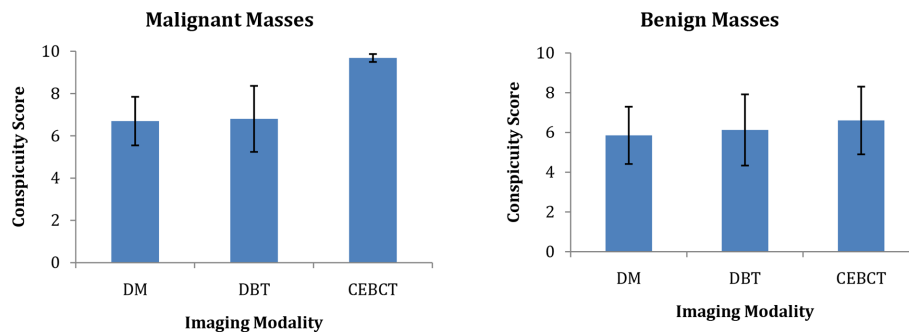
DCIS, ductal carcinoma *in situ*.

equal on DBT (8.5 ± 1.0 $n = 17$), and DM (8.8 ± 0.8 $n = 26$) ($p = \text{NS}$) but significantly less on CEbCT (4.0 ± 2.9 $n = 25$ $p < 0.001$) (Figure 3). The benign calcifications ranged in size from 4 to 18 mm with an average of 8 mm.

Matched subset analysis

55 out of 100 were imaged with all three modalities prior to biopsy. In this subset, 13 patients had malignant masses, 10 had malignant calcifications, 16 had benign masses and another 16 had benign calcifications. Results from this smaller group of patients followed the above analysis of the larger cohort closely. In this matched group, malignant masses were also significantly more conspicuous on CEbCT than on DBT or DM (9.5 ± 0.6 , 6.9 ± 3.2 , 5.6 ± 3.8 $n = 13$ respectively $p < 0.05$). Malignant calcification

Figure 1. Mass conspicuity on DM, DBT and CEbCT. CEbCT, contrast-enhanced breast CT; DBT, dedicated breast tomosynthesis; DM, digital mammography.



lesions were equally conspicuous on all three modalities (CEbCT 8.4 ± 0.8 , DBT 8.6 ± 0.6 , DM 8.8 ± 0.6 $n = 10$; $p = \text{NS}$).

Benign masses were equally conspicuous on CEbCT (6.5 ± 4.2), DBT (6.3 ± 3.9) and DM (6.0 ± 3.7 , $p = \text{NS}$). Conspicuity scores of benign calcifications were equal on DBT (8.5 ± 1.0), and DM (8.8 ± 0.7 , $p = \text{NS}$) but significantly less on CEbCT (4.8 ± 2.9 , $p < 0.001$).

Radiation dosimetry

For the database of patients used exclusively for dose comparisons ($N = 243$), the breast CT dose was on average 50.1% higher than two-view mammography, and thus was also about 50% higher than DBT as well. For the 55 patients in this study who underwent both two-view mammography and two-view DBT, the dose from breast CT was on average about 33% lower than the combination of mammography and DBT.

Comfort survey

50 out of 55 (91%) patients who were imaged by all three modalities completed a short survey regarding their comfort level on CEbCT. Responses are shown in Table 2. The score scales were

from 1 to 10 where 1 was very uncomfortable and 10 was designated as very comfortable. The respondents rated the comfort of the breath hold and contrast injection as 7.28 ± 2.76 and 8.36 ± 1.51 respectively and the overall exam as 6.50 ± 2.42 . The patients rated CEbCT as being more comfortable than both DM and DBT.

CEbCT CS correlation with breast density

62 of the 90 patients imaged by CEbCT had dense breast tissue (heterogeneously dense and extremely dense combined) and 28/90 had non-dense tissue (fatty and scattered fibroglandular tissue combined). The mean conspicuity scores \pm standard deviation of benign lesions were 4.8 ± 3.7 $n = 33$, vs 6.0 ± 3.9 $n = 14$, $p = 0.35$ in the dense vs non-dense categories respectively. The malignant lesion conspicuity scores (Figure 5, $n = 14$) were also not significantly different in the dense vs non-dense breasts (9.2 ± 0.9 $n = 29$ vs. 9.4 ± 0.7 , $p = 0.29$).

DISCUSSION

This study demonstrates that malignant masses are more conspicuous on dedicated CEbCT than both mammography and tomosynthesis. Malignant microcalcifications are equally conspicuous on all three modalities even for lesions as small as a

Figure 2. Invasive ductal carcinoma is occult on DM (a) and DBT (b) in extremely dense breast and enlarged axillary lymph node as the sole finding (white arrow). Abnormally enhancing irregular mass with extension to skin (yellow arrow) as well as metastatic lymph node (white arrow) visualized on coronal (c), sagittal (d) and axial (e) CEbCT. CEbCT, contrast-enhanced breast CT; DBT, dedicated breast tomosynthesis; DM, digital mammography.

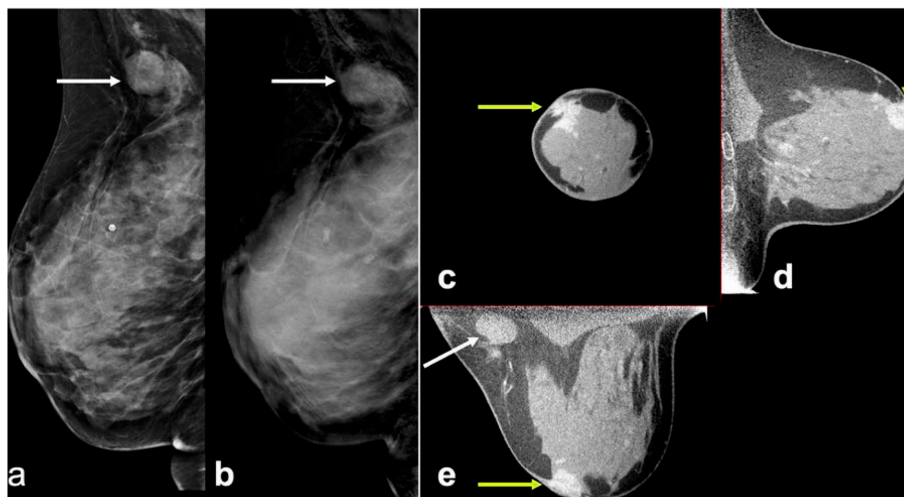
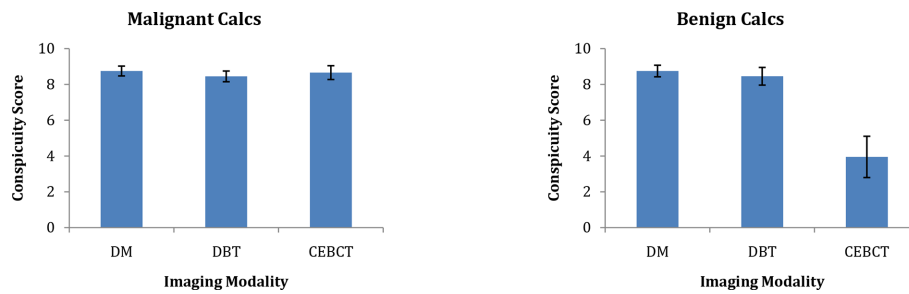


Figure 3. Comparison of microcalcification conspicuity on DM, DBT and CEbCT. CEbCT, contrast-enhanced breast CT; DBT, dedicated breast tomosynthesis; DM, digital mammography.



few millimeters. Benign calcifications on the other hand, remain better visualized by mammography and tomosynthesis when compared to CEbCT. There is no significant difference for visualization of benign masses on the three modalities.

Malignant microcalcifications are visualized equally on CEbCT and mammography—the gold-standard for calcification evaluation as well as with tomosynthesis. In contrast to both mammography and tomosynthesis, where benign and malignant microcalcifications are equally visualized, on CEbCT benign microcalcifications are not as conspicuous as malignant microcalcifications. This differential conspicuity between benign and malignant calcifications on CEbCT is advantageous over both DM and DBT, where all calcifications—benign and

malignant—may be equally visible and require tissue sampling to discriminate the two categories.

Overlap of mammographic features of benign and malignant lesions, both indolent and aggressive, necessitates core biopsy for definitive diagnosis. This decreases biopsy positive-predictive values (PPV) in standard clinical work-up of detected lesions. The enhancement differential between benign and malignant masses on CEbCT as reported previously¹ may be used as a quantitative tool for the assessment of these lesions. Recently, enhancement values for benign microcalcifications have been shown to be lower than that of malignant ones.² Used as a diagnostic tool, CEbCT may avert unnecessary biopsies for findings without enhancement that may be more appropriate for surveillance. As

Figure 4. Malignant microcalcification lesion on DM, DBT and CEbCT. Optical enlargement of mammographic magnification view (a) and tomosynthesis (b) show a group of pleomorphic microcalcifications. Coronal (c), sagittal (d) and axial (e) views on CEbCT show a 5 mm enhancing mass corresponding to the microcalcifications. Histopathology showed DCIS and invasive ductal carcinoma. CEbCT, contrast-enhanced breast CT; DBT, dedicated breast tomosynthesis; DCIS, ductal carcinoma in situ; DM, digital mammography.

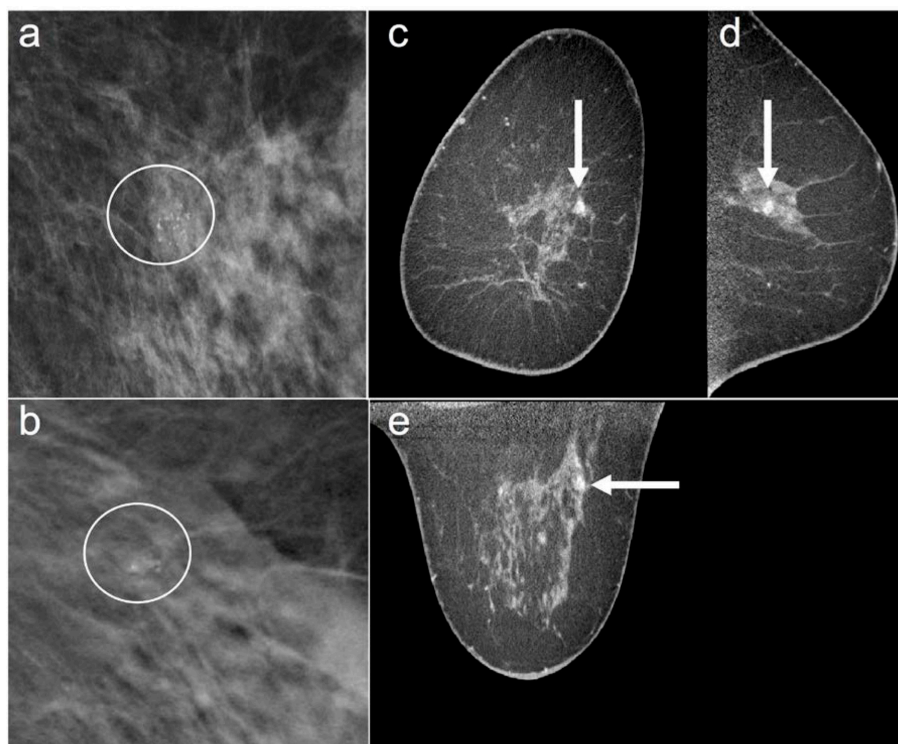


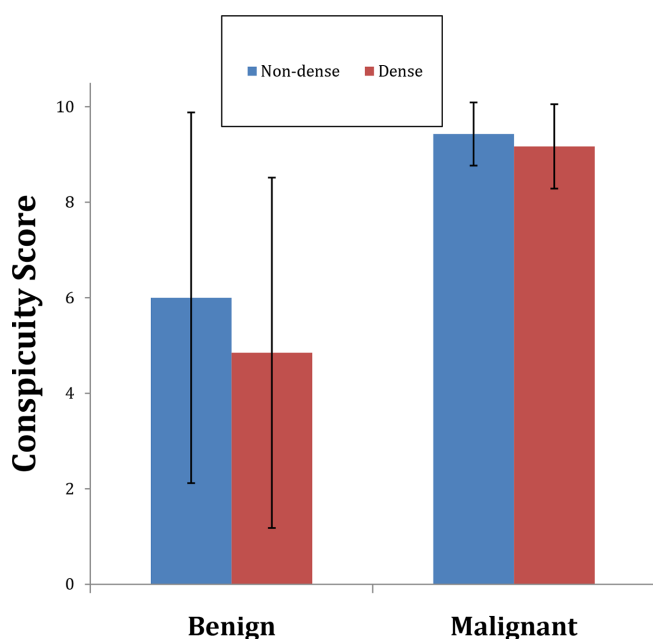
Table 2. Summary of responses to questionnaire completed by 50/55 females who were imaged with DM, DBT and CEbCT regarding the comfort level on CEbCT

	Mean (Std dev)	Median
How difficult was it for you to hold your breath during the breast CT exam? 1 = Very 10 = Not at all	7.28 (2.76)	8
How uncomfortable was the contrast (dye) injection? 1 = Very uncomfortable 10 = Very comfortable	8.36 (1.51)	9
Please rate your overall comfort level during the entire breast CT exam. 1 = Very uncomfortable 10 = Very comfortable	6.50 (2.42)	6.5
Please rate the overall comfort of the entire contrast breast CT exam compared to mammography. 1 = Much worse 10 = Much better	6.90 (2.41)	7.5
Please rate the overall comfort of the entire contrast breast CT exam compared to tomosynthesis. 1 = Much worse 10 = Much better	6.44 (2.14)	6

such, reducing biopsies of those lesions that do not enhance on CEbCT would increase biopsy PPV as well as potentially reduce the cost burden and the anxiety related to having an interventional procedure.

Biological characteristics of breast lesions may be obtained from any imaging technique that utilizes contrast material such as

Figure 5. Conspicuity scores of both benign and malignant lesions are not significantly different in dense and non-dense breasts on CEbCT. CEbCT, contrast-enhanced breast CT.



dynamic contrast-enhanced breast MRI (DCE-MRI), contrast enhanced spectral mammography (CESM) or contrast-enhanced tomosynthesis (CET). Tumor enhancement may correlate with the biological activity of tumor cells and provide a biomarker for disease progression. With DCE-MRI, the lack of enhancement of low grade ductal carcinoma *in situ* lesions has been described as advantageous for discriminating those indolent lesions which may not require the same treatment attention as more biologically aggressive ones.²⁴ There is developing evidence that CESM may have improved sensitivity over DM.²⁵ Comparisons of CESM, CET and DCE-MRI have also shown similar diagnostic accuracy and improved performance in comparison to DM and DBT.²⁶ As a fully three-dimensional modality, breast CT provides superior anatomical information in comparison to mammography and its derivative technologies, DBT, CESM and CET. CEbCT does not require compression like DM and DBT and has potential to quantify enhancement like MRI, which has potential for informing biopsy decision thresholds as opposed to CESM and CET where evaluation of enhancement is not quantitative. Additionally, each breast is imaged in less than 20 s in comparison to the time required to reposition the breast to obtain the standard mammographic CC and MLO views as well as MRI. One of the shortcomings of using CEbCT like any technique requiring contrast enhancement is the necessity of an intravenous injection as well as the potential for contrast reactions. In this study, patients did not find the contrast injection and breath hold for CEbCT to pose a barrier to performing the exam. Similar to the use of CT for imaging of other body parts, screening for contrast allergy history and renal disease would be prudent in clinical implementation.

Clinical trials comparing the performance of CEbCT to DCE-MRI are currently underway. Prospective studies directly comparing CEbCT to contrast-enhanced mammography and CET would be useful to define its role in clinical practice. These studies should not only focus on measuring diagnostic accuracy, but also, cost analysis and patient preferences.

CEbCT depicts breast tissue without compression and at the same radiation dose but without being affected by breast tissue density in contrast to mammograms. In this study we have shown that conspicuity of lesions, particularly, visualization of cancers on CEbCT is unaffected by breast density. This feature overcomes the most significant limitation of mammography and tomosynthesis performance in extremely dense breasts¹⁴ thereby decreasing false negative exams. In addition, tomosynthesis continues to require compression for adequate image production.

Our study has limitations. It is based on a small number of subjects in each category of lesions. Larger blinded studies evaluating receiver operating curves are needed to allow the evaluation of enhancement values in the spectrum of breast lesions. Another limitation of our study is the subjective scoring of lesion conspicuity on the three modalities by the two readers. The readers were involved in patient recruitment, therefore there is potential for recall bias.

In summary, we have shown that CEbCT is superior in the visualization of malignant masses and has potential for discriminating benign from enhancing malignant calcification lesions when compared to DM and DBT. The differences in appearance of lesions on CEbCT in comparison to tomosynthesis and mammography may be related to the biology of the findings characterized by degree of contrast enhancement and are independent of breast density. As a diagnostic tool, CEbCT may potentially decrease false-negative exams in extremely dense breasts where malignant lesions may be difficult to discern on mammography and tomosynthesis due to masking. CEbCT also holds promise in increasing biopsy PPV and thus avoiding costly interventions for lesions that are indistinguishable from malignancies on mammographic derivative studies. The potential for quantitation

of enhancement of breast lesions with CEbCT is advantageous when compared to contrast-enhanced mammographic techniques. Although randomized, blinded, multicentered trials with a larger number of participants are needed, our results demonstrate a promising role in the diagnostic setting for CEbCT in the detection of breast cancer.

ACKNOWLEDGMENT

This communication was funded in part by NIH grants P30 CA093373 and R01 CA181081. Comments made are solely the responsibility of the authors and do not necessarily represent the official views of the National Cancer Institute or the National Institutes of Health.

REFERENCES

- Prionas ND, Lindfors KK, Ray S, Huang S-Y, Beckett LA, Monsky WL, et al. Contrast-enhanced dedicated breast CT: initial clinical experience. *Radiology* 2010; **256**: 714–23. doi: <https://doi.org/10.1148/radiol.10092311>
- Aminololama-Shakeri S, Abbey CK, Gazi P, Prionas ND, Nosratieh A, Li C-S, et al. Differentiation of ductal carcinoma in-situ from benign micro-calcifications by dedicated breast computed tomography. *Eur J Radiol* 2016; **85**: 297–303. doi: <https://doi.org/10.1016/j.ejrad.2015.09.020>
- Skaane P, Bandos AI, Gullien R, Eben EB, Ekseth U, Haakenaasen U, et al. Comparison of digital mammography alone and digital mammography plus tomosynthesis in a population-based screening program. *Radiology* 2013; **267**: 47–56. doi: <https://doi.org/10.1148/radiol.12121373>
- Friedewald SM, Rafferty EA, Rose SL, Durand MA, Plecha DM, Greenberg JS, et al. Breast cancer screening using tomosynthesis in combination with digital mammography. *JAMA* 2014; **311**: 2499–507. doi: <https://doi.org/10.1001/jama.2014.6095>
- Gur D, Abrams GS, Chough DM, Ganott MA, Hakim CM, Perrin RL, et al. Digital breast tomosynthesis: Observer performance study. *AJR Am J Roentgenol* 2009; **193**: 586–91. doi: <https://doi.org/10.2214/AJR.08.2031>
- Gennaro G, Toledano A, di Maggio C, Baldan E, Bezzon E, La Grassa M, et al. Digital breast tomosynthesis versus digital mammography: a clinical performance study. *Eur Radiol* 2010; **20**: 1545–53. doi: <https://doi.org/10.1007/s00330-009-1699-5>
- Rafferty EA, Park JM, Philpotts LE, Poplack SP, Sumkin JH, Halpern EF, et al. Assessing radiologist performance using combined digital mammography and breast tomosynthesis compared with digital mammography alone: results of a multicenter, multireader trial. *Radiology* 2013; **266**: 104–13. doi: <https://doi.org/10.1148/radiol.12120674>
- Svahn TM, Chakraborty DP, Ikeda D, Zackrisson S, Do Y, Mattsson S, et al. Breast tomosynthesis and digital mammography: a comparison of diagnostic accuracy. *Br J Radiol* 2012; **85**: e1074–82. doi: <https://doi.org/10.1259/bjr/53282892>
- Brandt KR, Craig DA, Hoskins TL, Henrichsen TL, Bendel EC, Brandt SR, et al. Can digital breast tomosynthesis replace conventional diagnostic mammography views for screening recalls without calcifications? A comparison study in a simulated clinical setting. *AJR Am J Roentgenol* 2013; **200**: 291–8. doi: <https://doi.org/10.2214/AJR.12.8881>
- Noroozian M, Hadjiiski L, Rahnema-Moghadam S, Klein KA, Jeffries DO, Pinsky RW, et al. Digital breast tomosynthesis is comparable to mammographic spot views for mass characterization. *Radiology* 2012; **262**: 61–8. doi: <https://doi.org/10.1148/radiol.11101763>
- Zuley ML, Bandos AI, Ganott MA, Sumkin JH, Kelly AE, Catullo VJ, et al. Digital breast tomosynthesis versus supplemental diagnostic mammographic views for evaluation of noncalcified breast lesions. *Radiology* 2013; **266**: 89–95. doi: <https://doi.org/10.1148/radiol.12120552>
- Morel JC, Iqbal A, Wasan RK, Peacock C, Evans DR, Rahim R, et al. The accuracy of digital breast tomosynthesis compared with coned compression magnification mammography in the assessment of abnormalities found on mammography. *Clin Radiol* 2014; **69**: 1112–6. doi: <https://doi.org/10.1016/j.crad.2014.06.005>
- Spangler ML, Zuley ML, Sumkin JH, Abrams G, Ganott MA, Hakim C, et al. Detection and classification of calcifications on digital breast tomosynthesis and 2D digital mammography: a comparison. *AJR Am J Roentgenol* 2011; **196**: 320–4. doi: <https://doi.org/10.2214/AJR.10.4656>
- Rafferty EA, Durand MA, Conant EF, Copit DS, Friedewald SM, Plecha DM, et al. Breast cancer screening using Tomosynthesis and digital mammography in dense and Nondense breasts. *JAMA* 2016; **315**: 1784–6. doi: <https://doi.org/10.1001/jama.2016.1708>
- D'Orsi, C. J, Mendelson, E. B, Ikeda, D. M, al, e. eds. *Breast Imaging Reporting and Data System: ACR BI-RADS-Breast Imaging Atlas*. Reston, VA: American College of Radiology; 2003.
- Kwan ALC, Boone JM, Yang K, Huang S-Y. Evaluation of the spatial resolution characteristics of a cone-beam breast CT scanner. *Med Phys* 2007; **34**: 275–81. doi: <https://doi.org/10.1118/1.2400830>
- Boone JM, Yang K, Burkett GW, Packard NJ, Huang S-ying, Bowen S, et al. An X-ray computed tomography/positron emission tomography system designed specifically for breast imaging. *Technol Cancer Res Treat* 2010; **9**: 29–43. doi: <https://doi.org/10.1177/153303461000900104>
- Boone JM, dose N glandular. Normalized glandular dose (DgN) coefficients for arbitrary x-ray spectra in mammography: computer-fit values of Monte Carlo derived data. *Med Phys* 2002; **29**: 869–75. doi: <https://doi.org/10.1118/1.1472499>
- Boone JM, Kwan ALC, Seibert JA, Shah N, Lindfors KK, Nelson TR, et al. Technique factors and their relationship to radiation

- dose in pendant geometry breast CT. *Med Phys* 2005; **32**: 3767–76. doi: <https://doi.org/10.1118/1.2128126>
20. Sechopoulos I, Sabol JM, Berglund J, Bolch WE, Brateman L, Christodoulou E, et al. Radiation dosimetry in digital breast tomosynthesis: report of AAPM Tomosynthesis Subcommittee task group 223. *Med Phys* 2014; **41**: 091501. doi: <https://doi.org/10.1118/1.4892600>
21. Aminololama-Shakeri S, Hargreaves JB, Boone JM, Lindfors KK. Dedicated breast CT: screening technique of the future. *Curr Breast Cancer Rep* 2016; **8**: 242–7. doi: <https://doi.org/10.1007/s12609-016-0227-2>
22. Guo B, Yuan Y. A comparative review of methods for comparing means using partially paired data. *Stat Methods Med Res* 2017; **26**: 1323–40. doi: <https://doi.org/10.1177/0962280215577111>
23. Benjamini Y, Hochberg Y. Controlling the false discovery rate: a practical and powerful approach to multiple testing. *Journal of the Royal Statistical Society. Series B* 1995;: 289–300.
24. Kuhl CK, Schrading S, Bieling HB, Wardelmann E, Leutner CC, Koenig R, et al. MRI for diagnosis of pure ductal carcinoma in situ: a prospective observational study. *Lancet* 2007; **370**: 485–92. doi: [https://doi.org/10.1016/S0140-6736\(07\)61232-X](https://doi.org/10.1016/S0140-6736(07)61232-X)
25. Dromain C, Thibault F, Muller S, Rimareix F, Delalogue S, Tardivon A, et al. Dual-energy contrast-enhanced digital mammography: initial clinical results. *Eur Radiol* 2011; **21**: 565–74. doi: <https://doi.org/10.1007/s00330-010-1944-y>
26. Chou C-P, Lewin JM, Chiang C-L, Hung B-H, Yang T-L, Huang J-S, et al. Clinical evaluation of contrast-enhanced digital mammography and contrast enhanced tomosynthesis--Comparison to contrast-enhanced breast MRI. *Eur J Radiol* 2015; **84**: 2501–8. doi: <https://doi.org/10.1016/j.ejrad.2015.09.019>