UCSF
UC San Francisco Previously Published Works

Title
Current understanding of hypospadias: relevance of animal models

Permalink
https://escholarship.org/uc/item/60s7k7n0

Journal
Nature Reviews Urology, 12(5)

ISSN
1759-4812

Authors
Cunha, Gerald R
Sinclair, Adriane
Risbridger, Gail
et al.

Publication Date
2015-05-01

DOI
10.1038/nrurol.2015.57

Peer reviewed

eScholarship.org Powered by the California Digital Library
University of California

Current understanding of hypospadias: relevance of animal models

Gerald R. Cunha, Adriane Sinclair, Gail Risbridger, John Hutson and Laurence S. Baskin

Abstract | Hypospadias is a congenital abnormality of the penile urethra with an incidence of approximately 1:200–1:300 male births, which has doubled over the past three decades. The aetiology of the overwhelming majority of hypospadias remains unknown but appears to be a combination of genetic susceptibility and prenatal exposure to endocrine disruptors. Reliable animal models of hypospadias are required for better understanding of the mechanisms of normal penile urethral formation and hence hypospadias. Mice and/or rats are generally used for experimental modelling of hypospadias, however these do not fully reflect the human condition. To use these models successfully, researchers must understand the similarities and differences between mouse, rat and human penile anatomy as well as the normal morphogenetic mechanisms of penile development in these species. Despite some important differences, numerous features of animal and human hypospadias are shared: the prevalence of distal penile malformations; disruption of the urethral meatus; disruption of urethra-associated erectile bodies; and a common mechanism of impaired epithelial fusion events. Rat and mouse models of hypospadias are crucial to our understanding of hypospadias to ultimately reduce its incidence through better preventive strategies.

Cunha, G. R. *et al. Nat. Rev. Urol.* advance online publication XX Month 2015; doi:10.1038/nrurol.2015.57

Nature Reviews UNCORRECTED PROOF

Introduction

Hypospadias is the second most common congenital anomaly in boys, occurring in approximately 1:200–1:300 male births.[1] The incidence of hypospadias has doubled over the past 3 decades.[2] Treatment of hypospadias remains surgical, and multiple surgeries, especially for more severe forms of hypospadias, are often required to achieve functional and cosmetically acceptable outcomes.[3] Patients with severe hypospadias are at risk of complications leading to lifelong difficulties with urination and sexual function, and an increased risk of psychological problems. Thus, hypospadias is an important health issue, which can be a substantial burden on health-care resources. For most patients with hypospadias, the aetiology remains undefined. However, the leading hypothesis is that a combination of genetic susceptibility and environmental exposure to endocrine disruptors might cause this anomaly.[4,5] Accordingly, if exposure to environmental agents linked to hypospadias is avoided, then the incidence of hypospadias might be reduced.[6,7] Agents that have been implicated in the aetiology of hypospadias based upon epidemiological studies in humans and experimental animal studies include progestins, oestrogens, loratidine and various agents that produce an 'androgen blockade', including phthalates and anti-androgenic fungicides such as vinclozolin and procymidone.[8–18] A persistent question exists concerning the relevance of animal models to human hypospadias.

Competing interests
The authors declare no competing interests.

Fundamentally, hypospadias is an arrest in normal penile development, which can be understood best in the context of normal penile morphology and development. Patients with hypospadias typically have disturbances in penile patterning and malformation and/or abnormal positioning of the urethral meatus,[19] which might be situated distally on the glans, along the penile shaft or in the scrotum or perineum (Figure 1). In patients with hypospadias, three related anomalies are typically observed: a urethral defect, a preputial defect and chordee (abnormal curvature of the penis). About 50% of patients with hypospadias have defects occurring at the glans–shaft junction or distally on the glans.[20] Occurrence of the urethral defect is associated with thinning and absence of, or abortive corpus spongiosum.[19] Accordingly, the urethral defects associated with human hypospadias involve absence of the ventral urethral epithelium, corpus spongiosum and the ventral skin (Figure 2d–f).

A substantial amount of published research on hypospadias exists in both rats and mice. Each animal model has advantages and disadvantages, which will be discussed in detail. The aim of this Review is to define hypospadias in humans, rats and mice, and to discuss the similarities and differences between normal and abnormal development of external genitalia in these species.

Anatomy and development of the penis

Adult mouse, rat and human penile anatomy

The terminology describing the anatomy of the mouse and rat penis is quite different to that used to describe the human penis and must be understood to avoid confusion.

Department of Urology, University of California, San Francisco, 400 Parnassus Avenue, A610, San Francisco, CA 94143, USA. (**G.R.C.**, **A.S.**, **L.S.B.**) Department of Anatomy & Developmental Biology, Monash University, Clayton Campus, Building 76, Level 3, Wellington Road, Clayton, Victoria 3800, Australia (**G.R.**). Urology Department, Royal Children's Hospital, Parkville, Melbourne, Victoria 3052, Australia (**J.H.**).

Correspondence to: G.R.C.
cunhag@urology.ucsf.edu

Key points

- Hypospadias occurs in approximately 1:200–1:300 newborn males, and is the second most common congenital abnormality in boys
- For the overwhelming majority of patients with hypospadias the aetiology remains unknown
- Relevant animal models of hypospadias are needed to improve our understanding of this congenital anomaly
- Development of the mouse, rat and human penis and prepuce involves similar epithelial fusion events and disruption of urethra-associated erectile bodies leading to similar penile and preputial defects
- The ultimate goal of hypospadias research is to prevent or reduce the incidence of hypospadias in humans by defining the underlying environmental causes and genetic susceptibilities

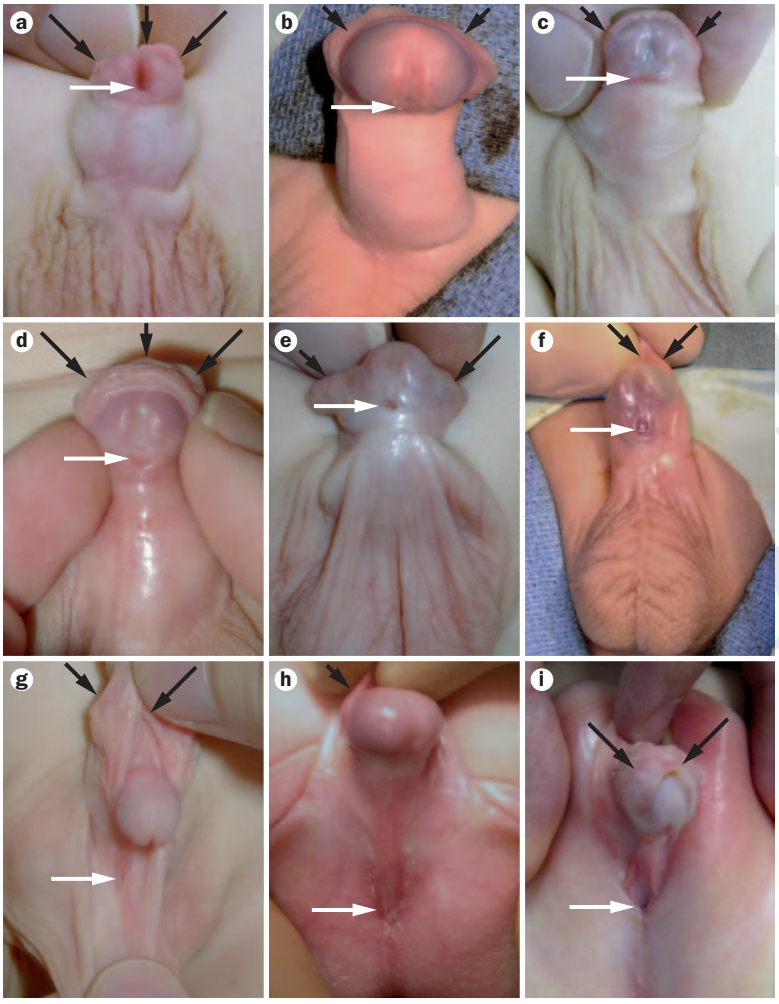

Figure 1 | Examples of human hypospadias. Human hypospadias is defined by an abnormal dorsal hooded foreskin that is deficient ventrally (black arrows) and an abnormal urethral orifice (white arrows) that can be situated on **a** | the dorsal hooded foreskin, **b** | the proximal glans, **c** | the coronal margin, **d**,**e** | the distal penile shaft, **f** | the mid-penile shaft, **g** | the penoscrotal junction, **h** | the scrotum, or **i** | the perineum. Penile curvature (parts g–i) is another commonly observed feature of human hypospadias.

In all species, the external part of the penis projects from the body wall, and the internal part lies beneath the body surface contour. The internal portion of the human penis is comprised of the proximal attachments of erectile bodies. The external or pendulous portion of the human penis is called the shaft or body of the penis and contains the corporal body and corpus spongiosum, which surrounds the urethra (Figures 2a, b). The distal portion of the corpus spongiosum forms the glans, which is small in size relative to the shaft.[21]

The anatomy of the mouse penis is well described, particularly the specialized distal aspect of the glans, which is malformed in hypospadias.[22] In both the mouse and rat the internal portion of the penis is called the body and contains attachments of erectile bodies to the pubic bones (Figure 2c). The external portion of the mouse penis, known as the glans, lies within the preputial space,[22] and contains the os penis and the fibrocartilagenous male urogenital mating protuberance (MUMP) as well as several erectile bodies (the MUMP corpus cavernosa, corpus cavernosum glandis and the corpus cavernosum urethrae) (Figure 3).[22] The murine glans penis is relatively long (in comparison to the human glans) with a proximal shaft and a specialized distal region homologous to the human glans penis (Figures 3, 4a and 5a–c **[Au: Figures re-numbered to reflect order of appearance, OK?]**).[22,23]

Published research describing the anatomy of the rat penis is limited, and information regarding the patterning of individual elements comprising the specialized distal aspect of the glans and the urethral meatus is currently inadequate. However, the rat penis shares some features with that of the mouse. Both mouse and rat penises are housed within a voluminous preputial space whose walls form a prominent elevation in the perineum. However, wholemount photos demonstrate dramatic differences in the gross and microscopic anatomy of the rat versus the mouse penis (Figures 3 and 4). The skeletal elements of the rat penis (like that of the mouse) consist of a proximal os penis and a distal fibrocartilagenous element (the rat homologue of the mouse MUMP) (Figure 4d).[24,25] In mice the fibrocartilagenous MUMP projects distally beyond the urethral meatus (Figure 3 and 4). By contrast, in the rat this fibrocartilagenous distal element lies proximally within the substance of the rat penis in association with the tubular urethra (Figures 4b, d, e). The rat glans contains a corpus cavernosum glandis (Figure 4d, e), but homologies with other mouse erectile bodies (such as the MUMP, corpus cavernosa and the corpus cavernosum urethrae) are yet to be determined. Thus, the morphologic complexity of the distal aspect of the penile glans and associated urethral meatus is substantially different in rats versus mice, and is inadequately described in the rat. Evidence exists that hypospadias-inducing agents such as exogenous oestrogens or 'androgen blockers' not only affect the urethral meatus, but also profoundly affect the spatial patterning and differentiation of many of the internal penile structures in mice.[23,26–28] Such inferences are inconclusive in the rat because current knowledge of normal rat penile morphology is inadequate.

Normal development of the human penis

The penis is a complex organ containing tissues derived from all three germ layers, which are organized in

Nature Reviews Urology

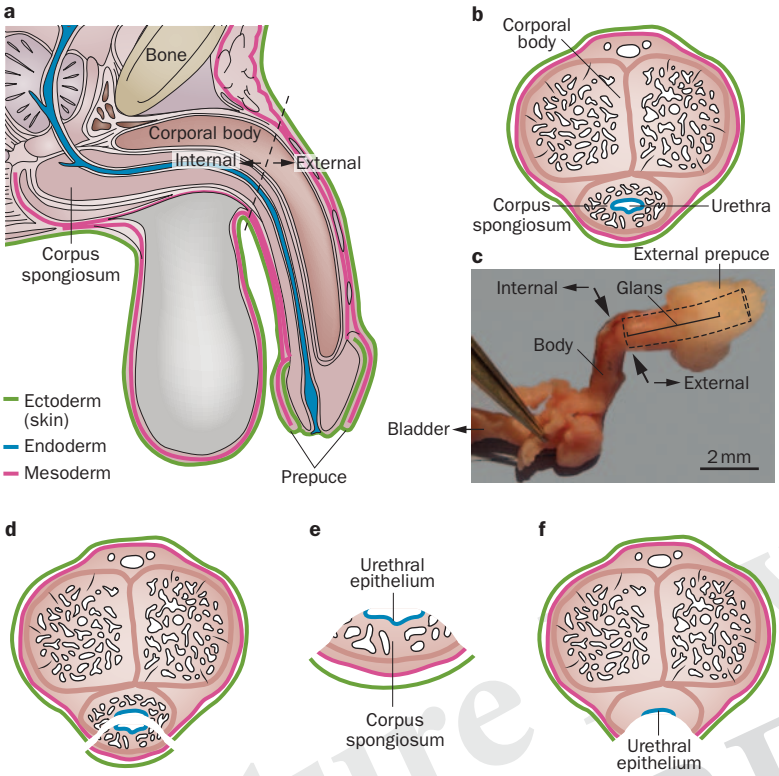

Figure 2 | Penile anatomy and development. Drawings of human penis **a** | in mid-sagittal view and **b** | in transverse section to illustrate germ layer derivation of the components of external genitalia. The urethra (blue) is derived from endoderm. The skin (green) is derived from ectoderm. The exact location of the ectoderm–endoderm junction in humans is still a matter of debate, but is thought to be near the urethral meatus **[Au: choice of colours selected for benefit of those with poor colour perception]**. All structures circumscribed in purple and shaded flesh colour are derived from mesoderm and include erectile bodies, connective tissue, blood vessels, and smooth muscle. **c** | Photograph of a dissected adult mouse penis. Large opposed arrows denote the boundary between the body of the mouse penis, which is situated internally, and the glans, which is situated externally (solid black line) and cannot be seen in this image because it lies within the preputial space (dotted lines). Changes that occur in the hypospadiac human urethra in which the defects involve absence of **d** | the ventral wall of the urethra, **e**,**f** | the corpus spongiosum and the ventral penile skin.

a spatially precise pattern (Figure 2a). According to common embryological theory, penile skin originates from the ectoderm, urethral epithelium is derived from endoderm, and most of the substance of the penis is derived from mesoderm, which forms the corporal bodies, vasculature, connective tissue and dermis.[29] Human external genital development is initiated identically in males and females and results in the formation of three primordial peri-cloacal elevations, the midline genital tubercle and bilateral genital swellings. These undifferentiated structures in both male and female embryos constitute the ambisexual stage of genital development. The genital tubercle is the primordium of both the penis and clitoris. In males the genital swellings fuse to form the scrotum owing to the presence of fetal testicular androgens.[30] At the same time as the male genital tubercle elongates to form the penis, a solid epithelial urethral plate grows distally into the glans and canalizes in a proximal to distal direction to form the urethral groove, which is bounded laterally by the urethral folds.[31] The penile urethra forms as a result of subsequent midline fusion of the urethral folds (Figure 6). Evidence suggests that human hypospadias results from failure of formation or fusion of the urethral folds.[1,31]

Normal development of the mouse penis

Development of external genitalia in mice, like that in humans, involves formation of the ambisexual genital tubercle containing a solid urethral plate. In humans, canalization of the urethral plate creates the urethral groove whose edges (urethral folds) subsequently fuse in the midline to form the penile urethra.[31] The fusion of the urethral folds in humans during development is manifest in adulthood as a ventral penile raphe.[21] By contrast, in mice the urethral plate appears to canalize directly to form most of the penile urethra.[32–34] Nonetheless, a subtle ventral penile raphe is evident in the adult mouse penis (Figure 4a). Raphes are adult manifestations of fetal fusion events; however, the exact origin and importance of the mouse ventral penile raphe has yet to be explained. Postnatally, the mouse urethral meatus appears to develop via fusion events (Figures 7 and 8), similar to those observed in human penile development, with the exception that in the mouse the open distal groove and associated folds should be called the urethral-preputial groove and urethral-preputial folds since fusion of these folds completes development of both the distal urethra, urethral meatus and the prepuce. Thus, we believe that development of the mouse penile urethra occurs in two phases. Prenatally, the penile urethra develops within the genital tubercle, presumably via canalization of the urethral plate to form most of the penile urethra.[32–34] Postnatally, the urethral meatus forms via fusion of elements that constitute the urethral meatus.[35,36] This fusion process is inferred from raphes, midline clefts and processes that define the adult mouse urethral meatus (Figures 4a and 5a–c). These two mechanistic scenarios are not mutually exclusive. Both theories are supported by considerable evidence, but need to be viewed with the understanding that the mechanism of formation of the mouse urethra within the 'penile shaft' (which occurs prenatally) differs from formation of the urethral meatus (which occurs postnatally). Postnatal formation of the mouse urethral meatus appears to involve multiple epithelial fusion events and, therefore, differs substantially from prenatal urethral development within the shaft of the glans.[32–34] In adulthood the mouse urethral meatus is located distally, where the MUMP joins the MUMP ridge (Figures 3 and 7a, b). Thus, the mouse urethral meatus forms postnatally via fusion of the MUMP with the MUMP ridge (Figures 5a, b).[37] The MUMP is known to develop via fusion of bilateral rudiments,[37] and the MUMP ridge has a prominent ventral cleft (Figure 5a), which suggests that the MUMP ridge is formed via fusion of bilateral halves. Critical examination of the MUMP ridge further reveals that it is composed of several processes separated by clefts at various positions around its circumference,

Nature Reviews Urology PROOF

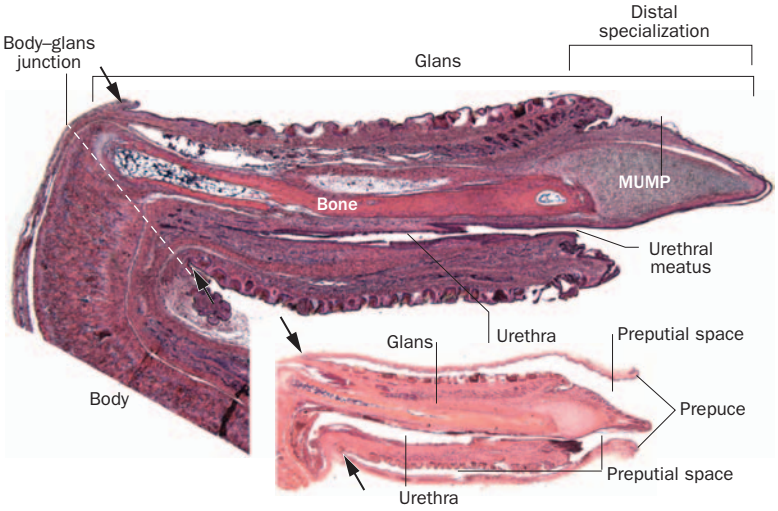

Figure 3 | Mid-sagittal haematoxylin–eosin stained sections of the adult mouse penis. The lower section depicts the glans penis within the proximal portion of the external prepuce and preputial space. Note the proximal attachment of the external prepuce to the penis indicated by the large solid arrows. In the upper section the external prepuce has been removed but large solid arrows indicate its proximal attachment. The junction between the body and the glans, which are situated internally and externally, respectively is indicated by the dashed line. Modified with permission obtained from the Society for the Study of Reproduction © Rodriguez *et al.*[22] *Biol. Reprod.* **85**, 1216–1221 (2011).

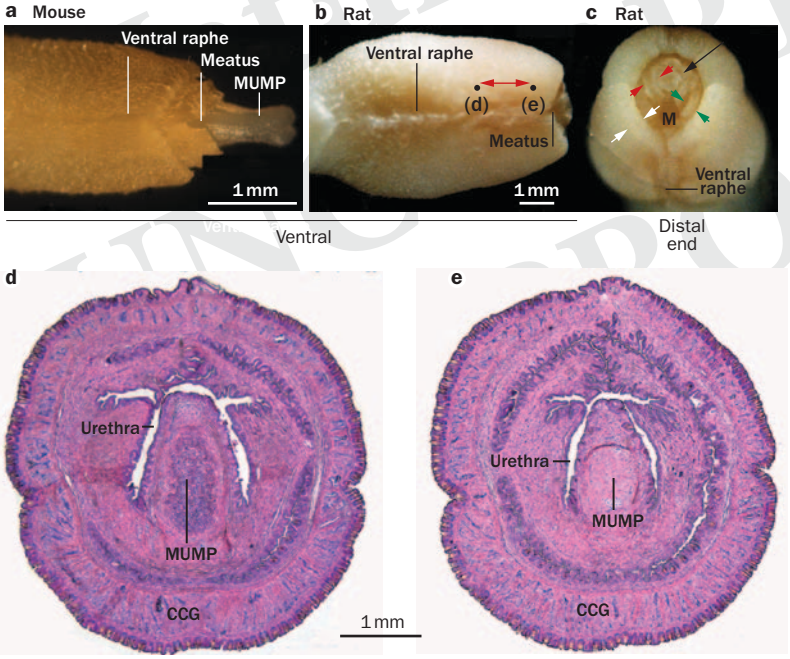

Figure 4 | Gross anatomy and histology of the mouse and rat penis. **a** | Ventral view of the adult mouse penis, note that the MUMP extends ~1 mm beyond the urethral meatus as well as the subtle ventral raphe. **b** | Ventral view of the adult rat penis, which is blunt distally, in part due to the internal localization of the fibrocartilagenous "MUMP". Also note the prominent ventral raphe. **c** | Distal end-on view of the rat penis. Note the presence of several epithelial folds (red, white and green opposed arrowheads). The urethral meatus is indicated by (M). The circular process (long arrow) dorsal to the meatus may be the distal aspect of the "MUMP". **d**,**e** | Histologic haematoxylin–eosin stained sections of the adult rat penis showing the fibrocartilagenous "MUMP", tubular urethra and corpus cavernosum glandis. Positions of sections d | proximal and e | distal are indicated by the dots and the double-headed arrow in b. Abbreviation: CCG, corpus cavernosum glandis; M, meatus; MUMP, male urogenital mating protuberance.

suggesting that the MUMP ridge formed via fusion of several bilateral elements (Figure 5a–c).[23,38] Thus, postnatal development of the mouse urethral meatus and prenatal development of the human penile urethra share a common mechanism, namely, epithelial fusion (Supplementary Table 1).

Preputial development in both humans and mice occurs as a result of initial epithelial–epithelial contact and ventral midline fusion of the urethral-preputial folds (Figures 5 and 7).[39,40] The initial point of epithelial fusion creates a midline epithelial seam, which is subsequently removed to establish midline mesenchymal confluence, thus defining the penile urethra and prepuce (Figures 5 and 7).[35]

Normal development of the rat penis

Development of the rat penis, similar to that of the mouse, begins prenatally and is completed postnatally. By contrast, human penile development occurs exclusively during prenatal periods (complete by 20 weeks gestation), owing to the vast differences in the lengths of gestation in rodents versus humans. Prenatal development of the rat penile urethra occurs via extension of the cloacal lumen along the ventral surface of the genital tubercle to its distal tip, and thus prenatal rat penile urethral development appears not to involve canalization of the urethral plate to form an open urethral groove and subsequent fusion of the urethral folds.[41] However, as in the mouse, postnatal fusion events are likely to be involved in the development of the rat urethral meatus. The prominent ventral penile raphe evident in adult rats (Figure 4b) could, therefore, be a manifestation of fusion events. The significance of the ventral penile raphe in rats and mice is unclear, but is presumably a manifestation of some type of developmental fusion event. The absence of studies on postnatal urethral development in the rat has impeded understanding of the mechanism of formation of the rat urethral meatus. Clearly, for both the rat and mouse, detailed descriptive studies on penile urethral development are required. Given the existence of vast differences between the rat and mouse in terms of both normal adult penile morphology (Figures 3 and 4) and hypospadias, substantial differences in penile morphogenesis are likely to exist in these species. Currently, data on differences in penile development between rats and mice are not sufficient to explain the differences in penile morphology and hypospadias observed in these species.

Mouse and rat hypospadias

Mouse and rat urethral hypospadias can be assessed using a variety of techniques: scanning electron microscopy, macro-photography, serial histological sectioning with or without three-dimensional reconstruction or optical projection tomography. Simple visual examination of adult penises of rats or mice with a dissecting microscope is sufficient to recognize abnormality (hypospadias) of the urethral meatus in fresh or fixed specimens (Figure 5), while other defects in penile morphologic patterning require histological

Nature Reviews UNCORRECTED PROOF

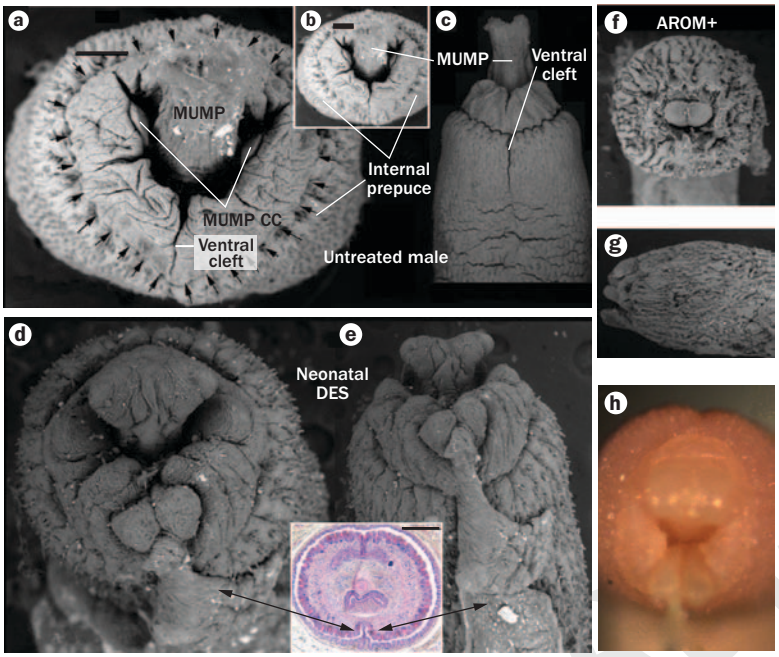

Figure 5 | Scanning electron micrographs of penises from mice with postnatal diethylstilbestrol exposure. **a**,**b**,**c** | Untreated 60-day-old mice. The MUMP and the MUMP ridge (white arrows), together comprise the Y-shaped urethral meatus. The MUMP ridge in turn is composed of several processes (1–4) separated by prominent deep grooves. The MUMP ridge is also split ventrally by a prominent cleft. **d**,**e** | 60-day-old mice treated with diethylstylbestrol (200 ng/g of body weight) from birth to day 10. These processes, grooves and ventral cleft are adult manifestations of a developmental process in which the urethral meatus formed as a result of multiple fusion events between the MUMP and the elements of the MUMP ridge. Striking disturbances in penile pattern include shortening of the MUMP, abnormal size and patterns of MUMP processes, perturbation of fusion between individual MUMP ridge processes, absence of the ventral cleft and the presence of a frenulum-like ventral tether attached to the inner surface of the external prepuce (double headed arrows). Accordingly, the neonatally diethylstylbestrol-treated mouse has a grossly abnormal urethral meatus, which is the definition of hypospadias. **f** | End-on and **g** | side views of the penis of an adult aromatase-overexpressing mouse showing severe truncation of the MUMP and disturbance in the pattern of constituents of the urethral meatus.

examination (Figure 9a, b).[26,27] For example, the teratogenic effects of oestrogen on the urethral meatus can be seen in mice treated neonatally with diethylstilbestrol (DES)[10,26,27] (Figures 5d, e and h) as well as in AROM+ mice expressing both mouse and human aromatases (Figure 5f, g) in which there is a physiological elevation in oestrogens.[42]

Hypospadias in rats and mice can be induced by a variety of agents, which for the most part fall into two categories: oestrogenic agents and androgen-blocking agents. In mouse models of hypospadias, DES is the most commonly used oestrogenic agent, although other oestrogenic compounds can also cause hypospadias in this model.[10] Androgen blockers include antiandrogens such as flutamide, vinclozolin and procymidone[17,43–46] as well as 5α-reductase inhibitors such as finasteride.[47,48] Phthalates, which inhibit testosterone production by the testes, also induce hypospadias in rats.[49–51]

Oestrogen-induced hypospadias has been described mostly in mice, although other teratogenic effects of oestrogens have been described in the rat penis.[28] Oestrogen-induced teratogenic effects on the mouse penis differ somewhat depending on whether exogenous oestrogens are administered prenatally or neonatally.[26,27] Unfortunately, the term 'hypospadias' has been used uncritically in the murine literature to refer to a range of defects, and owing to the pervading image of human hypospadias, the term 'mouse hypospadias' typically conjures the idea of a urethral defect of comparable severity to human midshaft hypospadias, which has rarely, if ever been seen in mice. To ensure clarity, first the precise type of hypospadias must be specified: preputial hypospadias; meatal hypospadias (and abnormal urethral meatus); or midshaft hypospadias. The designation of impaired (or retarded) urethral–preputial fold fusion in embryonic mice as 'hypospadias' is one point of confusion. For example, in a report of ours (and comparable reports of many others) pregnant mice were injected with 17α-ethinyl oestradiol or DES from days 12 to 17 of gestation and analysed at 18 days of gestation.[10] Analysis of serial histological sections revealed an extensive open 'urethral' groove in the embryonic genital tubercle that was designated as hypospadias (Figure 7f–j), with an incidence of 40–57% ($n = 134$), but does this type of malformation merit the term hypospadias? The tacit (but unproven) assumption is that embryonic genital tubercle malformations are irreversible and will progress to enduring adult penile malformations. The fundamental problem with 'embryonic hypospadias' is that in most studies embryonic genital tubercle defects were not allowed to progress to their definitive adult penile phenotypes. In a study utilizing the Kim *et al.*[10] protocol, 57 mice were treated *in utero* with DES from 12 to 17 days of gestation, and then aged to 60 days postnatal. Expected midshaft penile urethral hypospadias was not observed in adulthood ($n = 0/57$) and instead mild malformation of the urethral meatus was observed.[26] Similarly, Iguchi *et al.*[50] reported 'hypospadias' at the end of gestation elicited in mice treated with a 5α-reductase inhibitor, but hypospadias was not found when assessed at 90 days postnatal.[52] In both cases the embryonic genital tubercle malformations diagnosed as 'hypospadias' progressed to normality or to mild adult anomalies. While some embryonic genital tubercle defects reported previously might lead to definitive adult penile urethral malformations, this must be confirmed experimentally upon attainment of sexual maturity. In this regard, of 22 reports of murine 'hypospadias' (Supplementary Table 2), 16/22 studies were diagnosed as 'hypospadias' exclusively in embryonic or neonatal genital tubercles without verifying that the developmental defects actually progressed to adult penile hypospadias. Of the six reports in which mice were examined in adulthood,[11,52–56] adult midshaft urethral hypospadias was adequately documented in only one study, namely mice with impaired reverse ephrin-B2/Eph-B signalling.[54,56] However, germline impairment of ephrin-B2 reverse signalling profoundly affects earlier development of the cloaca, and thus the midshaft hypospadias described by Dravis *et al.*[54] might be a consequence of earlier cloacal

UNCORRECTED PROOF

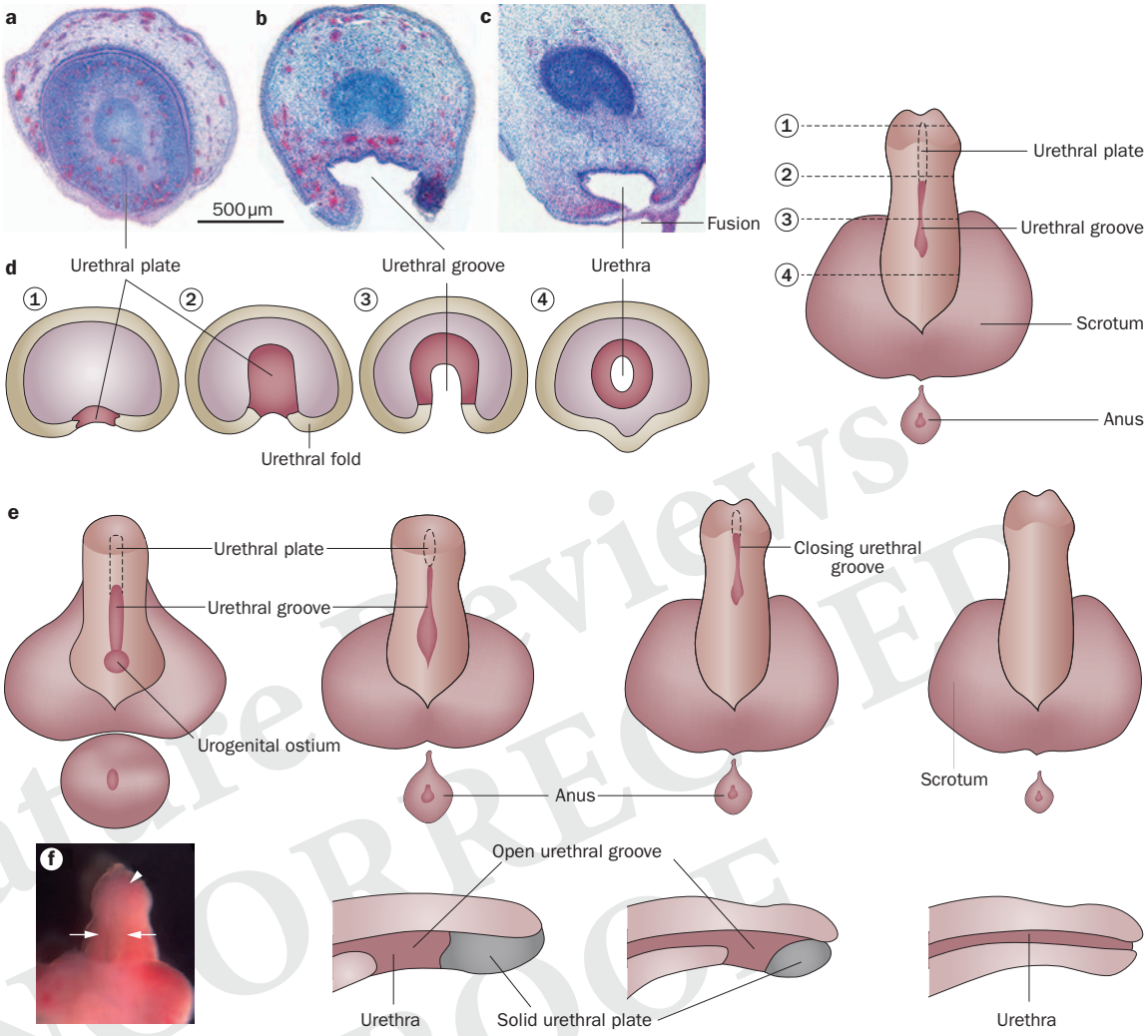

Figure 6 | Human penile urethral development. Transverse sections of the 12-week old human fetal penis showing **a** | the solid epithelial urethral plate (also depicted in diagrams d1 and d2). **b** | Canalized urethral plate and the urethral folds. **c** | Formation of the human urethra as a result of fusion of the urethral folds. **d** | Diagram depicting the solid urethral plate (d1–d2) , an open urethral groove (d3), and fusion of the urethral folds (d4) and mesenchymal confluence across the midline **e** | Diagram depicting proximal to distal fusion of the urethral groove and distal 'retraction' of the urethral plate. **f** | A photograph of a 12-week old human fetal penis. Note the open urethral groove (opposed arrows), and the position of the solid urethral plate (arrowhead). Adapted with permission obtained from Elsevier Ltd © Yamada *et al.*[72] *Differentiation* **71**, 445–460 (2003).

Nature Reviews UNCORRECTED PROOF

malformations having secondary effects on penile development (Supplementary Table 2). The report of adult hypospadias involving knockout of the androgen receptor co-chaperone protein (FKBP52)[55] clearly shows a defective urethral meatus with developmental defects that are consistent with failure of epithelial fusion events.

Interpreting embryonic or neonatal genital tubercle or penile malformations is often difficult, and therefore the best time to diagnose mouse or rat hypospadias is puberty or thereafter (>30 days postnatal), although for the discerning investigator, teratogenic changes seen in the neonatal period can indicate the occurrence of hypospadic development.[38,45] Another critical point is that mouse urethral hypospadias typically involves distal defects affecting the urethral meatus and not mid-shaft malformations (Figure 5). The failure of epithelial fusion events appears to be one of the morphogenetic mechanisms common to mouse and human urethral hypospadias.[1,26,27,35] Thus, while species differences exist in regard to normal penile anatomy, development and development of hypospadias, abnormalities in penile pattern, namely position and morphology of the urethral meatus owing to perturbation of growth, epithelial fusion and other developmental events involving the urethral plate are the essential features of both human and rodent urethral hypospadias.[26,27,32] Mouse urethral hypospadias studies have utilized both prenatal and neonatal DES treatments, which elicit somewhat different malformations, but are both consistent with the designation, meatal hypospadias. Clearly, the severity of the malformation varies with the timing of DES treatment.[26,27] Effects of prenatal or neonatal DES seen in adulthood include defects in the urethral meatus (Figures 5d and e), a defect in the corpus cavernosum

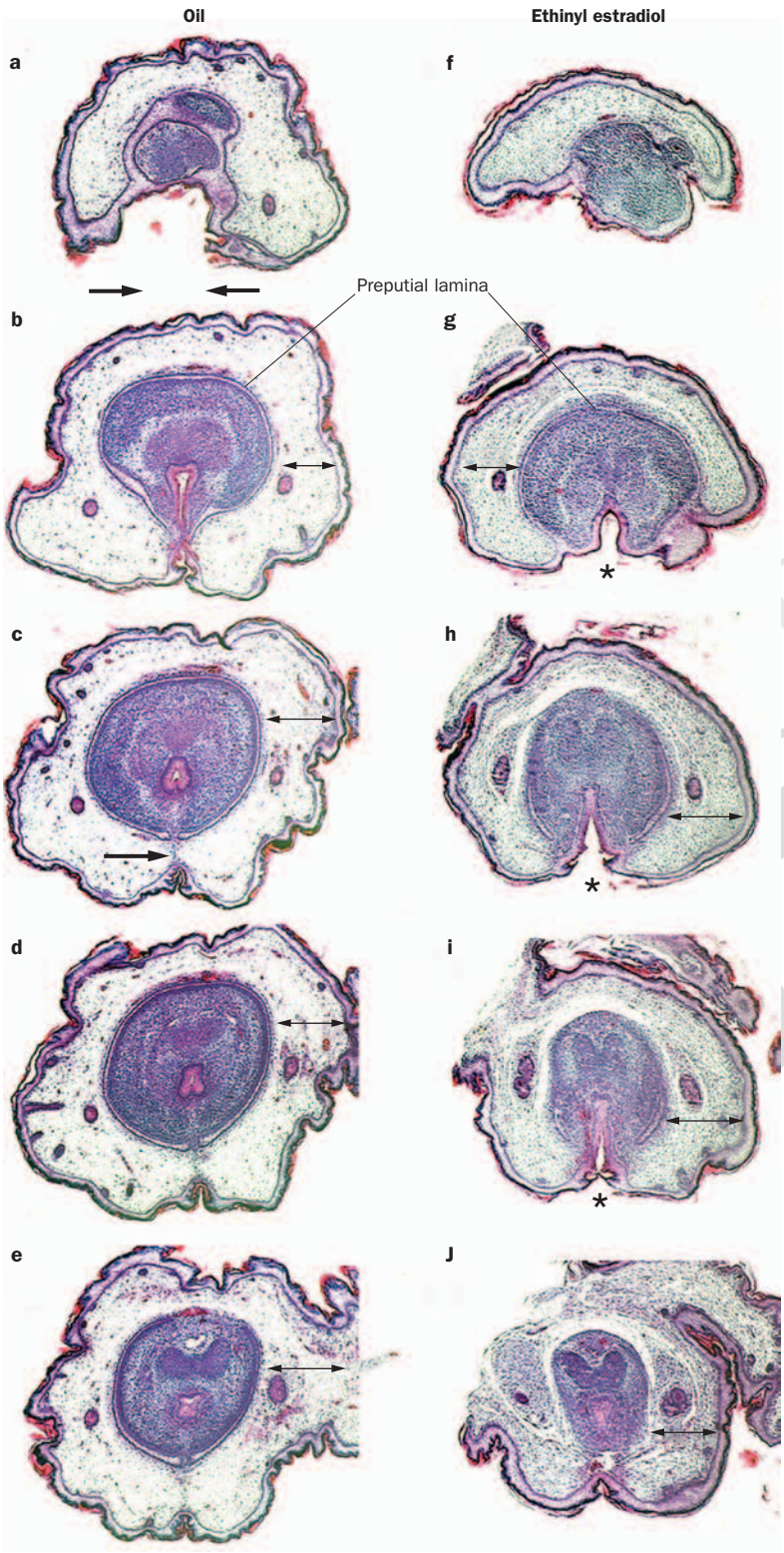

◀ **Figure 7** | Transverse sections through the genital tubercles of 18-day embryonic mice. Mice dams were injected with sesame oil or 17α-ethinyl oestradiol in sesame oil from days 12–17 of gestation and analysed at day 18 of gestation, sections are stained with haematoxylin–eosin. Serial section are from the distal to proximal direction (a–e and f–j). **a** | An open 'preputial/urethral groove,' opposed arrows indicate movement of the 'preputial/urethral folds' towards their fusion in the midline. **b** | Subsequent epithelial seam removal and **c**,**d**,**e** | mesenchymal confluence across the midline. Sections of the ethinyl oestradiol-treated genital tubercle at comparable locations have **f**,**g** | hypoplasia of the 'preputial/urethral folds'. **g**,**h**,**i** | Absence of their midline fusion, and an open 'preputial/urethral groove' designated by (*). Double-headed arrows indicate the external prepuce, asterisk indicates the presence of an open 'preputial/urethral' groove. Adapted with permission obtained from Elsevier Ltd © Kim *et al.*[10] *Environ. Res.* **94**, 267–275 (2004).

urethrae (the homologue of the human corpus spongiosum) (Figures 9a and b), and a defect in the ventral penile skin, manifested as a frenulum-like ventral tether (Figures 5d and e).[23,26,27] In a general sense these features of mouse hypospadias have direct counterparts in human hypospadias (Figures 2d–f), and in both species involve malformation and malpositioning of the urethral meatus.[20,26,27]

Preputial hypospadias in humans, rats and mice is fundamentally a ventral defect in the prepuce (Supplementary Table 3). The human and mouse prepuce forms as a result of fusion of the preputial folds (urethral–preputial folds in the case of the mouse) (Figures 7 and 8).[39,40] Accordingly mouse and human preputial hypospadias appears to result from failure of growth and/or fusion of the preputial folds. In adulthood, murine preputial hypospadias is easily recognized visually (Figures 9c and d).

A substantial amount of published research exists on rat hypospadias, especially in relation to various forms of 'androgen blockade'. However, descriptions of rat hypospadias are generally inadequate and mostly reported as text only, with little detailed description of the nature of the defects. Published wholemount images depict massive ventral shaft openings in the rat urethra, indicating substantial perturbation of normal development.[57] Given the inadequacy of description of adult rat penile anatomy and rat hypospadias, the paucity of studies on rat penile morphogenesis, and the complete absence on the morphogenetic mechanism(s) of rat hypospadias, future research efforts are required to capitalize on this potentially excellent animal model of hypospadias.

Experimental or spontaneous hypospadias in humans, rats and mice is associated with sex steroid hormone action and/or perturbation. Accordingly, the presence of androgen receptors within the developing penis[23,38,58] is an important correlate with hypospadias elicited via perturbation of androgen action.[9,23,38,52,58,59] Likewise, oestrogen induction of hypospadias is reinforced by the presence of oestrogen receptors α and β and aromatase in the developing rodent and human penises.[10,23,28,38,60–64]

Human studies

The case of 'DES sons' is particularly interesting. In a cohort study of 205 male infants exposed *in utero* to DES compared to 8,934 infants without DES exposure, the incidence of hypospadias was increased ~20-fold (prevalence ratio 21.3; 95% CI 6.5–70.1) in infants with *in utero* exposure to DES, although the absolute incidence of

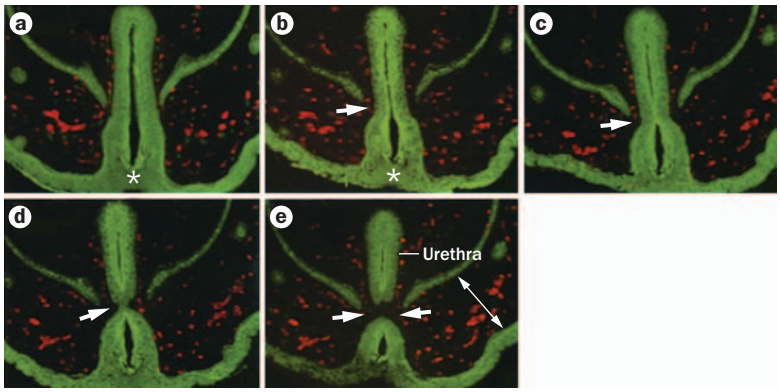

Figure 8 | Sections through an 18-day embryonic mouse genital tubercle. Sections were stained with anti-cytokeratin 8 (green) and smooth muscle α-actin (red) and visualized by epifluorescence. Part a is the most distal and part e is the most proximal. **a** | The preputial/urethral folds have fused to form a ventral epithelial seam (*). **b**,**c**,**d** | A second epithelial fusion and seam (white arrows) have formed to separate the urethra from the prepuce. **e** | The epithelial seam has disappeared establishing midline mesenchymal confluence (opposed white arrows), and segregating the urethral epithelium from other epithelia. Note the appearance of the prepuce (double-headed arrow) Adapted with permission obtained from Springer Science+Business Media © Baskin *et al*.[35] (2004). *Cell Tissue Res.* **305**, 379–387 (2001).

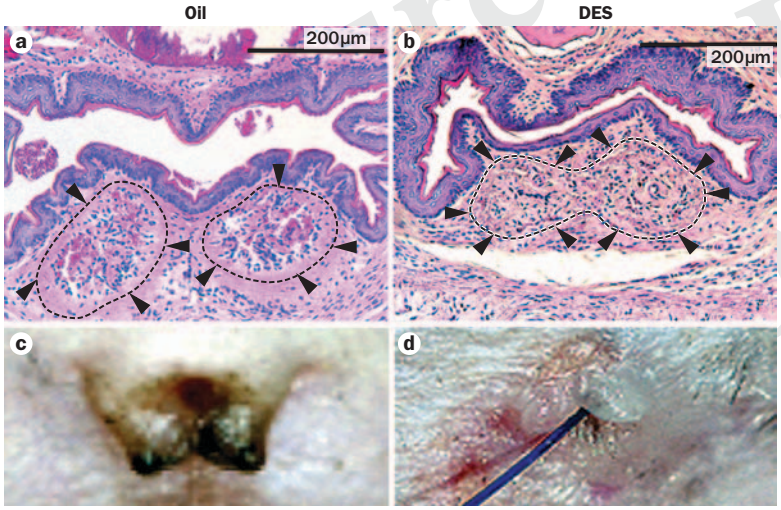

Figure 9 | Development of the distal adult mouse urethra. CD-1 mice were treated from birth to day 10 with **a** | sesame oil or **b** | DES (200ng/gbw), sections were analysed using haematoxylin–eosin staining. Corpus cavernosa urethrae are well demarcated (arrowheads) by smooth muscle in oil-treated mice, but are amorphous in DES-treated mice. **c**,**d** | Photographs of external prepuces of adult C57/6 mice treated from birth to day 10 with oil or DES (200ng/gbw). DES treatment profoundly impaired preputial development. Blue suture denotes the opening of the preputial space. Abbreviation: DES, diethylstylbestrol. Reproduced with permission obtained from Elsevier Ltd © Mahawong *et al*.[27] *Differentiation* **88**, 70–83 (2014).

hypospadias was limited to only four of the 205 boys with *in utero* exposure to DES.[60] These findings suggest that induction of hypospadias in humans requires genetic susceptibility, as well as exposure to an eliciting agent such as DES. A lower than expected incidence of hypospadias was observed in boys with exposure to DES *in utero*, therefore, it seems unlikely that hypospadias will be a consistent finding in the small cohorts of humans with genetic disorders affecting sex steroid production or action. Although, in patients with autosomal recessive 5α-reductase deficiency the incidence of hypospadias is 100%.[9] This latter finding emphasizes the risks associated with exposure to 'antiandrogenic' agents.

Studies from the past 10 years[63–69] have better defined the genes associated with hypospadias. A genome-wide association study of pooled DNA samples from 436 individuals with hypospadias and 494 without revealed a strong association between two common variants of diacylglycerol kinaseκ(*DGKK*; rs1934179 and rs7063116). However, the function of *DGKK* in urethral development remains unknown.[65] An even larger genome-wide association study of >1,000 patients with hypospadias identified associations between a number of genes that are known to have key roles in embryonic development and hypospadias, including *HOXA4*, *IRX5*, *IRX6* and *EYA1*.[66] Gene array studies of human preputial tissue from patients with hypospadias have identified a number of genes with altered expression patterns compared to foreskin tissue from individuals without hypospadias, which might have a role in development of hypospadias.[67] These genes include *CYR61*, *CTGF*, *ATF3* and *ZEB1*, which are known to be responsive to oestrogen. Expression studies in human urethral tissue have shown that *ZEBI* and *ATF3* are especially promising candidates, owing to their known localization within the developing urethra.[68–70] Conclusive data regarding protein expression and function in human tissue are currently limited to a possible association of hypospadias with *ATF3* overexpression[68] and *ZEB1* mutations.[69,70] A number of defects in single genes such as *ATF3*, *CTGF*, *CYR61*, *ZEB1*, *EGF*, *WT1*, *SF1*, *BMP4*, *BMP7*, *HOXA4*, *HOXB6*, *FGF8*, *FGFR2*, *AR*, *HSD3B2*, *SRD5A2* and *MAMLD1* have been associated with hypospadias.[71] Further genetic studies are required in order to fully understand the basis of genetic susceptibility to hypospadias.

Conclusions

To further the field of hypospadias research, and ultimately to prevent or reduce the occurrence of this serious congenital anomaly first requires well-defined and reproducible experimental animal models. Herein, we have defined hypospadias in mouse and rat models and documented numerous features that are analogous to human hypospadias as well as differences. Hopefully, future investigations will benefit from a more precise definition of mouse and rat hypospadias, making the ultimate goal of preventing this abnormality more obtainable. Currently, attempts to identify all the mutated genes that predispose to hypospadias, and the causative environmental agents that should be avoided during pregnancy are likely to have merely scratched the surface.

The development of reliable, relevant and adequately described animal models will enable a better understanding of the morphogenetic and molecular mechanisms of hypospadias. Following development of such models, strategies could be designed to better identify genetic susceptibilities and to prevent prenatal exposure to oestrogenic compounds and/or other toxic environmental agents.

Nature Reviews Urology PROOF

1. Baskin, L. S. Hypospadias and urethral development. *J. Urol.* **163**, 951–956 (2000).
2. Paulozzi, L. J., Erickson, J. D. & Jackson, R. J. Hypospadias trends in two US surveillance systems. *Pediatrics* **100**, 831–834 (1997).
3. Lee, O. T., Durbin-Johnson, B. & Kurzrock, E. A. Predictors of secondary surgery after hypospadias repair: a population based analysis of 5,000 patients. *J. Urol.* **190**, 251–255 (2013).
4. Kalfa, N., Philibert, P., Baskin, L. S. & Sultan, C. Hypospadias: interactions between environment and genetics. *Mol. Cell. Endocrinol.* **335**, 89–95 (2011).
5. Yiee, J. H. & Baskin, L. S. Environmental factors in genitourinary development. *J. Urol.* **184**, 34–41 (2010).
6. Willingham, E. & Baskin, L. S. Candidate genes and their response to environmental agents in the etiology of hypospadias. *Nat. Clin. Pract. Urol.* **4**, 270–279 (2007).
7. Baskin, L. S. Can we prevent hypospadias? *Fertil. Steril.* **89**, e39 (2008).
8. Buckley, J., Willingham, E., Agras, K. & Baskin, L. S. Embryonic exposure to the fungicide vinclozolin causes virilization of females and alteration of progesterone receptor expression *in vivo*: an experimental study in mice. *Environ. Health* **5**, 4 (2006).
9. Imperato-McGinley, J. 5α Reductase deficiency in man. *Prog. Cancer Res. Therap.* **31**, 491–496 (1984).
10. Kim, K. S. *et al.* Induction of hypospadias in a murine model by maternal exposure to synthetic estrogens. *Environ. Res.* **94**, 267–275 (2004).
11. Kojima, Y. *et al.* Spermatogenesis, fertility and sexual behavior in a hypospadiac mouse model. *J. Urol.* **167**, 1532–1537 (2002).
12. Willingham, E. *et al.* Steroid receptors and mammalian penile development: an unexpected role for progesterone receptor? *J. Urol.* **176**, 728–733 (2006).
13. Willingham, E., Agras, K., Vilela, M. & Baskin, L. S. Loratadine exerts estrogen-like effects and disrupts penile development in the mouse. *J. Urol.* **175**, 723–726 (2006).
14. Carmichael, S. L. *et al.* Maternal progestin intake and risk of hypospadias. *Arch. Pediatr. Adolesc. Med.* **159**, 957–962 (2005).
15. Ormond, G. *et al.* Endocrine disruptors in the workplace, hair spray, folate supplementation, and risk of hypospadias: case-control study. *Environ. Health Perspect.* **117**, 303–307 (2009).
16. Swan, S. H. *et al.* Decrease in anogenital distance among male infants with prenatal phthalate exposure. *Environ. Health Perspect.* **113**, 1056–1061 (2005).
17. Ostby, J. *et al.* The fungicide procymidone alters sexual differentiation in the male rat by acting as an androgen-receptor antagonist *in vivo* and *in vitro*. *Toxicol. Ind. Health* **15**, 80–93 (1999).
18. Rider, C. V. *et al.* Cumulative effects of *in utero* administration of mixtures of "antiandrogens" on male rat reproductive development. *Toxicologic Pathol.* **37**, 100–113 (2009).
19. Baskin, L. S., Erol, A., Li, Y. W. & Cunha, G. R. Anatomical studies of hypospadias. *J. Urol.* **160**, 1108–1115 (1998).
20. Baskin, L. S. & Ebbers, M. B. Hypospadias: anatomy, etiology, and technique. *J. Pediatr. Surg.* **41**, 463–472 (2006).
21. Clemente, C. D. (ed.) *Gray's Anatomy* (Lea & Febiger, 1985).
22. Rodriguez, E., Jr. *et al.* New insights on the morphology of adult mouse penis. *Biol. Reprod.* **85**, 1216–1221 (2011).
23. Blaschko, S. D. *et al.* Analysis of the effect of estrogen/androgen perturbation on penile development in transgenic and diethylstilbestrol-treated mice. *Anat. Rec. (Hoboken)* **296**, 1127–1141 (2013).
24. Beresford, W. A. & Burkart, S. The penile bone and anterior process of the rat in scanning electron microscopy. *J. Anat.* **124**, 589–597 (1977).
25. Izumi, K., Yamaoka, I. & Murakami, R. Ultrastructure of the developing fibrocartilage of the os penis of rat. *J. Morphol.* **243**, 187–191 (2000).
26. Mahawong, P. *et al.* Prenatal diethylstilbestrol induces malformation of the external genitalia of male and female mice and persistent second-generation developmental abnormalities of the external genitalia in two mouse strains. *Differentiation* **88**, 51–69 (2014).
27. Mahawong, P. *et al.* Comparative effects of neonatal diethylstilbestrol on external genitalia development in adult males of two mouse strains with differential estrogen sensitivity. *Differentiation* **88**, 70–83 (2014).
28. Goyal, H. O., Braden, T. D., Williams, C. S. & Williams, J. W. Role of estrogen in induction of penile dysmorphogenesis: a review. *Reproduction* **134**, 199–208 (2007).
29. Moore, K. L. & Persaud, T. V. N. The Developing Human (Saunders, 2003).
30. Sadler, T. W. Langman's Medical Embryology (Lippincott Williams & Wilkins, 2004).
31. Li, Y. *et al.* Canalization of the urethral plate precedes fusion of the urethral folds during male penile urethral development: the double zipper hypothesis. *J. Urology* http://dx.doi.org/10.1016/j.juro.2014.09.108.
32. Seifert, A. W., Harfe, B. D. & Cohn, M. J. Cell lineage analysis demonstrates an endodermal origin of the distal urethra and perineum. *Dev. Biol.* **318**, 143–52 (2008).
33. Hynes, P. J. & Fraher, J. P. The development of the male genitourinary system: II. The origin and formation of the urethral plate. *Br. J. Plast. Surg.* **57**, 112–121 (2004).
34. Hynes, P. J. & Fraher, J. P. The development of the male genitourinary system: III. The formation of the spongiose and glandar urethra. *Br. J. Plast. Surg.* **57**, 203–14 (2004).
35. Baskin, L. S. *et al.* Urethral seam formation and hypospadias. *Cell Tissue Res.* **305**, 379–387 (2001).
36. Yucel, S., Cavalcanti, A. G., Desouza, A., Wang, Z. & Baskin, L. S. The effect of oestrogen and testosterone on the urethral seam of the developing male mouse genital tubercle. *BJU Int.* **92**, 1016–1021 (2003).
37. Schlomer, B. J. *et al.* Sexual differentiation in the male and female mouse from days 0 to 21: a detailed and novel morphometric description. *J. Urol.* **190**, 1610–1617 (2013).
38. Rodriguez, E. Jr *et al.* Specific morphogenetic events in mouse external genitalia sex differentiation are responsive/dependent upon androgens and/or estrogens. *Differentiation* **84**, 269–279 (2012).
39. Perriton, C. L., Powles, N., Chiang, C., Maconochie, M. K. & Cohn, M. J. Sonic hedgehog signaling from the urethral epithelium controls external genital development. *Dev. Biol.* **247**, 26–46 (2002).
40. Petiot, A., Perriton, C. L., Dickson, C. & Cohn, M. J. Development of the mammalian urethra is controlled by Fgfr2-IIIb. *Development* **132**, 2441–2450 (2005).
41. Kluth, D., Fiegel, H. C., Geyer, C. & Metzger, R. Embryology of the distal urethra and external genitals. *Semin. Pediatr. Surg.* **20**, 176–187 (2011).
42. Li, X. *et al.* Altered structure and function of reproductive organs in transgenic male mice overexpressing human aromatase. *Endocrinology* **142**, 2435–2442 (2001).
43. Foster, P. M. & Harris, M. W. Changes in androgen-mediated reproductive development in male rat offspring following exposure to a single oral dose of flutamide at different gestational ages. *Toxicol. Sci.* **85**, 1024–1032 (2005).
44. Gray, L. E. *et al.* Effects of environmental antiandrogens on reproductive development in experimental animals. *Hum. Reprod. Update* **7**, 248–264 (2001).
45. Christiansen, S. *et al.* Combined exposure to anti-androgens causes markedly increased frequencies of hypospadias in the rat. *Int. J. Androl.* **31**, 241–248 (2008).
46. Christiansen, S. *et al.* Synergistic disruption of external male sex organ development by a mixture of four antiandrogens. *Environ. Health Perspect.* **117**, 1839–1846 (2009).
47. Bowman, C. J., Barlow, N. J., Turner, K. J., Wallace, D. G. & Foster, P. M. Effects of *in utero* exposure to finasteride on androgen-dependent reproductive development in the male rat. *Toxicol. Sci.* **74**, 393–406 (2003).
48. Clark, R. L. *et al.* Critical developmental periods for effects on male rat genitalia induced by finasteride, a 5 α-reductase inhibitor. *Toxicol. Appl. Pharmacol.* **119**, 34–40 (1993).
49. Fisher, J. S., Macpherson, S., Marchetti, N. & Sharpe, R. M. Human 'testicular dysgenesis syndrome': a possible model using in-utero exposure of the rat to dibutyl phthalate. *Hum. Reprod.* **18**, 1383–1394 (2003).
50. Foster, P. M. Disruption of reproductive development in male rat offspring following *in utero* exposure to phthalate esters. *Int. J. Androl.* **29**, 140–147 (2006).
51. Klinefelter, G. R. *et al.* Novel molecular targets associated with testicular dysgenesis induced by gestational exposure to diethylhexyl phthalate in the rat: a role for estradiol. *Reproduction* **144**, 747–761 (2012).
52. Iguchi, T., Uesugi, Y., Takasugi, N. & Petrow, V. Quantitative analysis of the development of genital organs from the urogenital sinus of the fetal male mouse treated prenatally with a 5 α-reductase inhibitor. *J. Endocrinol.* **128**, 395–401 (1991).
53. Silversides, D. W., Price, C. A. & Cooke, G. M. Effects of short-term exposure to hydroxyflutamide *in utero* on the development of the reproductive tract in male mice. *Can. J. Physiol. Pharmacol.* **73**, 1582–1588 (1995).
54. Dravis, C. *et al.* Bidirectional signaling mediated by ephrin-B2 and EphB2 controls urorectal development. *Dev. Biol.* **271**, 272–290 (2004).
55. Yong, W. *et al.* Essential role for Co-chaperone Fkbp52 but not Fkbp51 in androgen receptor-mediated signaling and physiology. *J. Biol. Chem.* **282**, 5026–5036 (2007).
56. Yucel, S., Dravis, C., Garcia, N., Henkemeyer, M. & Baker, L. A. Hypospadias and anorectal malformations mediated by Eph/ephrin signaling. *J. Pediatr. Urol.* **3**, 354–363 (2007).
57. Jiang, J., Ma, L., Yuan, L., Wang, X. & Zhang, W. Study on developmental abnormalities in hypospadiac male rats induced by maternal exposure to di-n-butyl phthalate (DBP). *Toxicology* **232**, 286–293 (2007).
58. Sajjad, Y., Quenby, S., Nickson, P., Lewis-Jones, D. I. & Vince, G. Immunohistochemical localization of androgen receptors in the urogenital tracts of human embryos. *Reproduction* **128**, 331–339 (2004).
59. Silver, R. I. *et al.* Expression and regulation of steroid 5 α-reductase 2 in prostate disease. *J. Urol.* **152**, 433–437 (1994).

Uncorrected Proof

60. Klip, H. *et al.* Hypospadias in sons of women exposed to diethylstilbestrol *in utero*: a cohort study. *Lancet* **359**, 1102–1107 (2002).
61. Crescioli, C. *et al.* Expression of functional estrogen receptors in human fetal male external genitalia. *J. Clin. Endocrinol. Metab.* **88**, 1815–1824 (2003).
62. Berkovitz, G. D., Fujimoto, M., Brown, T. R., Brodie, A. M. & Migeon, C. J. Aromatase activity in cultured human genital skin fibroblasts. *J. Clin. Endocrinol. Metab.* **59**, 665–671 (1984).
63. Jesmin, S. *et al.* Aromatase is abundantly expressed by neonatal rat penis but downregulated in adulthood. *J. Mol. Endocrinol.* **33**, 343–359 (2004).
64. Yonezawa, T., Higashi, M., Yoshioka, K. & Mutoh, K. Distribution of aromatase and sex steroid receptors in the baculum during the rat life cycle: effects of estrogen during the early development of the baculum. *Biol. Reprod.* **85**, 105–112 (2011).
65. van der Zanden, L. F. *et al.* Common variants in DGKK are strongly associated with risk of hypospadias. *Nat. Genet.* **43**, 48–50 (2011).
66. Geller, F. *et al.* Genome-wide association analyses identify variants in developmental genes associated with hypospadias. *Nat. Genet.* **46**, 957–963 (2014).
67. Wang, Z. *et al.* Up-regulation of estrogen responsive genes in hypospadias: microarray analysis. *J. Urol.* **177**, 1939–1946 (2007).
68. Liu, B. *et al.* Activating transcription factor 3 is up-regulated in patients with hypospadias. *Pediatr. Res.* **58**, 1280–1283 (2005).
69. Qiao, L., Tasian, G. E., Zhang, H., Cunha, G. R. & Baskin, L. ZEB1 is estrogen responsive *in vitro* in human foreskin cells and is over expressed in penile skin in patients with severe hypospadias. *J. Urol.* **185**, 1888–1893 (2011).
70. Kalfa, N. *et al.* Genomic variants of ATF3 in patients with hypospadias. *J. Urol.* **180**, 2183–2188 (2008).
71. van der Zanden, L. F. *et al.* Aetiology of hypospadias: a systematic review of genes and environment. *Hum. Reprod. Update* **18**, 260–283 (2012).
72. Yamada, G., Satoh, Y., Baskin, L. S. & Cunha, G. R. Cellular and molecular mechanisms of development of the external genitalia. *Differentiation* **71**, 445–460 (2003).

Acknowledgements
This work was supported by NSF Grant IOS-0920793 and NIH grant RO1 DK0581050.

Author contributions
All authors researched data for the article and provided a substantial contribution to discussions of content. G.R.C., AS., G.R., J.H. and L.S.B. all contributed equally to writing the article, and to reviewing and/or editing the manuscript before submission.

Nature Reviews UNCORRECTED PROOF