

# UC Davis

## UC Davis Previously Published Works

### Title

A reminder of peristalsis as a useful tool in the prenatal differential diagnosis of abdominal cystic masses

### Permalink

<https://escholarship.org/uc/item/60t1s4fx>

### Journal

Journal of Ultrasonography, 17(69)

### ISSN

2084-8404

### Authors

Gerscovich, Eugenio O  
Sekhon, Simran  
Loehfelm, Thomas W  
et al.

### Publication Date

2017-06-30

### DOI

10.15557/jou.2017.0019

Peer reviewed

**Submitted:**  
27.01.2017  
**Accepted:**  
28.03.2017  
**Published:**  
30.06.2017

## A reminder of peristalsis as a useful tool in the prenatal differential diagnosis of abdominal cystic masses

Eugenio O. Gerscovich, Simran Sekhon, Thomas W. Loehfelm,  
Sandra L. Wootton-Gorges, Adam Greenspan

*Department of Radiology, UC Davis Health, Sacramento, California*

*Correspondence: Eugenio O. Gerscovich, MD, Department of Radiology University of California, Davis Medical Center, 4860 Y Street, Suite 3100, Sacramento, CA 95817, tel.: (916) 734-0371, fax: (916) 734-6548, e-mail: eogerscovich@ucdavis.edu*

DOI: 10.15557/JouU.2017.0019

### Keywords

enteric duplication cyst,  
fetal abdominal  
masses,  
congenital  
abnormalities,  
prenatal diagnosis,  
ultrasound

### Abstract

With routine antenatal ultrasound and recent advances in ultrasound technology, fetal intraabdominal cystic masses are recognized more often and are better characterized than in the past. They may be classified as solid and cystic, and may originate from multiple structures. When considering the extensive differential diagnosis of cystic masses, the observation of peristalsis narrows the possibilities to the gastrointestinal tract. To find this feature on ultrasound, the examiner must expressly think and look for it, otherwise it may be missed. Our case report illustrates one of those cases.

### Case report

A 33-year-old gravida 4, para 3, term 3 woman was transferred to our medical center for obstetrical care with a dichorionic diamniotic twin pregnancy at a gestational age of 29 weeks 4 days. Provided transfer history indicated symmetrical growth of both twins and a 1 cm mass near the right kidney of fetus A, found on ultrasound examination at a gestational age of 21 weeks. The immediately previous pregnancy was associated with gestational diabetes mellitus that was managed by diet.

Physical examination at our institution indicated the patient had a Body Mass Index (BMI) of 30.45 kg/m<sup>2</sup>. Laboratory tests showed glycosuria. Noninvasive Prenatal Testing (NIPT) indicated a low risk for chromosomal abnormalities.

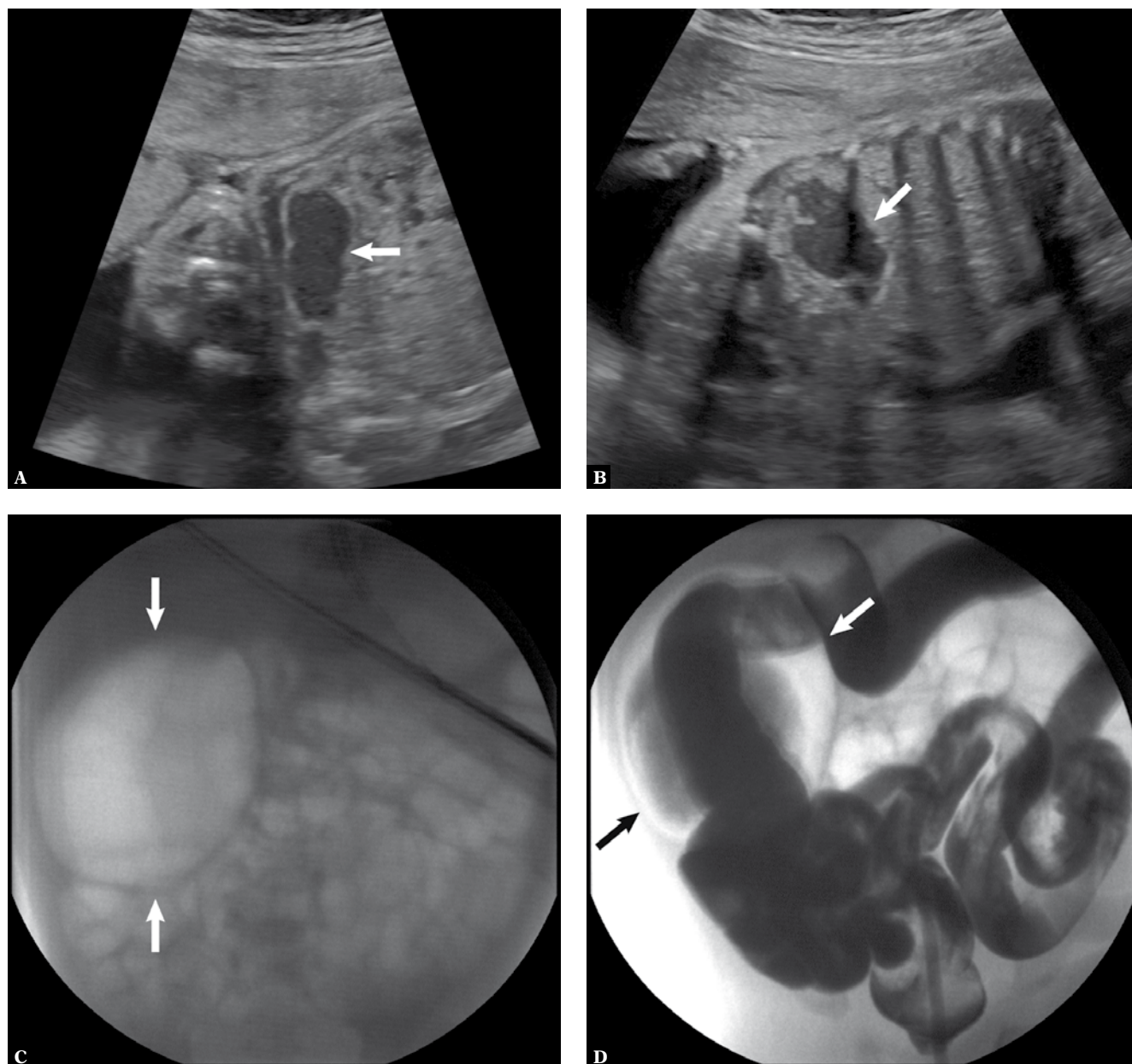
Our initial ultrasound examination at a clinical gestational age (EMA) of 30 weeks 5 days (29 weeks 6 days by ultrasound) was unremarkable except for a tubular cystic structure in the sub hepatic region of fetus A, measuring 3.2 × 1.5 cm. On careful examination, that structure showed peristalsis (Fig. 1 A, B). Follow-up ultrasound examination at a clinical EMA of 32 weeks 4 days (31 weeks 1 day by ultrasound) showed adequate

fetal growth, variable presentation and growth of the lesion to a size of 4.9 × 1.8 cm. Peristalsis of the lesion was again observed. Intraluminal fluid in the lesion was slightly echogenic. (Video clips available in the electronic version).

At no time was there dilation of bowel, abdominal free fluid, or calcifications. Gallbladder was normal. Diagnostic considerations included intestinal duplication, atresia, stenosis, and Meckel diverticulum.

The patient developed premature uncontrolled contractions and an uneventful cesarean section was performed at a gestational age of 35 weeks 3 days. At delivery, Fetus A, the one of concern, was a boy with an Apgar score of 7 at 1 minute and of 9 at 5 minutes. Fetal weight was 2385 grams. Physical examination of the newborn showed a soft abdomen, no tenderness, no palpable mass and adequate bowel sounds.

A nonionic contrast enema was performed on the same day. Preliminary image showed a gas-distended structure (corresponding to the fluid filled ultrasound finding) in the right hemi abdomen with an otherwise normal intestinal gas pattern (Fig. 1 C). Instillation of contrast showed no abnormalities of colon and distal ileum. When the con-



**Fig. 1.** Intestinal duplication. **A.** Fetus at EMA of 29 weeks 6 days. Ultrasound demonstrates the lesion at rest (arrow). **B.** Lesion (arrow) during peristalsis. **C.** One-day-old newborn. Abdominal radiograph shows gas in the lesion (arrows) with an otherwise normal gas pattern **D.** Contrast enema shows opacification of the colon and a large portion of the small bowel. The contrast also entered the lesion (arrows)

trast column reached the mid ileum, it entered the lesion (Fig. 1 D).

On the next day, the newborn underwent exploratory laparotomy; a focal dilation of the proximal ileum with adhesions to the adjacent structures was found and resected. Agreeing with the imaging studies, no proximal bowel obstruction was observed. Pathology evaluation of the resected specimen indicated a 10.2 cm-long segment of small bowel with a maximum transverse diameter of 3.2 cm. On the scout radiograph, previous to the

contrast enema, the gas distended focal dilation measured 5 × 4.3 cm. Both ends of the lesion were open and patent, and the lumen contained viscous brown material. All intestinal layers, including ganglion cells were present. It was reported as consistent with intestinal duplication.

Postoperative recovery was unremarkable and the newborn was discharged on the 16<sup>th</sup> postoperative day.

## Discussion

With routine antenatal ultrasound and recent advances in ultrasound technology, fetal intraabdominal cystic masses are recognized more often and are better characterized than in the past. The differential includes several possibilities, based upon the suspected structure of origin, as well as fetal gender. The masses can be further divided in 2 groups: those observed in the first trimester and those in the late second and third trimesters.

Abdominal cystic lesions in the first trimester are uncommon, generally have a good prognosis and may resolve spontaneously. The majority are isolated abnormalities, but they have been associated with other structural abnormalities, such as anorectal malformation, choledochal cysts, hepatic cysts, ileal duplication, and even fetal death<sup>(1)</sup>. In one study, a cyst was observed at a gestational age of 14–16 weeks and resolved afterwards, but the newborn subsequently developed a midgut volvulus at the age of 7 months<sup>(2)</sup>.

Cystic lesions in the late second and third trimesters are also infrequent and may originate from practically any organ. Kidneys are one of the most common, including multicystic dysplasia or duplication of the collecting system. Other organs of origin include the adrenal glands, liver, spleen, peritoneum, omentum, etc.<sup>(3)</sup>

Choledochal cysts are seen in the subhepatic region in association with the gallbladder or bile ducts. Ovarian cysts in female fetuses are usually functional, benign, and unlikely to appear before 23 weeks. They are usually simple and single, but may be bilateral. They show great mobility and may be found anywhere in the abdomen<sup>(3)</sup>. Megacystis is a dilation of the bladder usually associated with posterior urethral valves in male fetuses. Because of the urinary obstruction, associated oligohydramnios is frequent<sup>(4)</sup>. Within the gastrointestinal tract, duodenal atresia is the most common cause of perinatal intestinal obstruction. It exhibits a classic “double bubble” sign and is associated with Down syndrome in 30% of cases. It may be associated with other gastrointestinal malformations, such as esophageal atresia<sup>(5)</sup>. Mesenteric, omental and peritoneal cysts are considered to represent lymphatic hamartomas and are usually solitary. Lymphangioma should be considered along the same line<sup>(6)</sup>. Urachal cysts can be suspected by their location and association with the urinary bladder. Meconium pseudocysts originate from intestinal perforation and are the result of chemical peritonitis. They are associated with ascites and peritoneal calcifications. They demonstrate thick walls. Dilated bowel, hydrops and polyhydramnios are common<sup>(7)</sup>. Meckel’s diverticulum is one of the most common congenital abnormalities of the gastrointestinal tract observed in 2% of the population. It contains all layers of the GI tract and in up to 50% of cases it may have heterotopic gastric tissue with its associated possible complications. It may show peristalsis and can cause intestinal obstruction<sup>(8)</sup>.

Gastrointestinal (GI) duplication cyst can occur at any location of the tract, but it is more common in the jejunum and ileum, and represents an embryological failure of recanalization. It may be saccular or tubular and may or may not communicate with the GI tract. It resides along the mesenteric border of the bowel and presents as a cystic structure with a thick wall. The ‘target’ appearance of multiple layers may not be visualized on antenatal ultrasound. The cyst may show peristalsis, as in our case. It can cause complications of bowel obstruction, volvulus, intussusception and bleeding from heterotopic gastric mucosa<sup>(9)</sup>. Therefore, antenatal diagnosis is very valuable for surgical excision of the cyst in a planned and timely manner before the complications can develop.

Although the differential diagnosis for a fetal abdominal cystic mass is extensive, a systematic approach can narrow the possibilities. As a first step, the use of Doppler helps eliminate the possibility of a vascular lesion. Second, the location of the mass, fetal gender and the possible associated findings such as ascites, bowel dilation, calcifications, hydrops, or polyhydramnios, will reduce the number of differential possibilities. Finally, the careful analysis of the mass itself, including shape, wall thickness, type of fluid content, and possible peristalsis, will lead to an even more precise diagnosis.

The observation of peristalsis in fetuses with enteric duplication and Meckel diverticulum has been reported in literature. As this finding is fairly specific for those two diagnoses, it should be carefully assessed: the lesion should be magnified and the transducer kept stationary while searching for slow undulant contraction of the wall of the lesion. This is a very subtle finding that may go undetected unless specifically interrogated. A rare case of fetal segmental dilation of the ileum with no intestinal obstruction has been reported with similar findings of a cystic mass and peristalsis<sup>(10)</sup>. We feel that our reported case may fall under this category.

## Conclusion

In summary, the specific diagnosis of fetal cystic intraabdominal masses may be challenging. Intestinal duplication should always be considered whenever there is ultrasound evidence of a fetal abdominal cystic mass exhibiting peristalsis, a feature that is fairly specific for lesions originating in the GI tract.

## Conflict of interest

*The authors do not report any financial or personal links with other persons or organizations.*

## References

1. Khalil A, Cooke PC, Mantovani E, Bhide A, Papageorgiou AT, Thilaganathan B: Outcome of first-trimester fetal abdominal cysts: cohort study and review of the literature. *Ultrasound Obstet Gynecol* 2014; 43: 413–419.
2. Sepulveda W, Dickens K, Casasbuenas A, Gutierrez J, Dezerega V: Fetal abdominal cysts in the first trimester: prenatal detection and clinical significance. *Ultrasound Obstet Gynecol* 2008; 32: 860–864.
3. Agarwal R: Sonographic assessment of fetal abdominal cystic lesions: a pictorial essay. *Indian J Radiol Imaging* 1999; 9: 169–182.
4. Berrocal T, López-Pereira P, Arjonilla A, Gutiérrez J: Anomalies of the distal ureter, bladder, and urethra in children: embryologic, radiologic, and pathologic features. *Radiographics* 2002; 22: 1139–1164.
5. Chitty LS, Goodman J, Seller JM, Maxwell D: Esophageal and duodenal atresia in a fetus with Down's syndrome: prenatal sonographic features. *Ultrasound Obstet Gynecol* 1996; 7: 450–452.
6. Mostofian E, Ornvold K, Latchaw L, Harris RD: Prenatal sonographic diagnosis of abdominal mesenteric lymphangioma. *J Ultrasound Med* 2004; 23: 129–132.
7. Eckoldt F, Heling KS, Woderich R, Kraft S, Bollmann R, Mau H: Meconium peritonitis and pseudo-cyst formation: prenatal diagnosis and post-natal course. *Prenat Diagn* 2003; 23: 904–908.
8. Rushford MP, Stys SJ, Latchaw LA, Kasales C, Vaccaro T: Prenatal sonographic detection of Meckel diverticulum in utero with postnatal radiologic and surgical confirmation. *J Ultrasound Med* 2004; 23: 319–321.
9. Prada Arias M, García Lorenzo F, Montero Sánchez M, Muguera Velibre R: Enteric duplication cyst resembling umbilical cord cyst. *J Perinatol* 2006; 26: 368–370.
10. Waters KJ, Levine D, Lee EY, Buonomo C, Buchmiller TL: Segmental dilatation of the ileum: diagnostic clarification by prenatal and postnatal imaging. *J Ultrasound Med* 2007; 26: 1251–1256.