

UC Irvine

UC Irvine Previously Published Works

Title

Management Modalities and Outcomes Following Acute Scaphoid Fractures in Children: A Quantitative Review and Meta-Analysis

Permalink

<https://escholarship.org/uc/item/6143d35v>

Journal

Hand, 14(3)

ISSN

1558-9447

Authors

Shaterian, Ashkaun
Santos, Pauline Joy F
Lee, Christine J
[et al.](#)

Publication Date

2019-05-01

DOI

10.1177/1558944717735948

Copyright Information

This work is made available under the terms of a Creative Commons Attribution License, available at <https://creativecommons.org/licenses/by/4.0/>

Peer reviewed

Management Modalities and Outcomes Following Acute Scaphoid Fractures in Children: A Quantitative Review and Meta-Analysis

HAND
 2019, Vol. 14(3) 305–310
 © The Author(s) 2017
 Article reuse guidelines:
sagepub.com/journals-permissions
 DOI: 10.1177/1558944717735948
hand.sagepub.com

Ashkaun Shaterian¹, Pauline Joy F. Santos¹, Christine J. Lee¹,
 Gregory R. D. Evans¹, and Amber Leis¹

Abstract

Background: Early evaluation and appropriate management of pediatric scaphoid fractures are necessary to avoid complications. To date, current management of pediatric fractures varies among providers. The objective of this study was to compare clinical outcomes following different treatment modalities. **Methods:** A PubMed literature search identified studies involving acute scaphoid fractures in children. Studies were evaluated for treatment provided and their respective effects on union rate, wrist range of motion, and wrist pain. Data were pooled across studies, and quantitative statistical analysis was conducted to compare outcomes. **Results:** Seventeen studies representing 812 acute pediatric scaphoid fractures were included in the current analysis. We found 93.5% of scaphoid fractures were treated with cast immobilization vs 6.5% treated surgically as 13 of 17 authors treated all fractures with immobilization vs 4 of 17 studies who offered surgical intervention. We found pediatric scaphoid fractures had excellent bone union rates (96.2%) with no difference between the cast immobilization and surgery groups (*P* value NS). Long- and short-arm thumb spica immobilization protocols were commonly employed; however, we found no difference in the rates of union (*P* value NS). At follow-up, 99.0% of patients treated nonoperatively had normal wrist range of motion and 96.8% were pain free. **Conclusions:** Pediatric scaphoid fractures have excellent outcomes. Nonoperative treatment results in a high rate of union with few posttreatment wrist symptoms. Nonsurgical treatment represents an adequate treatment modality in a majority of acute pediatric scaphoid fractures, wherein the role for surgery needs to be better defined.

Keywords: scaphoid, fracture, children, pediatric, carpal, wrist

Introduction

Scaphoid fractures occur in children and adolescents accounting for 2.9% of all pediatric hand and wrist fractures.¹³ Adult literature has shown that the distally based vascularity, near complete cartilaginous surface, and numerous carpal articulations make scaphoid fractures susceptible to complications such as pseudarthrosis, nonunion, and avascular necrosis.^{3,6,9,13} Early evaluation and appropriate treatment are important in avoiding complications. While guidelines for treating adult scaphoid fractures have been well described,¹⁹ the pediatric fracture differs in etiology, morphology, and clinical outcomes.^{3,9} To date, guidelines for pediatric fractures have not been well established.

Operative and nonoperative treatments exist for pediatric scaphoid fractures. Nonoperative cast immobilization is commonly employed; however, providers prefer different casting positions and durations.^{7,12,15,16,31,35} While most

providers treat all pediatric fractures with cast immobilization, several providers promote surgical intervention under certain indications.^{5,14,18,30} Operative treatments can also vary, ranging from closed reduction percutaneous pinning to open reduction screw fixation.^{2,14,30} Ultimately, management of pediatric fractures varies significantly across providers without clear indications for surgical intervention.

Few studies have compared clinical outcomes following pediatric scaphoid fractures. The objective of this study was to conduct a literature review and systematic quantitative

¹University of California, Irvine, USA

Corresponding Author:

Ashkaun Shaterian, Department of Plastic Surgery, University of California, Irvine, 200 South Manchester Avenue, Suite 650, Orange, CA 92868, USA.

Email: ashateri@uci.edu

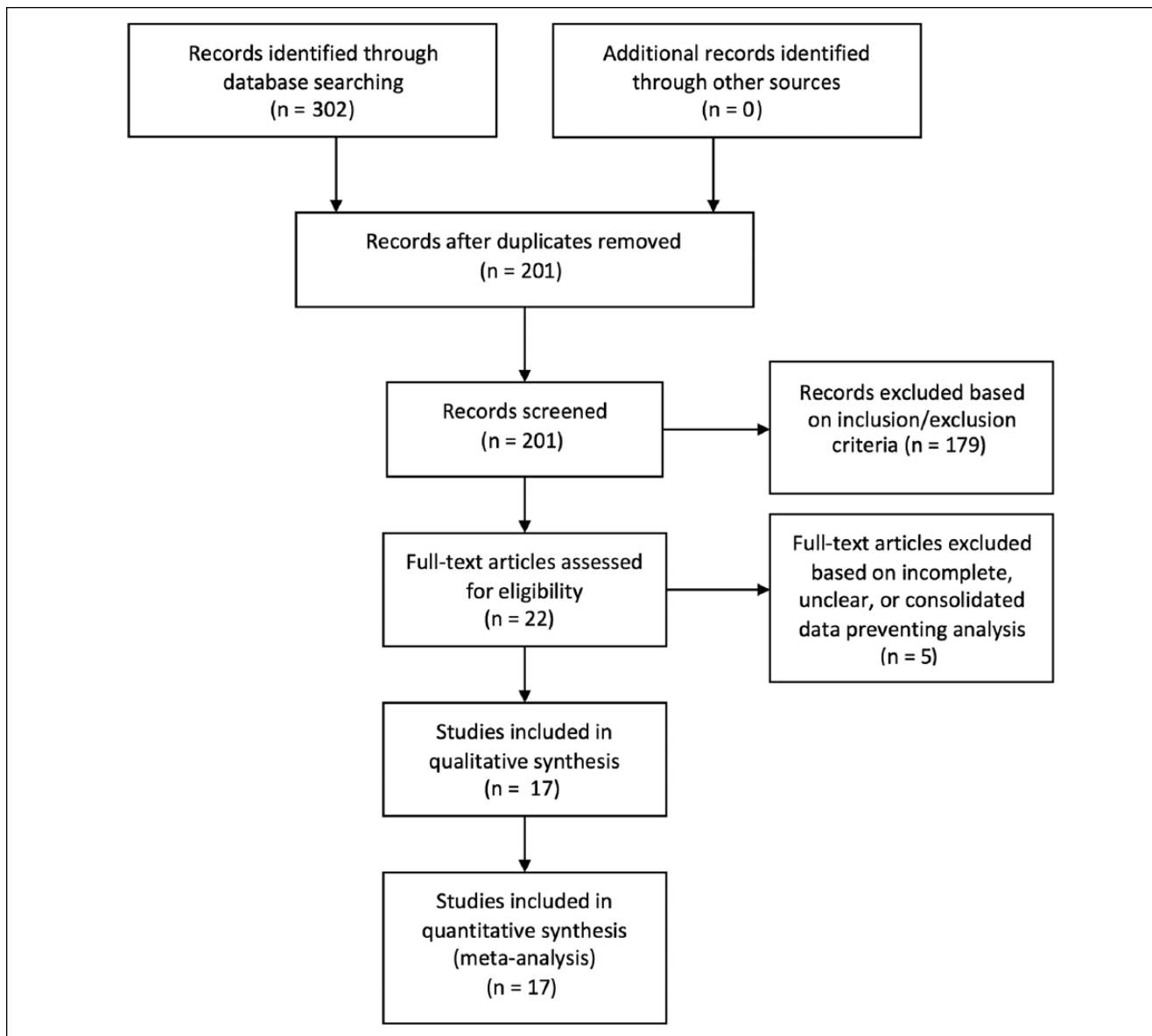


Figure 1. Study selection process.

analysis to compare union rates and posttreatment wrist complaints across different treatment modalities. We hope the resulting data will help define treatment algorithms for providers managing pediatric patients.

Materials and Methods

Search Methodology

A computerized literature search of PubMed databases was conducted to identify English-language studies focused on scaphoid fractures in children. The following keywords were used in our search: “scaphoid,” “fractures,” “children,”

and “surgery.” We used MeSH keywords and Boolean operators “AND/OR” to create combined data set searches. We reviewed databases for publications prior to 2016. Databases were last accessed on April 2017. Contact with study authors was attempted but did not yield additional data. As shown in Figure 1, 302 studies were identified from our initial database search. Duplicate articles were removed yielding 201 articles for subsequent screening. One hundred seventy-nine articles were excluded based on the inclusion/exclusion criteria, and another 5 articles were excluded based on incomplete, unclear, or consolidated data that could not be statistically analyzed. Ultimately, 17 articles were included in our study.

Inclusion/Exclusion Criteria

Inclusion/exclusion criteria were set to identify a specific study population. Studies were selected based on the following inclusion criteria: (1) studies evaluating pediatric patients defined as age less than 18 years; (2) studies containing a sample size greater than 4 subjects; (3) studies evaluating acute fracture presentations; (4) studies detailing treatment protocols; and (5) studies evaluating treatment outcomes. Studies were eliminated based on the following exclusion criteria: (1) studies representing review, meta-analysis, or case report studies; (2) studies in which fractures included malunions, nonunions, or chronic presentations; and (3) studies that did not correlate treatment and clinical outcomes. If studies included additional data on adult patients, chronic fractures, or malunions/nonunions, data were stratified to only include data that met inclusion/exclusion criteria.

Data Extraction and Statistical Analysis

Data were extracted independently by 2 members of the study team (P.S. and A.S.) and subsequently reviewed to ensure data accuracy. Articles were reviewed for patient- and treatment-related variables. Patient-related variables included patient age and fracture morphology (ie, displaced, proximal/middle/distal third fracture). Treatment-related variables included the specifics of treatment provided (ie, surgical vs nonsurgical, type and duration of immobilization, surgical fixation technique). Clinical outcomes evaluated included rate of bone union and posttreatment wrist symptoms related to wrist range of motion and wrist pain. Data were pooled across studies into a combined data set and statistical analysis was conducted. Summary statistics using Student *t* test and analysis of variance tests were used where appropriate to evaluate outcomes between treatment groups. Statistical significance was set with *P* value <.05, with all tests 2 sided.

This study was conducted using the Preferred Reporting Items for Systematic Reviews and Meta-Analyses (PRISMA) guidelines.²²

Results

Characteristics of Literature Reviewed

The current study analyzed 17 studies representing 812 acute pediatric scaphoid fractures. Studies were most commonly published between years 1990 and 2016 but included publications from years 1961 to 2016. Geographical locations of publications also varied. Studies were most commonly conducted in the United States^{5,14,15,35} or Europe^{1,7,12,13,16,18,20,21,23,29,31} but represented the following regions: Belgium,¹² Japan,³⁰ the United States,^{5,14,15,35} Finland,³¹ England,^{7,16,21,29} Sweden,²³ Denmark,²⁰ Serbia,¹³

Germany,¹⁸ Scotland,¹ and Canada.²⁷ We found 10 studies represented the university setting^{7,12,13,16,18,20,21,27,29,30} and 7 represented children's hospitals.^{1,5,14,15,23,31,35}

Treatment Protocols

Providers treated acute pediatric scaphoid fractures with either cast immobilization or surgical fixation. Here, we found 13 of 17 providers^{1,7,12,13,15,16,20,21,23,27,29,31,35} treated all scaphoid fractures nonoperatively with cast immobilization vs 4 of 17 providers who offered surgical intervention for proximal pole, unstable, or displaced fractures,^{5,14,18,30} based on the desire for early return to sports/activities,⁵ or fractures failing initial trial of casting.¹⁴ We found 93.5% (757 of 810) of scaphoid fractures were treated with cast immobilization and 6.5% (53 of 810) were treated with surgical fixation. We found 43.4% of surgically treated fractures underwent open reduction screw fixation,^{14,30} 50.9% underwent percutaneous screw fixation,^{14,18,30} and 5.7% underwent an unspecified surgical technique.⁵ Postoperative immobilization protocols were not documented systematically to draw generalized conclusions.

Next, our review of nonoperative treatments revealed a variety of immobilization techniques being employed. These most commonly included long-arm thumb spica protocols, short-arm thumb spica protocols, or a combination of short/long-arm thumb spica protocols; several studies did not specify their casting protocols. The duration of immobilization ranged from 1 to 16 weeks; however, variability in data presentation prevented further analysis to identify possible trends. Authors did not state their specific rationale for the choice of immobilization.

Rate of Union

To compare the efficacy of surgical and nonsurgical treatments, we evaluated rates of union between treatment modalities. In total, we found pediatric scaphoid fractures obtained excellent rates of union at 96.2% across all fractures types and treatment modalities. Patients treated with cast immobilization vs surgery showed no difference in rates of union (96.0% union in cast immobilization group vs 98.1% in surgery group; Figure 2) (*P* value NS). We reevaluated union rates after stratifying for surgically indicated fracture morphologies (ie, proximal pole, unstable, displaced fractures, fractures failing initial casting trial)^{5,14,18,30} and found no difference in rates of union between the cast immobilization and surgery groups (*P* value NS). We found only 8 patients with surgical indications underwent cast immobilization vs 51 patients who actually underwent surgery. These studies, however, did not further stratify for severity of fracture displacement or degree of fracture instability, which may have influenced whether surgery was recommended. This may have otherwise affected comparative union rates in higher risk fractures.

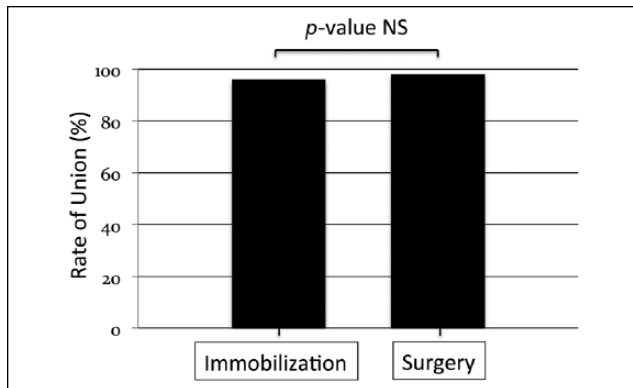


Figure 2. Rates of bone union following cast immobilization vs surgical intervention in acute pediatric scaphoid fractures.

Next, we compared union rates across the various casting protocols. We found no difference in rates of union between short-arm thumb spica (97.4%), long-arm thumb spica (100%), and protocols that employed a transition from long-arm to short-arm thumb spica (95.0%; *P* value NS) (Figure 3). We found the duration of immobilization to range from 1 to 16 weeks. We were unable to determine the role of immobilization time on union rates as they were not uniformly presented nor stratified by immobilization position or fracture type. This variability in data resulted in a low sample size, underpowered statistical testing, and the inability to draw generalized conclusions. Similarly, post-operative immobilization protocols were not systematically documented to draw generalized conclusions.

Posttreatment Wrist Complaints

To determine the incidence of posttreatment wrist sequela, we evaluated wrist range of motion and wrist pain following treatment. Following cast immobilization, we found 99.0% of patients treated nonoperatively had normal range of motion and 96.8% reported pain-free sequela. Studies did not detail whether symptomatic patients represented cases of nonunion, malunion, or delayed union. Four studies evaluated wrist symptoms following surgical fixation.^{5,14,18,30} These studies, however, did not stratify their analysis for acute fractures in surgically treated patients to conduct a comparative analysis. Similarly, too few studies evaluated surgery-related complications to draw generalized conclusions.

Discussion

In this study, we found pediatric scaphoid fractures achieved excellent union rates independent of the type of immobilization and whether patients were treated via operative vs nonoperative modalities. This likely reflects the fracture etiology and morphology specific to the pediatric population. Given the sequence of scaphoid ossification and

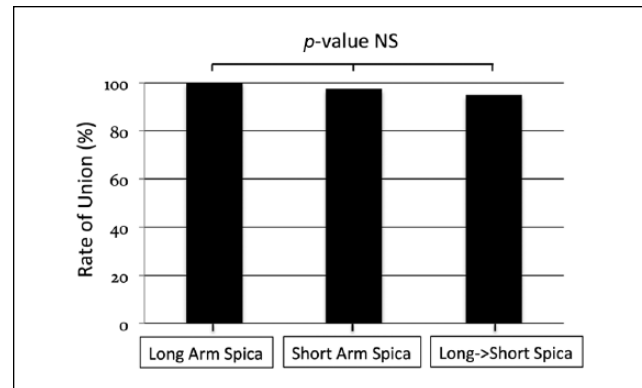


Figure 3. Rates of bone union following different immobilization protocols in acute pediatric scaphoid fractures.

delayed ossification of the proximal pole, most pediatric fractures occur at the distal pole and heal well given the retrograde blood supply of the scaphoid.²⁶ Furthermore, the incidence of unstable or displaced fractures is less frequent in pediatric patients as the etiology of injury is less severe with fewer high-velocity mechanisms.^{7,9,31} The anatomic and physiologic qualities of pediatric scaphoid fractures produce superior outcomes relative to the adult population²⁴ and likely accounts for the excellent union rates.

Nonoperative treatment with cast immobilization avoids the negative effects associated with surgery in childhood as exposure to anesthesia,¹³ placement of permanent hardware,^{26,33} possible growth restriction, and risks of infection, among numerous other complications.²⁶ Vinnars et al further promoted nonoperative treatment after finding it to be cost-effective relative to operative management.³³ Other providers have suggested that operative treatment should be reserved for patients at or near skeletal maturity to prevent growth restriction.³ To this end, our study results parallel numerous opinions^{3,11} that most pediatric scaphoid fractures heal well with cast immobilization wherein further studies are needed to better characterize the fracture patterns that would benefit from surgery.

Surgical intervention, in contrast, is offered by several providers.^{5,14,18,30} Cited indications include proximal pole, unstable, or displaced fractures,^{5,14,18,30} fractures failing a trial of nonoperative treatment,¹⁴ and patients desiring an early return to sports/activities.⁵ We found union rates were no different between cast immobilization and operative treatment groups. This analysis, however, did not stratify for severity of displacement nor degree of fracture instability, wherein more specific indications (ie, >2 mm displacement) may have influenced comparative union rates for higher risk fractures. Various studies suggest operative intervention can achieve good union rates with less time, a quicker return to activities, and may be an attractive alternative for higher risk injuries.^{4,25} Several authors have promoted surgical intervention with concern over occult

nonunions¹⁴ or the changing fracture patterns that resemble adults.^{14,18,27} While surgical intervention likely has a role in acute pediatric scaphoid fractures, its indications need to be defined beyond those cited in the current literature.

Despite numerous providers offering cast immobilization for acute pediatric fractures, we found a variety of casting protocols being employed. The short-arm thumb spica immobilizes the base of the thumb and reduces shear forces between the first metacarpal, trapezium, and scaphoid. The long-arm thumb spica, in addition, immobilizes the elbow to diminish rotational movement across the scaphoid caused by pronation and supination.³² Consistent with the literature on adult scaphoid fractures,¹⁰ our study found no difference in union rates across the specified casting protocols (short-arm thumb spica, long-arm thumb spica, combination long/short-arm thumb spica). Rather than the extent of coverage, Clay et al suggested that the most important factor is the quality of casting in its mold to the palm.⁸

Posttreatment sequela is an important clinical outcome marker following fracture treatment. Posttreatment wrist symptoms can result from nonunion, malunion, stiffness, arthritic development, concurrent soft tissue injury, and surgery-related complications, among other etiologies.^{14,17} In the current study, we found patients treated with cast immobilization achieved excellent wrist range of motion and wrist pain scores after treatment. The excellent rates following cast immobilization likely reflect the high union rates, low incidence of complication, and the remodeling potential of children.^{28,34} Similarly, studies evaluating surgical fixation found low rates of wrist symptoms after surgical intervention, but these studies did not stratify data for acute fracture presentations. While it appears surgical fixation can achieve good wrist scores given the high union rates and nonstratified study results,^{5,14,18,30} additional research is needed to compare wrist outcomes following cast immobilization and surgical treatment.

This study has several limitations. First, our study evaluated retrospective studies and thus risks unmeasured bias and uncontrolled variables. Furthermore, while a comprehensive review of the literature was attempted, this study risks incomplete retrieval of published research and reporting biases of published data. Studies reviewed were also limited in their nonsystematic evaluation of posttreatment wrist complaints, lack of consistent stratification of treatment outcomes by fracture morphology, and lack of details regarding postoperative immobilization protocols. Our study did not stratify results by patient age as younger children may have different fracture morphologies and outcomes relative to older adolescents. Similarly, we were unable to evaluate whether adolescents/young adults should be treated based on pediatric vs adult paradigms as chronological age functions on a continuum. Despite these limitations, we believe our study represents a reliable analysis that can be used to help guide management in pediatric scaphoid fractures.

Conclusion

Scaphoid fractures in children have excellent outcomes. Patients undergoing surgical interventions vs cast immobilization have comparable clinical outcomes. This likely represents the favorable prognostic factors characteristic of pediatric scaphoid fractures relative to adult fractures. Cast immobilization results in excellent rates of union with few posttreatment wrist complaints and serves as an adequate treatment modality for most pediatric fractures. While surgery likely has a role in pediatric fractures, the indications need to be better defined.

Ethical Approval

This study was given IRB exemption by our institutional review board.

Statement of Human and Animal Rights

This article does not contain any studies with human or animal subjects.

Statement of Informed Consent

This study does not contain any identifiable patient information and does not contain any human subjects. Informed consent was therefore not obtained.

Declaration of Conflicting Interests

The author(s) declared no potential conflicts of interest with respect to the research, authorship, and/or publication of this article.

Funding

The author(s) received no financial support for the research, authorship, and/or publication of this article.

References

1. Ahmed I, Ashton F, Tay WK, et al. The pediatric fracture of the scaphoid in patients aged 13 years and under: an epidemiological study. *J Pediatr Orthop*. 2014;34(2):150-154.
2. Andjelkovic SZ, Vuckovic CD, Lesic AR, et al. Fractures of the scaphoid, diagnosis and management—a review. *Acta Chir Iugosl*. 2013;60(2):99-102.
3. Anz AW, Bushnell BD, Bynum DK, et al. Pediatric scaphoid fractures. *J Am Acad Orthop Surg*. 2009;17(2):77-87.
4. Arora R, Gschwentner M, Krappinger D, et al. Fixation of nondisplaced scaphoid fractures: making treatment cost effective. Prospective controlled trial. *Arch Orthop Trauma Surg*. 2007;127(1):39-46.
5. Bae DS, Gholson JJ, Zurakowski D, et al. Functional outcomes after treatment of scaphoid fractures in children and adolescents. *J Pediatr Orthop*. 2016;36(1):13-18.
6. Cheung JP, Tang CY, Fung BK. Current management of acute scaphoid fractures: a review. *Hong Kong Med J*. 2014;20(1):52-58.

7. Christodoulou AG, Colton CL. Scaphoid fractures in children. *J Pediatr Orthop*. 1986;6(1):37-39.
8. Clay NR, Dias JJ, Costigan PS, et al. Need the thumb be immobilised in scaphoid fractures? a randomised prospective trial. *J Bone Joint Surg Br*. 1991;73(5):828-832.
9. D'Arienzo M. Scaphoid fractures in children. *J Hand Surg Br*. 2002;27(5):424-426.
10. Doornberg JN, Buijze GA, Ham SJ, et al. Nonoperative treatment for acute scaphoid fractures: a systematic review and meta-analysis of randomized controlled trials. *J Trauma*. 2011;71(4):1073-1081.
11. Elhassan BT, Shin AY. Scaphoid fracture in children. *Hand Clin*. 2006;22(1):31-41.
12. Fabre O, De Boeck H, Haentjens P. Fractures and non-unions of the carpal scaphoid in children. *Acta Orthop Belg*. 2001;67(2):121-125.
13. Gajdobranski D, Zivanović D, Mikov A, et al. Scaphoid fractures in children. *Srp Arh Celok Lek*. 2014;142(7-8):444-449.
14. Gholson JJ, Bae DS, Zurakowski D, et al. Scaphoid fractures in children and adolescents: contemporary injury patterns and factors influencing time to union. *J Bone Joint Surg Am*. 2011;93(13):1210-1219.
15. Greene MH, Hadied AM, LaMont RL. Scaphoid fractures in children. *J Hand Surg Am*. 1984;9(4):536-541.
16. Grundy M. Fractures of the carpal scaphoid in children. A series of eight cases. *Br J Surg*. 1969;56(7):523-524.
17. Hackney LA, Dodds SD. Assessment of scaphoid fracture healing. *Curr Rev Musculoskelet Med*. 2011;4(1):16-22.
18. Huckstadt T, Klitscher D, Weltzien A, et al. Pediatric fractures of the carpal scaphoid: a retrospective clinical and radiological study. *J Pediatr Orthop*. 2007;27(4):447-450.
19. Krasin E, Goldwirth M, Gold A, et al. Review of the current methods in the diagnosis and treatment of scaphoid fractures. *Postgrad Med J*. 2001;77(906):235-237.
20. Langhoff O, Andersen JL. Consequences of late immobilization of scaphoid fractures. *J Hand Surg Br*. 1988;13(1):77-79.
21. Leslie IJ, Dickson RA. The fractured carpal scaphoid. Natural history and factors influencing outcome. *J Bone Joint Surg Br*. 1981;63-B(2):225-230.
22. Moher D, Liberati A, Tetzlaff J, et al. Preferred reporting items for systematic reviews and meta-analyses: the PRISMA statement. *Int J Surg*. 2010;8(5):336-341.
23. Mussbichler H. Injuries of the carpal scaphoid in children. *Acta Radiol*. 1961;56:361-368.
24. Rhemrev SJ, Ootes D, Beeres FJ, et al. Current methods of diagnosis and treatment of scaphoid fractures. *Int J Emerg Med*. 2011;4:4.
25. Schadel-Hopfner M, Marent-Huber M, Sauerbier M, et al. Operative versus conservative treatment of non-displaced fractures of the scaphoid bone. Results of a controlled multicenter cohort study. *Unfallchirurg*. 2010;113(10):804, 806-813.
26. Sendher R, Ladd AL. The scaphoid. *Orthop Clin North Am*. 2013;44(1):107-120.
27. Stanciu C, Dumont A. Changing patterns of scaphoid fractures in adolescents. *Can J Surg*. 1994;37(3):214-216.
28. Suzuki K, Herbert TJ. Spontaneous correction of dorsal intercalated segment instability deformity with scaphoid malunion in the skeletally immature. *J Hand Surg Am*. 1993;18(6):1012-1015.
29. Tan YW, Maffulli N. Carpal scaphoid fracture in the skeletally immature: a single centre one-year prospective study. *Acta Orthop Belg*. 2009;75(5):616-622.
30. Toh S, Miura H, Arai K, et al. Scaphoid fractures in children: problems and treatment. *J Pediatr Orthop*. 2003;23(2):216-221.
31. Vahvanen V, Westerlund M. Fracture of the carpal scaphoid in children. A clinical and roentgenological study of 108 cases. *Acta Orthop Scand*. 1980;51(6):909-913.
32. Verdan C. The role of the anterior radiocarpal ligament in fractures of the scaphoid carpus; therapeutic deductions. *Z Unfallmed Berufskr*. 1954;47(4):294-297.
33. Vinnars B, Ekenstam FA, Gerdin B. Comparison of direct and indirect costs of internal fixation and cast treatment in acute scaphoid fractures: a randomized trial involving 52 patients. *Acta Orthop*. 2007;78(5):672-679.
34. Weber DM, Fricker R, Ramseier LE. Conservative treatment of scaphoid nonunion in children and adolescents. *J Bone Joint Surg Br*. 2009;91(9):1213-1216.
35. Wulff RN, Schmidt TL. Carpal fractures in children. *J Pediatr Orthop*. 1998;18(4):462-465.