UC Irvine

UC Irvine Previously Published Works

Title

Efficacy of Lasers and Light Sources for Telangiectasias in the Setting of Systemic Sclerosis and Systemic Lupus Erythematosus: A Review

Permalink

https://escholarship.org/uc/item/6199g8pv

Journal

Lasers in Surgery and Medicine, 58(9)

ISSN

0196-8092

Authors

Shah, Karishma S

Brady, Briana R Halle

Min, Michelle S

et al.

Publication Date

2026-11-01

DOI

10.1002/lsm.70184

Copyright Information

This work is made available under the terms of a Creative Commons Attribution License, available at https://creativecommons.org/licenses/by/4.0/

Peer reviewed

eScholarship.org Powered by the California Digital Library
University of California

Check for updates

Lasers in Surgery and Medicine

REVIEW ARTICLE

Efficacy of Lasers and Light Sources for Telangiectasias in the Setting of Systemic Sclerosis and Systemic Lupus Erythematosus: A Review

Karishma S. Shah | Briana R. Halle Brady | Michelle S. Min | Kristen M. Kelly

Department of Dermatology, University of California, Irvine, Irvine, California, USA

Correspondence: Kristen M. Kelly (kmkelly@hs.uci.edu)

Received: 19 June 2025 | **Revised:** 21 June 2026 | **Accepted:** 17 July 2026

Keywords: connective tissue disease | laser therapy | lupus erythematosus | PDL | pulsed dye laser | systemic sclerosis | telangiectasias

ABSTRACT

Objectives: Lasers and light sources are effective treatment modalities for numerous vascular conditions of the skin, including rosacea and port-wine capillary malformations. While they are widely accepted as effective therapies for sporadic idiopathic telangiectasias, there is limited data regarding their efficacy in treating telangiectasias that occur due to connective tissue diseases (CTD) of systemic sclerosis (SSc) and lupus erythematosus (LE). The primary objective of this review is to analyse data on the effectiveness of lasers and light sources in treating SSc and LE associated telangiectasias. Ultimately, we hope that this will help guide physicians in managing these telangiectasias.

Methods: A PubMed search was conducted March 2025 on the efficacy of lasers and light based devices known to help with vascular lesions in treating telangiectasias associated with a variety of connective tissue diseases including SSc, LE, dermatomyositis, mixed CTD, and morphea. Ultimately, 10 full-text articles met inclusion criteria. Available studies only investigated the use of either pulsed dye laser (PDL) or intense pulsed light (IPL) for telangiectasias within the context of SSc and LE, and thus these conditions became the focus of our review.

Results: All 10 articles demonstrated that PDL or IPL resulted in an improvement in telangiectasias associated with SSc and LE. In seven of the studies, there was both a reduction in the number of telangiectasias and overall visual improvement after PDL treatment. In all 4 studies that accounted for patient perspective, all subjects reported satisfaction with treatment and endorsed a better quality of life after PDL. Two studies suggested that telangiectasias secondary to SSc or LE may be more recalcitrant than sporadic telangiectasias, necessitating a greater number of treatments. One study found that PDL may be more effective than IPL when comparing clinical photographs and dermoscopic findings. All adverse events were transient and have also been seen in treatment of sporadic telangiectasias. No studies reported exacerbation of the underlying SSc or LE.

Conclusion: Overall, PDL and IPL appear to be relatively safe and effective treatments for managing SSc and SLE-associated telangiectasias. More treatment sessions may be required compared to sporadic idiopathic telangiectasias. Future randomized controlled studies with more objective outcomes would help better characterize the effect of light-based devices in this unique patient population.

1 | Introduction

Lasers and light sources remain successful treatment modalities for cutaneous vascular lesions. While several devices have demonstrated efficacy, including the potassium titanyl phosphate (KTP), long-pulse neodymium:yttrium-aluminum-garnet (Nd:YAG), alexandrite, and diode lasers, intense pulse light (IPL) and pulsed dye laser (PDL) are widely considered to be the treatment of choice for a variety of cutaneous vascular lesions [1].

All rights reserved, including rights for text and data mining and training of artificial intelligence technologies or similar technologies.

© 2026 Wiley Periodicals LLC.

PDL was developed in 1983 based on selective photothermolysis [2]. Selective photothermolysis describes brief pulses of selectively absorbed optical radiation causing specific damage to pigmented structures and cells [3, 4]. It is now well-studied in treating port-wine capillary malformations and telangiectasias [1, 5, 6].

Telangiectasias are superficial vascular lesions that develop due to capillary dilation. They commonly present on the face and lower extremities. Though most occur sporadically, they can also be associated with medical conditions, such as rosacea and connective tissue diseases (CTDs), like systemic sclerosis (SSc) and lupus erythematosus (LE).

SSc is an autoimmune disorder characterized by fibrosis of skin and internal organs. Abnormal vasculature manifests in SSc by Raynaud's phenomenon, digital ulcerations, pulmonary arterial hypertension, and cutaneous telangiectasias [7]. The 2013 American College of Rheumatology/European League Against Rheumatism (ACR/EULAR) criteria for SSc highlights the importance of cutaneous findings, including telangiectasias, in the classification of this condition [8]. Telangiectasias associated with SSc may increase over time and tend to impact visible regions, such as the face. It is therefore a leading cause of patient dissatisfaction [9].

LE is another autoimmune disorder that impacts numerous organs including skin, kidney, and lungs. This disease is also associated with abnormal vasculature given immune complex deposition in vessels and subsequent disruption of the endothelium [10]. Lupus erythematosus telangiectasias, now considered within the spectrum of cutaneous LE (CLE), was historically thought of as a distinct clinical entity characterized by symmetric and persistent circumscribed patches on both cheeks with visible dilated blood vessels [11]. Although telangiectasias are not specified in ACR/EULAR diagnostic criteria for systemic LE, they are often seen in patients with CLE, especially discoid LE (DLE) given its association with inflammation and atrophic scarring [12].

Although not life-threatening, SSc and LE associated telangiectasias contribute to significant cosmetic and psychological distress for patients. Studies in patients with SSc found that those with telangiectasias experienced significantly higher body image dissatisfaction and endorsed changes to their behavior, including social avoidance, compared to those without [9]. More specifically, greater social discomfort was significantly associated with upper body telangiectasias [13]. Identifying therapeutic options for these patients is important. However, due to concerns about wound healing and the impact of photosensitivity on disease pathogenesis, there are no current guidelines discussing their management with light-based devices. This review evaluates the available evidence on the efficacy, safety, and tolerability of lasers and light sources for treating SSc and LE associated telangiectasias.

2 | Methods

A literature review was conducted in March 2025 for all peer-reviewed articles published in the PubMed database using the following search queries: pulsed dye laser AND ((telangiectasia) OR (vessel) OR (vasculature) OR (vascular)) AND ((connective tissue disease) OR (systemic sclerosis) OR (CREST) OR (scleroderma)); pulsed dye laser AND ((telangiectasia) OR (vessel) OR (vasculature) OR (vascular)) AND ((connective tissue disease) OR (lupus erythematosus) OR (SLE) OR (LE) OR (systemic lupus erythematosus)); pulsed dye laser AND ((telangiectasia) OR (vessel) OR (vasculature) OR (vascular)) AND ((connective tissue disease) OR (dermatomyositis) OR (DM)); pulsed dye laser AND ((telangiectasia) OR (vessel) OR (vasculature) OR (vascular)) AND ((connective tissue disease) OR (vasculitis)); pulsed dye laser AND ((telangiectasia) OR (vessel) OR (vasculature) OR (vascular)) AND ((connective tissue disease) OR (mixed connective tissue disease) OR (MCTD))); pulsed dye laser AND ((telangiectasia) OR (vessel) OR (vasculature) OR (vascular)) AND ((connective tissue disease) OR (morphea)). This search strategy revealed 46 records in total. Only studies reporting the use of PDL for treatment of telangiectasias in patients with underlying CTD were included for final analysis. After full-text review, eight full-text articles were assessed and included in this review. The remaining 38 articles were excluded because they did not specifically discuss PDL treatment for telangiectasias nor did they include patients with underlying CTDs.

Search queries were repeated substituting “pulse dye laser” for “intense pulsed light.” This search strategy revealed 13 records in total. After full-text review, two full-text articles were assessed and included in this review. Similar searches were completed focused on the KTP laser, long-pulse Nd:YAG laser, alexandrite laser, and diode laser, none of which revealed records that fit our inclusion criteria.

3 | Results

Of the ten articles included, one was a clinical trial, one was a randomized control trial, two were retrospective case series, four were prospective case series, one was a prospective open-label study, and one was a case report. Overall, SSc and LE were the only two CTDs discussed in peer-reviewed articles from our search results (Figure 1).

3.1 | Systemic Sclerosis

3.1.1 | PDL

Of the eight articles included in this review on PDL, five exclusively discussed the use of PDL for SSc-associated telangiectasias in a total of 84 patients (Table 1). Across all articles, a variety of parameters were measured including number of treatments needed, physician opinion on visual appearance, patient satisfaction, histopathological findings, quality of life metrics, and adverse events.

3.1.1.1 | Laser Settings

It is important to note that laser settings varied from study to study, making it difficult to standardize and compare results

10969101, 2026, 9, Downloaded from https://onlinelibrary.wiley.com/doi/10.1002/lsm.70184 by University Of California Irvine Science Library Serials, Wiley Online Library on [06/11/2026]. See the Terms and Conditions (https://onlinelibrary.wiley.com/terms-and-conditions) on Wiley Online Library for rules of use; OA articles are governed by the applicable Creative Commons License

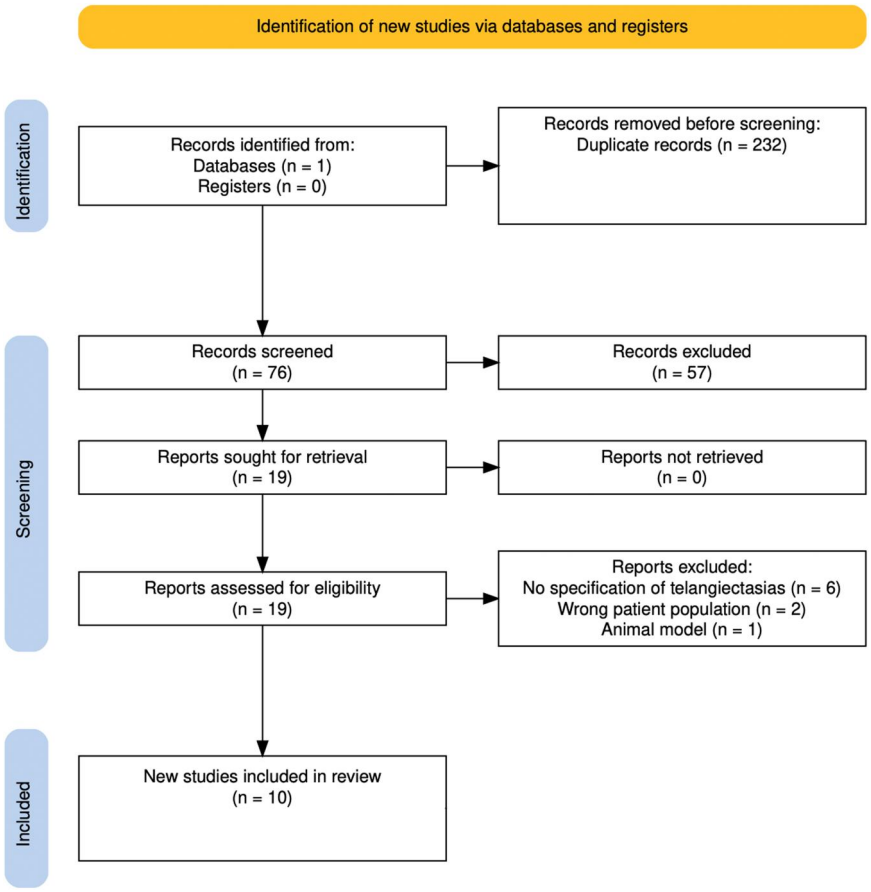

FIGURE 1 | PRISMA flow diagram depicting the literature review methodology and findings. Our search strategy revealed 76 unique articles. An initial screen yielded 19 relevant articles. After full-text review, nine articles were excluded as it was found that they did not meet inclusion criteria. A total of 10 articles were included in the final review.

(Table 2). Spot size ranged from 5 to 7 mm, pulse duration ranged from 0.45 to 1.5 ms, and fluence ranged from 5 to 9 J/cm^2 with devices of 585 or 595 nm.

3.1.1.2 | *Number of Treatments Needed*

Three of the five studies reported on the number of treatments required and, of those, only two specifically commented on the number of laser treatments needed compared to non-SSc-associated telangiectasias. The first study by Ciatti et al. in 1996 used flashlamp-pumped PDL for eight patients. Resolution required one to four treatments [14].

A study conducted in 2013 by Halachmi et al. compared the use of PDL in 16 patients with SSc-associated telangiectasias to 20 patients with sporadic telangiectasias. SSc-associated telangiectasias required an average of 3.24 treatments compared to 1.92 treatments for spontaneous cases. They also found that, of multiple factors including age, gender, body site, and lesion size, lesion size was the only variable that significantly affected the number of treatments needed [15]. Burillo-Martinez et al. further treated 23 patients with SSc using PDL. The mean number of PDL sessions for clearance was 3 (range 1–7). Although there was no control group, the authors commented that this number was higher than their typical single PDL treatment required for sporadic idiopathic telangiectasias (Table 1) [16].

When analyzed in aggregate, the mean number of treatments was 3.12 with a range of 1–7 (Table 3).

3.1.1.3 | *Physician Opinion on Quantity and Quality of Telangiectasias After Treatment*

Despite different measures, all studies reported efficacy. PDL was noted to be effective in treating SSc-associated telangiectasias for all eight patients in the initial 1996 study [14]. Similarly, Burillo-Martinez et al. cited that all 23 patients had positive response, with 10 achieving complete clearance [16]. All 16 patients in Halachmi et al. demonstrated significant improvement after PDL, with 95% clearance [15].

A randomized controlled trial conducted in 2014 by et al. followed a more rigorous protocol for analysis. All patient photographs were analyzed by two independent, blinded clinical observers. Improvements in appearance were noted at nearly all time points. Additionally, the median change in the number of lesions was −3 (range −10 to 0) [17]. Building on those results, a clinical trial from 2023 conducted by Kottler et al. followed a similar approach. Per their protocol, they assessed PDL efficacy both quantitatively and qualitatively. They analysed the number of telangiectasias from standardized photographs at baseline and 2 months after final treatment. The number of telangiectasias were assessed by both investigator and independent observer who reported a significant decline in telangiectasia number by

10969101, 2026, 9, Downloaded from https://onlinelibrary.wiley.com/doi/10.1002/lsm.70184 by University Of California Irvine Science Library Serials, Wiley Online Library on [06/11/2026]. See the Terms and Conditions (https://onlinelibrary.wiley.com/terms-and-conditions) on Wiley Online Library for rules of use; OA articles are governed by the applicable Creative Commons License

TABLE 1 | Study characteristics.

Author	Level of evidence[a]	Device used	# of patients	Age (mean)	Sex	# of Treatments needed	Quantitative assessment of telangiectasias	Qualitative assessment of telangiectasias	Impact on quality of life	Adverse effects	Follow-Up
Systemic sclerosis											
Dinsdale et al. [17]	1	PDL	19	59	18/19F	3[b]	Mean: −3 Range: −10 to 0	Physicians: Improvement Patients: Improvement	HADS: no change ASWAP: significant decrease	Transient bruising	16 weeks –9 months
Kottler et al. [18]	2	PDL	21	58.6	15/21F	4[b]	Mean: −5.42 (32% decrease)	Physicians: Improvement noted in 74% of patients	Skindex: significant decrease	Oozing/crusts, local epidermal blistering, edema, hypopigmentation	2 months
Ciatti et al. [14]	2	PDL	8	56	8/8F	Range: 1–4	—	—	—	Postoperative purpura of 7-10 days	2 years
Burillo-Martinez et al. [16]	3	PDL	23	49	23/23F	Mean: 3 Range: 1–7	100% clearance in 10 patients	Physicians: Very positive Patients: Mean global satisfaction score of 8.75/10	—	Purpura, edema, transient pigmentary changes, mild blistering	18-36 months
Halachmi et al. [15]	3	PDL	16	37.4	15/16F	Mean: 3.24	Mean: 95% clearance	Physicians: Significant improvement	—	—	—
Dinsdale et al. [17]	1	IPL	19	59	18/19F	3[b]	Mean: −3 Range: −6 to 1	Physicians: Improvement Patients: Improvement (although PDL preferred)	HADS: no change ASWAP: significant decrease	None	16 weeks –9 months
Murray et al. [19]	2	IPL	20	58	16/20F	3[b]	—	Physicians: Improvement at 1 and 6 months. For some, the degree of improvement was not maintained at 12 months	—	Transient edema, transient blistering	14 months

(Continues)

10969101, 2026, 9, Downloaded from https://onlinelibrary.wiley.com/doi/10.1002/lsm.70184 by University Of California Irvine Science Library, Wiley Online Library on [06/11/2026]. See the Terms and Conditions (https://onlinelibrary.wiley.com/terms-and-conditions) on Wiley Online Library for rules of use; OA articles are governed by the applicable Creative Commons License

TABLE 1 | (Continued)

Author	Level of evidence[a]	Device used	# of patients	Age (mean)	Sex	# of Treatments needed	Quantitative assessment of telangiectasias	Qualitative assessment of telangiectasias	Impact on quality of life	Adverse effects	Follow-Up
Lupus erythematosus											
Diez et al. [22]	2	PDL	9	45.3	5/9F	—	—	—	—	—	4 weeks
Baniandrés et al. [21]	3	PDL	6	41.67	5/6F	Mean: 2.5 Median: 2	Mean: 67.5% clearance[b]	—	—	Transient hyperpigmentation	22 months
Núñez et al. [20]	4	PDL	4	32	4/4F	Range: 3–6	> 75% clearance in all patients	Physicians: Excellent Patients: Excellent	—	Transient hyperpigmentation	16 wees
Li et al. [23]	4	IPL	1	21	F	5	—	Physicians: Improvement from severe to mild erythema	—	Transient mild erythema	6 months

Abbreviations: ASWAP, Adapted Satisfaction with Appearance Scale; HADS, Hospital Anxiety and Depression Scale; IPL, intense pulse light; PDL, pulsed-dye laser.
[a]Based upon the Levels of Evidence for Therapeutic Studies taken from the Center for Evidence-Based Medicine (https://pmc.ncbi.nlm.nih.gov/articles/PMC3124652/).
[b]All patients underwent this number of treatment sessions, regardless of their progress.

32% and 34%, respectively. Qualitatively, four dermatologists assessed visual improvement based upon clinical photos. They deemed that telangiectasias improved or strongly improved in 74% of patients (Table 1).

3.1.1.4 | *Histopathology*

Only Halachmi et al. reported histological findings. They obtained 19 skin biopsies of untreated telangiectasias from patients who met diagnostic criteria for scleroderma or CREST and compared them to biopsies from 10 patients without known systemic disease. The researchers found that in 89% of the SSc biopsies, the endothelium of the telangiectasias appeared thickened, suggesting a potential explanation as to why SSc telangiectasias may be more resistant to PDL than sporadic telangiectasias [15].

3.1.1.5 | *Patient Satisfaction and Quality of Life Measures*

Patient perspective was reported in three of the five studies. Dinsdale et al. found that 100% of patients reported overall improvement from treatment. Burillo-Martinez et al., found that on a scale of 0–10, with 10 being the most satisfied, the mean satisfaction score was 8.75 with 100% of patients saying that they would repeat treatment with PDL [16]. Further, 86% of patients studied by Kottler et al. felt that their telangiectasias were improved or strongly improved after treatment [18].

Two studies looked beyond reported patient satisfaction and measured the impact of PDL treatment on quality of life. Dinsdale et. al, utilized the Hospital Anxiety and Depression Scale (HADS), focused on assessing anxiety and depression, and the Adapted Satisfaction with Appearance Scale (ASWAP), which measures body image dissatisfaction and social discomfort related to appearance. While there was no significant improvement in HADS, there was significant improvement in the ASWAP, with mean scores decreasing by 13.9 (lower scores indicate lower dissatisfaction and distress) [17]. Kottler et al. used the Skindex score, which incorporates questions that assess three dimensions of quality of life: emotions, physical symptoms, and functioning. The higher the score, the greater the negative impact on quality of life. After treatment, there was a significant mean score reduction by 43.8%, with scores decreasing across all three components of Skindex (Table 1) [18].

3.1.1.6 | *Adverse Effects*

Three of the five studies quantified adverse effects (AEs). A pooled analysis was conducted across the 63 total patients included in these studies. AEs experienced were as follows: pigmentary alteration (9.5%), localized epidermal blistering (7.9%), bruising (7.9%), oozing/crusts (6.3%), and edema (6.3%). There was no evidence of scarring. No serious AEs, including worsening of underlying SSc, were reported (Table 3).

3.1.2 | *Intense Pulsed Light (IPL)*

Two articles investigated the use of IPL for SSc-associated telangiectasias in a total of 36 patients (Table 1) [17, 19]. Both

10969101, 2026, 9, Downloaded from https://onlinelibrary.wiley.com/doi/10.1002/lsm.70184 by University Of California Irvine Science Library Serials, Wiley Online Library on [06/11/2026]. See the Terms and Conditions (https://onlinelibrary.wiley.com/terms-and-conditions) on Wiley Online Library for rules of use; OA articles are governed by the applicable Creative Commons License

TABLE 2 | Device settings.

	# of Patients	Device used	Wavelength	Fluence	Pulse duration	Spot size
Systemic sclerosis						
Dinsdale et al. [17]	19	PDL	595 nm	9 J/cm^2	1.5 ms	7 mm
Kottler et al. [18]	21	PDL	595 nm	7.62 (mean) J/cm^2	0.5 ms	7 mm
Ciatti et al. [14]	8	PDL	585 nm	5–7 J/cm^2	0.45 ms	5 mm
Burillo-Martinez et al. [16]	23	PDL	585 nm	7–8.5 J/cm^2	0.5 ms	7 mm
Halachmi et al. [15]	16	PDL	585 nm	5.5–7 J/cm^2	0.45 ms	5–7 mm
Dinsdale et al. [17]	19	IPL	550–1100 nm	28–30 J/cm^2	—	—
Murray et al. [19]	20	IPL	550–1100 nm	24–36 J/cm^2	2–6 ms	—
Lupus erythematosus						
Díez et al. [22]	9	PDL	595 nm	11 J/cm^2	2 ms	7 mm
Baniandrés et al. [21]	6[a]	PDL	585 nm	5–7.75 J/cm^2	0.45 ms	5 mm
			595 nm	6–13 J/cm^2	1.5–10 ms	7 mm
Núñez et al. [20]	4	PDL	585 nm	6.75–7.75 J/cm^2	0.45 ms	5 mm
Li et al. [23]	1[b]	IPL	590–1200 nm	10–12 J/cm^2	4–5 ms	15 × 35 nm
			530–650 nm	10–12 J/cm^2	4–5 ms	15 × 35 nm

Abbreviations: J, joules; LE, lupus erythematosus; mm, millimeters; ms, milliseconds; SSc, systemic scleroderma.
[a]Only the 6 patients (14 total) with telangiectasias were included.
[b]Two different filters were used during each laser treatment session, leading to two different wavelengths

articles used similar device settings (Table 2) and performed a series of three treatments in most patients [17, 19].

The protocol for the 2014 trial by Dinsdale et al. was discussed above, with improvements in appearance noted at nearly all time points. For IPL, the median change in the number of lesions was −3 (range −6 to 1) [17]. Murray et al. similarly assessed changes based on laser doppler imaging, which showed a significant decrease in perfusion from baseline at 1- and 6-month follow-up, however no significant difference at 12-month follow-up. Clinical grading of photographs was also performed, as 75% were described as 'improved' or 'much improved' at 1- and 6-month visits and 63.5% at 12 months [19].

3.1.2.1 | *Adverse Effects*

The treatments were largely well-tolerated, as Dinsdale et al. documented mild erythema only noted by the device operator and Murray et al. reported two patients with transient side effects of facial edema and skin blistering [17, 19].

3.1.3 | *PDL Versus IPL*

The article by Dinsdale et al. is also pertinent in that it was a split-side, within-subject trial, providing direct comparison between PDL and IPL. Greater improvement was seen with PDL, both when comparing clinical photography scores and dermoscopy, and more patients preferred PDL over IPL. However, while no adverse effects were noted by patients from IPL treatment, most patients experienced transient purpura from PDL [17].

Dinsdale et al. also uniquely utilized laser doppler imaging, which maps blood flow over an area, in assessment of PDL efficacy. This technique utilizes two lasers, with the green laser (532 nm) imaging superficial, smaller blood vessels such as capillaries and the red laser (633 nm) focused on deeper, larger blood vessels. A decrease in perfusion would indicate a positive treatment effect. For images taken with both green and red lasers, telangiectasia perfusion decreased following treatment by both PDL and IPL. There was no change in blood flow between the 16 week and 9 month follow-up visit for both the green and red lasers indicating longevity of response [17].

3.2 | Lupus Erythematosus

3.2.1 | *PDL*

Of the eight articles included in this review on PDL, three specifically focused on patients with LE (Table 1). Patients with a variety of LE-associated skin findings received PDL treatment; however, only those with documented telangiectasias are discussed in this review, yielding a cumulative total of 18 patients. A variety of parameters were measured including number of treatments needed, physician opinion on visual appearance, patient satisfaction, histopathological findings, and AEs.

3.2.1.1 | *Laser Settings*

Laser settings similarly varied across studies. Spot size ranged from 5 to 7 mm, pulse duration ranged from 0.45 to 10 ms, and fluence ranged from 5 to 11 with devices of 585 or 595 nm (Table 2).

10969101, 2026, 9, Downloaded from https://onlinelibrary.wiley.com/doi/10.1002/lsm.70184 by University Of California Irvine Science Library Serials, Wiley Online Library on [06/11/2026]. See the Terms and Conditions (https://onlinelibrary.wiley.com/terms-and-conditions) on Wiley Online Library for rules of use; OA articles are governed by the applicable Creative Commons License

TABLE 3 | Pooled statistics on the outcomes of pulsed-dye laser treatments.

	Number of treatments needed	Quantitative assessment of telangiectasias	Impact on quality of life	Adverse effects
Systemic sclerosis	Mean: 3.12[1,2]	Median: −3[4]	HADS: No change[4]	Pigmentary alteration: 9.5%[2,4,5] Localized epidermal blistering: 7.9%[2,4,5] Bruising: 7.9%[2,4,5] Oozing/crusts: 6.3%[2,4,5]
		Range: −10 to 0[4]	ASWAP: Significant decrease[4]	
	Range: 1–7[2,3]	Average Clearance: 95%[1]	Skindex: Significant decrease[5]	Edema: 6.3%[2,4,5]
Lupus erythematosus	Mean: 2[6] Range: 1–6[6,7]	Average clearance: 71%[6,7]	Not assessed.	Slight transient hyperpigmentation: 10%[6,7]

Abbreviations: ASWAP, Adapted Satisfaction with Appearance Scale; HADS, Hospital Anxiety and Depression Scale.
[1]Halachmi et al. [15];
[2]Burillo-Martinez et al. [16];
[3]Ciatti et al. [14];
[4]Dinsdale et al. [17];
[5]Kottler et al. [18];
[6]Baniandrés et al. [21];
[7]Núñez et al. [20].

3.2.1.2 | *Number of Treatments Needed*

The first case series was published in 1996 by Núñez et al. and included four patients with what was described as telangiectatic chronic erythema of cutaneous LE (CLE). These patients received 3–6 treatments [20]. Seven years later, the same research group led by Baniandrés et al. identified six additional patients who were noted to have telangiectasias associated with CLE. The mean number of sessions required was 2.5 (range 1–5) and the median was 2 (Table 1) [21].

3.2.1.3 | *Physician Opinion on Quantity and Quality of Telangiectasias after Treatment*

In order to analyze improvement and clearance, Núñez et al. compared pre-treatment and post-treatment photographs that were reviewed by three blinded dermatologists. At 16 weeks follow-up, clearance was considered "excellent" by dermatologists for all four cases, with greater than 75% clearance [20]. Baniandrés et al. also noted average clearance of 67.5% (range 50%–80%) with a 75% median. This study also noted that, of all skin findings (including atrophy and hyperkeratosis), the most beneficial results were obtained with telangiectasias and erythema, with telangiectasias showing the most improvement results (Table 1) [21]. The average clearance between these two studies was 71% (Table 3).

3.2.1.4 | *Histopathology*

Post-treatment histologic examination by Núñez et al. showed a reduction in the diameter of blood vessels for all four patients [20]. Díez et al. performed biopsies before treatment (BT), 10 min immediately after laser treatment (IP), and 4 weeks after final laser treatment (PT). BT and IP biopsies had thicker vessel walls with a double line trace involving the luminal face of endothelial cells and a branched distribution of staining involving the stromal face. For PT biopsies, vessel appeared as single thin lines on the luminal side with no branching on the stromal side. Additionally, superficial vessel area was significantly reduced after treatment in all 8 patients [22].

3.2.1.5 | *Patient Satisfaction and Opinion on the Quality of Telangiectasias After Treatment*

Only Núñez et al. reported on patient perspective, citing that all four patients felt improvement was excellent at 16 weeks follow-up [20].

3.2.1.6 | *Adverse Effects*

Of the 10 patients pooled from both studies, only one instance of "slightly transient hyperpigmentation" was observed. There were no other AEs reported, including worsening of underlying CLE (Table 3) [20, 21].

3.2.2 | *IPL*

One case report detailed the use of IPL for facial telangiectasia and acne-induced post-inflammatory erythema in a patient with lupus [23], with device settings listed in Table 2. After 5 monthly treatments, significant improvement in capillary dilation and erythema was observed.

10969101, 2026, 9, Downloaded from https://onlinelibrary.wiley.com/doi/10.1002/lsm.70184 by University Of California Irvine Science Library Serials, Wiley Online Library on [06/11/2026]. See the Terms and Conditions (https://onlinelibrary.wiley.com/terms-and-conditions) on Wiley Online Library for rules of use; OA articles are governed by the applicable Creative Commons License

3.2.2.1 | *Adverse Effects*

Transient mild erythema during treatment was seen; however, no other adverse events occurred, and lupus disease activity remained stable during and 6 months after treatment (Table 1) [23].

4 | Discussion

Telangiectasias can be distressing and are often located in visible locations in both SSc and LE. While there are several devices available to treat vascular lesions, PDL has been reported in the literature most commonly for treatment of telangiectasia associated with SSc and LE, with a smaller number of reports available using IPL.

The articles included in our review demonstrate that across a variety of metrics, PDL resulted in an improvement in telangiectasias associated with SSc and LE. Improvements were also documented with IPL; however, this literature is more limited, with one study demonstrating superiority of PDL over IPL when evaluating degree of improvement. A reduction in the number of telangiectasias and visual improvement was noted by dermatologists in all studies. Patients also reported satisfaction with improved quality of life. Laser settings varied across all studies, making it difficult to compare the efficacy of the different parameters. In general, authors used shorter pulse durations for PDL (0.45–1.5 ms). Most studies also used higher energies for PDL (range: 5–9 J/cm^2) with a spot size ranging from 5 to 7 mm, which was tolerated without any major side effects. However, given the lack of comparative studies and variation between individual devices, definitive recommendations for treatment would be premature.

There is evidence to suggest that telangiectasias due to SSc and LE may be more recalcitrant than sporadic telangiectasias, necessitating a greater number of treatments. This is likely secondary to endovascular pathology unique to SSc and LE which may lead to more refractory disease or inflammatory mediators that promote vessel recurrence and/or formation. Hallmark features of microvascular change in SSc include intimal proliferation, perivascular fibrosis, and thickening of the basement membrane thought to be driven in part by endothelial cells undergoing mesenchymal transition [24, 25]. In SLE, endovascular change is driven by immune-complex deposition leading to leukocyte infiltration, endothelial dysfunction, and inflammation [26, 27].

The efficacy and safety of PDL treatment for idiopathic facial telangiectasias are well established [2, 28]. While overall well-tolerated, short-term side effects include purpura and edema, with crusting and bleeding less commonly observed, and long-term adverse events include pigmentary changes and scarring reported rarely [2, 29]. Similar AEs were observed when using the same device for treating SSc and LE.

While most studies used digital photographs for comparison, two studies evaluated microscopic changes. Effects at the cellular level remain unexplored, likely due to the invasive nature of traditional biopsy and histological evaluation. Optical coherence tomography (OCT) is an emerging technology used for performing cross-sectional imaging. It is akin to ultrasound imaging except that it uses light rather than sound to provide information about tissue structure in real time and on the micron scale. A recent study utilized OCT to better understand the efficacy of laser therapy for vascular lesions including telangiectasias, spider veins, and cherry angiomas. This modality safely allowed for the evaluation of vessel morphology and blood flow which may pave the way for tailored laser treatment [30]. Future studies could consider the use of OCT for telangiectasias in patients with SSc and LE to better characterize how these lesions differ from sporadic telangiectasias to help establish a consensus on optimal laser settings.

Other limitations of the studies in our review include varying lengths of follow-up and a lack of attention given to the systemic therapies that patients were using at the time of laser treatment. With persistent disease, patients are likely to continue developing new lesions and it would be helpful to analyze the efficacy of PDL within the context of therapy and control of underlying disease. Additionally, with regards to studies that focused on patients with LE, there was no diagnostic distinction between patients with DLE and other forms of CLE such as acute or subacute CLE. This is an important point of investigation because telangiectasias present in DLE typically exhibit greater atrophy and scarring, which leads to vascular remodeling, membrane thickening, and dermal fibrosis [31]. Thus, in order to optimize therapy, it would be beneficial to study laser settings in larger cohorts of patients with different forms of CLE.

Future areas of study include other light-based devices and their efficacy for treatment of SSc and LE related telangiectasias. Other lasers including the long-pulse 532 nm Nd:YAG have been shown to be effective for the treatment of sporadic telangiectasias on the leg [32] and face [33]. However, we found no published studies examining their use in SSc and LE related telangiectasias nor comparative studies against PDL. Additionally, as mentioned previously, there is limited literature on IPL therapy for treatment of SSc and LE related telangiectasias [17, 19].

Finally, multimodality likely provides maximal therapeutic impact. Integrating laser therapy with topical vasoconstrictors may enhance therapeutic efficacy, although realistically this may not be feasible for certain patients with underlying CTDs given physiologic vasoconstriction from their disease (ie. Raynaud's syndrome). Further investigation is warranted [34].

5 | Conclusion

Overall, PDL and IPL appear to be relatively safe and effective treatments for managing SSc and LE associated telangiectasias. More treatment sessions may be required compared to sporadic idiopathic telangiectasias. Future randomized controlled studies with more objective outcomes would help better characterize the effect of light-based devices in this unique patient population.

Conflicts of Interest

Dr. Kristen M. Kelly: Consultant Primus pharmaceuticals, Candela, Cutera, Sciton, Michaelson Diagnostics; Research grants or funding Candela, Lutronic, FDZJ, Michaelson Diagnostics, Sciton. Equipment provided to clinic: Cutera, Michaelson Diagnostics, FDZJ,

10969101, 2026, 9, Downloaded from https://onlinelibrary.wiley.com/doi/10.1002/lsm.70184 by University Of California Irvine Science Library Serials, Wiley Online Library on [06/11/2026]. See the Terms and Conditions (https://onlinelibrary.wiley.com/terms-and-conditions) on Wiley Online Library for rules of use; OA articles are governed by the applicable Creative Commons License

Lutronic; Board Member ASLMS. Dr. Michelle S. Min: Consultant for BMS and UCB; Royalties from McGraw Hill; Research funding from Amgen, AZ, BI, BMS, Priovant.

Data Availability Statement

Data sharing not applicable to this article as no datasets were generated or analysed during the current study.

References

1. T. Wall, "Current Concepts: Laser Treatment of Adult Vascular Lesions," *Seminars in Plastic Surgery* 21, no. 3 (2007): 147–158, https://doi.org/10.1055/s-2007-991183.

2. J. M. Smit, C. G. Bauland, D. S. Wijnberg, and P. H. M. Spauwen, "Pulsed Dye Laser Treatment, a Review of Indications and Outcome Based on Published Trials," *British Journal of Plastic Surgery* 58, no. 7 (2005): 981–987, https://doi.org/10.1016/j.bjps.2005.04.057.

3. K. Nouri, M. P. Rivas, M. Stevens, et al., "Comparison of the Effectiveness of the Pulsed Dye Laser 585 nm Versus 595 m in the Treatment of New Surgical Scars," *Lasers in Medical Science* 24, no. 5 (2009): 801–810, https://doi.org/10.1007/s10103-009-0698-8.

4. R. R. Anderson and J. A. Parrish, "Selective Photothermolysis: Precise Microsurgery by Selective Absorption of Pulsed Radiation," *Science* 220 (1983): 524–527.

5. Q. Zhai, S. Cheng, R. Liu, J. Xie, X. Han, and Z. Yu, "Meta-Analysis of the Efficacy of Intense Pulsed Light and Pulsed-Dye Laser Therapy in the Management of Rosacea," *Journal of Cosmetic Dermatology* 23, no. 12 (2024): 3821–3827, https://doi.org/10.1111/jocd.16549.

6. S. Bajaj, J. Tao, D. A. Hashemi, and R. G. Geronemus, "Weekly Pulsed Dye Laser Treatments for Port-Wine Birthmarks in Infants," *JAMA Dermatology* 160, no. 6 (2024): 606–611, https://doi.org/10.1001/jamadermatol.2024.0293.

7. A. A. Shah, F. M. Wigley, and L. K. Hummers, "Telangiectases in Scleroderma: A Potential Clinical Marker of Pulmonary Arterial Hypertension," *The Journal of Rheumatology* 37, no. 1 (2010): 98–104, https://doi.org/10.3899/jrheum.090697.

8. F. van den Hoogen, D. Khanna, J. Fransen, et al., "2013 Classification Criteria for Systemic Sclerosis: An American College of Rheumatology/European League Against Rheumatism Collaborative Initiative," *Annals of the Rheumatic Diseases* 72, no. 11 (2013): 1747–1755, https://doi.org/10.1136/annrheumdis-2013-204424.

9. H. Ennis, A. L. Herrick, C. Cassidy, C. E. Griffiths, and H. L. Richards, "A Pilot Study of Body Image Dissatisfaction and the Psychological Impact of Systemic Sclerosis-Related Telangiectases," *Clinical and Experimental Rheumatology* 31, no. 2 Suppl 76 (2013): 12–17.

10. D. Accapezzato, R. Caccavale, M. P. Paroli, et al., "Advances in the Pathogenesis and Treatment of Systemic Lupus Erythematosus," *International Journal of Molecular Sciences* 24, no. 7 (2023): 6578, https://doi.org/10.3390/ijms24076578.

11. P. E. Bechet, "Lupus Erythematosus Telangiectodes," *Archives of Dermatology* 58 (1948): 128, https://doi.org/10.1001/archderm.1948.01520210038006.

12. L. Uva, D. Miguel, C. Pinheiro, J. P. Freitas, M. Marques Gomes, and P. Filipe, "Cutaneous Manifestations of Systemic Lupus Erythematosus," *Autoimmune Diseases* 2012 (2012): 834291, https://doi.org/10.1155/2012/834291.

13. L. R. Jewett, M. Hudson, V. L. Malcarne, M. Baron, and B. D. Thombs, "Sociodemographic and Disease Correlates of Body Image Distress Among Patients With Systemic Sclerosis," *PLoS One* 7, no. 3 (2012): e33281, https://doi.org/10.1371/journal.pone.0033281.

14. S. Ciatti, J. Varga, and S. S. Greenbaum, "The 585 Nm Flashlamp-Pumped Pulsed Dye Laser for the Treatment of Telangiectases in Patients With Scleroderma," *Journal of the American Academy of Dermatology* 35, no. 3 Pt 1 (1996): 487–488, https://doi.org/10.1016/s0190-9622(96)90638-6.

15. S. Halachmi, O. Gabari, S. Cohen, R. Koren, D. B. Amitai, and M. Lapidoth, "Telangiectasis in CREST Syndrome and Systemic Sclerosis: Correlation of Clinical and Pathological Features With Response to Pulsed Dye Laser Treatment," *Lasers in Medical Science* 29, no. 1 (2014): 137–140, https://doi.org/10.1007/s10103-013-1298-1.

16. S. Burillo-Martinez, M. Prieto-Barrios, V. Velasco-Tamariz, F. Tous-Romero, S. López-Gómez, and L. Maroñas-Jimenez, "Case Series of Pulsed Dye Laser Treatment of Telangiectasia in 23 Patients With Systemic Sclerosis," *International Journal of Dermatology* 56, no. 8 (2017): e165–e167, https://doi.org/10.1111/ijd.13595.

17. G. Dinsdale, A. Murray, T. Moore, et al., "A Comparison of Intense Pulsed Light and Laser Treatment of Telangiectases in Patients With Systemic Sclerosis: A Within-Subject Randomized Trial," *Rheumatology* 53, no. 8 (2014): 1422–1430, https://doi.org/10.1093/rheumatology/keu006.

18. D. Kottler, L. Dupechez, N. Martin Silva, et al., "Efficacy, Tolerance and Acceptability of Pulsed Dye Laser on Facial and Neckline Telangiectasias in Systemic Scleroderma: A Prospective Open-Label Monocentric Study in 21 Patients," *Journal of Cosmetic and Laser Therapy* 25, no. 5–8 (2023): 77–85, https://doi.org/10.1080/14764172.2024.2313472.

19. A. K. Murray, T. L. Moore, H. Richards, H. Ennis, C. E. M. Griffiths, and A. L. Herrick, "Pilot Study of Intense Pulsed Light for the Treatment of Systemic Sclerosis-Related Telangiectases," *British Journal of Dermatology* 167, no. 3 (2012): 563–569, https://doi.org/10.1111/j.1365-2133.2012.11019.x.

20. M. Núñez, P. Boixeda, E. S. Miralles, R. F. de Misa, and A. Ledo, "Pulsed Dye Laser Treatment of Telangiectatic Chronic Erythema of Cutaneous Lupus Erythematosus," *Archives of Dermatology* 132, no. 3 (1996): 354–355.

21. O. Baniandrés, P. Boixeda, P. Belmar, and A. Pérez, "Treatment of Lupus Erythematosus With Pulsed Dye Laser," *Lasers in Surgery and Medicine* 32, no. 4 (2003): 327–330, https://doi.org/10.1002/lsm.10169.

22. M. T. T. Díez, P. Boixeda, C. Moreno, J. A. González, M. L. Zamorano, and P. J. Olasolo, "Histopathology and Immunohistochemistry of Cutaneous Lupus Erythematosus After Pulsed Dye Laser Treatment," *Dermatologic Surgery* 37, no. 7 (2011): 971–981, https://doi.org/10.1111/j.1524-4725.2011.02041.x.

23. Z. Li, J. Lu, and M. Wu, "Intense Pulsed Light Improves Facial Telangiectasia and Acne-Induced Post-Inflammatory Erythema in Systemic Lupus Erythematosus Patient: A Case Report," *Journal of Cosmetic Dermatology* 24, no. 8 (2025): e70389, https://doi.org/10.1111/jocd.70389.

24. P. A. Nicolosi, E. Tombetti, N. Maugeri, P. Rovere-Querini, S. Brunelli, and A. A. Manfredi, "Vascular Remodelling and Mesenchymal Transition in Systemic Sclerosis," *Stem Cells International* 2016 (2016): 4636859, https://doi.org/10.1155/2016/4636859.

25. J. Ko, M. Noviani, V. R. Chellamuthu, S. Albani, and A. H. L. Low, "The Pathogenesis of Systemic Sclerosis: The Origin of Fibrosis and Interlink With Vasculopathy and Autoimmunity," *International Journal of Molecular Sciences* 24, no. 18 (2023): 14287, https://doi.org/10.3390/ijms241814287.

26. L. Atehortúa, M. Rojas, G. M. Vásquez, and D. Castaño, "Endothelial Alterations in Systemic Lupus Erythematosus and Rheumatoid Arthritis: Potential Effect of Monocyte Interaction," *Mediators of Inflammation* 2017 (2017): 9680729, https://doi.org/10.1155/2017/9680729.

27. L. Moschetti, S. Piantoni, E. Vizzardi, et al., "Endothelial Dysfunction in Systemic Lupus Erythematosus and Systemic Sclerosis: A Common Trigger for Different Microvascular Diseases," *Frontiers in Medicine* 9 (2022): 849086, https://doi.org/10.3389/fmed.2022.849086.

10969101, 2026, 9, Downloaded from https://onlinelibrary.wiley.com/doi/10.1002/lsm.70184 by University Of California Irvine Science Library Serials, Wiley Online Library on [06/11/2026]. See the Terms and Conditions (https://onlinelibrary.wiley.com/terms-and-conditions) on Wiley Online Library for rules of use; OA articles are governed by the applicable Creative Commons License

28. M. Alam, J. S. Dover, and K. A. Arndt, "Treatment of Facial Telangiectasia With Variable-Pulse High-Fluence Pulsed-Dye Laser: Comparison of Efficacy With Fluences Immediately Above and Below the Purpura Threshold," *Dermatologic Surgery* 29, no. 7 (2003): 681–685, https://doi.org/10.1046/j.1524-4725.2003.29181.x.

29. S. Iyer and R. E. Fitzpatrick, "Long-Pulsed Dye Laser Treatment for Facial Telangiectasias and Erythema: Evaluation of a Single Purpuric Pass Versus Multiple Subpurpuric Passes," *Dermatologic Surgery* 31, no. 8 (2005): 898–903, https://doi.org/10.1097/00042728-200508000-00002.

30. K. Harst, J. Welzel, and S. Schuh, "How Efficient Is Laser Therapy for Telangiectasias, Spider Veins, and Cherry Angiomas?-A Study Using Dynamic Optical Coherence Tomography," *Lasers in Surgery and Medicine* 55, no. 7 (2023): 625–635, https://doi.org/10.1002/lsm.23676.

31. C. Bitar, T. D. Menge, and M. P. Chan, "Cutaneous Manifestations of Lupus Erythematosus: A Practical Clinicopathological Review for Pathologists," *Histopathology* 80, no. 1 (2022): 233–250, https://doi.org/10.1111/his.14440.

32. R. M. Adrian, "Treatment of Leg Telangiectasias Using a Long-Pulse Frequency-Doubled Neodymium:YAG Laser at 532 nm," *Dermatologic Surgery* 24, no. 1 (1998): 19–23, https://doi.org/10.1111/j.1524-4725.1998.tb04046.x.

33. L. Bennardo, C. Patruno, E. Zappia, et al., "Combination of Specific Vascular Lasers and Vascular Intense Pulsed Light Improves Facial Telangiectasias and Redness," *Medicina* 58, no. 5 (2022): 651, https://doi.org/10.3390/medicina58050651.

34. G. Micali, P. A. Gerber, F. Lacarrubba, and G. Schäfer, "Improving Treatment of Erythematotelangiectatic Rosacea With Laser And/Or Topical Therapy Through Enhanced Discrimination of Its Clinical Features," *The Journal of Clinical and Aesthetic Dermatology* 9, no. 7 (2016): 30–39.

10969101, 2026, 9, Downloaded from https://onlinelibrary.wiley.com/doi/10.1002/lsm.70184 by University Of California Irvine Science Library Serials, Wiley Online Library on [06/11/2026]. See the Terms and Conditions (https://onlinelibrary.wiley.com/terms-and-conditions) on Wiley Online Library for rules of use; OA articles are governed by the applicable Creative Commons License