

Dynamic Morphology of Clear Corneal Cataract Incisions

Peter J. McDonnell, MD,¹ Mehran Taban, BS,¹ Melvin Sarayba, MD,¹ Bin Rao, MS,² Jun Zhang, PhD,² Rhett Schiffman, MD, MS, MHJA,³ Zhongping Chen, PhD²

Objective: Clear corneal cataract incisions without sutures allow for rapid visual rehabilitation after phacoemulsification but might be associated with an increased risk of postoperative infection. The goal of this study was to examine in vitro dynamic changes in unhealed clear corneal cataract incisions that might adversely affect the risk of intraocular infection.

Design: Laboratory investigation.

Methods: Self-sealing clear corneal incisions were created in cadaveric human and rabbit eyes, and intraocular pressure was controlled with an infusion cannula. Incisions were imaged in real time using optical coherence tomography as intraocular pressure was varied. Using an artificial anterior chamber, India ink was applied to the surface of cadaveric human corneas with clear corneal incisions to detect possible flow of surface fluid along the incision. Intraocular pressure was varied by raising and lowering the infusion bottle so as to simulate the variation in intraocular pressure that would occur with successive blinks.

Results: Optical coherence tomography demonstrated variation of corneal wound morphology in response to changes in intraocular pressure. Higher intraocular pressures were associated with close apposition of the wound edges, with no tendency for wound leakage. At low intraocular pressures, however, wound edges tended to gape, starting at the internal aspect of the wound. One incision opened along the entire length, allowing fluid flow across the cornea. Histologic examination revealed India ink particles in all incisions for up to three fourths of the length of the wound.

Conclusions: Transient reduction of intraocular pressure might result in poor wound apposition in clear corneal incisions, with the potential for fluid flow across the cornea and into the anterior chamber, with the attendant risk of endophthalmitis. *Ophthalmology* 2003;110:2342–2348 © 2003 by the American Academy of Ophthalmology.

Self-sealing clear corneal incisions in the temporal cornea offer several advantages with phacoemulsification, including obviating the need for suturing, minimizing induction of astigmatism, decreasing bleeding and subconjunctival hemorrhage, and speeding the recovery of visual acuity.^{1,2} A progressive increase in the percentage of surgeons preferring clear corneal incisions over scleral tunnel incisions in the United States and Europe has occurred over the past decade.³ Some studies, however, reveal an increased inci-

dence of postoperative endophthalmitis after clear corneal cataract incisions^{4–8} (Jensen et al. *Invest Ophthalmol Vis Sci* [CD-ROM], 2002). Powe et al⁹ performed the only meta-analysis of the English literature, reviewing studies from 1979 to 1991 (a period that predates self-sealing clear corneal incisions) and reported an incidence of 0.13% for acute endophthalmitis after cataract extraction. Reviewing patient records from 1992 to 1996, John and Noblitt⁴ reported incidences of acute endophthalmitis of 0.29% and 0.02% after cataract extraction with clear corneal and scleral tunnel incisions, respectively, representing an almost 15-fold increase in risk. Lertsumitkul et al⁸ reported a 3.5-fold increased risk of postoperative endophthalmitis with clear corneal temporal incisions compared with superior scleral incisions. Nagaki et al⁶ noted a 5.6-fold increase risk of endophthalmitis with clear corneal incisions compared with sclerocorneal incisions. Colleaux and Hamilton⁵ reported a 2.6-fold increase in risk of endophthalmitis with clear corneal incisions, although the statistical power of this study was limited such that the difference did not achieve statistical significance ($P = 0.14$). The suggestion of increased risk of acute endophthalmitis with self-sealing clear corneal incisions raises the question whether it might be possible for surface bacteria to traverse these clear corneal incisions during the postoperative period.

Originally received: January 23, 2003.

Accepted: April 8, 2003.

Manuscript no. 230037.

¹ Department of Ophthalmology, University of California Irvine, Irvine, California.

² Department of Biomedical Engineering, University of California Irvine, Irvine, California.

³ Allergan, Inc., Irvine, California.

Supported in part by NIH grants EY10335, RR01192, EB00293, and CA091717, by an award from the Alcon Research Institute, and by an unrestricted gift from Allergan, Inc.

Dr Rhett Schiffman is an employee of Allergan, Inc. All other authors have no commercial or proprietary interest in any of the instruments or products used in this study.

Correspondence to Peter J. McDonnell, MD, Wilmer Ophthalmological Institute, Maumenee 727, 600 North Wolfe Street, Baltimore, MD 21287-9278. E-mail: pmcdonn1@jhmi.edu.

Surgeons typically examine the clear corneal incisions at the completion of the procedure by inflating the anterior chamber with balanced salt solution and applying pressure to the anterior cornea to check for leakage from the wound. If there is some leakage, the surgeon might elect to place a cannula into the wound and inject balanced salt solution, so as to “hydrate” the wound and allow the swollen stroma to appose the wound edges and prevent fluid flow through the wound. Such tests, however, make several assumptions, including that the eye will remain well pressurized during the early postoperative period, that the hydrated wound will not be rapidly deturgescenced by the corneal endothelium, and that the absence of aqueous outflow from the wound correlates with the inability of surface fluid from the tear film to flow into the wound, possibly contaminating the aqueous humor and predisposing to infection. However, intraocular pressure is known to vary in the postoperative period, frequently dropping to less than 5 mmHg,¹⁰ and telemetric intraocular pressure monitoring devices suggest that large fluctuations in intraocular pressure occur in individual eyes in response to blinking.¹¹ Coleman and Trokel¹² showed that, in the cannulated eye of a conscious human subject, voluntary blinking resulted in pressure spikes of 10 mmHg, whereas squeezing of the lids resulted in rises of intraocular pressure exceeding 80 mmHg. The possibility of imbibition of surface fluid through the self-sealing clear corneal wound into the anterior chamber in the early postoperative period is suggested by an apparently increased occurrence of endophthalmitis in up to 0.29% of cases^{4–8} (Jensen et al. Invest Ophthalmol Vis Sci [CD-ROM], 2002), the association of corneal wound infiltrates with endophthalmitis or the occurrence of wound infiltrates alone,^{13–19} and the occasional observation of a small air bubble in the anterior chamber the day after surgery (Randall Olson, personal communication, July 20, 2002).

We describe a set of experiments to determine whether clear corneal cataract wounds might permit flow of surface fluid into the wound and across the cornea, at least intermittently, during the early postoperative period. Optical coherence tomography (OCT) was used to examine incision morphology in situ as intraocular pressure was varied. To test for fluid inflow into the corneal wound, as opposed to fluid outflow, India ink applied to the corneal surface was used to look for evidence of penetration of surface fluid into the corneal incisions in histologic sections of fixed tissue.

Materials and Methods

Tissue Preparation and Surgical Procedure

Intact human globes were obtained from the San Diego Eye Bank. Donor corneoscleral segments were obtained from the Donor Network of Arizona (Phoenix, AZ). Freshly enucleated New Zealand white rabbit eyes were obtained from a local abattoir. Globes were placed in a specially designed globe holder, and the eye was oriented so that the temporal cornea was placed at the 12-o'clock position under the operating microscope. A 23-gauge needle was inserted through the limbus at the 6 o'clock position, 180° away from the site for the clear corneal incision. Intraocular pressure was set by adjusting the height of the bottle of balanced salt solution connected to the 23-gauge needle with intravenous tubing.

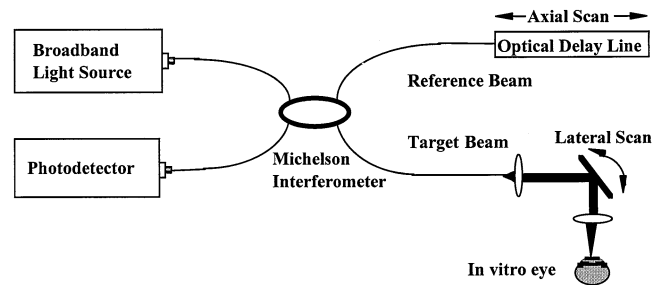


Figure 1. Schematic illustration of optical coherence tomography device used to image corneal incisions in enucleated eyes.

An experienced ophthalmic surgeon performed all surgical incisions. In three human globes, standard two-planned clear corneal incisions were created using a 3.0-mm disposable keratome (Alcon, Fort Worth, TX) under microscopic visualization. Incision tunnel lengths were varied from 2.0 to 2.5 mm. We tested for leakage of aqueous from the corneal incision by depressing the corneal surface peripheral to the incision using a cellulose acetate sponge.

In two human globes, nearly vertical peripheral corneal incisions were created with the same keratome blade to be able to contrast these incisions with the self-sealing incisions. To create these incisions, the keratome blade was oriented approximately perpendicular to the corneal surface and used to penetrate into the anterior chamber in a single plane.

Five human donor corneas were placed on an artificial anterior chamber (ALTK System, Moria/Microtech, Doylestown, PA), with the scleral rim secured in place. Intraocular pressure was maintained through infusion fluid from a bottle of balanced salt solution connected to the anterior chamber with intravenous tubing. The clear corneal incisions were then created as described previously for the intact human globes. India ink (Sanford Corp., Bellwood, IL) was then applied to the corneal surfaces to test for inflow of fluid as described later.

In two freshly enucleated rabbit globes, clear corneal incisions were created as described previously in the human eyes. These eyes were similarly cannulated to allow control of intraocular pressure.

Optical Coherence Tomography

Direct visualization of the corneal wound anatomy was achieved using OCT. Optical coherence tomography is a recently developed modality for high-resolution (2–10 μm) imaging of in vivo biologic tissue. It is similar to ultrasound imaging, except near infrared light is used instead of sound waves. This nondestructive, noncontact method for imaging tissue in situ takes advantage of the short coherence length of broadband light sources to perform micrometer-scale cross-sectional imaging of biologic tissues.^{20–23} The principle of OCT has been described in detail previously.²⁰ Figure 1 shows the OCT setup used in our experiment.²³ It is a fiber-based Michelson interferometer in which scanning the optical path length in the reference arm produces interference fringes, and the fringe envelope represents the scattering amplitude at different depths in the sample. Light from a broadband low-coherence source (center wavelength 1300 nm and bandwidth 70 nm) is coupled into a fiberoptic interferometer by a 2×2 fiber coupler and then split equally between the reference and target arms of the interferometer. Light backscattered from the tissue is coupled back into the fiber and forms interference fringes with the light reflected from the reference arms. High axial spatial resolution is possible,




Figure 2. Optical coherence tomography experimental setup. The human globe is placed in a special holder beneath the imaging lens. The globe is cannulated through the nasal limbus 180° away from the temporal self-sealing corneal incision.

because interference fringes are observed only when the path length differences between the light from the sample arm and the reference arm are within the coherence length of the source. Hence the axial resolution depends on the coherence length of the source (8 μm), and the lateral resolution depends on the beam waist of the focused beam (15 μm). After light is collected with a photodetector, the signal is digitized and processed with a personal computer. Two-dimensional, cross-sectional images are produced by raster scanning the beam with optical delay line (for depth scan) and a motorized stage (for lateral scan). Optical coherence tomography imaging is displayed in real time (two frames per second) while scanning progresses.

To image the corneal incisions, the eyes were oriented under the device, with the globe oriented vertically (Fig 2). The OCT device was used to scan across the anterior segment of the globe, so as to traverse the center of the corneal incision, showing the incision in profile.

Light Microscopy

To test for the morphologic evidence of ingress of surface fluid into the corneal wound, India ink was applied to the surface of the cornea after creation of the clear corneal incision. The ink was applied using three separate techniques, with each technique producing the same results. In one approach, the India ink was applied with a dropper onto the area of the cornea that included the superficial entrance site of the wound. In a second approach, a suction trephine (Katena Products, Inc., Denville, NJ) was applied to the cornea, creating a 9-mm diameter circular well around the 3-mm wound. Into this well was placed 2 or 3 drops of India ink. Finally, India ink was applied to a supersaturated cellulose sponge, which was lightly held in place against the site of the wound, and from which a small amount of India ink flowed to cover the adjacent corneal surface. The intraocular pressure was then varied

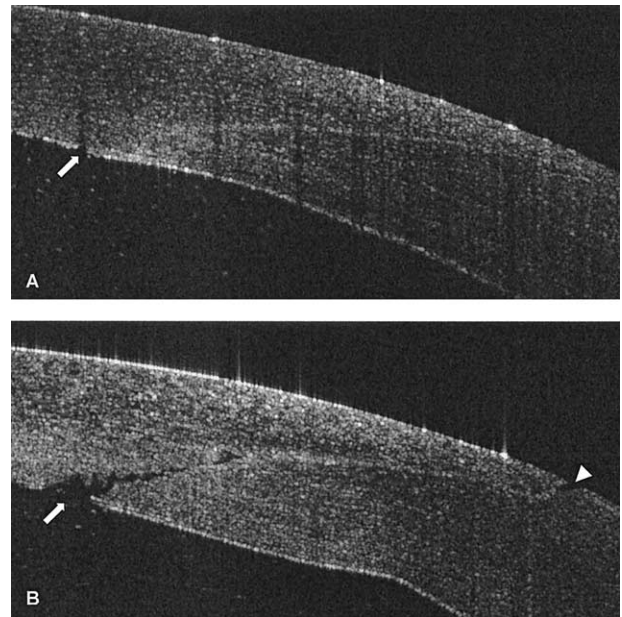


Figure 3. Optical coherence tomograph of two-planned clear corneal incision in human globe. **A**, Well-pressurized eye (intraocular pressure of 40 mmHg) with incision edges closely apposed everywhere except for slight separation of Descemet's membrane (arrow). The incision is visible as a bright line traversing the stroma. **B**, As intraocular pressure is varied, a wedge-shaped internal wound gap is seen (arrow), and a small wedge-shaped zone of separation of the superficial incision is apparent (arrowhead). The internal wound gap involves 39% of the incision.

(raised and lowered by raising and lowering the infusion bottle) so as to simulate the variation in intraocular pressure that would occur with 20 successive blinks, at the rate of approximately one blink every 5 seconds. The corneal surface was then gently irrigated with balanced salt solution to wash away the India ink present on the corneal surface. The specimen was then removed from the artificial anterior chamber and fixed in 10% buffered formaldehyde for 1 week. Histologic sections were then prepared through the cornea, with sections oriented radially from the 3-o'clock to the 9-o'clock position, so as to demonstrate the course of the clear corneal incisions from the corneal surface to Descemet's membrane.

Results

OCT of Self-Sealing Incisions

Optical cross-sections of rabbit and human clear corneal incisions imaged the incisions along their length. In general, the cornea showed some edema (decreased signal density and increased thickness) in the region of the incisions, and in particular in the posterior stroma peripheral to the entry site of the incision into the anterior chamber. In real time, the morphology of these wounds was not constant but varied in response to changes in the intraocular pressure. When the eyes were well pressurized (20 mmHg or higher), the chambers were deeply formed, and the wound edges were well apposed. The incision was visible as a bright line traversing the stroma, extending from the corneal surface to Descemet's membrane (Fig 3A). Pressure applied along the wound edge with a dry cellulose acetate sponge failed to result in egress of aqueous fluid. Elevation of intraocular pressure up to 40 to 50 mmHg did not result in any separation of the wound edges. As the

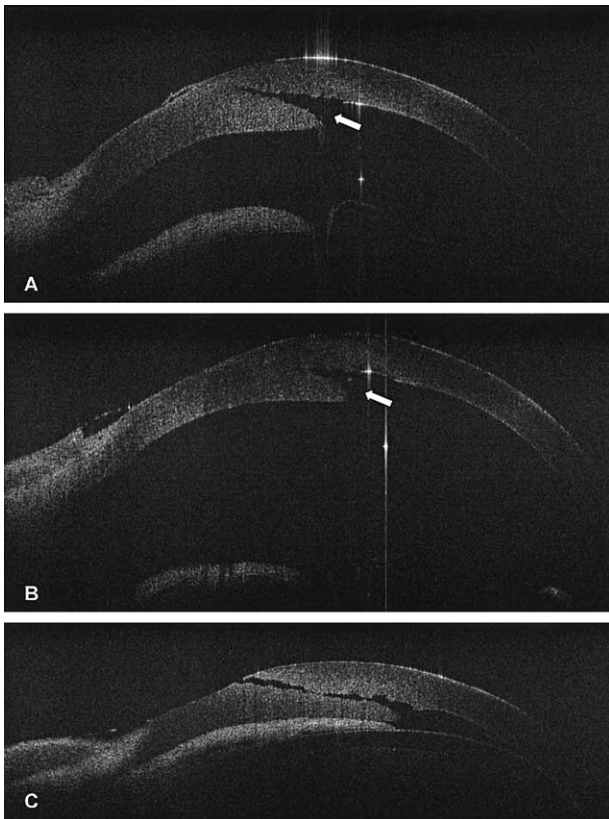


Figure 4. A, Optical coherence tomograph of clear corneal incision in well-pressurized rabbit eye without wound leak with wedge-shaped gap (arrow) extending along 76% of the incision length. B, Well-pressurized rabbit cornea with posterior wound gap (arrow) extending along 82% of the incision length, with deeply formed chamber and no clinically detectable wound leak. C, Reduction of intraocular pressure to 5 mmHg results in full-thickness gaping along the incision, with spontaneous egress of fluid from the corneal wound and progressive flattening of the anterior chamber. The iris is visualized between the cornea and anterior lens capsule.

infusion bottle was lowered to reduce intraocular pressure to 10 mmHg and below, the wound edges progressively separated (Fig 3B). The separation began at the internal aspect of the wound, with posterior migration of the posterior and peripheral wound leaflet. This separation resulted in a wedge-shaped gaping in the internal aspect of the incision. The incision imaged in Figure 3B gaped internally for up to 39% of the length of the incision, whereas as a percentage of the anteroposterior corneal thickness, the gape reached 64%. Occasionally, a wedge-shaped gaping of the cut ends of Bowman's layer and the anterior wound was demonstrable (Fig 3B).

In rabbit corneas, the degree of internal wound gaping exceeded that seen in humans, extending from 76% to 82% of the incision length (Fig 4A, B). The same type of pressure dependence of wound morphology was documented. In a well-pressurized eye of 20 mmHg or higher, the wound did not leak, and the superficial aspect of the wound was well apposed. As intraocular pressure was reduced by lowering the infusion bottle, the gaping extended anteriorly, until wound separation was visible from endothelial to epithelial aspects of the incision (Fig 4C). Coincident with this wound margin separation, the spontaneous flow of aqueous through the wound was observed, and the chamber became shallower. Raising the bottle of infusion fluid to again elevate intraocular pressure resulted in prompt (within a few seconds) closure of

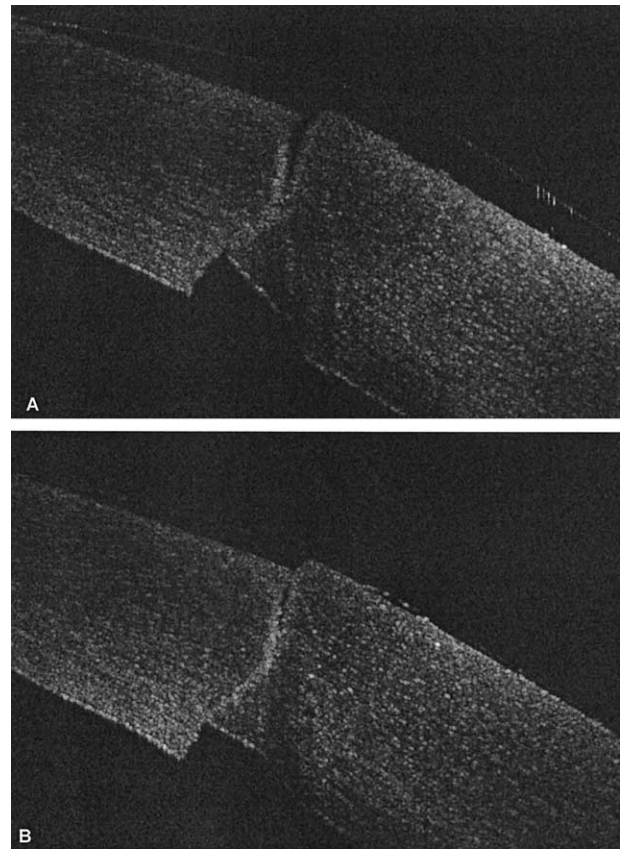


Figure 5. Vertical incision through peripheral cornea. Intraocular pressures of 20 mmHg and higher result in misalignment of wound edges at Descemet's membrane and superficial wedge-shaped separation along 52% of incision length (A). Reduction of intraocular pressure to 5 mmHg results in dramatic reduction of separation of incision edges (B).

the corneal wound at its superficial margin, termination of fluid leakage from the wound, and deepening of the anterior chamber. The initial closure of the incision occurred at the superficial aspect, so that flow through the wound ceased, although there remained a wedge-shaped gape at the internal aspect of the wound. As intraocular pressure continued to be raised, in most rabbit eyes and in all human eyes, the posterior and peripheral wound leaflets became apposed to the anterior and central cornea, with apparently complete closure of the wound.

OCT of Vertical Corneal Incisions

Images of vertical incisions also showed changes in response to variation of intraocular pressure. With intraocular pressures of 20 mmHg or higher, the anterior wound edges gaped open, with the posterior wound edges apparently forced together by the intraocular pressure (Fig 5A). It was common for these incisions to leak, at least intermittently, at these higher pressures, and pressure on the adjacent corneal surface elicited a brisk flow of aqueous. At low pressures of 5 mmHg or less, the wound edges became largely well apposed (Fig 5B). As intraocular pressure was again progressively raised, full-thickness separation of wound edges was achieved, and the wounds began to leak. Reduction of intraocular pressure was again followed by progressive reapposition of the incision edges, first at the internal margin of the incision and extending toward the external surface of the cornea.

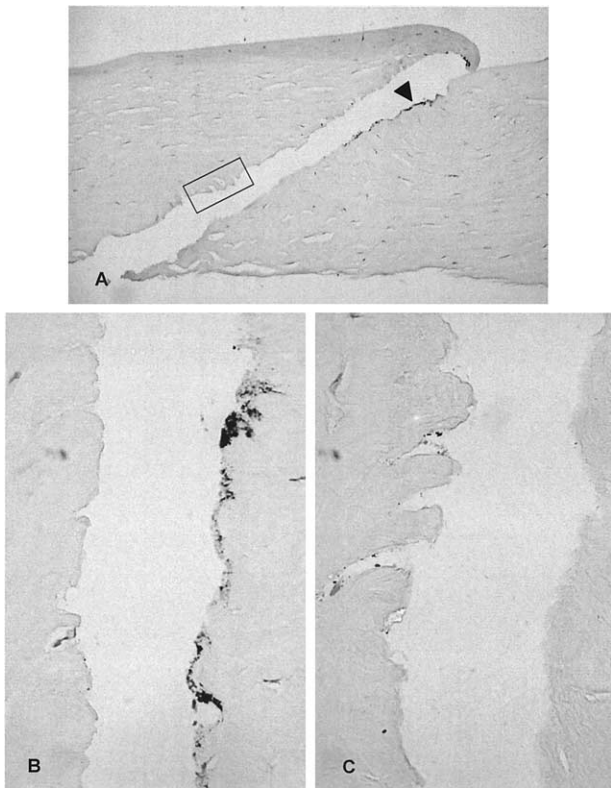


Figure 6. India ink penetration into clear corneal incision. **A**, Low-power micrograph demonstrates heavy, confluent accumulation of India ink particles (black arrowhead) adjacent to the superficial margin of the corneal incision (stain, hematoxylin–eosin; original magnification, $\times 20$). **B**, Higher power micrograph demonstrates heavy accumulation of India ink along the incision (stain, hematoxylin–eosin; original magnification, $\times 40$). **C**, High-power micrograph of the region indicated within the box in **A**. India ink particles are present within gaps between severed stromal lamellae at up to 73% of the incision length (stain, hematoxylin–eosin; original magnification, $\times 40$).

India Ink Penetration

Whether India ink was applied to the surface of the cornea as a drop, with a supersaturated cellulose sponge, or placed within a well, the India ink quickly became visible through the operating microscope within the clear corneal incisions. Histologic examination of the wounds confirmed partial penetration of India ink particles along the edges of the incisions in every cornea (Fig 6). Ink particles were present within the incisions generally in a confluent distribution (Fig 6A, B) involving the superficial one third to one half of the length of the incision. Deeper to the confluent aggregate of India ink, isolated foci of ink particles were seen usually adherent to and trapped between severed stromal lamellae along the incision. In one cornea, ink particles were present at least 73% of the way to the internal (endothelial) end of the incision (Fig 6C).

Discussion

Our study of ex vivo human and rabbit eyes represents an effort to experimentally explore cataract wound stability in the first hours after surgery. The differences from normal

living human eyes, which possess a functional endothelial pump, might be significant, and future in vivo studies are warranted. In situ OCT shows that corneal incisions in both human and rabbit eyes do not result in a stable wound morphology immediately after they are created. In well-pressurized eyes, the wound margins of self-sealing clear corneal incisions were well apposed along the length of the incision, resulting in appropriate “self-sealing.” With all such incisions that were visualized, however, fluctuations in intraocular pressure within a physiologic range (<5 – 40 mmHg) designed to mimic those pressures measured in blinking animal eyes¹¹ and human eyes¹² after clear corneal cataract surgery,¹⁰ resulted in relative movement of the wound edges. Intraocular pressures as high as 50 mmHg did not result in wound separation or leakage, but reductions in intraocular pressure in the range of 5 to 10 mmHg resulted in gaping of the anterior and posterior incision edges visible with OCT. Initially, the posterior/peripheral leaflet separated from the anterior/central leaflet, creating a wedge-shaped opening in the internal aspect of the incision. In some globes with apparently well-constructed wounds without leakage when intraocular pressure was in the range of 10 to 50 mmHg, reduction of intraocular pressure to 5 mmHg or less produced separation of wound edges along the entire length of the incision. This full-thickness wound separation was associated with aqueous leakage from the wound, either spontaneously or with pressure applied to the adjacent corneal surface. The difference observed in dimensional stability between rabbit and human corneas agrees well with the known differences in corneal material properties between these two species.^{24,25}

With vertical incisions, the changes in wound morphology were opposite those seen with the self-sealing tunnel incisions. Low pressures resulted in well-apposed wound edges, whereas progressive elevation of intraocular pressure effected progressive separation of the edges of the incision, beginning at the anterior corneal surface. Although further studies are necessary, this finding supports the creation of a beveled clear corneal incision as opposed to a simpler straight vertical incision.

The light micrographs of clear corneal incisions show penetration of India ink into all of the corneal wounds, indicating that these incisions draw surface tear fluid into and along the incisions before any healing of the wound and closure of the surface epithelial defect can occur. This corresponds to the separation at Bowman’s layer and superficial stroma seen in all the human globes at low pressures. The technique we used, applying India ink onto the corneal surface, followed by washing the surface to remove free ink, and then placing the corneas in liquid fixative for 1 week, possibly washed away some India ink particles that might have entered the corneal incision. Thus, we believe the technique used, which detected ink particles in incisions for up to 73% of their length, likely tended to underestimate the degree to which surface fluid penetrates into the clear corneal sutureless incisions when intraocular pressure approaches 5 mmHg.

The intermittent gaping of the internal aspect of the self-sealing cataract incisions, observed with OCT when the intraocular pressure is transiently reduced, suggests a pos-

sible route by which organisms present on the ocular surface might gain access to the aqueous humor. The drawing of tear film into the wound as demonstrated with the India ink, followed by a transient gaping of the internal aspect of the incision, would allow bacteria to reach the aqueous without necessarily having a continuous gaping along the full-length of the cataract incision. Approximately one fifth of eyes experience drops in intraocular pressure to 5 mmHg or less after clear corneal cataract surgery.¹⁰ The gaping of the internal aspect of the incision, which consistently occurs when intraocular pressure drops to 5 mmHg or less, would result in aqueous contact with the exposed stroma, which microorganisms might have reached, as did the India ink particles in our experiments. This two-part mechanism would allow for inoculation of organisms into the aqueous without creating a full-thickness communication between anterior chamber and tear film, which would be recognized clinically as a wound leak.

Another possible mechanism for anterior chamber contamination in the early postoperative period would be a transient decline in intraocular pressure that might allow gaping of the corneal incision along its length. Obviously, intraocular pressures the day after cataract surgery might vary widely, most often attracting the surgeon's attention if the pressures are elevated, possibly related to retained viscoelastic material.²⁶ Although not often measured, intraocular pressure is often low in the first minutes to hours after phacoemulsification. Shingleton et al¹⁰ found that 23 of 112 eyes (21%) had intraocular pressures of 5 mmHg or less 30 minutes after clear corneal phacoemulsification, with a mean of 10.0 ± 4.3 mmHg. When examined after 24 hours, however, the intraocular pressures were higher in almost all eyes (mean, 16.9 ± 4.4 mmHg), and very few eyes continued to exhibit very low pressures. Similarly, Rhee et al²⁷ measured pressure immediately and 25 minutes after clear corneal sutureless cataract surgery and noted an average pressure decline of approximately 20 mmHg. Thus, whereas persistent clinically recognized hypotony is very uncommon after clear corneal phacoemulsification, transient hypotony in the first few hours after surgery is actually common. In addition, after eye rubbing or blinking, the intraocular pressure can spike and then transiently undershoot the baseline pressure.¹¹ Our imaging of incisions with OCT and India ink penetration suggest that some eyes might indeed have full-thickness gaping along the length of the clear corneal incision, with a large wedge-shaped opening in the posterior cornea, a small wedge-shaped opening involving Bowman's layer and anterior stroma, and an intervening very narrow separation of the wound. Thus, we believe the possibility does, indeed, exist for bacteria to traverse the corneal incisions in some eyes during this early postoperative period when intraocular pressures might be low, and the wound morphology is so labile. This postoperative entry of microorganisms into the eye would explain the development of staphylococcal endophthalmitis in an eye after clear corneal surgery despite an aqueous aspirate at the conclusion of surgery that was culture negative.²⁸ Similarly, it would explain how one eye with a bacterial organism cultured from the aqueous at the time of surgery²⁹ could develop

postoperative endophthalmitis caused by a different bacteria (Ta CN, personal communication, September 27, 2002).

If organisms in the precorneal tear film can gain access to the corneal stroma along the incision and the anterior chamber in the early postoperative period, this might have important implications in the prophylaxis against endophthalmitis. Specifically, the possibility of postsurgical inoculation creates a requirement for the maintenance of therapeutic levels of antibiotic in the tear film, the aqueous humor, or both, especially during the period of relative hypotony for the first minutes to hours after surgery. At present, there is no clear consensus regarding the optimal perioperative prophylaxis in cataract surgery.³⁰ One controversial mechanism, currently in use by some surgeons, is the intracameral injection of vancomycin at the end of surgery or in the infusion fluid during surgery. This approach would allow the killing of organisms that gain entry into the eye during surgery and after completion of surgery, but the relatively short half-life of vancomycin within the aqueous (less than 2 hours) indicates it might not be very effective against delayed inoculation through the corneal incision.³¹ Although some studies suggest that vancomycin prophylaxis is effective,³¹⁻³⁴ others argue that efficacy has not been demonstrated or that the drug might be toxic.³⁵⁻³⁸ If transiently low intraocular pressure does allow delayed inoculation of the anterior chamber from organisms on the ocular surface, the ideal prophylactic antibiotic would have a longer half-life within the anterior chamber than does vancomycin. Another option would be the frequent topical administration of antibiotic in the early postoperative period to maintain high, possibly suprathreshold, levels in the tear film. Such an approach could reduce the number of viable organisms on the ocular surface and adnexa that might gain access into the eye. Also, if surface tear fluid did gain access into the eye, this fluid would contain levels of antibiotic needed to sustain a bactericidal concentration within the aqueous humor. The traditional postoperative management of patching the eye at the end of cataract surgery, without instillation of topical medications for 24 hours, would seem relatively undesirable if the inoculation of organisms into the anterior chamber after completion of the procedure can be responsible for endophthalmitis after clear corneal sutureless incisions.

This study also provides further evidence for the applications of OCT in ophthalmic imaging.³⁹⁻⁴² The ability of OCT to noninvasively evaluate the cornea and other structures, both in vitro and in vivo, makes it an invaluable device for ophthalmologists.

References

1. Agapitos PJ. Cataract surgical techniques. *Curr Opin Ophthalmol* 1993;4:39-43.
2. Lyle WA, Jin GJ. Prospective evaluation of early visual and refractive effects with small clear corneal incision for cataract surgery. *J Cataract Refract Surg* 1996;22:1456-60.
3. Leaming DV. Practice styles and preferences of ASCRS members: 2000 survey. *J Cataract Refract Surg* 2001;27:948-55.
4. John ME, Noblitt R. Endophthalmitis. Scleral tunnel vs. clear corneal incision. In: Buzard KA, Friedlander MH, Febraro

- JL, eds. The Blue Line Incision and Refractive Phacoemulsification. Thorofare, NJ: Slack, Inc.; 2001:53–6.
5. Colleaux KM, Hamilton WK. Effect of prophylactic antibiotics and incision type on the incidence of endophthalmitis after cataract surgery. *Can J Ophthalmol* 2000;35:373–8.
 6. Nagaki Y, Hayasaka S, Kadoi C, et al. Bacterial endophthalmitis after small-incision cataract surgery: effect of incision placement and intraocular lens type. *J Cataract Refract Surg* 2003;29:20–6.
 7. Stonecipher KG, Parmley VC, Jensen H, Rowsey JJ. Infectious endophthalmitis following sutureless cataract surgery. *Arch Ophthalmol* 1991;109:1562–3.
 8. Lertsumitkul S, Myers PC, O'Rourke MT, Chandra J. Endophthalmitis in the western Sydney region: a case-control study. *Clin Exp Ophthalmol* 2001;29:400–5.
 9. Powe NR, Schein OD, Gieser SC, et al. Cataract Patient Outcome Research Team. Synthesis of the literature on visual acuity and complications following cataract extraction with intraocular lens implantation. *Arch Ophthalmol* 1994;112:239–52.
 10. Shingleton BJ, Wadhvani RA, O'Donoghue MW, et al. Evaluation of intraocular pressure in the immediate period after phacoemulsification. *J Cataract Refract Surg* 2001;27:524–7.
 11. Percicot CL, Schnell CR, Debon C, Hariton C. Continuous intraocular pressure measurement by telemetry in alpha-chymotrypsin-induced glaucoma model in the rabbit: effects of timolol, dorzolamide, and epinephrine. *J Pharmacol Toxicol Methods* 1996;36:223–8.
 12. Coleman DJ, Trokel S. Direct-recorded intraocular pressure variations in a human subject. *Arch Ophthalmol* 1969;82:637–40.
 13. Cosar CB, Cohen EJ, Rapuano CJ, Laibson PR. Clear corneal wound infection after phacoemulsification. *Arch Ophthalmol* 2001;119:1755–9.
 14. Kau HC, Tsai CC, Kao SC, et al. Corneal ulcer of the side port after phacoemulsification induced by *Acinetobacter baumannii*. *J Cataract Refract Surg* 2002;28:895–7.
 15. Chiang RK, Rapuano CJ. Recurrent methicillin-resistant *Staphylococcus aureus* wound ulcer after clear-cornea cataract surgery. *CLAO J* 2002;28:109–10.
 16. Rao SK, Madhavan HN, Sitalakshmi G, Padmanabhan P. *Nocardia asteroides* keratitis: report of seven patients and literature review. *Indian J Ophthalmol* 2000;48:217–21.
 17. Mendicute J, Orbegozo J, Ruiz M, et al. Keratomycosis after cataract surgery. *J Cataract Refract Surg* 2000;26:1660–6.
 18. Ramaswamy AA, Biswas J, Bhaskar V, et al. Postoperative *Mycobacterium chelonae* endophthalmitis after extracapsular cataract extraction and posterior chamber intraocular lens implantation. *Ophthalmology* 2000;107:1283–6.
 19. Maxwell DP Jr, Diamond JG, May DR. Surgical wound defects associated with endophthalmitis. *Ophthalmic Surg* 1994;25:157–61.
 20. Fujimoto JG, Brezinski ME, Tearney GJ, et al. Optical biopsy and imaging using optical coherence tomography. *Nat Med* 1995;1:970–2.
 21. Huang D, Swanson EA, Lin CP, et al. Optical coherence tomography. *Science* 1991;254:1178–81.
 22. Fercher AF. Optical coherence tomography. *J Biomed Opt* 1996;1:157–73.
 23. Ren H, Ding Z, Zhao Y, et al. Phase-resolved functional optical coherence tomography: simultaneous imaging of in situ tissue structure, blood flow velocity, standard deviation, birefringence, and Stokes vectors in human skin. *Opt Lett* 2002;27:1702–04.
 24. Jue B, Maurice DM. The mechanical properties of the rabbit and human cornea. *J Biomech* 1986;19:847–53.
 25. Hoeltzel DA, Altman P, Buzard K, Choe K. Strip extensometry for comparison of the mechanical response of bovine, rabbit, and human corneas. *J Biomech Eng* 1992;114:202–15.
 26. Arshinoff SA, Albani DA, Taylor-Laporte J. Intraocular pressure after bilateral cataract surgery using Healon, Healon5 and Healon GV. *J Cataract Refract Surg* 2002;28:617–25.
 27. Rhee DJ, Deramo VA, Connolly BP, Blecher MH. Intraocular pressure trends after supranormal pressurization to aid closure of sutureless cataract wounds. *J Cataract Refract Surg* 1999;25:546–9.
 28. Leong JK, Shah R, McCluskey PJ, et al. Bacterial contamination of the anterior chamber during phacoemulsification cataract surgery. *J Cataract Refract Surg* 2002;28:826–33.
 29. Ta CN, Egbert PR, Singh K, et al. Prospective randomized comparison of 3-day versus 1-hour preoperative ofloxacin prophylaxis for cataract surgery. *Ophthalmology* 2002;109:2036–40.
 30. Liesegang TJ. Perioperative antibiotic prophylaxis in cataract surgery. *Cornea* 1999;18:383–402.
 31. Mendivil Soto A, Mendivil MP. The effect of topical povidone-iodine, intraocular vancomycin, or both on aqueous humor cultures at the time of cataract surgery. *Am J Ophthalmol* 2001;131:293–300.
 32. Abu el-Asrar AM, Kadry AA, Shibl AM, et al. Antibiotics in the irrigating solutions reduce *Staphylococcus epidermidis* adherence to intraocular lenses. *Eye* 2000;14:225–30.
 33. Beigi B, Westlake W, Chang B, et al. The effect of intracameral, per-operative antibiotics on microbial contamination of anterior chamber aspirates during phacoemulsification. *Eye* 1998;12(Pt 3a):390–4.
 34. Gills JP. Antibiotics in irrigating solutions [letter]. *J Cataract Refract Surg* 1987;13:344.
 35. Gordon YJ. Vancomycin prophylaxis and emerging resistance: are ophthalmologists the villains? The heroes? *Am J Ophthalmol* 2001;131:371–6.
 36. Feys J, Salvanet-Bouccara A, Emond JP, Dublanchet A. Vancomycin prophylaxis and intraocular contamination during cataract surgery. *J Cataract Refract Surg* 1997;23:894–7.
 37. Townsend-Pico WA, Meyers SM, Langston RH, Costin JA. Coagulase-negative *Staphylococcus* endophthalmitis after cataract surgery with intraocular vancomycin. *Am J Ophthalmol* 1996;121:318–9.
 38. Axer-Siegel R, Stiebel-Kalish H, Rosenblatt I, et al. Cystoid macular edema after cataract surgery with intraocular vancomycin. *Ophthalmology* 1999;106:1660–4.
 39. Neubauer AS, Priglinger SG, Thiel MJ, et al. Sterile structural imaging of donor cornea by optical coherence tomography. *Cornea* 2002;21:490–4.
 40. Hirano K, Ito Y, Suzuki T, et al. Optical coherence tomography for the noninvasive evaluation of the cornea. *Cornea* 2001;20:281–9.
 41. Hoerauf H, Wirbelauer C, Scholz C, et al. Slit-lamp-adapted optical coherence tomography of the anterior segment. *Graefes Arch Clin Exp Ophthalmol* 2000;238:8–18.
 42. Izatt JA, Hee MR, Swanson EA, et al. Micrometer-scale resolution imaging of the anterior eye in vivo with optical coherence tomography. *Arch Ophthalmol* 1994;112:1584–9.