

UCLA

UCLA Previously Published Works

Title

Intravascular Ultrasound Imaging in Human Peripheral and Coronary Arteries in Vivo :
ADVANCES IN IMAGING TECHNIQUES FOR DIAGNOSIS OF CARDIOVASCULAR DISEASES

Permalink

<https://escholarship.org/uc/item/61v375kw>

Journal

Circulation Journal, 56(6)

ISSN

1346-9843

Authors

MORIUCHI, MSAHITO

SAITO, SATOSHI

HONYE, JUNKO

et al.

Publication Date

1992

DOI

10.1253/jcj.56.578

Copyright Information

This work is made available under the terms of a Creative Commons Attribution License, available at <https://creativecommons.org/licenses/by/4.0/>

Peer reviewed

Intravascular Ultrasound Imaging in Human Peripheral and Coronary Arteries in Vivo

MSAHITO MORIUCHI, M.D., SATOSHI SAITO, M.D., JUNKO HONYE, M.D.
YASUO TAMURA, M.D., KAZUHIRA HIBIYA, M.D., RIKA MORIUCHI, M.D.
TOMOHIKO KAMATA, M.D., MASAZUMI TSUJI, M.D., TSUNEO MIZUMURA, M.D.
DON MAHON, M.D.*, JOHN A. MALLERY, M.D.*
AND JONATHAN M. TOBIS, M.D.*

To determine the feasibility of intravascular ultrasound imaging in vivo, a miniaturized high frequency transducer catheter was introduced into human peripheral (n=10) and coronary (n=4) arteries. Cross-sectional ultrasound images were obtained from iliofemoral arteries in 10 patients using a 20 MHz transducer catheter (1.2 mm in diameter) and from coronary arteries in 4 patients using a 30 MHz transducer catheter 5 French size (Fr) following successful coronary angioplasty. Ultrasound images obtained from peripheral arteries showed a three-layered appearance (echo-reflective intima, echo-lucent media and echo-reflective adventitia) in the normal arteries. In diseased arteries, the location, amount and extent of atheromatous plaque were clearly documented. The arterial diameters measured by ultrasound closely correlated with the measurements by angiography ($r=0.91$) in the peripheral arteries. Coronary angiograms obtained following balloon angioplasty revealed smooth edges at the dilatation sites without significant narrowing in all patients. However, a significant amount of residual atheromatous plaque was clearly observed on the ultrasound images at the previously dilated sites. Coronary dissection, which was identified as an echo-lucent area behind the plaque, was noted in 2 patients. Ultrasound images also revealed the presence of calcium in the plaque which was unrecognized on the angiograms in 3 patients. In addition, direct measurement of the lumen cross-sectional area was possible on the ultrasound images.

These results indicate that (1) the clinical use of intravascular ultrasound imaging catheters is feasible in human peripheral and coronary arteries in vivo, (2) both quantitative and qualitative assessments of atheromatous plaque are possible, and (3) this device will be useful for determining the quantitative and morphologic changes following coronary angioplasty.

(*Jpn Circ J* 1992; **56**: 578–585)

INTRAVASCULAR ultrasound imaging is a new modality which provides visualization of the arterial lumen and wall structures

Key words:

Intravascular ultrasound
Atherosclerosis
Coronary angioplasty

in cross-section. In vitro studies have shown the accuracy and consistency of this method when compared with histology^{1–6} With technologic advances in catheter design, these devices are being used to study human peripheral and coronary arteries in vivo^{7–10} In this manuscript we would like to summa-

Second Department of Internal Medicine Nihon University School of Medicine, Tokyo and *Division of Cardiology University of California, Irvine

Mailing address: Masahito Moriuchi, M.D. Second Department of Internal Medicine Nihon University School of Medicine 30-1 Oyaguchi-Kami-cho, Itabashi-ku Tokyo 173, Japan

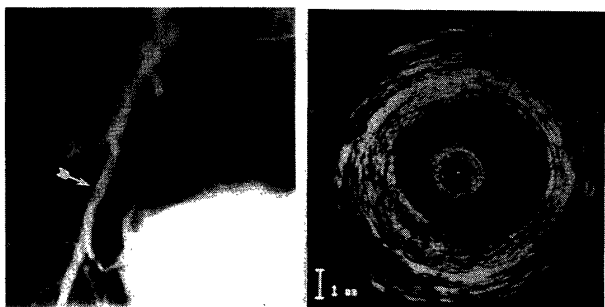


Fig. 1. An iliac artery angiogram and corresponding ultrasound image. There is no atherosclerotic narrowing on the angiogram; however, fibrous thickening of intima is demonstrated on the ultrasound image. Three-layered appearance of the arterial wall (echo-reflective intima, echo-lucent media and echo-reflective adventitia) is noted in the rest of the artery.

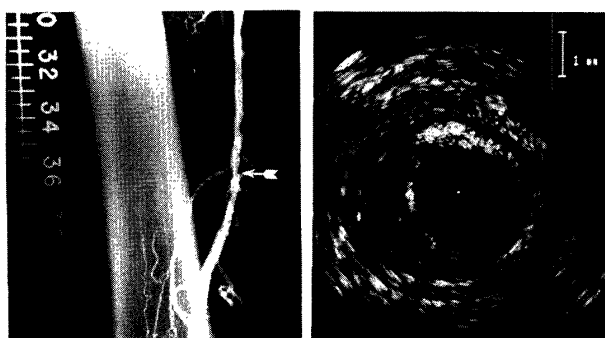


Fig. 2. A femoral artery angiogram following atherectomy and the corresponding ultrasound image. The location and thickness of the residual plaque is clearly visualized on the ultrasound image.

alize our peripheral and preliminary coronary artery studies in vivo.

METHODS

(1) Intravascular ultrasound imaging catheter

Two different models of intravascular ultrasound imaging catheter were used. A flexible intravascular ultrasound catheter (Intertherapy Inc. Costa Mesa, CA) was used in the peripheral artery study which was conducted at the University of California, Irvine. This catheter consists of a 20 MHz transducer subassembly and a 1.6 mm plastic introducing sheath. The transducer assembly is 1.2 mm in diameter and is connected to a motor-driven unit. The catheter is driven at 1800 rpm and real-time images are obtained at 30 frames per second. In the coronary

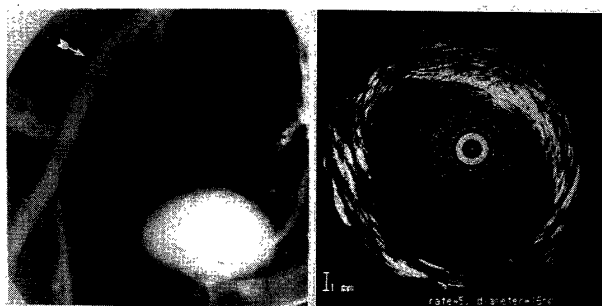


Fig. 3. An angiogram from a large iliac artery and corresponding ultrasound image. Although the shape of the artery is irregular on the ultrasound image, there is no evidence of intimal thickening. Angiography also demonstrated a normal iliac artery. This phenomenon is thought to be due to inadequate alignment of the catheter. When the artery is too large, it is often difficult to position the catheter parallel to the long axis of the artery and distortion of the image occurs.

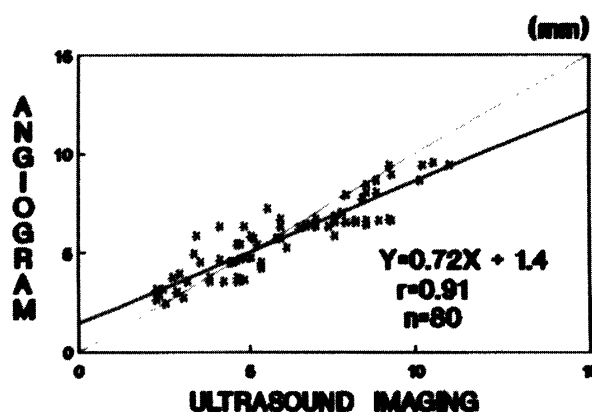


Fig. 4. Relation between ultrasound images and angiography in measuring the diameter of iliofemoral arteries. There was a good correlation ($r=0.91$) between measurements made by the two methods.

artery study which was performed at Nihon University, Tokyo, a commercially available 5 Fr. ultrasound catheter (Cardiovascular Imaging System), containing a 30 MHz fixed crystal and mirror which was rotated mechanically at 1800 rpm was used. The catheter is advanced by a monorail system using a 0.014 guidewire.

(2) Procedures

A: Peripheral artery imaging

Ten patients were studied after obtaining informed consent approved by the Human Subjects Review Committee. Intravascular

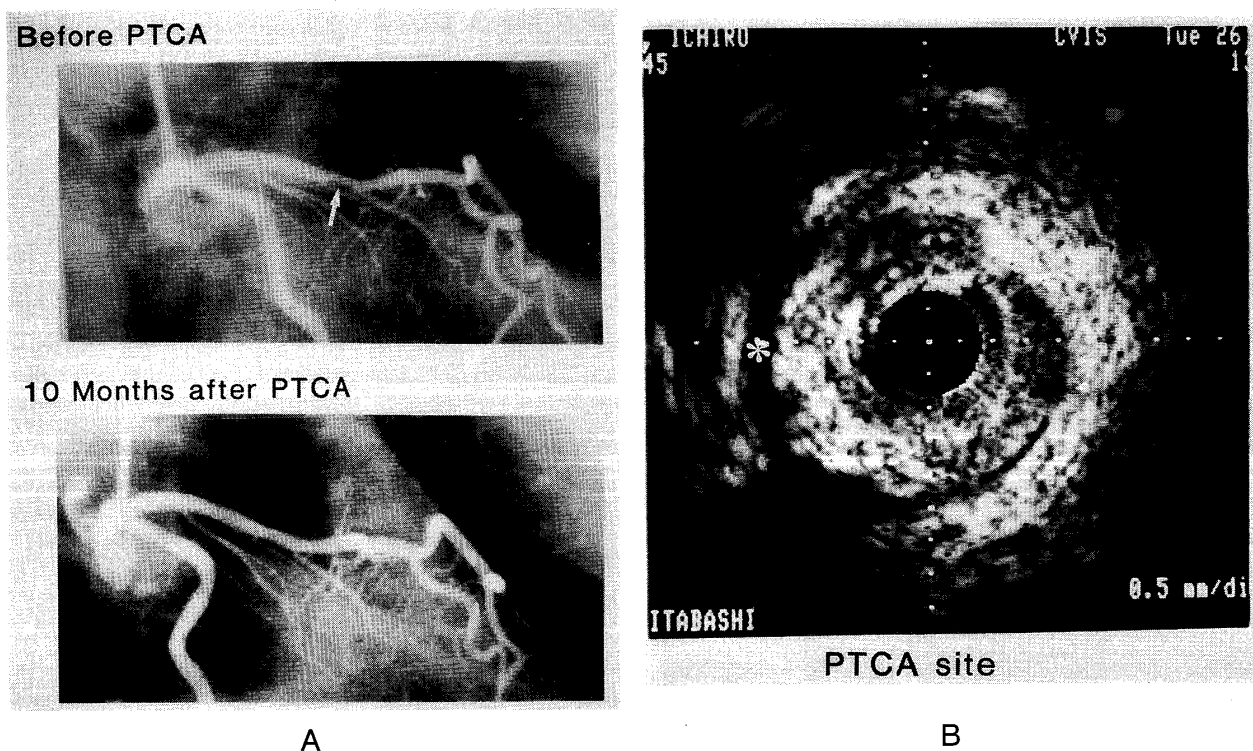


Fig.5. A: Left coronary angiograms in right anterior oblique projection before and after coronary angioplasty. A 77% stenosis was noted at the proximal portion of the left anterior descending coronary artery before coronary angioplasty (upper panel, arrow). Following coronary angioplasty, the stenosis was reduced to 22% and was still patent 10 months later (lower panel).
 B: An intracoronary ultrasound image obtained from the left anterior descending coronary artery following coronary angioplasty. There is a large amount of residual atheromatous plaque at the previously dilated site. An echo-lucent plane suggesting a dissection is noted behind the plaque from 4 to 12 o'clock (asterisk).

ultrasound imaging of the iliac and femoral arteries was performed at the time of cardiac catheterization or during peripheral angioplasty.

The ultrasound catheter was introduced retrograde into the iliac artery or antegrade into the femoral artery. Cross-sectional ultrasound images were obtained along the length of the artery and stored onto the computer disk. Then angiography was performed and the arterial diameters were measured at the site where the ultrasound images were obtained.

B: Coronary artery imaging

Four patients gave written, informed consent. Following successful coronary balloon angioplasty, the guiding catheter was replaced with a 9 Fr. guiding catheter to accommodate the ultrasound device. The previously dilated section of the artery was recrossed with a 0.014 guidewire. Over

the guidewire, the ultrasound catheter was advanced into the coronary artery and positioned at the previously dilated site. Cross-sectional ultrasound images were obtained and stored onto the computer disk. The measurements obtained by the ultrasound catheter were compared to those from angiography.

RESULTS

(1) Peripheral artery imaging

High resolution real-time ultrasound images were obtained in all 10 patients without any complication. Fig.1 shows an ultrasound images obtained from an iliac artery and the corresponding angiogram. There is no evidence of atherosclerosis on the angiogram; however, a thickened intima is seen at the lower-left portion on the ultrasound image. A bright halo reflection is

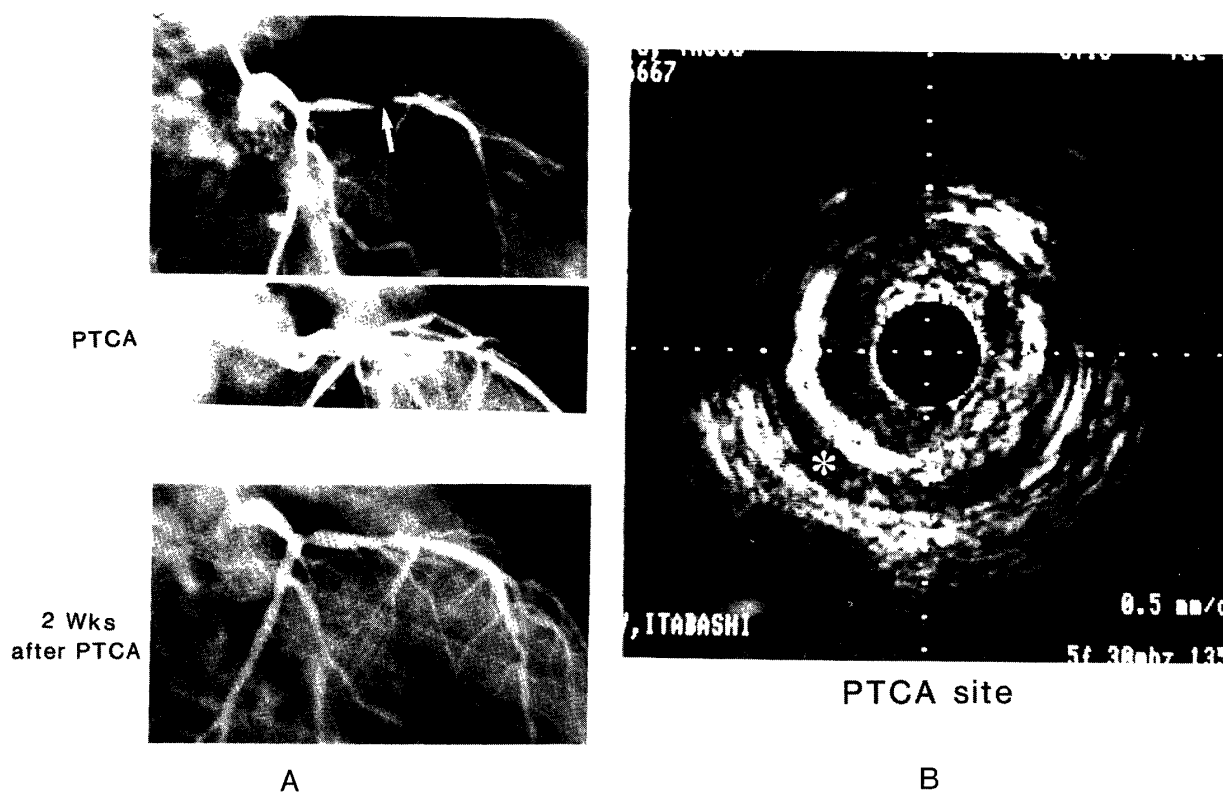


Fig. 6. A: Left coronary angiograms in right anterior projection of a patient with acute myocardial infarction. There was a 95% stenosis at the proximal portion of the left anterior descending coronary artery on the initial angiogram (upper panel, arrow) which was successfully dilated by balloon angioplasty (middle panel). Angiogram obtained 2 weeks later also demonstrated a patent lumen with no evidence of dissection (lower panel).
 B: An intracoronary ultrasound image from the left anterior descending coronary artery 2 weeks after emergency angioplasty. The lumen is adequately opened; however, there is a dissection plane behind the plaque from 2 to 12 o'clock (asterisk). Circular fibrocalcific plaque is only evident on the ultrasound image.

noted around the central black area of the transducer. This finding is consistent with our in vitro studies which demonstrated that the ultrasound image of an artery is mildly attenuated with the presence of blood!¹¹ Fig. 2 illustrates an ultrasound image obtained from a femoral artery following a successful atherectomy. The angiogram showed only a 20% residual stenosis at the site of atherectomy. On the ultrasound image, however, there was residual atheroma on the top of the image and the edge of the atheroma was sharp. This finding is consistent with an in vitro study which showed a similar pattern of an "atherectomy bite" following atherectomy.⁴ An ultrasound images obtained from a larger iliac artery is shown in Fig. 3. Although the angiogram demonstrated no apparent lesion, the shape of the

artery was non-circular. Close inspection of the images in real-time revealed that there was no evidence of intimal thickening in all portion of this artery. This phenomenon is thought to be related to inadequate axial alignment of the catheter. There was a good correlation between the angiograms and ultrasound images in measuring the diameter of the artery ($Y=0.72X+1.4$, $r=0.91$, Fig. 4).

(2) Coronary artery imaging

Coronary artery imaging was also performed without any complication in all four patients. Representative cases are briefly described below.

Patient 1: A 65 y/o male patients was admitted to our hospital because of severe anterior chest pain. Coronary angiography

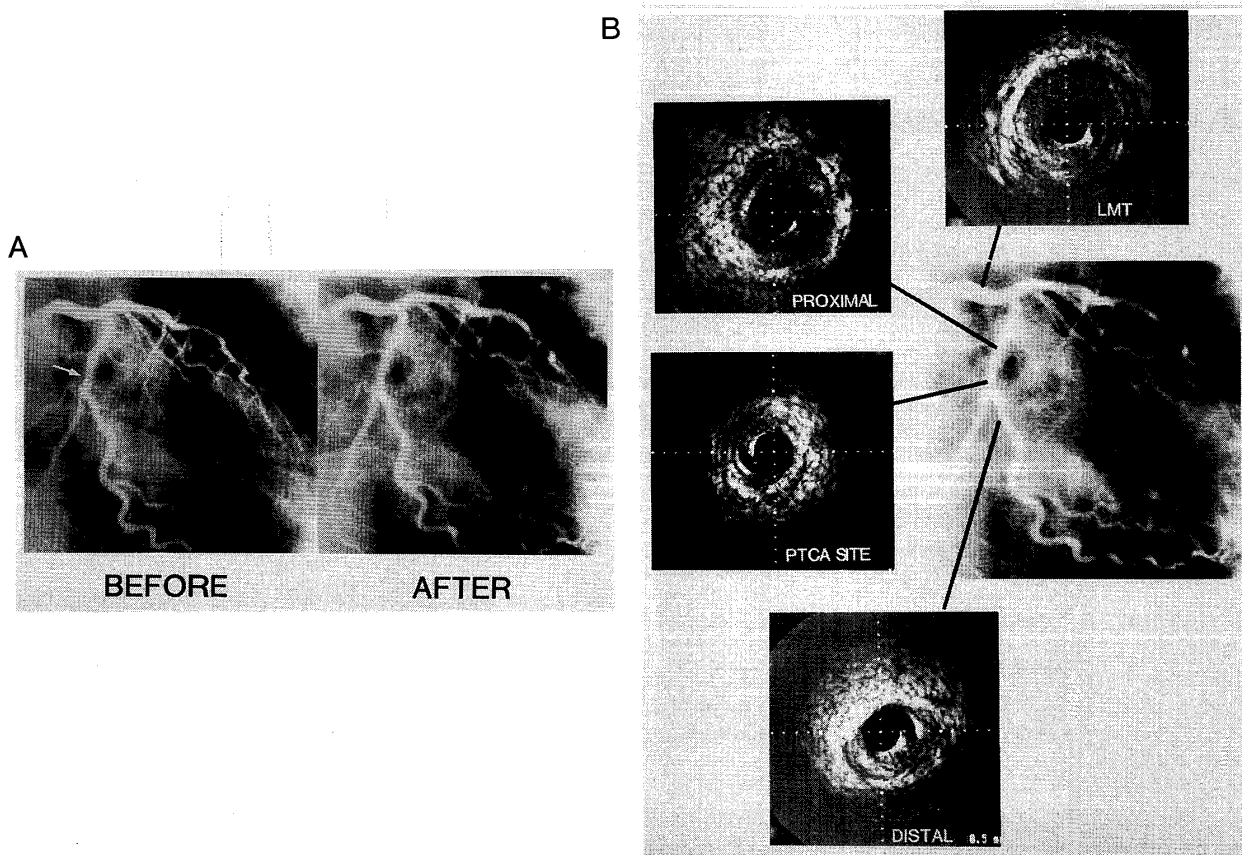


Fig. 7. A: Left coronary angiograms in right anterior projection before and after coronary angioplasty. There was a 75% stenosis at the middle portion of the left circumflex coronary artery (left panel) which was dilated by balloon angioplasty with a smooth residual appearance (right panel).
 B: Intracoronary ultrasound images obtained from left main trunk and left circumflex coronary and corresponding angiogram following coronary angioplasty. At the site of dilation, the lumen is adequately opened but residual eccentric plaque is still documented. In this artery, there is no evidence of plaque fracture or dissection. Ultrasound images also revealed fibrous thickening even at the angiographically normal portions (left maintrunk, proximal and distal to original stenosis).

revealed a 77% stenosis at the midportion of the left anterior descending coronary artery (LAD) (Fig. 5A, upper panel). Coronary angioplasty was performed in a standard manner and the stenosis was reduced to 22% following successful dilation. Ten months later he underwent repeat cardiac catheterization which showed no evidence of restenosis. The lumen was persistently patent and the arterial wall was smooth on the angiogram (Fig. 5A, lower panel). Ultrasound imaging of this artery, however, demonstrated a significant circumferential atherosclerotic lesion which contained hard calcified plaque. In addition, a dissection plane was identified as an echo-lucent band behind the thickened intima (Fig. 5B). The

lumen cross-sectional area determined by ultrasound was 3.6 mm^2 . This represented 20% of the available area bounded by the media.

Patient 2: A 55 y/o male was admitted to our hospital because of acute anterior myocardial infarction. Emergency coronary angiography revealed a 95% stenosis at the mid-portion of the LAD associated with reduced flow of contrast (TIMI grade 2) (Fig. 6A, upper panel). Because of the persistency of the chest pain, coronary angioplasty was performed with a 2.5 mm balloon. After balloon dilatation, the residual coronary stenosis was 50% and there was no evidence of dissection (Fig. 6A, middle panel). Repeat coronary angiography performed 2

weeks later demonstrated a patent lumen with no evidence of restenosis, and coronary stenosis was measured at 34% (Fig. 6A, lower panel). On the ultrasound image obtained at the level of the previous balloon dilatation, the cross-sectional lumen area was 6.3 mm² which represented a 30% lumen stenosis. An echolucent area consistent with a dissection plane was noted behind the fibrocalcific plaque (Fig. 6B).

Patient 3: A 58 y/o male patient with acute inferior infarction was transferred to our hospital after receiving 2400 × 10⁴ units of tissue plasminogen activator. Emergency coronary angiography performed on the next day revealed successful reperfusion but there was a 95% residual stenosis in the mid-portion of the left circumflex coronary artery (LCX) (Fig. 7A, left panel). Coronary angioplasty was performed and there was no apparent residual stenosis on the angiogram (Fig. 7A, right panel). The ultrasound catheter was then advanced into the left coronary artery and images were obtained along the length of the LCX artery. At the site of dilatation, there was an eccentric stenosis from 3 to 9 o'clock. This represented a 45% cross-sectional area stenosis. However, there was no evidence of an intimal tear or dissection (Fig. 7B). Although the left main trunk, and proximal and distal sites to the original stenosis were judged to be normal on the angiogram, the ultrasound images clearly demonstrated the presence of eccentric fibrous plaques.

DISCUSSION

Angiography has been the gold standard for assessing lesion severity for many years.¹² However, there are several limitations to projection imaging techniques such as angiography. Visual interpretation of angiograms is known to have substantial intra- and interobserver variability, and postmortem measurements do not correlate well with angiographic findings.¹³⁻¹⁶ Intravascular ultrasound imaging may be more accurate for determining stenosis severity because it provides cross-sectional images of the vessel which provides the opportunity to directly measure the lumen cross-sectional area. Several in vitro studies have demonstrated excellent correlations between ultrasound

images and histologic sections!¹⁻⁶ Hodgson et al reported a good correlation between ultrasound and histology in measuring vessel cross-sectional area! Mallery et al compared the wall thickness of the artery measured by ultrasound to the measurement by histology and obtained a good correlation between the two methods.⁶ Moreover, cross-sectional areas of artificial stenoses in a plastic tube model were more accurately measured by ultrasound imaging than by roentgenography!⁷

In the peripheral artery study, ultrasound images were obtained from angiographically normal iliofemoral arteries. Our results clearly demonstrate that high resolution real-time ultrasound imaging can be obtained from humans in vivo. The three-layered appearance of the artery (intima, media and adventitia) was visualized in the normal arteries, and the extent and location of the atheromatous plaque was precisely detected. The fact that atheromatous plaque was depicted even at angiographically normal segments, indicates that intravascular ultrasound is more sensitive than angiography for detecting early atherosclerotic changes? Quantitative and qualitative analysis by ultrasound may be useful for evaluating progression or regression of atherosclerosis.

Precise assessment of the atherosclerotic lesion is also important for patients treated with atherectomy. Theoretically, atherectomy removes only atheromatous plaque protruding into the lumen!⁴ However, initial clinical trials demonstrate that not only atheromatous plaque but also muscular media or adventitia is occasionally removed as well!¹⁸ Adequate visualization of atheromatous plaque by intravascular ultrasound imaging may aid in directing the atherectomy device to the target site. The good correlation found between the angiographic and ultrasound measurements of arterial diameter indicate the accuracy of ultrasound. This is probably because we selected patients who had normal arteries on angiography. Poorer correlation may be obtained if significantly atherosclerotic arteries are used. However, in this case, ultrasound may be more accurate in determining the severity of the stenosis because ultrasound directly measures the artery cross-sectional area.

Since its introduction in 1977, coronary

angioplasty has gained wide acceptance as a non-surgical form of therapy for coronary artery disease. However, the mechanism of angioplasty is still unclear. Morphologic and histologic changes have been reported from human autopsy studies by several investigators^{19,20} However, these results only represent a small subset of patients who undergo coronary angioplasty. Thus the mechanism of dilatation observed in patients with clinically successful angioplasty has not been elucidated.

Ultrasound images obtained from coronary arteries clearly demonstrate that there is a large amount of residual atherosclerotic disease following successful coronary angioplasty even though there is only mild residual narrowing on angiography. Calcification was also evident on the ultrasound images only in 3 patients. Moreover, dissection planes which were unrecognized on the angiogram were noted behind the atheromatous plaque in 2 patients. In addition to the qualitative analysis, it was possible to directly quantitate lumen cross-sectional area and atheroma area on the ultrasound images. Tobis et al recently classified ultrasound images following coronary angioplasty into 6 categories according to the morphologic patterns depending on the presence of plaque fracture or dissection and suggested that the primary mechanism of dilatation was fracture of the plaque in most cases¹⁰ Our experience is limited and our conclusions from this present study must be tentative. However, it is clear from these combined studies that intravascular ultrasound is more sensitive than angiography in determining the arterial wall changes following coronary angioplasty. It is anticipated in the near future that accumulation of more data will provide clues to understand the mechanism of successful coronary angioplasty.

There is some image degradation when images are obtained in vivo compared to in vitro. To obtain a good image, it is important to align the catheter parallel to the long axis of the artery, otherwise the distorted image may lead to misinterpretation. This phenomenon is more likely to occur in a large artery as shown in Fig. 3 or a tortuous artery segment. We also previously reported that there is an attenuation of image intensity when blood or contrast material is used as the

fluid medium instead of saline solution.¹¹ Moreover, if there is a hard calcified plaque, measurement of atheroma area or visualization of a dissection plane may be impossible. It is also difficult to differentiate a thrombus from soft fibrous plaque. Thus it is important to consider the influence of these factors in order to precisely interpret ultrasound images obtained in vivo.

In summary, our results demonstrate that (1) intravascular ultrasound imaging is feasible in human peripheral and coronary arteries in vivo, that (2) high quality real-time images are obtainable and both qualitative and quantitative analysis of atheromatous plaque are possible and that (3) quantitative and morphologic changes following coronary angioplasty could be assessed more precisely by ultrasound than angiography. Further clinical trials will be needed to define the role and significance of this new imaging technology.

REFERENCES

1. HODGSON J, EBERLE MJ, SAVAKUS AD.: Validation of a real time percutaneous intravascular ultrasound imaging catheter. *Circulation* 1988; **78**: II-21
2. MALLERY JA, TOBIS JM, GESSERT J, GRIFFITH J, BESSEN M, MCLEAY L, HENRY WL.: Identification of tissue components in human atheroma by an intravascular ultrasound imaging catheter. *Circulation* 1988; **78**: II-22
3. BATRORELLI AL, PLOTKIN BN, ALMAGOR Y, GESSERT JC, ROBERTS WC, LEON MB.: Intravascular ultrasound imaging of atherosclerotic coronary arteries: an in vitro validation study. *J Am Coll Cardiol* 1989; **13**: 4A
4. TOBIS JM, MALLERY JA, MAHON D, GRIFFITH J, GESSERT J, BESSEN M, HENRY WL.: Intravascular ultrasound visualization of atheroma plaque removal by atherectomy. *J Am Coll Cardiol* 1989; **13**: 222A
5. TOBIS JM, MALLERY JA, GESSERT J, GRIFFITH J, MAHON D, BESSEN M, MCLEAY L, MORIUCHI M, MCRAE M, HENRY WL.: Intravascular ultrasound cross-sectional arterial imaging before and after balloon angioplasty in vitro. *Circulation* 1989; **80**: 873-882
6. MALLERY JA, TOBIS JM, GRIFFITH J, GESSERT J, MCRAE M, MOUSSABECK O, BESSEN M, MORIUCHI M, HENRY WL.: Assessment of normal and atherosclerotic arterial wall thickness with an intravascular ultrasound imaging catheter. *Am Heart J* 1990; **119**: 1392-1400
7. YOCK PG, JOHNSON EL, LINKER DT.: Intravascular ultrasound: Development and clinical potential. *Am J Cardiac Imaging* 1988; **2**: 185-193
8. TOBIS JM, MALLERY JA, LEHMANN K,

- ZALESKY P, GRIFFITH J, GESSERT J, MORIUCHI M, MCRAE M, BESSEN M, DWYER M-L, GREEP N, HENRY WL.: Intravascular ultrasound imaging of human coronary arteries in vivo: analysis of tissue characterizations with comparison to in vitro histologic specimens. *Circulation* 19991; **83**: 913-926
9. EHRlich S, HONYE J, MAHON D, BERNSTEIN R, TOBIS JM.: Unrecognized stenosis by angiography documented by intravascular ultrasound imaging. *Cathet Cardiovasc Diagn* 1991; **23**: 198-201
 10. TOBIS JM, MAHON D, HONYE J, GESSERT J, DWYER M-L, GRIFFITH J, HENRY WL.: Cross sectional morphology of balloon dilatation in vivo by intravascular ultrasound. *J Am Coll Cardiol* 1991; **17**: II-157A
 11. MORIUCHI M, TOBIS JM, MAHON D, GESSERT J, GRIFFITH J, MACRAE M, MOUSABECK O, HENRY WL.: The reproducibility of intravascular ultrasound imaging in vitro. *J Am Soc Echo* 1990; **3**: 444-450
 12. GOULD KL, KELLY KO, BOLSON EL.: Experimental validation of quantitative coronary arteriography for determining pressure-flow characteristics of coronary stenosis. *Circulation* 1982; **66**: 930-938
 13. DETRE KM, WRIGHT E, MURPHY ML, TAKAO T.: Observer agreement in evaluation coronary angiograms. *Circulation* 1975; **52**: 979-986
 14. ZIR LM, MILLER SW, DINSMORE RE, GILBERT JP, HAWTHORNE JW.: Interobserver variability in coronary angiography. *Circulation* 1976; **53**: 627-632
 15. DEROUEN TA, MURRAY JA, OWEN W.: Validity in the analysis of coronary angiograms. *Circulation* 1977; **55**: 324-328
 16. GRONDIN CM, DYRDA I, POSTERNAC A, CAMPEAU L, BOURASSA MG, LESPERANCE J.: Discrepancies between cineangiographic and postmortem findings in patients with coronary artery disease and recent myocardial revascularization. *Circulation* 1974; **49**: 703-708
 17. MORIUCHI M, TOBIS JM, GORDON I, BERGMAN A, GRIFFITH J, HENRY WL.: Functional significance of arterial stenosis predicted by angiography and intravascular ultrasound imaging catheter. *J Am Coll Cardiol* 1990; **15**: 106A
 18. GARRAT KN, KAUFMAN UP, EDWARDS WD, VLIETSTRAN RE, HOLMES DR.: Safety of percutaneous coronary atherectomy with deep arterial resection. *Am J Cardiol* 1989; **64**: 538-540
 19. BLOCK PC, MYOLER PK, STERZER S, FAL-LON JT.: Morphology after transluminal angioplasty in human beings. *N Engl J Med* 1981; **305**: 382-385
 20. WALLER BF, GORFINKEL HJ, ROGERS FJ, KENT KM, ROBERTS WC.: Early and late morphologic changes in major epicardial coronary arteries after percutaneous transluminal coronary angioplasty. *Am J Cardiol* 1984; **53**: 42C-47C