UC Berkeley
UC Berkeley Previously Published Works

Title
Effect of chronic topical latanoprost on the sclera and lamina cribrosa of form-deprived myopic Guinea pigs.

Permalink
https://escholarship.org/uc/item/6228z2q9

Authors
El-Nimri, Nevin W
Yao, Melissa
Huerta, Andrea
et al.

Publication Date
2019-09-01

DOI
10.1016/j.exer.2019.107740

Peer reviewed

eScholarship.org Powered by the California Digital Library
University of California

Experimental Eye Research 186 (2019) 107740

Contents lists available at ScienceDirect

Experimental Eye Research

journal homepage: www.elsevier.com/locate/yexer

Effect of chronic topical latanoprost on the sclera and lamina cribrosa of form-deprived myopic Guinea pigs

Nevin W. El-Nimri*, Melissa Yao, Andrea Huerta, Michelle Hoang, Christine F. Wildsoet

School of Optometry and Vision Science, University of California Berkeley, Berkeley, CA, United States

ABSTRACT

The purpose of this study was to investigate the effects of latanoprost, an ocular hypotensive prostaglandin analog, on scleral collagen fibers and laminar pores in myopic guinea pigs. Young guinea pigs underwent monocular form deprivation (FD; white plastic diffusers) from 14-days of age for 10-weeks. After the first week, FD eyes also received daily topical A) latanoprost (Lat, 0.005%, n = 5) or B) artificial tears (AT; n = 5). At the end of the treatment period, animals were sacrificed, eyes enucleated and optic nerve heads (ONH) excised to include a 4 mm diameter ring of surrounding sclera for scanning electron microscopy (SEM), and an additional 6 mm ring of sclera surrounding the ONH was excised for transmission electron microscopy (TEM). For SEM, ONH samples were first immersed in 0.2M NaOH for 30 h to isolate the collagenous structures. All samples were stained with osmium tetroxide, dried through an ethanol series and finally subjected to critical point drying before imaging. Image J was used to analyze the dimensions of laminar pores (SEM images) and scleral collagen fibers (TEM images). As previously reported in a related study, latanoprost was effective in inhibiting myopia progression in FD eyes of the guinea pigs. The scleral fibers of FD myopic eyes treated with AT were smaller and more variable in cross-sectional areas compared to untreated (fellow) eyes (mean areas: 0.0059 ± 0.0013 vs. 0.0085 ± 0.002 μm^2; $p < 0.001$), consistent with scleral changes reported for human myopia. In contrast, the scleral fibers of the Lat-treated FD eyes were similar to those of fellow eyes (0.0083 ± 0.002 vs. 0.0078 ± 0.0014 μm^2). However, laminar pore size appeared unaffected by either the FD or drug treatments, with no significant difference found between FD eyes and their fellows, for either treatment group. That daily topical latanoprost appeared to protect against myopia-related changes in scleral collagen, rather than exaggerating them, as might be predicted from its known action on the uveoscleral extracellular matrix, lends further support its use for myopia control. In this guinea pig myopia model, the lamina cribrosa appeared unaffected.

1. Introduction

Myopia (near-sightedness) has become a significant public health concern, as its prevalence continues to increase in the United States (Vitale et al., 2009) and around the world, especially Asia (Pan et al., 2015). The sclera plays an important role as a determinant of eye size and thus in the development of myopia, which reflects excessive eye elongation. Comprising mainly of collagen type I, with fibroblasts functioning to produce and maintain the extracellular matrix, the sclera is known to undergo structural and biomechanical changes in myopic eyes. These changes are a byproduct of altered gene and protein expressions, including, but not limited to type 1 collagen, matrix metalloproteases (especially MMP2), tissue inhibitors of MMPs (TIMP), TGF beta, and integrins (Barathi and Beuerman, 2011; McBrien et al., 2006; McBrien and Gentle, 2003; Metlapally and Wildsoet, 2015; Rada et al., 1999). For example, expression of MMP2, an enzyme associated with collagen breakdown, was shown to be increased and expression of TIMP-1 to be decreased, in the myopic sclera of tree shrews (Guggenheim and McBrien, 1996; Siegwart and Norton, 2001). This increased remodelling of the scleral matrix leads to altered scleral microarchitecture, collagen fibers becoming reduced in size and more disorganized, and the sclera, thinner and weaker. In highly myopic eyes, the exaggerated and sustained biomechanical instability of the thinned sclera may lead to scleral creep (irreversible scleral stretching) and posterior staphyloma, in the event of mechanical scleral failure (Avetisov et al., 1983; Curtin, 1969; 1979).

The role in ocular growth (enlargement) of intraocular pressure (IOP), which exerts a stretching influence on the scleral wall of the eye, has been the subject of a number of investigations making use of experimental animal models (Nickla, 2013). During myopia development and progression, when scleral remodelling is upregulated, the sclera is predicted to be more susceptible to the stretching influences of IOP and thus eye enlargement to accelerate as a consequence (Cahane and Bartov, 1992). That the converse is also true, i.e., that ocular elongation can be slowed by decreasing IOP and so the tension experienced by the sclera, was tested in our recently published study using the topical ocular hypotensive drug, latanoprost, and the guinea pig form-deprivation myopia (FDM) model. We reported topical latanoprost to be effective in both lowering IOP and slowing myopia progression in young guinea pigs (El-nimri and Wildsoet, 2018).

The use of IOP lowering drugs for controlling myopia progression has another potential merit. Growing evidence from a number of

* Corresponding author. School of Optometry and Vision Science, 588 Minor Hall, University of California Berkeley, Berkeley, CA, 94720, United States.
E-mail address: nnimri@berkeley.edu (N.W. El-Nimri).

https://doi.org/10.1016/j.exer.2019.107740
Received 2 April 2019; Received in revised form 11 July 2019; Accepted 18 July 2019
Available online 19 July 2019
0014-4835/ © 2019 Elsevier Ltd. All rights reserved.

studies links myopia with an increased risk of primary open angle glaucoma (POAG), a leading cause of irreversible blindness (Flitcroft, 2012). Eyes with POAG typically exhibit high intraocular pressure (IOP) and altered diurnal IOP rhythms, as well as thinning of the neuroretinal rim and excavation of the optic nerve head (ONH). The latter ONH changes reflect the loss of retinal ganglion cell (RGC) axons as they pass through the lamina cribrosa (LC) (Flammer et al., 2002), a sieve-like structure bridging the scleral canal through which the axons pass to form the optic nerve, and which is also reported to be altered in glaucomatous eyes (Yang et al., 2007).

The mechanism(s) underlying the increased susceptibility of myopes to glaucoma is not well understood. Of possible contributing factors is the failure of the LC to adequately support the RGC axons as they exit the eye. As the sclera becomes progressively thinner and mechanically weaker with myopia progression, one might expect similar changes in the LC since it is continuous, at least posteriorly, with the adjacent sclera (Cahane and Bartov, 1992). A thinner and weaker peripapillary sclera in myopia could also affect the biomechanical properties of the LC, potentially explaining, at least in part, the increased risk of glaucomatous damage in myopic patients (Jonas et al., 2011; Norman et al., 2011). In fact, it was found that the LC thickness is decreased in eyes with longer axial lengths and thinner posterior scleras (including the sclera adjacent to the optic disc border) in non-glaucomatous monkeys, a similar finding to that in humans (Jonas et al., 2016).

Latanoprost is one of a number of prostaglandin (PG) analogues, which are currently considered the first-line treatment for POAG, because they reliably reduce IOP, by approximately 30%, and offer 24-h control (Aptel et al., 2008). The IOP reduction achieved with topical PGs is associated with increased uveoscleral (UV) outflow, achieved through increases in the levels of matrix metalloproteinases (2 and 3), leading to remodelling of the extracellular matrix (ECM) within the UV pathway (Russo et al., 2009). The latter activity profile raises the obvious question of whether the sclera is similarly remodelled, despite latanoprost's demonstrated ability to slow myopia progression in the FDM guinea pig model. The study reported here involved an electron microscopy evaluation of the microarchitecture of scleral tissue harvested in the previous study. The lamina cribrosas from the same eyes were also collected for evaluation. These analyses suggest that daily topical latanoprost not only protects against excessive ocular elongation, but also normalizes the scleral microarchitecture. In addition, the LC microarchitecture was not adversely affected, by either the induction of myopia or topical latanoprost.

2. Methods

Animals & treatment: Pigmented guinea pigs were used in this study, with breeders obtained from the University of Auckland, New Zealand. Study animals were bred on-site and housed in a temperature-controlled room with a light/dark cycle of 12L/12D (on at 9.30 a.m., off at 9.30 p.m.). Pups were weaned at 5 days of age and housed as single-sex groups in 41 cm wide X 51 cm long transparent plastic wire-top cages, with free access to water and vitamin C-supplemented food, with additional fresh fruit and vegetables given five times a week as diet enrichment. All animal care and treatments in this study conform to the ARVO Statement for the Use of Animals in Ophthalmic and Vision Research. Experimental protocols were approved by the Animal Care and Use Committee of the University of California, Berkeley.

A total of 20 animals were used in the initial study of myopia progression. For complete details, see (El-nimri and Wildsoet, 2018). That study comprised 2 groups of 10 animals, all of which underwent monocular form deprivation (FD), using detachable white plastic diffusers, starting at 14 days of age and continued for 10 weeks. The same eyes also received daily, one drop of either latanoprost (0.005% ophthalmic solution, Akorn, Lake Forest, IL) or artificial tears (AT), starting one week after the initiation of diffuser wear and continuing throughout the rest of the 10-week treatment period. Untreated contralateral eyes served as controls. Tissues from 5 animals of each of the two groups were collected for the current study, which involved both scanning and transmission electron microscopy imaging (SEM, TEM).

Electron microscopy: After the final *in vivo* measurements in the initial study, randomly selected animals were sacrificed, eyes enucleated and posterior eyecups isolated. Using disposable punches, ONHs were first excised to include a 4 mm ring of surrounding sclera for SEM, followed by a 6 mm ring of sclera surrounding the ONH sample for TEM.

ONH samples were first soaked in 0.2M NaOH for 30 h, to remove cellular components, leaving only collagenous component of the LC. The samples were then fixed in 4% glutaraldehyde in 0.1M sodium cacodylate, stained with osmium tetroxide, dried through an ethanol series, and finally subjected to critical point drying before imaging. LC samples were imaged using a Hitachi TM-1000 scanning electron microscope. Images were captured at 600× magnification.

Scleral samples were first fixed in 4% glutaraldehyde in 0.1M sodium cacodylate, stained with osmium tetroxide, dried through an acetone series, infiltrated with resin and finally embedded in molds. The resin blocks were first trimmed down by hand and then sectioned (70 nm thickness sections) using a diamond knife on a Reichert-Jung Ultracut E microtome. Sections were then placed on coated copper mesh grids, stained with uranyl acetate and lead citrate and finally imaged using an FEI Tecnai 12 transmission electron microscope. Images were captured from three different samples from each eye at a magnification of 6800×.

Statistical and image analysis: A custom image J program was used to measure scleral collagen fiber cross-sectional area and LC pore area from captured images after manually selecting the borders of each individual collagen fiber, as well as LC pore (Fig. 1). Graphical data

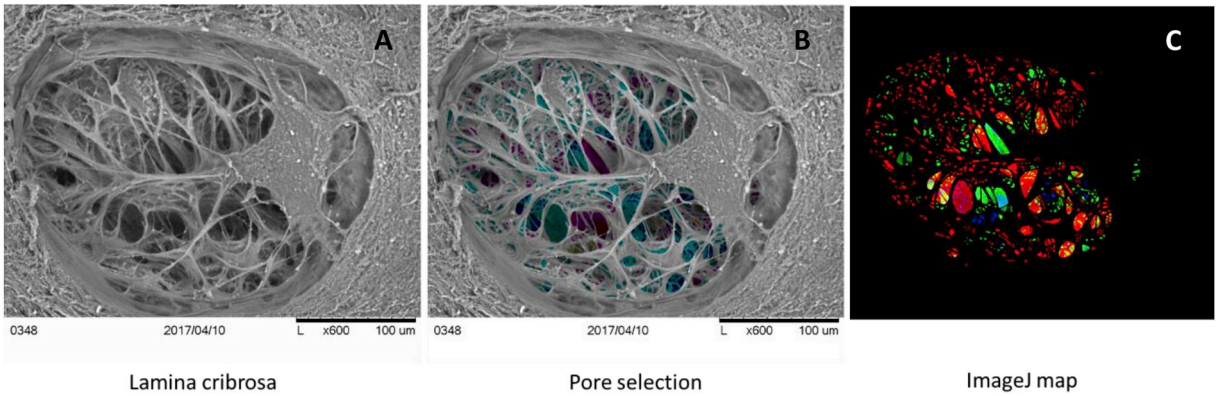

Fig. 1. Representative image of A) the lamina cribrosa, captured using scanning electron microscopy (SEM) and imaged at 600X, B) pore selection by custom image J program, C) pore map generated by image J.

Table 1
Summary of mean interocular differences in IOP, RE, and AL (± SEM) for monocularly form-deprived (FD) guinea pigs treated in their deprived eyes with either topical latanoprost or artificial tears (as a control treatment) for this study and our recently published study (data in brackets). Summary statistics indicate significance of change over the 10-week treatment period.

Parameter	Treatment Groups	Time of measurement		Statistics (p-value)
		Baseline	Week 10	
IOP (mmHg)	FD + Artificial tears	−0.44 ± 0.67 (−0.30 ± 0.51)	2.99 ± 0.81 (1.80 ± 1.16)	> 0.999 (0.525)
	FD + Latanoprost	0.06 ± 0.67 (0.07 ± 0.35)	−4.17 ± 1.28 (−5.17 ± 0.96)	0.01 (< 0.001)
Refractive Error (D)	FD + Artificial tears	+0.35 ± 0.70 (0.025 ± 0.36)	−8.3 ± 1.43 (−8.20 ± 0.71)	< 0.001 (< 0.001)
	FD + Latanoprost	0.00 ± 0.5 (−0.15 ± 0.35)	−0.85 ± 0.42 (−2.25 ± 0.54)	> 0.999 (0.03)
Optical AL(mm)	FD + Artificial tears	−0.02 ± 0.02 (0.00 ± 0.015)	0.1 ± 0.07 (0.29 ± 0.04)	< 0.0001 (< 0.001)
	FD + Latanoprost	−0.03 ± 0.03 (0.02 ± 0.02)	0.01 ± 0.03 (0.06 ± 0.02)	> 0.999 (0.202)

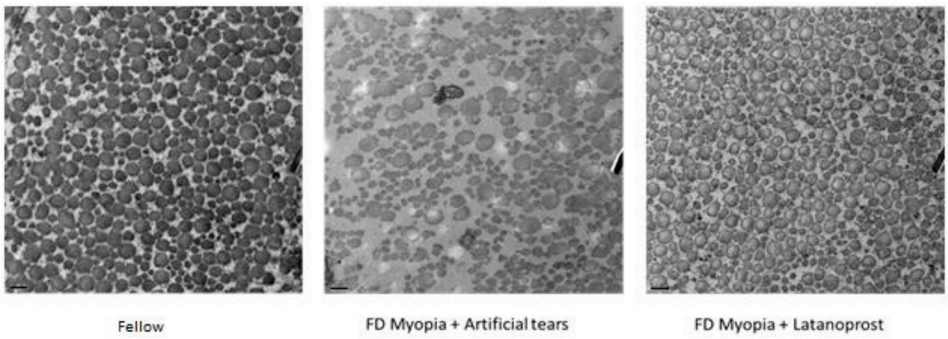

Fig. 2. Representative TEM images of scleras from A) fellow eyes of the latanoprost group, B) FD eyes treated with artificial tears (AT), and C) FD eyes treated with latanoprost at 6800X. Compared to the sclera of the fellow eye (left panel), which shows a predominance of medium to large collagen fibers, the sclera of the AT-treated myopic eye (middle panel) has a higher proportion of smaller collagen fibers, and is less compact, contrasting with the sclera of the latanoprost-treated eye (right panel), which closely resembles that of the normal fellow sclera.

Table 2
Scleral collagen fiber cross-sectional areas; mean (± SEM) and percentages of small (< 6000 nm^2), medium (6000–12,000 nm^2), and large (> 12,000 nm^2) fibers in form-deprived (FD)- and fellow eyes of artificial tears (AT)- and latanoprost (Lat)-treated groups. Statistics indicate significance of difference between numbers of small and large scleral fiber areas, expressed in percentage terms; differences between other groups not significant.

Eye	Scleral Collagen Fiber Area				
	Area (μm^2)	Small (%)	Medium (%)	Large (%)	P-value
FD-AT	0.0059 ± 0.0013	51.7 ± 9.1	28.8 ± 3.3	19.5 ± 6.5	0.02
Fellow-AT	0.0085 ± 0.002	39.6 ± 13.1	35.2 ± 0.6	25.2 ± 12.7	0.32
FD-Lat	0.0083 ± 0.002	37.6 ± 7.1	32.0 ± 1.7	30.4 ± 5.9	0.91
Fellow-Lat	0.0078 ± 0.0014	36.8 ± 8.4	36.4 ± 4.0	26.8 ± 8.4	0.62

analysis made use of Prism 6 (GraphPad Software, La Jolla, CA, USA). Data for treated and fellow eyes are reported as mean ± SEM. Two-tailed t-tests were applied to compare the average collagen fiber areas of treated and fellow eyes for both latanoprost and AT FDM groups (paired t-tests) as well as differences between the groups (unpaired t-tests). LC pore areas were similarly compared. Two-way ANOVAs were applied to compare the differences between multiple area categories (represented in percentages) of collagen fibers and LC pores. Two-way repeated measures ANOVAs, in combination with a Bonferroni post hoc test, were applied to compare the differences between latanoprost and AT groups in IOP, refractive error, optical axial length.

3. Results

Effects of latanoprost on intraocular pressure, refractive error, and axial length: As described in our previous paper, latanoprost (Lat) significantly reduced IOP and slowed myopia progression (El-nimri and Wildsoet, 2018). Mean interocular IOP differences (± SEM) recorded at baseline and week-10 for the subsets of 5 animals per group used in this EM study were −0.44 ± 0.67 and 2.99 ± 0.81 mmHg ($p > 0.999$) for the AT (control) group and 0.06 ± 0.67 and −4.17 ± 1.28 mmHg ($p = 0.01$) for the Lat group. Equivalent interocular differences for optical axial length at baseline and week-10 were −0.02 ± 0.02 and 0.31 ± 0.07 mm ($p < 0.0001$; AT), and −0.03 ± 0.03 and 0.01 ± 0.03 mm ($p > 0.999$; Lat), and for refractive error were +0.35 ± 0.70 and −8.3 ± 1.43 D ($p < 0.001$; AT), and 0.00 ± 0.5 and −0.85 ± 0.42 D ($p > 0.999$; Lat) (Table 1).

Effect of latanoprost on scleral collagen: Both the distribution of scleral collagen fibers and their cross-sectional area dimensions were qualitatively examined. In the normal guinea pig sclera, as represented by that of fellow eyes, scleral collagen fibers were evenly spaced (Fig. 2A). In contrast, the sclera from myopic FD eyes treated with AT (FD-AT eyes), was clearly altered, with increased spacing between the collagen fibers; there also appeared to be a higher proportion of smaller fibers (Fig. 2B). Interestingly, the FD eyes treated with Lat (FD-Lat eyes), were not only less myopic, but their scleras had more evenly spaced collagen fibers than those of the FD-AT eyes, more similar to those of the fellow eyes (Fig. 2C).

Collagen fiber cross-sectional area data for the treated and fellow eyes of both groups are summarized in Table 2 and shown graphically in Fig. 3 (top panel). That the scleras of FD-AT eyes had smaller fibers compared to those of their fellows was confirmed statistically (0.0059 ± 0.0013 μm^2, FD-AT vs. 0.0085 ± 0.002 μm^2, fellow ($p < 0.001$)), while the scleral fiber dimensions for FD-Lat eyes and their fellows were similar to each other (0.0083 ± 0.002 μm^2, FD-Lat vs. 0.0078 ± 0.0014 μm^2, fellow ($p = 0.057$). There was also a significant difference between the scleral fiber areas of FD-AT and FD-Lat eyes, being smaller on average in FD-AT eyes ($p < 0.001$).

To further compare the effects of the various treatment on scleral collagen fibers, cross-sectional area data were categorized into one of

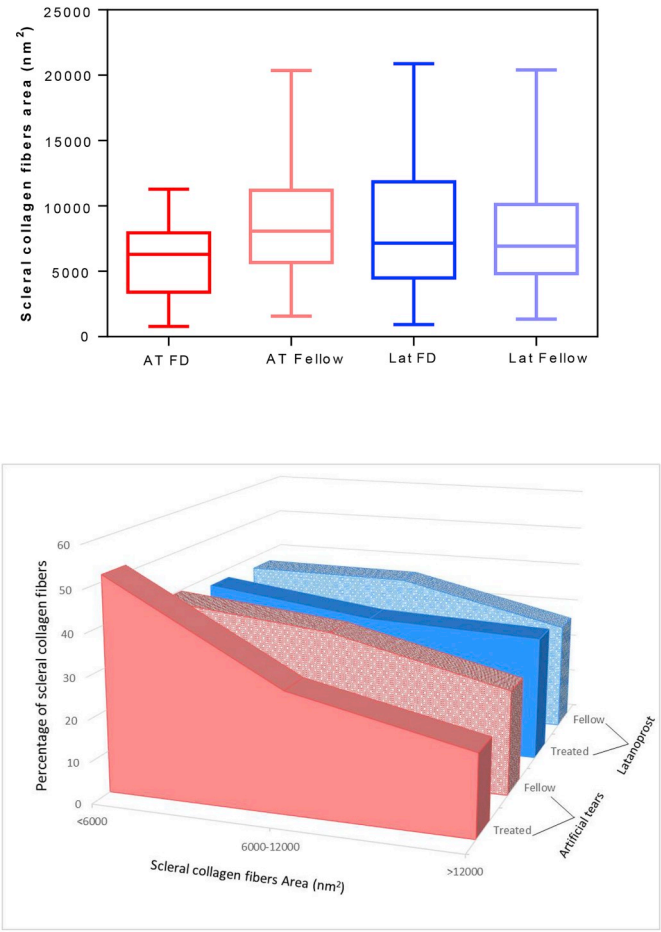

Fig. 3. Top: Mean scleral collagen fibers area (nm^2) for treated and fellow eyes of the artificial tear (AT) and latanoprost (Lat) groups, shown as box-plots. Bottom: Percentage of each of three categories of scleral collagen fibers, based on cross-sectional areas (small, < 6000 nm^2; medium, 6000–12,000 nm^2; large, > 12,000 nm^2), shown for the treated and fellow eyes of the AT and Lat groups.

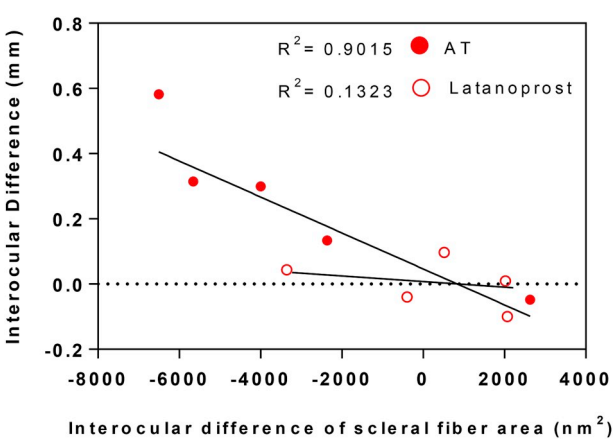

Fig. 4. Interocular differences in average scleral collagen fiber area (nm^2) for individual animals of artificial tear (AT) and latanoprost treated groups, plotted against interocular differences in axial length for the same animals.

three groups, small (< 6000 nm^2), medium (6000–12,000 nm^2), and large (> 12,000 nm^2). For both the AT and the Lat groups, the percentage of scleral collagen fibers in each category was calculated for both treated eyes and their fellows. Results of this analysis are shown in Fig. 3 (bottom panel) and summarized in Table 2. The FD-AT eyes had the highest percentage of the smallest fibers (51.7 ± 9.1%), and the lowest percentage of the largest fibers (19.5 ± 6.5%) ($p = 0.02$), compared to their fellows (39.6 ± 13.1%, small vs. 25.2 ± 12.7%, large; $p = 0.32$). On the other hand, the FD-Lat eyes and their fellows had similar percentages of small (37.6 ± 7.1%, FD-Lat; 36.8 ± 8.4%, fellow; $p > 0.999$), medium (32.0 ± 1.7%, FD-Lat; 36.4 ± 4.0%, fellow; $p > 0.999$), and large fibers (30.4 ± 5.9%, FD-Lat; 26.8 ± 8.4%, fellow; $p > 0.999$). The scleral collagen profiles of FD-Lat eyes and their fellows were also similar to and not significantly different from those of the fellow eyes of the FD-AT group.

How tightly related were the changes in scleral collagen fibers area to eye elongation? To address this question, the interocular difference of the average collagen fiber area was plotted against the interocular difference of the axial length for both AT and Lat groups. The AT group showed a negative linear correlation between axial length and collagen fiber area ($r^2 = 0.9$, $p = 0.014$), while there was no significant linear correlation between these parameters for the Lat group ($r^2 = 0.13$, $p = 0.55$) (Fig. 4).

Effect of latanoprost on lamina cribrosa: Representative images of the LCs of FD-Lat and FD-AT eyes and their fellows, captured by SEM, are shown in Fig. 5. The LCs of FD-AT eyes and their fellows were very similar in appearance and this is reflected in their pore area profiles, which were not significantly different (21.69 ± 8.88 vs. 22.21 ± 8.71 μm^2; $p > 0.999$). Likewise, there was no difference between the LC pore area profiles of FD-Lat eyes and their fellows (18.30 ± 9.15 vs. 18.87 ± 9.33 μm^2; $p > 0.999$). Nonetheless, it is noteworthy that FD-Lat eyes and their fellows tended to have slightly smaller laminar pores areas, on average, than the FD-AT eyes and their fellows (Table 3).

The laminar pores data were further analyzed after categorization based on size, into one of three groups, small (< 15 μm^2), medium (15–30 μm^2), and large (> 30 μm^2). The percentage of lamina cribrosa pores in each category was calculated for the treated and fellow eyes of both AT and Lat groups. This analysis further confirmed the lack of any significant difference between the LCs of treated eyes and their fellows. For all eyes, the smallest laminar pores accounted for the highest percentage of pores, while there were approximately equal numbers of medium and large pores, expressed in percentage terms (Table 3 and Fig. 6).

4. Discussion

In our previously published study (El-nimri and Wildsoet, 2018), we examined the efficacy of topical latanoprost, as a representative prostaglandin analog, for controlling myopia progression in a form-deprived guinea pig model of myopia. We found that topically applied latanoprost was effective in both lowering IOP and slowing myopia progression in this model. This paper describes an extension of that study, where we investigated the effect of latanoprost on the sclera and lamina cribrosa of guinea pigs under-going monocular form deprivation as a myopia-inducing treatment.

Key observations of the current study were altered scleral morphology for the myopic FD guinea pig eyes compared to that of untreated fellow (normal) eyes, and apparent normalization of scleral morphology in FD eyes treated with latanoprost. In the sclera of untreated (normal) eyes, collagen fibers were relatively evenly spaced; also, while the fibers ranged in size from quite small to quite large, medium-sized fibers dominated. In contrast, the scleras of the more myopic eyes, treated only with artificial tears, had both a higher proportion of smaller collagen fibers and overall, the fibers were more sparsely spaced. The latter picture fits well with other descriptions of myopic scleras. For example, in 1979, Curtin (Curtin et al., 1979), in examining human myopic eyes by electron microscopy, noted the following differences in myopic sclera: predominantly lamellar, reduction in fibril diameters (below 60–70 nm), greater dispersion for the range of fibril diameters, greater prevalence of extremely small diameter fibrils,

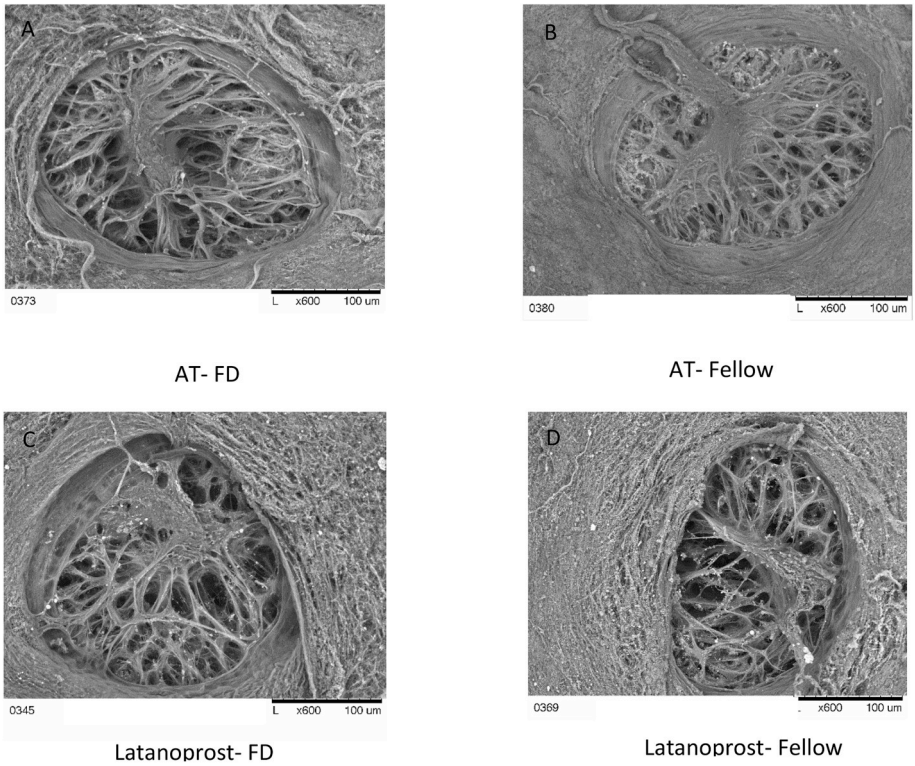

Fig. 5. Representative SEM images of the lamina cribrosas (600X) from FD and fellow eyes from artificial tear (AT) group (top panel), and FD and fellow eyes from latanoprost group (bottom panel).

Table 3
Laminar pore area (mean ± SEM), and percentages of small (< 15 μm^2), medium (15–30 μm^2), and large (> 30 μm^2) pores, in form-deprived (FD)- and fellow eyes of artificial tears (AT)- and latanoprost (Lat)-treated groups. Statistics indicate significance of difference between numbers of small and large LC pores, expressed in percentage terms; differences between numbers of small and medium LC pores, are all significant.

Eye	Lamina Cribrosa Pore Area				
	Area (μm^2)	Small (%)	Medium (%)	Large (%)	P-value
FD-AT	21.69 ± 8.88	65.3 ± 15.4	16.5 ± 5.2	18.2 ± 10.9	0.07
Fellow-AT	22.21 ± 8.71	63.9 ± 13.5	16.6 ± 3.2	19.5 ± 11.5	0.09
FD-Lat	18.30 ± 9.15	71.3 ± 16.7	10.7 ± 5.7	18.0 ± 11.0	0.03
Fellow-Lat	18.87 ± 9.33	68.9 ± 16.7	13.3 ± 6.1	17.7 ± 10.8	0.04

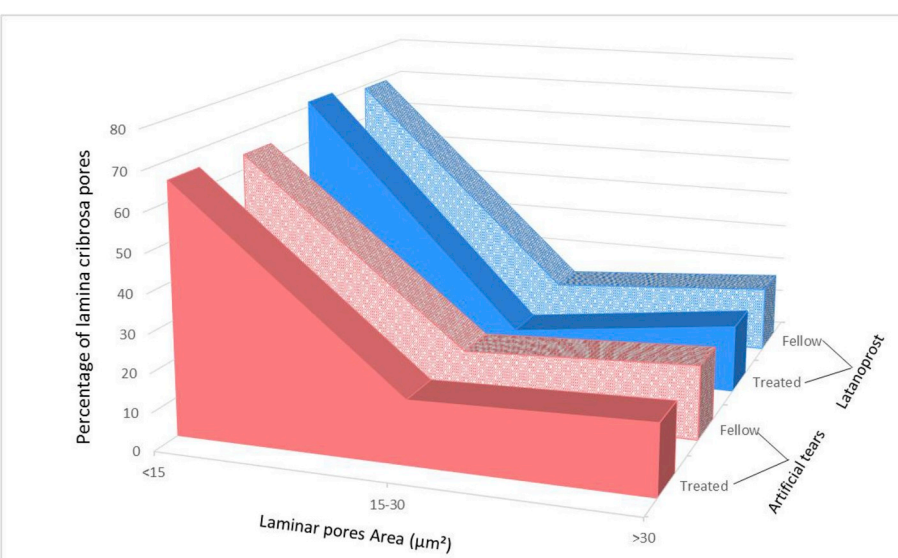

Fig. 6. Graph showing percentage of laminar pores in each of three size categories (small, < 15 μm^2; medium, 15–30 μm^2; large (> 30 μm^2). for the treated and fellow eyes of artificial tear (AT) and latanoprost groups. For all eyes, the smallest laminar pores accounted for the highest percentage, while there was approximately equal numbers of medium and large pores.

and unusual star-shaped fibrils on cross-section. With the exception of the last observation, this description also captures the changes in the scleras of our myopic guinea pigs.

Similar to human myopic scleral changes, myopia development and progression in tree shrews and mice have also been linked to changes in scleral collagen fiber spacing and diameter, as viewed by TEM. For example, in one study involving long-term (≥3 months) form deprivation in tree shrews, the resulting myopia was linked to an increase in the proportion of small diameter scleral collagen fibrils (McBrien et al., 2001). Similar scleral changes were also observed in a transgenic mouse model, which exhibits high myopia (Song et al., 2016). These findings are consistent with our own observation of a higher proportion of the smaller collagen fibers in the scleras of the form deprived myopic eyes of guinea pigs treated only with artificial tears. Furthermore, the scleral changes in these same animals were closely related to the induced changes in eye length, with the average size of collagen fibers decreasing with increased elongation (Fig. 4).

Interestingly, in our study, latanoprost not only inhibited myopia progression but also appeared to normalize the scleral collagen mosaic in these eyes. While it is not possible to establish a causal relationship between the latter finding and the slowed myopia progression observed, it was nonetheless, an unexpected result, given that latanoprost's ocular hypotensive action has been attributed to enhanced uveal extracellular matrix remodelling (Li et al., 2016; Oh et al., 2006; Ooi et al., 2009). Should similar protein expression changes, i.e. increases and decreases expressions of matrix metalloproteinase (MMPs) and tissue inhibitor of metalloproteinase (TIMPs) respectively, occur in the nearby sclera, one would expect the myopic changes to be exaggerated. Lending weight to the latter prediction are observations involving monkey and human sclera of increased MMP expression and increased permeability after exposure to topical prostaglandins *in vivo*, (Aihara et al., 2002; Kim et al., 2001; Weinreb, 2001).

That in the current study, the sclera from eyes treated with latanoprost had a similar appearance to the fellow eyes raises the possibility that the effect of lowering IOP outweighed any enhanced scleral remodelling effects of latanoprost. It is known that the scleral mechanical load is mainly derived from IOP-related strain and stress (Jia et al., 2016), and observed increases in MMP gene expression in a monkey experimental glaucoma model, has been attributed to elevated IOP (Agapova et al., 2003). While elevated IOP can be ruled out as an explanation for the altered scleral morphology in FD eyes treated with artificial tears (El-nimri and Wildsoet, 2018), both static and dynamic stress were shown to be important regulators of collagen synthesis in an *in vitro* study involving scleral explants (O'Brien, 2010). Thus it is plausible that the reduction in IOP achieved with latanoprost was responsible for the normalization of scleral morphology, although other sites of action and mechanisms cannot be ruled out. For example, *in vivo* SD-OCT imaging of latanoprost treated eyes revealed the posterior choroid of these eyes to be structurally altered (unpublished result El-Nimri et al., ARVO abstract 2018). Nonetheless the latter observation tends to rule out an alternative pharmacokinetic explanation for the apparent normalization of scleral morphology that the posterior sclera was less exposed to latanoprost than the anterior sclera, due to our use of topical drops.

To date, the effect of myopia on the architecture of the lamina cribrosa has not been investigated in any animal model, although a previous study by our group used scanning electron microscopy to image the lamina cribrosa of normal pigmented and albino guinea pigs (Ostrin and Wildsoet, 2016). The guinea pig was shown to have a well-organized, collagen-based lamina cribrosa, making it a promising model for investigating the relationship between myopia and glaucoma. Histomorphometric studies of human globes have found the lamina cribrosa to be thinner in highly myopic eyes when compared to eyes with normal axial length (Jonas et al., 2012, 2004), and in another study involving normal monkeys (no myopia or glaucoma), lamina cribrosa thickness was found to decrease and the posterior sclera to thin, with increasing axial length (Jonas et al., 2016). However, in the current study, no abnormalities in the lamina cribrosa architecture were identified in either of FD groups, including the one treated with latanoprost, which is itself reassuring from a therapeutic perspective.

Our interest in the lamina cribrosa architecture of the myopic guinea pigs stems from *in vivo* human studies suggesting that both high myopia and glaucoma significantly increase the risk of lamina cribrosa damage, and the further suggestion that lamina cribrosa changes in highly myopic eyes with no glaucoma may partially explain the increased risk of glaucoma in these eyes (Miki et al., 2015). Eyes with tilted discs, as commonly encountered in human myopia, appear more susceptible to focal temporal lamina cribrosa defects and associated glaucomatous visual field defects, (Sawada et al., 2017). Interestingly, none of the myopic guinea pigs that were also imaged *in vivo* using SD-OCT showed tilted discs (unpublished data). It is plausible that this difference between the guinea pig and human eyes reflects differences in the anatomical location of the optic nerve insertion site, raising the further possibility that shearing forces on the lamina cribrosa may be less in the case of guinea pig lamina cribrosa, as reflected in our failure to detect any related structural abnormalities. Nonetheless, because the SEM technique used in this study only allows for characterization of the surface structure of the lamina cribrosa, we cannot rule out changes in the deeper layers. It is also possible that such changes as described in humans may slowly evolve over time, while our study was limited to a 10-week monitoring period.

Finally, this study is not without its limitations. In this study, we did not investigate the effect of topical latanoprost on the sclera of normal (non-myopic) eyes, its focus being on the ability of latanoprost to slow or prevent myopia progression. Nonetheless, examining its effect on the sclera of normal eyes is a logical extension of the current research, and critical to establishing whether latanoprost may be used prophylactically to prevent myopia.

5. Conclusions

In summary, our study suggests that daily topical latanoprost not only protects against excessive ocular elongation, as reported in our recently published paper (El-nimri and Wildsoet, 2018), but it also normalizes the scleral microstructure. Furthermore, topical latanoprost does not appear to have any adverse effects on the lamina cribrosa architecture, although that of untreated myopic eyes was also apparently normal. While there is still much more to learn about mechanisms underlying the myopia control effect of latanoprost, these results present a favorable picture for this off-label application.

Acknowledgements

This research was supported by NIH/NEI grants R01EY012392 and T32EY704337. Special thanks to Dr Benjamin Smith (Vision Science Program, UC Berkeley), for the image analysis program, to UC Berkeley undergraduate students, Anna Barcellos and Sami Sweidan, for help with TEM sample preparation and imaging, and data analysis respectively.

References

Agapova, O., Kaufman, P., Lucarelli, M., Gabelt, B., Hernandez, M., 2003. Differential expression of matrix metalloproteinases in monkey eyes with experimental glaucoma or optic nerve transection. Brain Res. 967 (1–2), 132–143.
Aihara, M., Lindsey, J.D., Weinreb, R.N., 2002. Reduction of intraocular pressure in mouse eyes treated with latanoprost. Investig. Ophthalmol. Vis. Sci. 43 (1), 146–150.
Aptel, F., Cucherat, M., Denis, P., 2008. Efficacy and tolerability of prostaglandin analogs. J. Glaucoma 17, 667–673.
Avetisov, E.S., Savitskaya, N.F., Vinetskaya, M.I., Iomdina, E.N., 1983. A study of biochemical and biomechanical qualities of normal and myopic eye sclera in humans of different age groups. Metab. Pediatr. Syst. Ophthalmol. 7, 183–188.
Barathi, V.A., Beuerman, R.W., 2011. Molecular mechanisms of muscarinic receptors in mouse scleral fibroblasts: prior to and after induction of experimental myopia with

atropine treatment. Mol. Vis. 17, 680–692.
Cahane, M., Bartov, E., 1992. Axial length and scleral thickness thickness effect on susceptibility to glaucomatous damage: a theoretical model implementing laplace's law. Ophthalmic Res. 24, 280–284.
Curtin, B., 1969. Physiopathologic aspects of scleral stress-strain. Trans. Am. Ophthalmol. Soc. 67, 417–461.
Curtin, B.J., Iwamoto, T., Renaldo, D.P., 1979. Normal and staphylomatous sclera of high myopia. An electron microscopic study. Arch. Ophthalmol. 97, 912–915 (Chicago, Ill. 1960).
El-nimri, N.W., Wildsoet, C.F., 2018. Effects of topical latanoprost on intraocular pressure and myopia progression in young Guinea pigs. Investig. Ophthalmol. Vis. Sci. 59, 2644–2651.
Flammer, J., Orgül, S., Costa, V.P., Orzalesi, N., Krieglstein, G.K., Serra, L.M., Renard, J.P., Stefánsson, E., 2002. The impact of ocular blood flow in glaucoma. Prog. Retin. Eye Res. 21, 359–393.
Flitcroft, D.I., 2012. The complex interactions of retinal, optical and environmental factors in myopia aetiology. Prog. Retin. Eye Res. 31, 622–660.
Guggenheim, J.A., McBrien, N.A., 1996. Form-deprivation myopia induces activation of scleral matrix metalloproteinase-2 in tree shrew. Investig. Ophthalmol. Vis. Sci. 37, 1380–1395.
Jia, X., Yu, J., Liao, S.-H., Duan, X.-C., 2016. Biomechanics of the sclera and effects on intraocular pressure. Int J Ophthalmol. 9 (12), 1824–1831.
Jonas, J.B., Berenshtein, E., Holbach, L., 2004. Lamina cribrosa thickness and spatial relationships between intraocular space and cerebrospinal fluid space in highly myopic eyes. Investig. Ophthalmol. Vis. Sci. 45 (8), 2660–2665.
Jonas, J.B., Jonas, S.B., Jonas, R.A., Holbach, L., Panda-Jonas, S., 2011. Histology of the parapapillary region in high myopia. Am. J. Ophthalmol. 152, 1021–1029.
Jonas, J.B., Jonas, R.A., Jonas, S.B., Panda-Jonas, S., 2012. Lamina cribrosa thickness correlated with peripapillary sclera thickness. Acta Ophthalmol. 90, e248–e250.
Jonas, J.B., Kutscher, J.N., Panda-Jonas, S., Hayreh, S.S., 2016. Lamina cribrosa thickness correlated with posterior scleral thickness and axial length in monkeys. Acta Ophthalmol. 94, e693–e696.
Kim, J.W., Lindsey, J.D., Wang, N., Weinreb, R.N., 2001. Increased human scleral permeability with prostaglandin exposure. Investig. Ophthalmol. Vis. Sci. 42, 1514–1521.
Li, X., He, F., Gabelt, B.T., Wang, Y., Cai, S., Cao, J., Fan, N., Kaufman, P.L., Liu, X., 2016. Effects of latanoprost and bimatoprost on the expression of molecules relevant to ocular inflow and outflow pathways. PLoS One 11 (3), e0151644.
McBrien, N.A., Gentle, A., 2003. Role of the sclera in the development and pathological complications of myopia. Prog. Retin. Eye Res. 22, 307–338.
McBrien, N.A., Cornell, L.M., Gentle, A., 2001. Structural and ultrastructural changes to the sclera in a mammalian model of high myopia. Investig. Ophthalmol. Vis. Sci. 42 (10), 2179–2187.
McBrien, N.A., Metlapally, R., Jobling, A.I., Gentle, A., 2006. Expression of collagen-binding integrin receptors in the mammalian sclera and their regulation during the development of myopia. Investig. Ophthalmol. Vis. Sci. 47, 4674–4682.
Metlapally, R., Wildsoet, C.F., 2015. Scleral mechanisms underlying ocular growth and myopia. In: Progress in Molecular Biology and Translational Science, pp. 241–248.
Miki, A., Ikuno, Y., Asai, T., Usui, S., Nishida, K., 2015. Defects of the lamina cribrosa in high myopia and glaucoma. PLoS One 10, e0137909.
Nickla, D.L., 2013. Ocular diurnal rhythms and eye growth regulation: where we are 50 years after lauber. Exp. Eye Res. 114, 25–34.
Norman, R.E., Flanagan, J.G., Sigal, I.A., Rausch, S.M.K., Tertinegg, I., Ethier, C.R., 2011. Finite element modeling of the human sclera: influence on optic nerve head biomechanics and connections with glaucoma. Exp. Eye Res. 93, 4–12.
Oh, D.-J., Martin, J.L., Williams, A.J., Russell, P., Birk, D.E., Rhee, D.J., 2006. Effect of latanoprost on the expression of matrix metalloproteinases and their tissue inhibitors in human trabecular meshwork cells. Investig. Ophthalmol. Vis. Sci. 47, 3887.
Ooi, Y.H., Oh, D.-J., Rhee, D.J., 2009. Effect of bimatoprost, latanoprost, and unoprostone on matrix metalloproteinases and their inhibitors in human ciliary body smooth muscle cells. Investig. Ophthalmol. Vis. Sci. 50, 5259.
Ostrin, L.A., Wildsoet, C.F., 2016. Optic nerve head and intraocular pressure in the Guinea pig eye. Exp. Eye Res. 146, 7–16.
O'Brien, Prema, 2010. Scleral Bioreactor: Design and Use for Evaluation of Myopia Therapiese. PhD Dissertation.
Pan, C.-W., Dirani, M., Cheng, C.-Y., Wong, T.-Y., Saw, S.-M., 2015. The age-specific prevalence of myopia in Asia: a meta-analysis. Optom. Vis. Sci. 92, 258–266.
Rada, J.A., Perry, C.A., Slover, M.L., Achen, V.R., 1999. Gelatinase A and TIMP-2 expression in the fibrous sclera of myopic and recovering chick eyes. Investig. Ophthalmol. Vis. Sci. 40 3091–9.
Russo, L., Peano, B., Trivedi, S., Cavalcanto, T., Olenchock, B., Caruso, J., Smolock, A., Vishnevsky, O., Gardner, R., 2009. Regulated expression of matrix metalloproteinases, inflammatory mediators, and endometrial matrix remodeling by 17beta-estradiol in the immature rat uterus. Reprod. Biol. Endocrinol. 7 (124).
Sawada, Y., Araie, M., Ishikawa, M., Yoshitomi, T., 2017. Multiple temporal lamina cribrosa defects in myopic eyes with glaucoma and their association with visual field defects. Ophthalmology 124, 1600–1611.
Siegwart, J.T., Norton, T.T., 2001. Steady state mRNA levels in tree shrew sclera with form-deprivation myopia and during recovery. Investig. Ophthalmol. Vis. Sci. 42, 1153–1159.
Song, Y., Zhang, F., Zhao, Y., Sun, M., Tao, J., Liang, Y., Ma, L., Yu, Y., Wang, J., Hao, J., 2016. Enlargement of the axial length and altered ultrastructural features of the sclera in a mutant lumican transgenic mouse model. PLoS One 11, e0163165.
Vitale, S., Sperduto, R.D., Ferris, F.L., 2009. Increased prevalence of myopia in the United States between 1971-1972 and 1999-2004. Arch. Ophthalmol. 127, 1632–1639.
Weinreb, R.N., 2001. Enhancement of scleral macromolecular permeability with prostaglandins. Trans. Am. Ophthalmol. Soc. 99, 319–343.
Yang, H., Downs, J.C., Girkin, C., Sakata, L., Bellezza, A., Thompson, H., Burgoyne, C.F., 2007. 3-D histomorphometry of the normal and early glaucomatous monkey optic nerve head: lamina cribrosa and peripapillary scleral position and thickness. Investig. Ophthalmol. Vis. Sci. 48, 4597.