

# UCLA

## UCLA Previously Published Works

### Title

Intraoperative Indocyanine Green Laser Angiography in Pediatric Autologous Ear Reconstruction

### Permalink

<https://escholarship.org/uc/item/62b3d630>

### Journal

Plastic & Reconstructive Surgery Global Open, 4(5)

### ISSN

2169-7574

### Authors

Martins, Deborah B  
Farias-Eisner, Gina  
Mandelbaum, Rachel S  
et al.

### Publication Date

2016-05-01

### DOI

10.1097/gox.0000000000000696

Peer reviewed



# Intraoperative Indocyanine Green Laser Angiography in Pediatric Autologous Ear Reconstruction

Deborah B. Martins, BS\*  
 Gina Farias-Eisner, MD\*  
 Rachel S. Mandelbaum,  
 BS\*  
 Han Hoang, MD\*  
 James P. Bradley, MD†  
 Justine C. Lee, MD, PhD\*

**Summary:** Skin flap vascularity is a critical determinant of aesthetic results in autologous ear reconstruction. In this study, we investigate the use of intraoperative laser-assisted indocyanine green angiography (ICGA) as an adjunctive measure of skin flap vascularity in pediatric autologous ear reconstruction. Twenty-one consecutive pediatric patients undergoing first-stage autologous total ear reconstruction were retrospectively evaluated. The first 10 patients were treated traditionally (non-ICGA), and the latter 11 patients were evaluated with ICGA intraoperatively after implantation of the cartilage construct and administration of suction. Relative and absolute perfusion units in the form of contour maps were generated. Statistical analyses were performed using independent sample Student *t* test. Statistically significant differences in exposure and infection were not found between the 2 groups. However, decreased numbers of surgical revisions were required in cases with ICGA versus without ICGA ( $P = 0.03$ ), suggesting that greater certainty in skin flap perfusion correlated with a reduction in revision surgeries. In cases of exposure, we found an average lowest absolute perfusion unit of 14.3, whereas cases without exposure had an average of 26.1 ( $P = 0.02$ ), thereby defining objective parameters for utilizing ICGA data in tailoring surgical decision making for this special population of patients. Defined quantitative parameters for utilizing ICGA in evaluating skin flap vascularity may be a useful adjunctive technique in pediatric autologous ear reconstruction. (*Plast Reconstr Surg Glob Open* 2016;4:e709; doi: 10.1097/GOX.0000000000000696; Published online 19 May 2016.)

**T**he challenge of autologous ear reconstruction is to balance sufficient skin flap perfusion with tight adaptation to the cartilage construct to

generate a defined, aesthetic result. Although skill in sculpture of the cartilage framework contributes to the aesthetic outcome of the reconstructed ear, a

From the \*Division of Plastic and Reconstructive Surgery, University of California Los Angeles David Geffen School of Medicine, Los Angeles, Calif.; and †Division of Plastic and Reconstructive Surgery, Temple University, Los Angeles, Calif.

Received for publication June 15, 2015; accepted March 2, 2016.

Copyright © 2016 The Authors. Published by Wolters Kluwer Health, Inc. on behalf of The American Society of Plastic Surgeons. All rights reserved. This is an open-access article distributed under the terms of the Creative Commons Attribution-Non Commercial-No Derivatives License 4.0 (CCBY-NC-ND), where it is permissible to download and share the work provided it is properly cited. The work cannot be changed in any way or used commercially.

DOI: 10.1097/GOX.0000000000000696

**Disclosure:** All authors have no financial interests including products, devices, or drugs associated with this manuscript. There are no commercial associations that might pose or create a conflict of interest with information presented in this submitted manuscript such as consultancies, stock ownership, or patent licensing arrangements. All sources of funds supporting the completion of this manuscript are under the auspices of the University of California Los Angeles. This work was supported by the Bernard G. Sarnat Endowment for Craniofacial Biology (JCL). JCL is also supported by IK2BX002442-01A2 from the US Department of Veterans Affairs. The authors have no financial interest to declare in relation to the content of this article. The Article Processing Charge was paid for by the authors

thick skin flap may efface the details of the cartilage construct. Conversely, a thin skin flap with insufficient vascularity may result in devastating results including exposure, infection, and loss of the cartilage construct. In both circumstances, a skin flap error causes undesirable results of the reconstructed ear and contributes to the frustration of surgeons with autologous ear reconstruction.

Intraoperative imaging techniques have been widely implemented in various reconstructive procedures. Specifically, laser-assisted indocyanine green angiography (ICGA) has demonstrated utility in evaluating skin flap perfusion in adults and has been suggested to improve postoperative outcomes although limitations, such as assessment of venous insufficiency, exist.<sup>1-4</sup> This technology has been sparingly used in pediatric patients or for ear reconstruction. In this study, we describe the use of laser-assisted ICGA in first-stage autologous ear reconstruction.

### METHODS

Twenty-one consecutive pediatric patients undergoing first-stage autologous total ear reconstruction between 2011 and 2015 performed by the senior surgeons (J.P.B. and J.C.L.) using a modified Firmin-Nagata technique were retrospectively evaluated. The first 10 patients were treated traditionally (non-ICGA) and the latter 11 patients were subjected to ICGA. Five milligrams of ICG was administered intravenously after implantation of the cartilage construct and administration of suction. Perfusion was evaluated using the SPY Elite system (Novadaq, Bonita Springs, Fla.). Areas that appeared to be underperfused would be clinically re-evaluated and excised, if necessary. Relative and absolute perfusion units (RPU and APU, respectively) contour maps were generated using the SPY-Q

software. Statistical analyses were performed using Microsoft Excel (Redmond, WA) with independent sample Student *t* tests.

### RESULTS

Twenty-one pediatric patients (mean age 8.3 years) received first-stage autologous rib cartilage ear reconstructions (Table 1). The average operative time was 4.0 hours, and mean follow-up time was 1.57 years. Age, sex, microtia grade, and operative time were not associated with exposure or other complications.

When comparing reconstructed ears with and without ICGA, operative time did not differ significantly between the groups. The ICGA cohort demonstrated slightly fewer cartilage exposures secondary to skin flap necrosis in comparison with the non-ICGA cohort. All exposures except 1 occurred at the distal aspect of the skin flap at the incision, 1 exposure occurred due to a fold in the skin between the helix and superior crus that was not recognized intraoperatively. All exposures were treated by returning to the operating room for either simple skin closure or closure with a small fascial flap and split-thickness skin graft. One infection occurred in the non-ICGA group and none in the ICGA group. Differences in exposures and infection rates did not reach statistical significance. Excluding the second-stage elevation of the reconstructed ear, there was a difference between the 2 groups in the number of revision surgeries. The non-ICGA group required an average of 2.1 revisions, whereas an average of 0.8 revisions were performed for the ICGA group ( $P=0.03$ ). No systemic complications occurred.

To determine methods of predicting exposure, we evaluated the lowest RPU and APU in reconstructions with and without exposure complications (Table 2 and Fig. 1). RPU was determined relative to the perfusion found on the native lobule of the

**Table 1. Demographics and Surgical Details**

	Overall	Non-ICGA	ICGA	<i>P</i>
Age, mean years (range)	8.3 (4.6–19.1)	7.7 (5.1–11.3)	8.8 (4.6–19.1)	0.22
Microtia grade, n (%)				
Grade II	8 (33.3%)	3 (30.0%)	4 (36.4%)	0.39
Grade III lobular type	14 (66.7%)	7 (70.0%)	7 (63.6%)	
Operative time, mean hours (range)	4.0 (1.9–6.2)	3.9 (3.2–5.8)	4.0 (1.9–6.2)	0.42
Inpatient time, mean days (range)	2.0 (1–3)	2.0 (1–3)	2 (2–2)	0.50
Exposures, n (%)	7 (33.3%)	4 (40%)	3 (27.3%)	0.28
Infections, n (%)	1 (5.2%)	1 (10.0%)	0 (0%)	0.17
Revisions (excluding elevation), average (range)	1.4 (0–6)	2.1 (0–6)	0.8 (0–2)	0.03
Types of revisions, n (% of revisions)				
Lobule rotation	10 (55.6%)	6	4	0.67
Deepening of helical root	4 (15.3%)	3	1	0.79
Tragal reconstruction (composite skin/cartilage graft)	1 (3.8%)	1	0	0.56
Conchal bowl deepening	1 (3.8%)	1	0	0.56
Debridement and closure	7 (26.7%)	4	3	0.42
Hardware removal	4 (15.4%)	2	2	0.37

reconstructed ear. Although RPU and APU both demonstrated lower values as expected in the ears with exposure versus those without exposure, only the differences in APU reached statistical significance. Specifically, the mean lowest APU was found to be 14.3 in ears with exposures versus 26.1 in those without exposures ( $P = 0.02$ ).

## DISCUSSION

The balance of blood supply to aesthetics is well known to be a precarious one in ear reconstruction. In this report, we demonstrate that laser-assisted intraoperative ICGA can be safely used in children undergoing autologous total ear reconstruction. Greater confidence in skin flap vascularity with ICGA use translated to decreased revision rates. Unlike reports in adults, a lower average APU was correlated with necrosis, thereby suggesting differences in the pediatric craniofacial population.

Exposures requiring reoperation did occur in the cohort of patients who had ICGA, partially due to the learning curve required in evaluating areas that definitively required excision. In all cases, the distal edges of the skin flap had delayed filling and venous congestion. In cases with exposure, the lowest APU was  $\leq 20$  (average = 14.3). This APU threshold is lower in

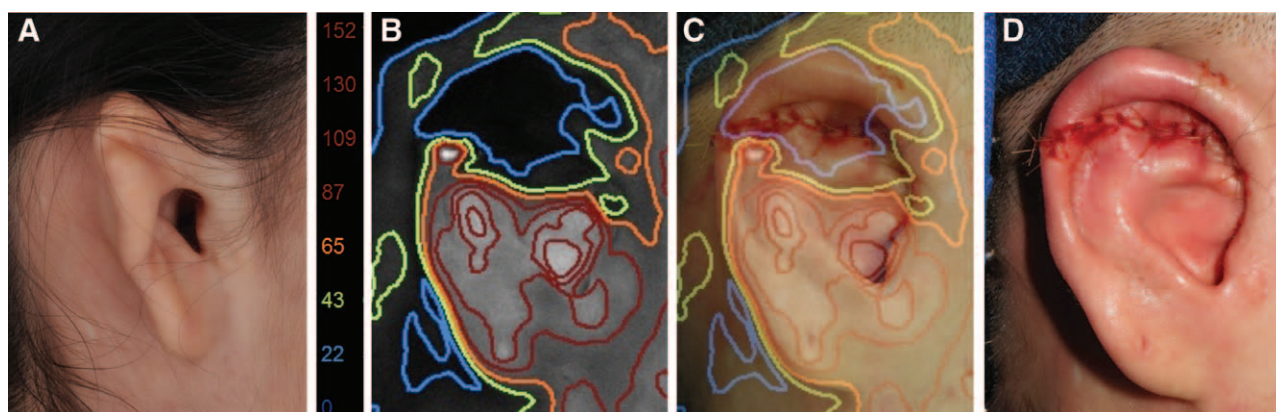
comparison with the reported APU of 23.8 or less in postmastectomy skin flap necrosis,<sup>5</sup> potentially highlighting differences in the recovery of vascularity in the respective anatomic sites and ages of the patient populations. Of note, in patients without exposures, the APU reached as low as 12. There are 2 reasons for this discrepancy. First, variabilities in contour found in ear reconstruction result in variabilities in fluorescence, highlighting a limitation in ICGA use. Thus, low values need to be carefully clinically correlated to ascertain that contour irregularities were not responsible for decreased fluorescence. Second, some areas with low values, which did not result in outright exposure, suffered from slow healing. Such areas were uniformly small and did not hinder a successful outcome.

Limitations exist when using ICGA in ear reconstruction. Similar to other reports, some ambiguity in perfusion estimation exists partially secondary to contour irregularities and venous insufficiency.<sup>4</sup> Although the angiography machine is readily available at our institution, each ICG kit costs at least \$500. However, this cost could potentially be offset by decreases in revision rates.

Intraoperative maneuvers to account for skin flap concerns frequently take place in ear reconstruction. The cartilage construct may be reduced in projection or size to accommodate the pediatric skin pocket. In cases without ICGA, greater uncertainty for ischemia resulted in significant modifications such as omitting the tragus and planning for a staged reconstruction of the tragus using a composite skin cartilage graft. In our series, such modification of the cartilage construct was performed at a lower rate in the ICGA group resulting in lower numbers of revision procedures.

**Table 2. Relative and Absolute Perfusion Units**

	Exposure	No Exposure	<i>P</i>
Relative perfusion units (mean %, range)	12.5% (12.5–12.5%)	20.3% (12.5–37.5%)	0.05
Absolute perfusion units (n, range)	14.3 (11–20)	26.1 (12–49)	0.02



**Fig. 1.** Determination of lowest absolute perfusion units in intraoperative laser-assisted indocyanine green angiography of pediatric reconstructed ears. Quantitative determination of APU were evaluated intraoperatively and clinically correlated. Panels show a preoperative photograph (A), APU contour map (B), APU map/photograph overlay (C), and an intraoperative photograph (D) of a reconstructed ear that did not suffer subsequent exposure. Numbers in color to the left of the APU map denote the APU corresponding to each colored area. Numbers in color to the left of the APU map denote the APU corresponding to each colored area.

**Justine C. Lee, MD, PhD**

Division of Plastic and Reconstructive Surgery  
 University of California Los Angeles  
 200 UCLA Medical Plaza, Suite 465  
 Los Angeles, CA 90095  
 E-mail: justine@ucla.edu

**REFERENCES**

1. Gurtner GC, Jones GE, Neligan PC, et al. Intraoperative laser angiography using the SPY system: review of the literature and recommendations for use. *Ann Surg Innov Res.* 2013;7:1.
2. Newman MI, Jack MC, Samson MC. SPY-Q analysis toolkit values potentially predict mastectomy flap necrosis. *Ann Plast Surg.* 2013;70:595–598.
3. Hinchcliff KM, Yao A, Taub PJ. Laser-assisted indocyanine green imaging to assess perfusion of scalp closure in an infant. *J Craniofac Surg.* 2013;24:2004–2006.
4. Wu C, Kim S, Halvorson EG. Laser-assisted indocyanine green angiography: a critical appraisal. *Ann Plast Surg.* 2013;70:613–619.
5. Phillips BT, Fourman MS, Rivara A, et al. Comparing quantitative values of two generations of laser-assisted indocyanine green dye angiography systems: can we predict necrosis? *Eplasty* 2014;14:e44.