

UC San Diego

UC San Diego Previously Published Works

Title

Continuous Transversus Abdominis Plane (TAP) Blocks for Postoperative Pain Control after Hernia Surgery: A Randomized, Triple-Masked, Placebo-Controlled Study

Permalink

<https://escholarship.org/uc/item/631796h4>

Journal

Pain Medicine, 15(11)

ISSN

1526-2375

Authors

Heil, Justin W
Nakanote, Ken A
Madison, Sarah J
et al.

Publication Date

2014-11-01

DOI

10.1111/pme.12530

Peer reviewed

ACUTE PAIN & PERIOPERATIVE PAIN SECTION

Original Research Article

Continuous Transversus Abdominis Plane (TAP) Blocks for Postoperative Pain Control after Hernia Surgery: A Randomized, Triple-Masked, Placebo-Controlled Study

Justin W. Heil, MD,* Ken A. Nakanote, BA,[†]
Sarah J. Madison, MD,* Vanessa J. Loland, MD,*
Edward R. Mariano, MD, MAS,*
NavParkash S. Sandhu, MD, MS,*
Michael L. Bishop, MD,* Rishi R. Agarwal, MD,*
James A. Proudfoot, MSc,[‡] Eliza J. Ferguson, BS,*
Anya C. Morgan, MA, CCRC,* and
Brian M. Ilfeld, MD, MS (Clinical Investigation)*

Departments of *Anesthesiology and [†]Biostatistics,
and [‡]School of Medicine, University of California San
Diego, San Diego, California, USA

Reprint requests to: Brian M. Ilfeld, MD, MS (Clinical
Investigation), Department of Anesthesiology, 200
West Arbor Drive, MC 8990, San Diego, CA 92130,
USA. Tel: (858) 657-7030; Fax: (858) 683-2003;
E-mail: bilfeld@ucsd.edu.

Disclosure: The contributions of Drs. Heil,¹ Loland,⁴
and Mariano⁵ occurred while working at the University
of California San Diego, San Diego, California. These
investigators subsequently moved to Naval Medical
Center San Diego (San Diego, California),¹ the
University of Washington (Seattle, Washington),³ and
Stanford University (Stanford, California),⁴ respectively.

I-Flow Corporation (Lake Forest, CA, USA) provided
funding for the current study. This company also
provided the portable infusion pumps used in this
investigation, and had no input into any aspect of
study conceptualization, design, and implementation;
data collection, analysis and interpretation; or
manuscript preparation. The contents of this article
are solely the responsibility of the authors and do not
necessarily represent the official views of the funding
entities.

Conflict of Interest: During the period of subject
enrollment, Drs. Ilfeld and Mariano taught workshops
on continuous peripheral nerve blocks, receiving
honoraria from I-Flow Corporation. Dr. Ilfeld had no
financial relationship with this company during data

analysis and manuscript preparation. Dr. Mariano
taught workshops during data analysis and
manuscript preparation.

Submitted, in part, as a scientific abstract for the
annual meeting of the American Society of
Anesthesiologists, New Orleans, Louisiana, October
11–15, 2014.

Abstract

Background. Single-injection transversus abdo-
minis plane (TAP) block provides postoperative
analgesia and decreases supplemental analgesic
requirements. However, there is currently no evi-
dence from randomized, controlled studies investi-
gating the possible benefits of continuous TAP
blocks. Therefore, the aim of this randomized,
triple-masked, placebo-controlled study was to
determine if benefits are afforded by adding a
multiple-day, ambulatory, continuous ropivacaine
TAP block to a single-injection block following
hernia surgery.

Methods. Preoperatively, subjects undergoing uni-
lateral inguinal (N = 19) or peri-umbilical (N = 1)
hernia surgery received unilateral or bilateral TAP
perineural catheter(s), respectively. All received a
ropivacaine 0.5% (20 mL) bolus via the catheter(s).
Subjects were randomized to either postoperative
perineural ropivacaine 0.2% or normal saline using
portable infusion pump(s). Subjects were dis-
charged home where the catheter(s) were removed
the evening of postoperative day (POD) 2. Subjects
were contacted on POD 0–3. The primary endpoint
was average pain with movement (scale: 0–10)
queried on POD 1.

Results. Twenty subjects of a target 30 were
enrolled due to the primary surgeon's unanticipated
departure from the institution. Average pain queried
on POD 1 for subjects receiving ropivacaine (N = 10)

Heil et al.

was a mean (standard deviation) of 3.0 (2.6) vs 2.8 (2.7) for subjects receiving saline (N = 10; 95% confidence interval difference in means -2.9 to 3.4; $P = 0.86$). There were no statistically significant differences detected between treatment groups in any secondary endpoint.

Conclusions. The results of this study do not support adding an ambulatory, continuous ropivacaine infusion to a single-injection ropivacaine TAP block for hernia surgery. However, the present investigation was underpowered, and further study is warranted.

Key Words. Anesthesiology; Regional Pain; Postoperative Pain

Introduction

Over 60% of ambulatory patients undergoing inguinal hernia surgery experience moderate to severe postoperative pain at home [1]. The transversus abdominis plane (TAP) block [2] has been shown to provide analgesia and opioid sparing in the early postoperative period for surgeries involving the abdominal wall [3,4]. While a single-injection TAP block provides up to 12 hours of analgesia following surgical procedures, the surgical pain often outlasts the duration of even the longest-acting local anesthetic available for use in peripheral nerve blocks [5,6]. However, the block may be prolonged nearly indefinitely using a percutaneously inserted perineural catheter and subsequent local anesthetic infusion [7]. Case reports of such a "continuous" TAP block have been published for both in and outpatients (using a portable infusion pump) following abdominal, pelvic, and inguinal surgical procedures [8–12].

Although it might seem self-evident that a continuous infusion of local anesthetic would extend the duration of analgesia, there are reasons to question the degree of spread of local anesthetic in the TAP. In cadavers, 20 mL of dye injected in the TAP midway between the iliac crest and costal margin only consistently spread to cover T11, T12, and L1, with T10 only being covered 50% of the time [13]. Because of the extremely low volume, injection pressure, and dose of an infusion relative to a single injection, it is unlikely that the spread of a continuous infusion would cover more levels than a single injection. Unfortunately, there is no published randomized, controlled trial investigating continuous TAP blocks, and it therefore remains unknown if this technique provides benefits in addition to single-injection TAP blocks.

We therefore designed and executed this randomized, triple-masked, placebo-controlled clinical study to determine the efficacy of continuous TAP blocks in providing analgesia following inguinal and abdominal ambulatory surgical procedures. The primary endpoint was average pain with movement on postoperative day (POD) 1.

Secondary endpoints included the least, average, and worst pain as well as opioid consumption on POD 0–3.

Methods

The local Institutional Review Board (Human Research Protection Program, University California San Diego, San Diego, California) approved the protocol and oversaw the study through data analysis. The investigation was prospectively registered on ClinicalTrials.gov prior to beginning enrollment (NCT00944151). Patients offered enrollment included adults (>18 years) undergoing unilateral ambulatory inguinal and/or abdominal surgery who desired a peripheral nerve block for postoperative analgesia. Exclusion criteria included preexisting pain remote from the surgical site, history of chronic opioid use or substance abuse, pregnancy, known hepatic or renal insufficiency, peripheral neuropathy involving the surgical site, morbid obesity (body mass index > 40 kg/m²), incarceration, and inability to communicate with the investigators and hospital staff.

Catheter Insertion

Following written, informed consent, a TAP catheter was placed by an attending anesthesiologist or a regional anesthesia fellow under the direct supervision of an attending physician using a standardized ultrasound-guided technique [12]. A posterior approach, targeting the most lateral/posterior section of the TAP, was used to place the catheter at a point where the T10-L1 nerves are closest to each other [14]. Patients were placed in a lateral decubitus position with the operative side up and a pillow placed under the dependent side to extend the space between the iliac crest and costal margin on the nondependent side. Standard American Society of Anesthesiologists monitors and oxygen via facemask were applied. Intravenous fentanyl and midazolam were titrated to patient comfort. The skin was prepared with chlorhexidine gluconate (Chloraprep One Step, Medi-Flex Hospital Products, Inc, Overland Park, KS, USA) and a sterile fenestrated drape applied.

A 6- to 13-MHz linear ultrasound transducer (HFL38, Fujifilm Sonosite M-Turbo, Bothell, WA, USA) in a sterile sheath was placed at the midaxillary line in a transverse orientation in the space between iliac crest and costal margin, and the external oblique, internal oblique, and transversus abdominis muscles identified in the ultrasound plane. After anesthetizing the skin with 1% lidocaine, a 17-gauge Tuohy-tip epidural needle was introduced posterior to the ultrasound transducer and advanced in-plane in an anterior direction, with a final needle tip position between the internal oblique and transversus abdominis muscles. Ten milliliters of normal saline was injected via the needle under direct visualization to confirm proper positioning of the needle tip. A flexible 19-gauge, single-orifice, open-tipped catheter (Arrow FlexTip Plus, Teleflex Medical, Research Triangle Park, NC, USA) was advanced 3–5 cm past the needle tip. The needle was withdrawn over the catheter and the catheter

secured to the patient's ipsilateral chest wall with an anchoring device and sterile occlusive dressings. Twenty milliliters of ropivacaine 0.5% with epinephrine 5 µg/mL was injected through the catheter with gentle, intermittent aspiration and visual confirmation of local anesthetic in the TAP on ultrasound. The TAP block was considered successful if the patient exhibited a decreased sensation to cold (alcohol swab) in the ipsilateral T10-L1 distribution within 30 minutes of the local anesthetic bolus. Patients who did not demonstrate a successful block had their catheter replaced or were removed from the study.

Bilateral Catheters

For subjects undergoing surgery affecting both sides of the body (e.g., umbilical hernia repair), a catheter using the same protocol was subsequently inserted on the contralateral side.

Randomization

Subjects were randomized preoperatively following confirmation of a successful initial block. A computer-generated table was used by the Investigational Drug Service to assign patients to one of two treatment groups: ropivacaine 0.2% or normal saline (placebo) perineural infusion. The portable infusion pumps and study solutions were prepared by the same pharmacy service. Randomization was stratified by both the number of catheters (unilateral vs bilateral) and surgeon. For unilateral infusions, a portable infusion pump (ON-Q C-bloc, I-Flow Corporation, Lake Forest, CA, USA) with a 400-mL internal reservoir (basal 10 mL/h; no patient-controlled bolus) was filled with study fluid. For bilateral infusions, a similar portable infusion pump was filled with 600 mL and attached to a Y-connector that infused 7 mL/h (total flow: 14 mL/h) to each of the two bilateral catheters. Subjects, investigators, and all clinical staff were masked to treatment group assignments.

Intraoperative Management

Intraoperatively, all subjects received a general anesthetic comprised of inhaled volatile anesthetic mixed in oxygen. Intravenous fentanyl was administered for cardiovascular responsiveness to noxious stimuli. No local anesthetic infiltration was permitted within the operating room.

Postoperative Management

Intravenous fentanyl was administered for breakthrough pain in the postanesthesia care unit. The portable infusion pump was attached to the perineural catheter(s) in the recovery room. Subjects were discharged home with a prescription for a synthetic oral opioid (oxycodone 5 mg tablets). No additional analgesics such as acetaminophen or nonsteroidal anti-inflammatory medications were permitted. The subject and caretaker were given standard postoperative outpatient instructions as well as verbal and

written instructions on the use of the infusion pump and catheter. Subjects were provided with telephone and pager numbers for an Acute Pain Service physician available at all times.

Follow-Up and Outcomes

Subjects were contacted by telephone beginning the afternoon/evening of surgery, and each afternoon thereafter through the third POD. Information obtained included average and worst pain scores (Numeric Rating Scale 0–10; 0 = no pain, 10 = worst pain imaginable), oral opioid use, and sleep disturbances (both difficulty sleeping because of pain [yes/no] and number of awakenings due to pain [#]). Patients were also questioned about symptoms of local anesthetic toxicity and the appearance of the catheter site(s). On POD 2, after exhaustion of the local anesthetic reservoirs, patients' caretakers were instructed on removal of the catheter(s), with a physician in telephone contact throughout.

Statistical Analysis

Sample size calculations were centered around our primary hypothesis that a continuous TAP block will decrease "average pain" with movement on POD 1 by 2 points on the numeric rating scale of 0–10. Based on a standard deviation of 1 for the ropivacaine group and 2.5 for the placebo group [5], and assuming a two-sided type I error protection of 0.05 and a power of 0.80, approximately 15 patients in each group were required to reveal a 50% reduction in mean pain scores. To allow for a higher degree of intersubject endpoint variability, we set a goal of randomizing 20 subjects in each treatment group.

All analyses were executed using the open source statistical software R (2013)^{1,2} and performed according to the intention-to-treat principle [15]. For the primary endpoint, we compared average pain scores on POD 1 with a *t*-test and report the associated type II error. For the secondary endpoints, we used generalized estimating equation (GEE) methods to account for correlated repeated measures over time. Repeated measures proportional odds logistic regression was used for each 0–10 score, coarsened down to three categories (mild [0–3], moderate [4–6], or severe [7–10]) using the R package *repolr* [16]. We used a Poisson and logistic GEE models for count and binary data, respectively.

Results

Twenty subjects enrolled, and all had unilateral (N = 19) or bilateral (N = 1) catheter(s) inserted successfully per protocol. There were no statistically significant differences among the demographic and surgical variables between the treatment groups (Table 1). All subjects underwent unilateral inguinal hernia repair with the exception of a single subject undergoing a small umbilical hernia repair who received bilateral catheters. Enrollment was curtailed

Table 1 Population data and procedural information

Perineural Infusion	Ropivacaine	Placebo	P Value
Age (years)	61 (20)	60 (21)	0.94
Sex (female/male)	8/2	10/0	0.47
Height (cm)	175 (7)	176 (6)	0.85
Weight (kg)	77 (12)	80 (12)	0.60
BMI	25.1 (4.6)	25.9 (3.7)	0.69
Unilateral catheters (#)	9	10	N/A
Catheter insertion (min)	7.8 (5.1)	5.2 (1.5)	0.15
Worst pain during insertion (0–10)	1.6 (1.8)	2.0 (1.9)	0.63
Surgical time (min)	85 (50)	95 (30)	0.64
Hydromorphone (mg)	0.0 (0.0)	0.1 (0.4)	0.36
Morphine (mg)	0.0 (0.0)	1.1 (3.0)	0.36
Midazolam (mg)	2.6 (2.3)	3.0 (1.8)	0.71
Fentanyl (μ g)	182 (73)	254 (96)	0.15

Values are reported as mean (standard deviation) or number of subjects, as indicated. BMI = body mass index; N/A = not applicable.

prior to attaining full enrollment due to the primary surgeon's unanticipated departure from the institution.

Primary Endpoint

Average pain queried on POD 1 for subjects receiving ropivacaine (N = 10) was a mean (SD) of 3.0 (2.6) vs 2.8 (2.7) for subjects receiving saline (N = 10; 95% CI difference in means -2.9 to 3.4; $P = 0.86$).

Secondary Endpoints

There were no statistically significant differences detected between treatment groups in any of the secondary endpoints, including least, average, and worst pain scores (Figure 1), as well as supplemental opioid requirements (Figure 2) and sleep disturbances (Table 2). By POD 2, three subjects from each treatment group were experiencing leakage from the catheter site. There were no other adverse events.

Table 2 Data on sleep disturbances

Perineural Infusion	Ropivacaine	Placebo
Difficulty sleeping due to pain		
First night (#)	2	2
Second night (#)	1	1
Third night (#)	1	0
Awakenings due to pain		
First night (#)	0 (0–0)	0 (0–0)
Second night (#)	0 (0–0)	0 (0–0)
Third night (#)	0 (0–0)	0 (0–0)

Values are reported as median (interquartile) or number of subjects, as indicated. There were no statistically significant differences between treatments at any time point.

Discussion

The results of this randomized, triple-masked, placebo-controlled study do not support adding a continuous TAP block to a single-injection ropivacaine TAP block for outpatients undergoing hernia surgery. While there are multiple case reports and small series asserting the analgesic benefit of continuous TAP blocks, ours is the first randomized, controlled trial to investigate this technique. Given our results with pain scores for the placebo group in the range that we expected based on our experience with historic controls, further supportive evidence is needed to justify catheter placement and maintenance for this surgical population to outweigh potential risks [17].

Single-Injection TAP Blocks

In contrast to our negative findings for the continuous perineural infusion, there is a good deal of evidence from multiple high-quality studies that single-injection TAP techniques do provide analgesic and opioid-sparing benefits. However, the value of the block appears dependent on the surgical procedure and resulting pain intensity. Single-injection TAP blocks have been used for cesarean section, laparoscopic cholecystectomy, total abdominal hysterectomy, retropubic prostatectomy, and large bowel resections with midline incisions [2,5,9,18–22]; however, well-designed randomized, controlled trials are available for few of these indications. A study by Aveline and colleagues demonstrated improvement in results using ultrasound-guided TAP block vs a blind ilioinguinal/iliohypogastric nerve block technique for open hernia repairs [23]. Salman and colleagues found a significant reduction in opioid use when a single-injection TAP block was administered in the setting of spinal anesthesia and dex-ketoprofen for inguinal herniorrhaphy [24]. However, Petersen and colleagues found no

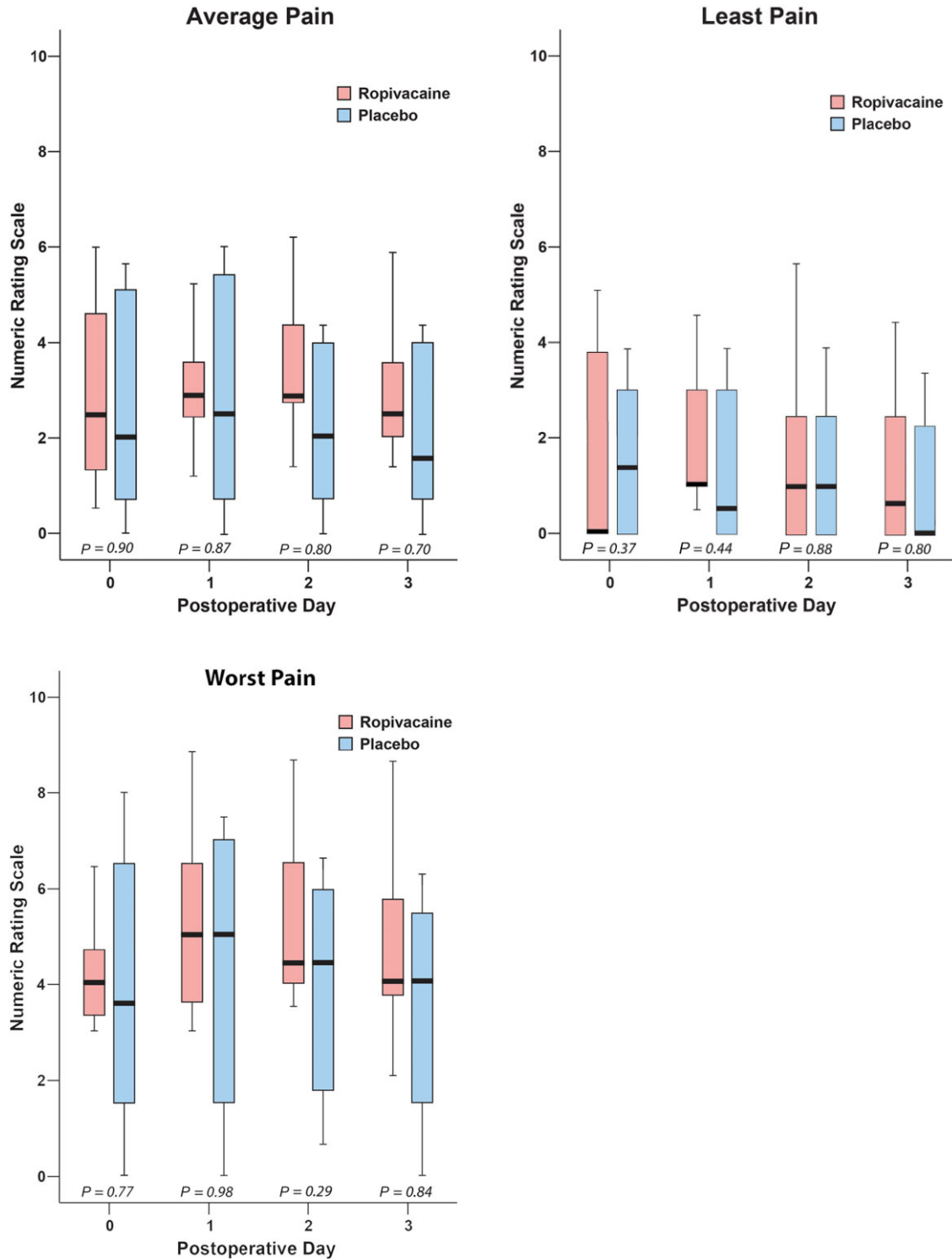


Figure 1 Effects of a transversus abdominis plane infusion (ropivacaine, 0.2%, vs placebo) on *average*, *least*, and *worst pain* following inguinal and abdominal surgery (Numeric Rating Scale: 0–10). Perineural infusions were discontinued on postoperative day 2. Data are expressed as median (horizontal line), 25th–75th percentiles (box), and 10th–90th percentiles (whiskers). For tightly clustered data, the median horizontal line also represents 10th, 25th, 75th, and/or 90th percentile(s), as appropriate.

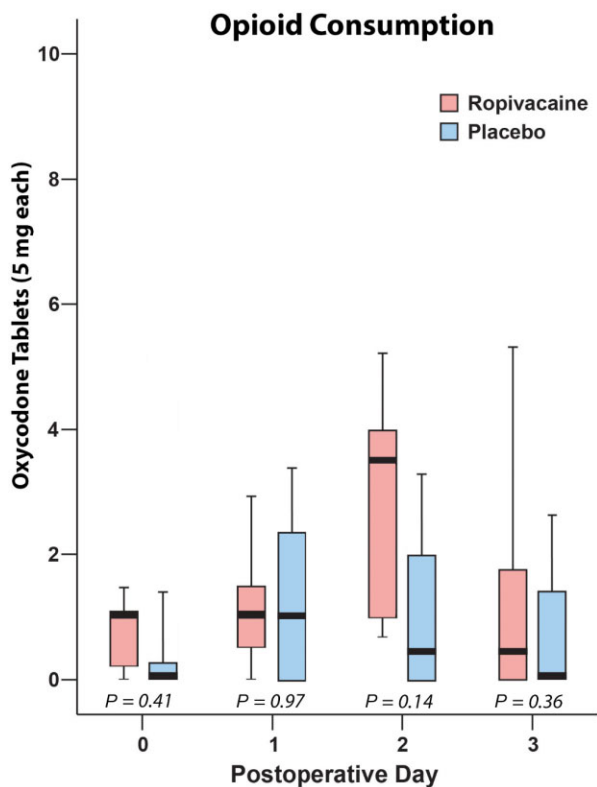


Figure 2 Effects of a transversus abdominis plane infusion (ropivacaine, 0.2%, vs placebo) on *supplemental opioid requirements* following inguinal and abdominal surgery (Numeric Rating Scale: 0–10). Perineural infusions were discontinued on postoperative day 2. Values are the number of oxycodone tablets (5 mg each)—a synthetic oral opioid—consumed for each time point. Data are expressed as median (horizontal line), 25th–75th percentiles (box), and 10th–90th percentiles (whiskers). For tightly clustered data, the median horizontal line also represents 10th, 25th, 75th, and/or 90th percentile(s), as appropriate.

significant difference in pain scores when comparing local anesthetic infiltration, placebo infiltration, and single-injection TAP blocks for open hernia repair over the course of 24 hours [25].

Continuous TAP Blocks

Niraj and colleagues reported using TAP catheters for continuous local anesthetic infusions for sustained postoperative analgesia for inpatients [8]. Heil and colleagues published a case series of outpatient TAP catheters following inguinal hernia repair [12]. In this small series, all

patients reported numeric rating scale pain scores less than 4 on a 0–10 Numeric Rating Scale of pain for the duration of the infusion, and none required opioid analgesics during the 2 days that the catheters were in place [12]. The negative results of the present study—the first randomized, controlled trial—may seem disappointing. The benefits of continuous peripheral nerve blocks in other anatomic locations besides the TAP are well documented [17]. It might seem a foregone conclusion that TAP infusions would provide similar benefits. However, such inference from studies involving other anatomic sites should be avoided as their local anesthetic effects are often specific to one anatomic site or target nerve [18]. Inguinal and lower abdominal surgical procedures often involve multiple dermatomes, and while a high-volume and pressure single-injection TAP block might spread to multiple nerves, a low-volume and pressure continuous infusion may affect only one to two nerves immediately adjacent to the catheter tip. For example, we provided exclusively a basal infusion of 7 or 10 mL/h (ropivacaine 0.2%) without patient-controlled bolus doses. The optimal delivery regimen for TAP infusions remains unknown; therefore, a higher basal infusion rate and/or local anesthetic concentration than used in this study may yield superior results. In addition, a possibility is that repeated, regularly scheduled/triggered bolus doses might spread the local anesthetic to a larger area than a continuous basal infusion.

Limitations

There are a number of limitations of our study. Our a priori power analysis suggested that 15 subjects in each treatment group were required to reveal a 50% reduction in mean pain scores. However, because the surgeon who was providing the subjects for this study left the institution prior to the completion of enrollment, we enrolled only 10 subjects in each treatment group. This resulted in an underpowered study that may explain the lack of observed treatment effect.

This study included exclusively inguinal and umbilical hernia procedures, and its results should be applied only to similar surgeries. Other more invasive surgical procedures may be more amenable to treatment with a continuous TAP block, and further study is definitely warranted. In addition, other infusion modalities might provide improved effectiveness. Similarly, the optimal TAP catheter insertion protocol and equipment remain uninvestigated and unknown. It is possible that a different technique than the one used in the present study and/or a different perineural catheter design may provide different results. Our results are applicable only to single-injection continuous TAP blocks using ropivacaine and not single-injection peripheral nerve blocks using ultra-long-acting liposomal bupivacaine [26]. Finally, of the 20 subjects enrolled in this study, 18 (90%) were women. It is possible that TAP catheters have different efficacy among men, which this study could not detect with only two men enrolled.

In summary, this investigation provides no evidence that following hernia surgery, adding a multiple-day,

ambulatory, continuous ropivacaine infusion to a single-injection ropivacaine TAP block results in improved analgesia or other benefits. However, further study with larger sample sizes, different surgical procedures, various infusion modalities, diverse catheter insertion techniques, and dissimilar catheter types is warranted.

Acknowledgments

Funding for this project is provided by the National Institutes of Health grant GM077026 (P.I.: Dr. Ilfeld) from the National Institute of General Medical Sciences (Bethesda, Maryland); the Clinical and Translational Research Institute, University of California, San Diego (San Diego, California), with funding provided by the National Institutes of Health grants UL1RR031980 and UL1TR000100; the Department of Anesthesiology, University of California San Diego (San Diego, California); and I-Flow Corporation (Lake Forest, California).

Notes

1. Zeileis A, Kleiber C, Jackman S. Regression models for count data in R. *J Stat Software* 2008; 27. Available at: <http://www.jstatsoft.org/v27/i08> (accessed February 22, 2013).
2. R Core Team. R: A language and environment for statistical computing. R Foundation for Statistical Computing, Vienna, Austria; 2013. Available at: <http://www.R-project.org/>.

References

- 1 Rawal N, Hylander J, Nydahl PA, Olofsson I, Gupta A. Survey of postoperative analgesia following ambulatory surgery. *Acta Anaesthesiol Scand* 1997;41: 1017–22.
- 2 Carney J, Finnerty O, Rauf J, et al. Ipsilateral transversus abdominis plane block provides effective analgesia after appendectomy in children: A randomized controlled trial. *Anesth Analg* 2010;111:998–1003.
- 3 Abdallah FW, Chan VW, Brull R. Transversus abdominis plane block: A systematic review. *Reg Anesth Pain Med* 2012;37:193–209.
- 4 Abdallah FW, Halpern SH, Margarido CB. Transversus abdominis plane block for postoperative analgesia after Caesarean delivery performed under spinal anaesthesia: A systematic review and meta-analysis. *Br J Anaesth* 2012;109:679–87.
- 5 McDonnell JG, O'Donnell B, Curley G, et al. The analgesic efficacy of transversus abdominis plane block after abdominal surgery: A prospective randomized controlled trial. *Anesth Analg* 2007;104:193–7.
- 6 Taylor R Jr, Pergolizzi JV, Sinclair A, et al. Transversus abdominis block: Clinical uses, side effects, and future perspectives. *Pain Pract* 2013;13:332–44.
- 7 Borghi B, D'Addabbo M, White PF, et al. The use of prolonged peripheral neural blockade after lower extremity amputation: The effect on symptoms associated with phantom limb syndrome. *Anesth Analg* 2010;111:1308–15.
- 8 Niraj G, Kelkar A, Fox AJ. Oblique sub-costal transversus abdominis plane (TAP) catheters: An alternative to epidural analgesia after upper abdominal surgery. *Anaesthesia* 2009;64:1137–40.
- 9 Gucev G, Yasui GM, Chang TY, Lee J. Bilateral ultrasound-guided continuous ilioinguinal-iliohypogastric block for pain relief after cesarean delivery. *Anesth Analg* 2008;106:1220–2.
- 10 Hebbard PD, Barrington MJ, Vasey C. Ultrasound-guided continuous oblique subcostal transversus abdominis plane blockade: Description of anatomy and clinical technique. *Reg Anesth Pain Med* 2010; 35:436–41.
- 11 Allcock E, Spencer E, Frazer R, Applegate G, Buckenmaier C III. Continuous transversus abdominis plane (TAP) block catheters in a combat surgical environment. *Pain Med* 2010;11:1426–9.
- 12 Heil JW, Ilfeld BM, Loland VJ, Sandhu NS, Mariano ER. Ultrasound-guided transversus abdominis plane catheters and ambulatory perineural infusions for outpatient inguinal hernia repair. *Reg Anesth Pain Med* 2010;35:556–8.
- 13 Tran TM, Ivanusic JJ, Hebbard P, Barrington MJ. Determination of spread of injectate after ultrasound-guided transversus abdominis plane block: A cadaveric study. *Br J Anaesth* 2009;102:123–7.
- 14 Rozen WM, Tran TM, Ashton MW, et al. Refining the course of the thoracolumbar nerves: A new understanding of the innervation of the anterior abdominal wall. *Clin Anat* 2008;21:325–33.
- 15 Todd MM. Clinical research manuscripts in Anesthesiology. *Anesthesiology* 2001;95:1051–3.
- 16 Parsons NR, Costa ML, Achten J, Stallard N. Repeated measures proportional odds logistic regression analysis of ordinal score data in the statistical software package R. *Comput Stat Data Anal* 2009; 53:632–41.
- 17 Ilfeld BM. Continuous peripheral nerve blocks: A review of the published evidence. *Anesth Analg* 2011;113:904–25.
- 18 Ilfeld BM, Loland VJ, Gerancher JC, et al. The effects of varying local anesthetic concentration and volume on continuous popliteal sciatic nerve blocks: A dual-center, randomized, controlled study. *Anesth Analg* 2008;101:701–7.

Heil et al.

- 19 McDonnell JG, Curley G, Carney J, et al. The analgesic efficacy of transversus abdominis plane block after cesarean delivery: A randomized controlled trial. *Anesth Analg* 2008;106:186–91.
- 20 Carney J, McDonnell JG, Ochana A, Bhinder R, Laffey JG. The transversus abdominis plane block provides effective postoperative analgesia in patients undergoing total abdominal hysterectomy. *Anesth Analg* 2008;107:2056–60.
- 21 El-Dawlatly AA, Turkistani A, Kettner SC, et al. Ultrasound-guided transversus abdominis plane block: Description of a new technique and comparison with conventional systemic analgesia during laparoscopic cholecystectomy. *Br J Anaesth* 2009;102:763–7.
- 22 Kadam RV, Field JB. Ultrasound-guided continuous transverse abdominis plane block for abdominal surgery. *J Anaesthesiol Clin Pharmacol* 2011;27:333–6.
- 23 Aveline C, Le Hetet H, Le Roux A, et al. Comparison between ultrasound-guided transversus abdominis plane and conventional ilioinguinal/iliohypogastric nerve blocks for day-case open inguinal hernia repair. *Br J Anaesth* 2011;106:380–6.
- 24 Salman AE, Yetisir F, Yurekli B, et al. The efficacy of the semi-blind approach of transversus abdominis plane block on postoperative analgesia in patients undergoing inguinal hernia repair: A prospective randomized double-blind study. *Local Reg Anesth* 2013;6:1–7.
- 25 Petersen PL, Mathiesen O, Stjernholm P, et al. The effect of transversus abdominis plane block or local anaesthetic infiltration in inguinal hernia repair: A randomised clinical trial. *Eur J Anaesthesiol* 2013;30:415–21.
- 26 Ilfeld BM. Liposome bupivacaine in peripheral nerve blocks and epidural injections to manage postoperative pain. *Expert Opin Pharmacother* 2013;14:2421–31.