

UCSF

UC San Francisco Previously Published Works

Title

Hepatotoxicity after transarterial chemoembolization and transjugular intrahepatic portosystemic shunt: do two rights make a wrong?

Permalink

<https://escholarship.org/uc/item/63k3b8tx>

Journal

Journal of vascular and interventional radiology : JVIR, 24(1)

ISSN

1051-0443

Authors

Kohi, Maureen P
Fidelman, Nicholas
Naeger, David M
[et al.](#)

Publication Date

2013

DOI

10.1016/j.jvir.2012.08.032

Peer reviewed

Hepatotoxicity after Transarterial Chemoembolization and Transjugular Intrahepatic Portosystemic Shunt: Do Two Rights Make a Wrong?

Maureen P. Kohi, MD, Nicholas Fidelman, MD, David M. Naeger, MD, Jeanne M. LaBerge, MD, Roy L. Gordon, MD, and Robert K. Kerlan, Jr, MD

ABSTRACT

Purpose: To compare the rates of hepatotoxicity after transarterial chemoembolization for hepatocellular carcinoma (HCC) in patients with and without a transjugular intrahepatic portosystemic shunt (TIPS) who were stratified into comparable risk groups.

Materials and Methods: A retrospective review of patients with HCC who were treated with transarterial chemoembolization between January 2005 and December 2009 was performed. Of 158 patients with comparable model for end-stage liver disease (MELD) scores, 10 had a patent TIPS. Hepatobiliary severe adverse events (SAEs) occurring after transarterial chemoembolization were documented. In addition, 1-year survival and liver transplantation rate after transarterial chemoembolization were calculated in each group.

Results: The incidence of hepatobiliary SAEs after transarterial chemoembolization was nearly two times higher in patients with a TIPS (70%) than in patients without a TIPS (36%; $P = .046$). The liver transplantation rate 1 year after transarterial chemoembolization was 2.5 times higher in patients with a TIPS (80%) than in patients without a TIPS (32%; $P = .004$). There was no significant difference in 1-year survival between the two groups after transarterial chemoembolization.

Conclusions: Patients with HCC and a patent TIPS are more likely to develop significant hepatotoxicity after transarterial chemoembolization than comparable patients without a TIPS in place.

ABBREVIATIONS

CPT = Child-Pugh-Turcotte; HCC = hepatocellular carcinoma; MELD = model for end-stage liver disease; NCI CTCAE = National Cancer Institute Common Terminology Criteria for Adverse Events; SAE = severe adverse event; TIPS = transjugular intrahepatic portosystemic shunt

Hepatocellular carcinoma (HCC) is the second most frequent cause of cancer death worldwide in men and the sixth leading cause of cancer death in women (1,2). Transplantation and surgical resection are considered to be the only curative treatments (3–5). Only a small percentage of patients with HCC are candidates for

resection (6,7). Liver-directed therapies are widely used to “bridge” patients to transplant or to treat patients with unresectable HCC (8). Transarterial chemoembolization has become a commonly employed treatment for HCC (9–11). However, hepatic dysfunction is frequently observed after chemoembolization (12,13).

In addition to predisposing patients to HCC, cirrhosis leads to portal hypertension (14). A transjugular intrahepatic portosystemic shunt (TIPS) is an important therapeutic option in managing the complications of portal hypertension, such as variceal bleeding and refractory ascites (15). Some patients who have undergone a TIPS procedure for the treatment of complications related to portal hypertension are later found to have HCC and require therapy for the cancer. However, such patients are not considered ideal candidates for transarterial chemoembolization because of the diversion of the portal venous flow via the TIPS. Previous reports of transarterial chemoembolization in patients with a TIPS have included case reports or small patient series without direct comparison with a

From the Department of Radiology and Biomedical Imaging, University of California, San Francisco, 505 Parnassus Avenue, M-361, San Francisco, CA 94143. Received March 31, 2012; final revision received July 16, 2012; accepted August 17, 2012. Address correspondence to M.P.K.; E-mail: maureen.kohi@ucsf.edu

An oral presentation of the abstract of this paper was presented at the SIR 36th Annual Scientific Meeting.

None of the authors have identified a conflict of interest.

© SIR, 2013

J Vasc Interv Radiol 2013; 24:68–73

<http://dx.doi.org/10.1016/j.jvir.2012.08.032>

control, non-TIPS group (16–20). The purpose of our study was to compare the rates of hepatotoxicity after transarterial chemoembolization for HCC in patients with and without a patent TIPS who were stratified into comparable risk groups.

MATERIALS AND METHODS

Patients

Our study was approved by our institutional review board. An informed consent requirement was waived. A retrospective record review of patients who underwent transarterial chemoembolization at our institution between January 2005 and December 2009 was performed. We identified 10 patients who had a patent TIPS at the time of the transarterial chemoembolization procedure within the specified 5-year time period. Calculated model for end-stage liver disease (MELD) scores for the patients ranged from 10–18. A TIPS procedure had been performed on six patients for secondary prevention of variceal bleeding. The remaining four patients had undergone a TIPS procedure because of refractory ascites.

Seven patients had undergone the TIPS procedure at another institution, and records from the procedure were unavailable for review. The remaining three patients underwent the TIPS procedure at our institution using previously described techniques (21). A GORE VIATORR stent graft (W.L. Gore & Associates, Flagstaff, Arizona) was used for shunt creation in two cases, with the TIPS in the third case formed using a WALLSTENT (Boston Scientific, Natick, Massachusetts). In all three cases, a decrease in

portosystemic gradient was noted from 32 mm Hg to 11 mm Hg, 20 mm Hg to 10 mm Hg, and 32 mm Hg to 8 mm Hg. We identified 148 patients with comparable MELD scores who did not have a TIPS and were treated with transarterial chemoembolization in the same 5-year time period to serve as the control population. All patients were also classified using the Child-Pugh-Turcotte (CPT) classification system. All patients had a diagnosis of HCC, which was based on European Association for the Study of the Liver guidelines (22). Characteristics of the patient population are summarized in **Table 1**.

TIPS patency was confirmed using Doppler abdominal ultrasound performed within 6 months of the transarterial chemoembolization procedure as part of routine clinical care. In all patients with a TIPS, vascular flow was present throughout the entire shunt, and midshunt velocities were > 60 cm/s. Based on prior reports (25,26), midshunt velocities > 60 cm/s were considered a reliable indicator of TIPS patency.

Transarterial Chemoembolization Regimen

Transarterial chemoembolization was performed with a combination of doxorubicin hydrochloride (25 mg), mitomycin C (10 mg), and cisplatin (50 mg) administered in a 1:1 emulsion with ethiodized oil (Ethiodol; Laboratoires Guerbet, Roissy, France). The aqueous component for the emulsion was Omnipaque 350 contrast agent (Amersham Pharmacia Biotech, Piscataway, New Jersey). The transarterial chemoembolization regimen was similar for patients with and

Table 1. Patient Characteristics

Variables	TIPS Group (n = 10)	Non-TIPS Group (n = 148)	P Value
Age (y), median (range)	59 (51–72)	59 (40–82)	.79
Male gender, number of patients (%)	9 (90)	124 (84)	.99
MELD score, median (range)	15 (10–18)	12 (10–18)	.35
CPT score, median (range)	7 (5–11)	7 (5–12)	.61
Child-Pugh class, number of patients (%)			.12
A	5 (50)	41 (28)	
B	3 (30)	89 (60)	
C	2 (20)	18 (12)	
Cause of cirrhosis, number of patients (%)			.19
Viral hepatitis	6 (60)	115 (78)	
Alcohol	1 (10)	9 (6)	
NASH	2 (20)	8 (5)	
Other/combination	1 (10)	16 (11)	
BCLC stage, number of patients (%)			.97
0	1 (10)	17 (11)	
A	5 (50)	77 (52)	
B	2 (20)	26 (18)	
C	0 (0)	7 (5)	
D	2 (20)	21 (14)	

BCLC = Barcelona Clinic Liver Cancer (23,24), CPT = Child-Pugh-Turcotte, MELD = model for end stage liver disease, NASH = nonalcoholic steatohepatitis, TIPS = transjugular intrahepatic portosystemic shunt.

without a TIPS. The dose of doxorubicin was reduced by 50% in patients with serum bilirubin level > 3.5 mg/dL. The dose of doxorubicin was reduced for two patients (20%) in the TIPS group and for 16 patients (11%) in the non-TIPS group. Mitomycin C was withheld for two patients in the TIPS group (20%) and for 50 patients (34%) in the non-TIPS group who had white blood cell count < 3,000/ μ L or platelet count < 60,000/ μ L. Cisplatin was not administered to two patients (20%) in the TIPS group and to 25 patients (24%) in the non-TIPS group who had a serum creatinine level > 1.2 mg/dL.

Chemoembolization was performed in a selective fashion, with a 3-F microcatheter (Renegade HI-FLO, Boston Scientific) coaxially placed into a second-order or third-order branch off the right or left hepatic artery in close proximity to the tumor. The endpoint of the embolization was defined as stasis of flow in the targeted second-order or third-order branches off the selected hepatic artery. In case of residual arterial flow at the completion of drug delivery, flow stasis was achieved by injecting slurry of gelatin sponge (Gelfoam; Pharmacia & Upjohn, Kalamazoo, Michigan).

Study Outcomes

Determination of hepatotoxicity after transarterial chemoembolization was based on the presence of one of the hepatobiliary severe adverse events (SAEs) defined using the National Cancer Institute Common Terminology Criteria for Adverse Events (NCI CTCAE) version 4.03 (27). Hepatotoxicity was documented if at least one of the following abnormal laboratory values or clinical states was observed within 30 days after transarterial chemoembolization: NCI CTCAE grade 3 or 4 for serum levels of total bilirubin, aspartate aminotransferase, alanine aminotransferase, or creatinine; international normalized ratio for prothrombin time; platelet count; presence of severe symptoms of ascites indicating invasive intervention; or clinical hepatic failure manifesting through asterixis, mild encephalopathy, limiting self-care or activities of daily living, hepatic necrosis, or gastric or intestinal hemorrhage. Liver transplantation rate and overall survival 1 year after transarterial chemoembolization were documented.

Statistical Analysis

Continuous variables including patient age, MELD score, and CPT scores were compared using the Wilcoxon rank sum test. Categorical variables such as gender distribution, Child-Pugh class, etiology of cirrhosis, and Barcelona Clinic Liver Cancer stage were compared using Fisher exact test (selected because of the small number of patients in some categories). Rates of hepatobiliary SAEs and liver transplantation after transarterial chemoembolization were compared using the Fisher exact test. Kaplan-Meier survival curves were generated for a period of 1 year after transarterial chemoembolization, and differences were assessed with the log-rank test. A *P* value < .05 was considered statistically significant.

RESULTS

The study groups were similar in age range, gender distribution, MELD score, CPT score, cirrhosis etiologies, and Barcelona Clinic Liver Cancer stage (Table 1). In the TIPS group, within 30 days of transarterial chemoembolization, 7 patients (70%) had one or more hepatobiliary SAEs compared with 54 patients (36%) in the non-TIPS group (*P* = .046). Individual SAEs are summarized in Table 2. Among the hepatobiliary SAEs documented, grade 3 or 4 hyperbilirubinemia in the TIPS group was seen in 6 patients (60%) compared with 29 patients (20%) in the non-TIPS group (*P* = .009). Four of six cases (67%) of grade 3 or 4 hyperbilirubinemia in the TIPS group were reversible. In the non-TIPS group, 20 of 29 cases (69%) of grade 3 or 4 hyperbilirubinemia were reversible. No significant difference was noted between the two groups with respect to the proportions of patients with grade 3 or 4 aspartate aminotransferase (*P* = .71) or alanine aminotransferase levels (*P* = .45); presence of symptoms of severe ascites indicating invasive intervention (*P* = .12); or hepatic failure manifested by asterixis, mild encephalopathy, or limiting self-care or activities of daily living (*P* = 1). None of the patients experienced grade 3 or 4 thrombocytopenia, hepatic necrosis, or gastric or intestinal hemorrhage.

Of the patients with one or more hepatobiliary SAEs, 2 of 7 patients (29%) in the TIPS group had at least one irreversible SAE compared with 11 of 54 patients (20%) in the non-TIPS group (*P* = .63). The irreversible SAE in the TIPS group was grade 3 hyperbilirubinemia, and the irreversible SAEs in the non-TIPS group were grade 3 hyperbilirubinemia and ascites. The remainder of the patients experienced only reversible SAEs. Mean interval time to improvement to below a grade 3 abnormality level was 2.8 months in the TIPS group (range, 1–7 months) compared with 1.3 months in the non-TIPS group (range, 1–6 months; *P* = .05).

Mean follow-up period after transarterial chemoembolization was 16 months (range, 1–59 months). Eight of the patients with a TIPS (80%) received a liver transplant within 1 year of transarterial chemoembolization. The rate of transplantation in the non-TIPS group was significantly lower (*P* = .004), with 47 patients (32%) having received an organ within 1 year of transarterial chemoembolization. None of the transplanted patients died within 1 year of transarterial chemoembolization. Overall survival at 1 year after transarterial chemoembolization was not significantly different (*P* = .98) between the two groups (Fig 1).

DISCUSSION

A patent TIPS diminishes portal venous flow to the liver parenchyma by diverting flow away from the liver. Arterial embolization would be expected to decrease hepatic perfusion further and could lead to liver tissue damage. Prior case reports have illustrated the successful therapeutic effects of a

Table 2. Hepatobiliary Severe Adverse Events

Severe Adverse Events	TIPS Group (n = 10)	Non-TIPS Group (n = 148)	P Value
Total bilirubin, number of patients (%)			.009*
Grade 3: total bilirubin > 3–10 × ULN	6 (60)	26 (18)	
Grade 4: total bilirubin > 10 × ULN	0 (0)	3 (2)	
AST, number of patients (%)			.71*
Grade 3: AST > 5–20 × ULN	2 (20)	35 (24)	
Grade 4: AST > 20 × ULN	1 (10)	1 (0.7)	
ALT, number of patients (%)			.45*
Grade 3: AST > 5–20 × ULN	0 (0)	8 (5)	
Grade 4: AST > 20 × ULN	1 (10)	0 (0)	
Ascites, number of patients (%)			.12
Grade 3: severe symptoms; invasive intervention indicated	2 (20)	8 (5)	
Hepatic failure, number of patients (%)			.99
Grade 3: asterixis; mild encephalopathy; limiting self-care ADL	0 (0)	1 (0.7)	

ADL = activities of daily living, ALT = alanine aminotransferase, AST = aspartate aminotransferase, TIPS = transjugular intrahepatic portosystemic shunt, ULN = upper limits of normal.

* P value generated using the total number of patients with grade 3 and grade 4 severe adverse events in each group.

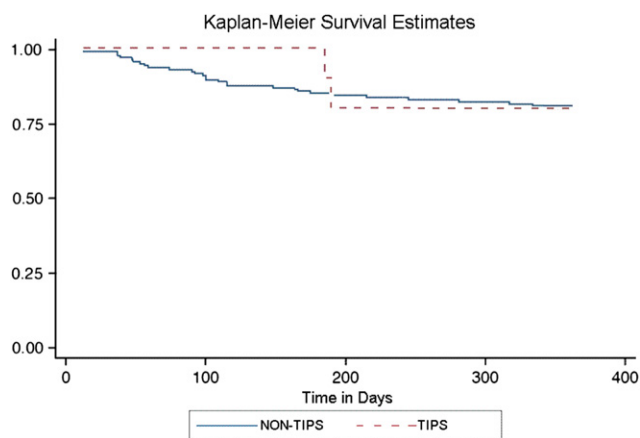


Figure 1. The difference in Kaplan-Meier curves as measured by the log-rank test was not significant ($P = .98$). (Available in color online at www.jvir.org.)

TIPS in the setting of variceal bleeding in patients with preexisting HCC (28–30). However, in each case, there was concern regarding hepatic dysfunction caused by the TIPS-induced decrease in portal blood flow. When such a nutrient-deprived liver parenchyma is subjected to chemoembolization, hepatic dysfunction in the form of hyperbilirubinemia, transaminitis, or ascites can ensue.

In our study population, the rate of severe hepatotoxicity, as defined by development of a number of NCI CTCAE grade 3 or 4 hepatobiliary SAEs 30 days after transarterial chemoembolization, was nearly two times higher in patients with a patent TIPS compared with patients without a TIPS. The rate of grade 3 or 4 hyperbilirubinemia was three times higher in the TIPS group compared with the group without TIPS.

Despite the increased incidence of hepatobiliary SAEs in the TIPS group, overall survival 1 year after transarterial chemoembolization was not significantly different between the two groups. The rate of liver transplantation within 1

year after transarterial chemoembolization was 2.5 times higher in patients with a TIPS compared with patients without TIPS. Although other underlying factors may have contributed to this increased transplantation rate, the higher incidence of hepatobiliary SAEs after transarterial chemoembolization may have been the cause of the increased need for liver transplantation. The higher rate of transplantation in the TIPS group may explain the observed similarity in the survival rates observed in both groups 1 year after transarterial chemoembolization.

Our study is the first to compare hepatotoxicity after transarterial chemoembolization between patients with and without a patent TIPS. Prior case reports have described transarterial chemoembolization in patients with a TIPS (16–20) with successful results. Tesdal et al (16) treated six patients with HCC and a TIPS with transarterial chemoembolization using epirubicin. Three of the six patients underwent additional percutaneous ethanol injection procedures. Of the six patients, one patient underwent liver transplantation, two patients died of peritonitis or liver failure, and the remaining three patients had stable disease without signs of hepatic deterioration. The patients who were alive by the end of the follow-up period and had not received a liver transplant were in Child-Pugh class A or B. The authors concluded that transarterial chemoembolization and additional locoregional therapies can be safe for patients with a TIPS and HCC, as long as underlying liver function is adequate. Our study data do not support this conclusion. Although most of our patients with a TIPS had a similar severity of cirrhosis (Child-Pugh class A or B), 70% of them experienced hepatobiliary SAEs. However, Tesdal et al (16) did not administer gelatin sponge slurry, after transarterial chemoembolization, and the dose of epirubicin was adjusted based on liver function and tumor size. It is possible that this difference in the transarterial chemoembolization regimen may partly explain the differences observed in hepatobiliary SAEs between their study and ours.

Kang et al (17) showed that selective transarterial chemoembolization may be a safe and effective treatment for HCC in patients with a TIPS. In their study, only 1 of 20 patients experienced adverse events (spontaneous bacterial peritonitis) after transarterial chemoembolization. This rate is lower than the rate of SAEs noted in our study (70%). An explanation for this difference could be the different chemoembolization regimen. Kang et al (17) performed chemoembolization using a mixture of iodized oil and cisplatin, followed by absorbable gelatin sponge particles. Their results also suggested that late tumor staging was a poor prognostic factor for patient survival. Because of the small number of patients in our study, we did not evaluate for a correlation between tumor staging and patient survival.

There are limitations in our study. The small number of patients in the TIPS group and a comparatively large number of patients in the non-TIPS group potentially limit the power to detect small differences between the two groups. However, the sample sizes reflect the maximum number of patients with a TIPS and without a TIPS who underwent transarterial chemoembolization retrospectively at our institution during the specified time period. Multiple comparisons performed with one group having a small sample size increase the risk of a type I error. We sought to limit the number of primary comparisons to three: survival, transplant, and total SAEs. We secondarily compared individual SAEs, although the one statistically significant result could be considered in the context of multiple comparisons in secondary aims. Another limitation was the availability of abdominal ultrasound evaluation for TIPS patency within 6 months of the transarterial chemoembolization. We acknowledge that this is a long period of time and can result in underdiagnosis of possible TIPS stenoses, which may result in shunt dysfunction at the time of transarterial chemoembolization. The retrospective nature of the study limits a more accurate assessment of shunt patency at the time of transarterial chemoembolization. Review of medical records for each of the patients with a TIPS performed within 1 week of transarterial chemoembolization did not show clinical signs of TIPS dysfunction such as variceal bleeding or recurrent ascites, suggesting that the TIPS was patent at the time of transarterial chemoembolization. Although laboratory data were available on all patients within 1 month of transarterial chemoembolization and at regular intervals during their clinical follow-up period, clinical data regarding the presence of ascites or encephalopathy were limited to notes documented during clinic visits or based on follow-up imaging; this may have underestimated the number of patients who experienced ascites or encephalopathy after transarterial chemoembolization in each group. A prospective study of patients with a patent TIPS who are undergoing chemoembolization would be helpful in further delineating the risks and benefits of transarterial chemoembolization in patients with HCC and a patent TIPS.

In conclusion, our study suggests that in patients with a patent TIPS who are diagnosed with HCC, transarterial

chemoembolization is not a wrong choice of therapy. The data suggest that transarterial chemoembolization carries a higher risk of significant hepatic decompensation in patients with a TIPS compared with patients without a TIPS. However, transarterial chemoembolization can be performed in these patients with the foresight that they may be more likely to develop liver decompensation, and should liver failure ensue, a liver transplantation may be required. Conversely, transarterial chemoembolization may not be safe for patients with a TIPS who are not transplant candidates. Awareness of the increased risk of hepatic decompensation after transarterial chemoembolization should aid hepatologists and interventional radiologists in making appropriate recommendations for patients with HCC and a patent TIPS.

REFERENCES

1. Jemal A, Bray F, Center MM, Ferlay J, Ward E, Forman D. Global cancer statistics. *CA Cancer J Clin* 2011; 61:69–90.
2. Altekruse SF, McGlynn KA, Reichman ME. Hepatocellular carcinoma incidence, mortality, and survival trends in the United States from 1975 to 2005. *J Clin Oncol* 2009; 27:1485–1491.
3. Höpfner M, Schuppan D, Scherübl H. Growth factor receptors and related signaling pathways as targets for novel treatment strategies of hepatocellular cancer. *World J Gastroenterol* 2008; 14:1–14.
4. Bruix J, Hessheimer AJ, Forner A, Boix L, Vilana R, Llovet JM. New aspects of diagnosis and therapy of hepatocellular carcinoma. *Oncogene* 2006; 25:3848–3856.
5. Petrowsky H, Busuttill RW. Resection or ablation of small hepatocellular carcinoma: what is the better treatment? *J Hepatol* 2008; 49:502–504.
6. Llovet JM, Fuster J, Bruix J. Barcelona-Clinic Liver Cancer Group. The Barcelona approach: diagnosis, staging, and treatment of hepatocellular carcinoma. *Liver Transpl* 2004; 10:S115–S120.
7. Figueras J, Jaurrieta E, Valls C, et al. Resection or transplantation for hepatocellular carcinoma in cirrhotic patients: outcomes based on indicated treatment strategy. *J Am Coll Surg* 2000; 190:580–587.
8. McWilliams JP, Yamamoto S, Raman SS, et al. Percutaneous ablation of hepatocellular carcinoma: current status. *J Vasc Interv Radiol* 2010; 21:S204–S213.
9. Kothary N, Weintraub JL, Susman J, Rundback JH. Transarterial chemoembolization for primary hepatocellular carcinoma in patients at high risk. *J Vasc Interv Radiol* 2007; 18:1517–1526.
10. Llovet JM, Real MI, Montaña X, et al. Barcelona Liver Cancer Group. Arterial embolisation or chemoembolisation versus symptomatic treatment in patients with unresectable hepatocellular carcinoma: a randomised controlled trial. *Lancet* 2002; 359:1734–1739.
11. Brown DB, Nikolic B, Covey AM, et al. Quality improvement guidelines for transhepatic arterial chemoembolization, embolization, and chemotherapeutic infusion for hepatic malignancy. *J Vasc Interv Radiol* 2012; 23:287–294.
12. Lamm J, Malagari K, Vogl T, et al. PRECISION V Investigators. Prospective randomized study of doxorubicin-eluting-bead embolization in the treatment of hepatocellular carcinoma: results of the PRECISION V study. *Cardiovasc Intervent Radiol* 2010; 33:41–52.
13. Marelli L, Stigliano R, Triantos C, et al. Transarterial therapy for hepatocellular carcinoma: which technique is more effective? A systematic review of cohort and randomized studies. *Cardiovasc Intervent Radiol* 2007; 30:6–25.
14. Kim MY, Baik SK, Yea CJ, et al. Hepatic venous pressure gradient can predict the development of hepatocellular carcinoma and hyponatremia in decompensated alcoholic cirrhosis. *Eur J Gastroenterol Hepatol* 2009; 21:1241–1246.
15. Haskal ZJ, Martin L, Cardella JF, et al. Society of Interventional Radiology Standards of Practice Committee. Quality improvement guidelines for transjugular intrahepatic portosystemic shunts. *J Vasc Interv Radiol* 2003; 14:S265–S270.
16. Tesdal IK, Wikström M, Flechtenmacher C, Filser T, Duerber C. Percutaneous treatment of hepatocellular carcinoma in patients with

- transjugular intrahepatic portosystemic shunts. *Cardiovasc Intervent Radiol* 2006; 29:778–784.
17. Kang W, Kim JH, Ko GY, Gwon DI, Yoon HK, Sung KB. Transarterial chemoembolization for hepatocellular carcinoma after transjugular intrahepatic portosystemic shunt. *Acta Radiol* 2012; 53:545–550.
 18. Sakaguchi H, Uchida H, Maeda M, et al. Combined transjugular intrahepatic portosystemic shunt and segmental Lipiodol hepatic artery embolization for the treatment of esophagogastric varices and hepatocellular carcinoma in patients with cirrhosis: preliminary report. *Cardiovasc Intervent Radiol* 1995; 18:9–15.
 19. Tazawa J, Sakai Y, Yamane M, et al. Long-term observation after transjugular intrahepatic portosystemic stent-shunt in two patients with hepatocellular carcinoma. *J Clin Gastroenterol* 2000; 31:262–267.
 20. Nicolini A, Saccheri S, Lovaria A, et al. Prevention of variceal rebleeding and treatment of liver carcinoma by consecutive transjugular intrahepatic portosystemic shunt and hepatic artery chemoembolization. *Ital J Gastroenterol* 1996; 28:269–271.
 21. Ring EJ. The role of TIPS in variceal bleeding. *J Vasc Interv Radiol* 1997; 8:S108–S111.
 22. O'Neil BH, Venook AP. Hepatocellular carcinoma: the role of the North American GI Steering Committee Hepatobiliary Task Force and the advent of effective drug therapy. *Oncologist* 2007; 12:1425–1432.
 23. Llovet JM, Brú C, Bruix J. Prognosis of hepatocellular carcinoma: the BCLC staging classification. *Semin Liver Dis* 1999; 19:329–338.
 24. Bruix J, Llovet JM. Prognostic prediction and treatment strategy in hepatocellular carcinoma. *Hepatology* 2002; 35:519–524.
 25. Haskal ZJ, Carroll JW, Jacobs JE, et al. Sonography of transjugular intrahepatic portosystemic shunts: detection of elevated portosystemic gradients and loss of shunt function. *J Vasc Interv Radiol* 1997; 8:549–556.
 26. Feldstein VA, Patel MD, LaBerge JM. Transjugular intrahepatic portosystemic shunts: accuracy of Doppler US in determination of patency and detection of stenoses. *Radiology* 1996; 201:141–147.
 27. National Cancer Institute. Common Terminology Criteria for Adverse Events, version 4.03, June 14, 2010. Available at: http://ctep.cancer.gov/protocolDevelopment/electronic_applications/ctc.htm. Accessed March 30, 2012.
 28. Mingoli A, Modini C, Salvatori F, et al. Emergency transjugular intrahepatic portosystemic shunt in patients with active variceal bleeding and hepatocarcinoma. *Ital J Gastroenterol* 1995; 27:309–312.
 29. Serafini FM, Zwiebel B, Black TJ, Carey LC, Rosemurgy AS. Transjugular intrahepatic portosystemic stent shunt in the treatment of variceal bleeding in hepatocellular cancer. *Dig Dis Sci* 1997; 42:59–65.
 30. Tazawa J, Sakai Y, Yamane M, et al. Long-term observation after transjugular intrahepatic portosystemic stent-shunt in two patients with hepatocellular carcinoma. *J Clin Gastroenterol* 2000; 31:262–267.