

UC Office of the President

Recent Work

Title

Dental Laser Applications: Periodontal Treatment and Intra-Oral Surgery

Permalink

<https://escholarship.org/uc/item/63n4m9xs>

Author

Wilder-Smith, PE

Publication Date

2002

Copyright Information

This work is made available under the terms of a Creative Commons Attribution License, available at <https://creativecommons.org/licenses/by/4.0/>

Peer reviewed

III-3

Dental Laser Applications: Periodontal Treatment and Intra-Oral Surgery

Petra Wilder-Smith

Contents

Extended Summary	317
Indication	317
Criteria for Exclusion	318
Comparison with Alternative Methods	318
Haemostasis	318
Surface Lesions	319
Excision and Biopsy	319
Implant Exposure	319
Frenectomy	319
Preprosthetic Surgery	319
Gingivectomy and Gingivoplasty	320
Patients with Haemorrhagic Disorders	320
Effects on Collateral Structures and Wound Healing	320
Results	321
Discussion	321
References	322

Extended Summary

One of the greatest advantages of laser use is a high rate of patient acceptance. Patients expect reduced intra-operative and postoperative discomfort and improved treatment speed and outcome from laser procedures. When used for suitable applications with appropriate techniques, lasers can indeed provide these advantages. Particularly in the field of soft tissue surgery, lasers can offer substantial advantages over conventional techniques for procedures such as frenectomy, gingivectomy, gingivoplasty, ablation of pathological lesions, incisional and excisional biopsy, soft tissue tuberosity reductions, operculum removal, coagulation of graft donor sites and crown-lengthening procedures. The strong absorption of radiation from the argon laser in pigmented tissues permits excellent haemostasis and selective destruction of lesions which have a large vascular component, such as haemangiomas, telangiectasias, epulides, haemorrhagic gingival hyperplasias and granulomas containing a large blood component, while sparing superficial non-pigmented structures from damage.

Use of lasers for periodontal and intra-oral soft tissue surgery is significantly restricted by two factors. The first is the extreme thermal sensitivity of intra-oral structures such as the dental pulp and bone, which precludes application of laser techniques in close proximity to these structures. The second is the still significant cost of laser systems. Although the cost/benefit ratio of such technology may be acceptable in multi-user or specialized practices, it may not be appropriate for surgeries devoting a lesser portion of their time to laser-related procedures.

Indication

In approaching the concept of laser use for periodontal and intra-oral soft tissue surgery, laser efficacy for achieving any specific treatment goal, as well as the clinical acceptability of the side effects of the laser use must be considered.

In many respects, laser properties are ideally suited to soft tissue surgery in the oral cavity: characteristics such as surgical precision and efficacy, haemostasis, bacterial elimination, minimal postoperative scarring, reduced postoperative pain and swelling provide many advantages over conventional surgical techniques. The thin, flexible fibre or waveguide delivery systems currently available on most clinical lasers allow easy access to all areas of the mouth. Specially configured laser tips, ranging from very fine for excellent surgical precision, to wide for rapid ablation of large surfaces, and including curved or side-firing designs, are available for ensuring optimal surgical access, control and outcome.

Many areas of routine CO₂ and, to a lesser extent, argon or Nd:YAG laser applications for soft tissue surgery have developed over the past 30 years. Typical applications include haemostasis and treatment of patients with haemorrhagic disorders, ablation of pathological lesions, incisional and excisional biopsies, coagulation of graft donor sites, implant exposure, frenectomies, preprosthetic surgery, soft tissue tuberosity reductions, gingivectomies, gingivoplasties, crown-lengthening procedures and operculum removal.

In almost all intra-oral soft tissue surgery, the minimal penetration depth of CO₂ laser irradiation into the tissues proves very advantageous. Rapid, effective surgical performance with effective haemostasis and minimal involvement of adjacent and underlying structures is achieved. Typically, a short burst of CO₂ laser light is absorbed within the first 0.3 mm of soft tissue, and thermal effects in collateral soft tissues extend 15–300 µm, depending on the laser configuration used.

The strong absorption of radiation from the argon laser in pigmented tissues achieves excellent haemostasis and selective destruction of lesions which have a large vascular component, such as haemangiomas, telangiectasias, epulides, haemorrhagic gingival hyperplasias and granulomas containing a large blood component, while sparing superficial non-pigmented structures from damage. Irradiation from the argon laser is absorbed within the first 1–2 mm of soft tissue, and collateral tissue effects are slightly greater than those produced by the CO₂ laser.

Lasers emitting at wavelengths with lower tissue absorption and significant optical scattering, such as the Nd:YAG laser, or some of the semiconductor or diode systems now available, will tend to impact underlying and adjacent structures to a greater extent than CO₂ or argon lasers, although collateral effects can to a certain extent be mitigated by use of appropriate tips and cooling.

Criteria for Exclusion

Because lasers used for soft tissue surgery achieve their effects mainly through thermal mechanisms, tissues lying under or adjacent to the surgical site will experience greater or lesser degrees of thermal alteration or damage. Thus, laser procedures must be performed with caution in proximity to heat-sensitive structures. This is particularly relevant in the oral cavity. The periodontal tissues overlying bony structures are extremely thin and tightly bound in some areas of the mouth. A temperature increase of as little as 10 °C can cause osseous necrosis. The cutting effects of surgical lasers are achieved at temperatures exceeding 100 °C, necessitating extreme caution when working with a laser in thin oral soft tissues with close proximity to bone. In the enclosed environment of the periodontal pocket, laser-generated heat is retained. Here, also, exists the potential for thermal damage to bony periodontal structures. Additionally, transmission of laser energy through the dentinal tubules directly to the pulpal tissues can threaten pulpal vitality. A temperature rise as small as 5.5 °C can cause pulpal necrosis.

The Nd:YAG and the Er:YAG laser have been proposed for calculus ablation and smear layer removal after conventional root planing procedures. Although root cleaning can be achieved, effects are usually patchy, with areas of inadequate cleansing and zones of thermal damage [1, 2]. Laser-induced char layers prevent connective tissue and/or epithelial reattachment [3]. These limitations, as well as concerns regarding the achievement of complete bacterial elimination, in order to avoid bacterial repopulation and re-infection of adjacent tissues, speak against the use of laser techniques as an alternative or adjunct to conventional root planing procedures [4–7]. Moreover, a post-irradiation decrease in protein/mineral ratio and surface alterations seems to render irradiated root surfaces potentially unfavourable for fibroblast attachment [8, 9].

Caution is necessary when working in proximity to metal dental restorations, due to the danger of oral or ocular damage from reflected laser light [10].

Comparison with Alternative Methods

Haemostasis

One of the great advantages of laser surgery is the establishment of excellent operative visibility due to a relatively blood-free surgical field. Moreover, coagulation of bleeding areas or of soft tissue graft donor sites is extremely effective. Postoperative bleeding from a donor site after soft tissue grafting poses a ma-

major challenge to dental clinicians. Once laser coagulation is achieved, chances for postoperative bleeding are minimal. For active bleeding sites, argon, Nd:YAG and Ho:YAG are the lasers of choice. In non-bleeding areas, to prevent subsequent bleeding, nearly all lasers are applicable. To coagulate an actively bleeding site with a CO₂ laser, bleeding must first be momentarily stopped, usually by pressure or administration of additional local anaesthetic.

Surface Lesions

Removal of oral lesions by application of laser energy is readily achieved for surface exophytic and invasive lesions. Rapid removal of surface lesions is easily achieved using an unfocused beam of relatively large diameter (1 cm or more). Applications of this sort include ablation of a wide range of white lesions (once a biopsy has been taken and a diagnosis established), especially of the buccal mucosa, palate and floor of the mouth. In our experience, the CO₂ laser is well suited to these applications because of its ability to ablate tissue rapidly in the unfocused mode with minimal underlying tissue damage.

Symptomatic relief of aphthous ulcers and herpetic lesions can be achieved using the laser in the defocused mode. Here, goal of the laser therapy is to remove necrotic material from the lesion surface, disinfect the remaining wound and create a conservative laser wound which will heal more quickly, with less discomfort and fewer complications than the original lesion. As these lesions usually occur on the lip, potential laser effects on underlying bone are not a concern, and a wide range of lasers including argon, CO₂ and Nd:YAG have been successfully used for this application. It should be noted that appropriate precautions should be employed when applying laser treatment to herpetic lesions since the herpes virus and verruca virus may be transmitted via the laser plume.

Excision and Biopsy

Precise biopsy or excision of exophytic, invasive or other lesions is achieved using a focused beam with a minimal diameter where the surgical technique is similar to that used with a scalpel. The depth of penetration of the incision made by the focused laser beam or contact tip will vary with the power density used and the speed of movement of the laser across the surgical site. In most instances, sutures are not necessary and the laser wound is left to heal by secondary intention.

Some authors have hypothesized minimization of seeding and metastasis from malignant lesions dur-

ing surgery by using laser techniques to seal blood vessels and lymphatics related to the lesion. Animal studies and a small number of clinical investigations appear to confirm this concept [11]. Conversely, recent investigations in animals have raised concerns about promotion of malignant transformation in potentially pre-malignant leukoplakic lesions by CO₂ laser incision [12].

On the tongue conventional biopsies or excisional procedures tend to cause immediate and copious bleeding, significantly hindering the surgical process. Lesions on the tongue can be removed almost bloodlessly using the CO₂ laser, and most often without the need for sutures.

Implant Exposure

Exposure of single or multiple fixture implants is readily performed using the laser by simple vaporization of the tissue overlying the implant until the surgical healing cap is reached. This is usually best accomplished in the defocused mode, often eliminating the need for a flap and suturing, and reducing the level of postoperative discomfort. Where there is a need for apically positioning a flap, or for uncovering implants within osseous structures, or where regeneration or augmentation materials have been used, conventional flap procedures may be indicated.

Frenectomy

Goal of frenectomy is to release attachment with minimal damage to surrounding tissues, and particularly the CO₂ and argon laser provide enormous advantages over conventional scalpel surgery, including very rapid, efficient tissue removal with a bloodless field. As with most laser procedures, sutures are usually not needed – which can be difficult and uncomfortable to place and remove in the mobile non-keratinized oral mucosa – and the patient experiences minimal discomfort during the healing period.

Preprosthetic Surgery

Conventional surgical techniques for preprosthetic surgical needs such as removal of inflammatory hyperplasia, epulides, for tuberosity reduction or vestibular deepening procedures commonly cause extensive bleeding, limiting intra-operative visibility and requiring suturing. Significant postoperative pain results, and grafting may become necessary to cover the wound. Wound contraction after healing may compromise the surgical result. The laser provides

good surgical access and precision, haemostasis during and after the procedure, speed, minimal scarring and wound contraction, minimal or absent postoperative pain as well as near-normal colour and texture of the wound. Suturing is rarely needed, so that the normal anatomical contour is preserved.

Gingivectomy and Gingivoplasty

If thermal or direct damage to underlying bone and tooth substance is avoided by judicious case and wavelength selection, gingivectomy and gingivoplasty can advantageously be accomplished using the laser. Tissue overgrowth, pseudopockets or hyperplasias resulting from disease, drug therapy such as phenytoin, cyclosporine, nifedipine and others, orthodontic treatment or congenital conditions are precisely and rapidly removed. Intra-operative haemostasis and reduced postoperative pain are further advantages of laser use over conventional techniques for this type of application, where because of its minimal penetration depth in soft tissue (thus minimally impacting underlying bone and tooth structures) and its speed, the CO₂ laser is particularly advantageous. In some cases, tooth protection can be achieved by shielding with a device such as a periosteal elevator. Near the tooth margins, the beam should be used in the focused mode to precisely contour the gingival margin and to permit optimal control of laser beam impingement on target and adjacent tissues. Distant from the gingival margin, the beam is used in the defocused mode to ablate and vaporize excess tissue. Particularly for

mentally handicapped patients, the laser offers enormous advantages over conventional treatment options, due to the speed of treatment, and greatly reduced postoperative bleeding and pain.

Patients with Haemorrhagic Disorders

Patients with disorders such as haemophilia, Sturge-Weber syndrome and idiopathic thrombocytopenic purpura can be effectively treated for intra-oral lesions using the laser, as they lose minimal amounts of blood intra-operatively due to the coagulative effects of lasers. These patients should, however, still be cross-matched for blood to cover all contingencies.

Effects on Collateral Structures and Wound Healing

Obviously, scalpels cause no collateral thermal damage. Lasers tend to cause less thermal damage in adjacent or underlying tissues than electrocautery, whereby the amount of collateral damage caused depends on the laser wavelength and laser pulse regimens used, as well as coolant and surgical technique. The amount of tissue destroyed adjacent to a laser incision is of considerable importance in determining the rate and quality of wound healing. Using a CO₂ laser with extremely short pulses and high peak powers, collateral thermal damage in oral soft tissues ranged from 15–170 µm (Figs. 1–3) [13]. The ability to predict and control collateral effects of laser use are of prime importance in ensuring good treatment out-

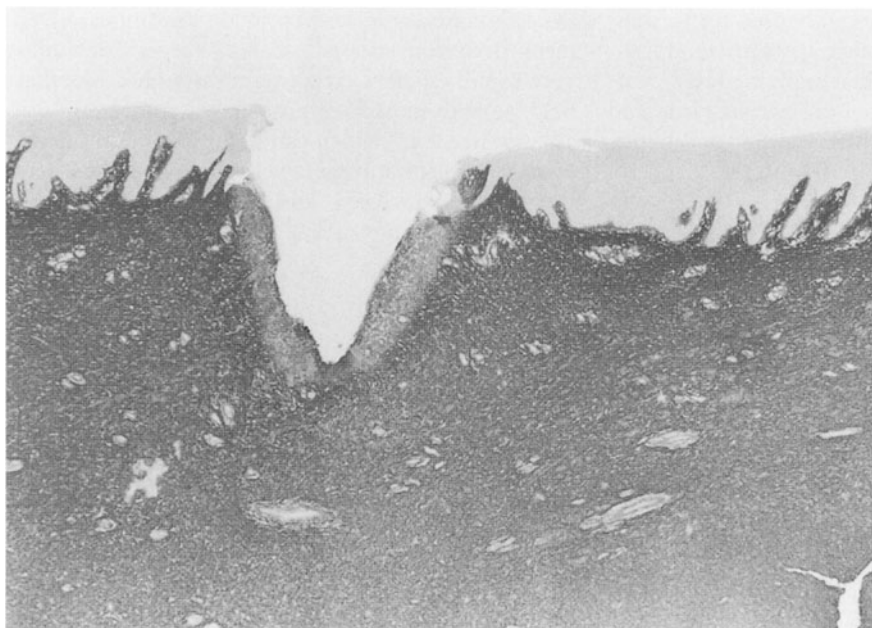


Fig. 1. Typical incision profile in oral soft tissue using a CO₂ laser at 9W average and peak power, continuous wave mode and 40 Hz. Incision is deep and wide, and collateral damage is relatively great

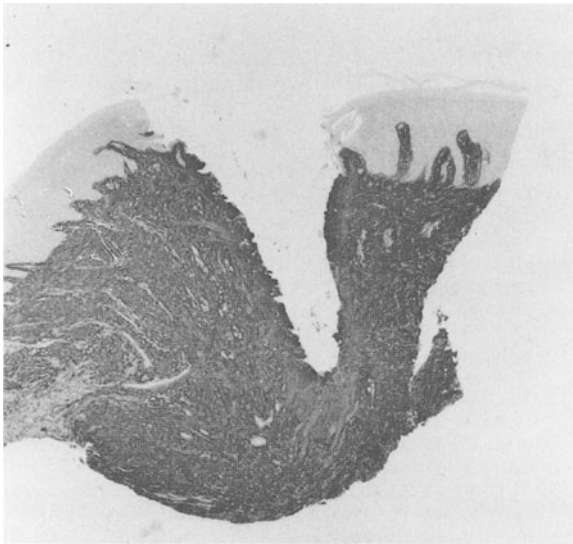

Fig. 2. Typical incision profile in oral soft tissue using a CO₂ laser at 3 W average power, 20 W peak power, 300 μs pulse duration and 1100 Hz. Incision is deep and narrow, and collateral damage is moderate

come and avoiding damage to adjacent structures. Moreover, a thick layer of thermal damage at the margins of a wound will tend to delay healing and weaken wound cohesive strength.

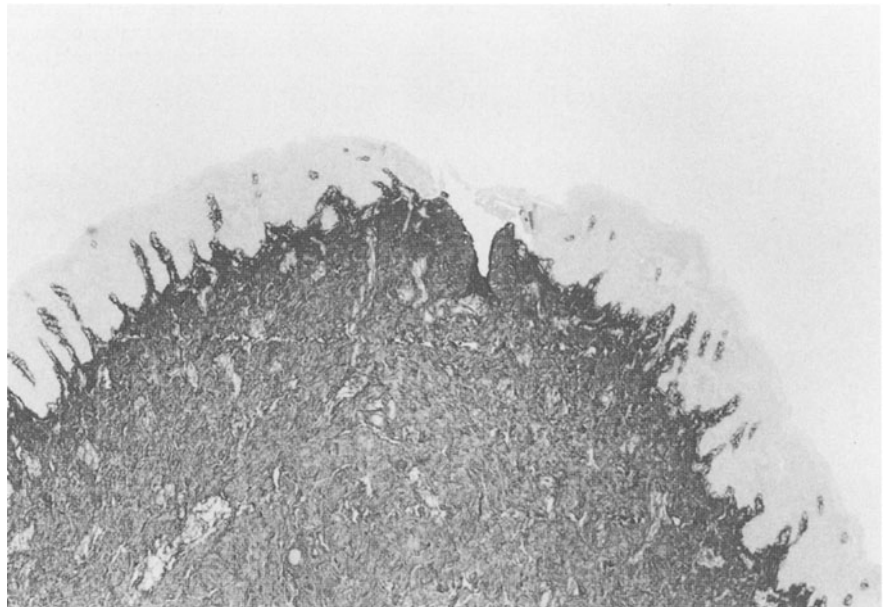
Laser wounds heal in a fashion similar to scalpel wounds. Although initial healing appears to be slightly delayed, wound contraction and scar formation are reduced, leading to an improved cosmetic result.

Results

Accumulated clinical and research experience over the past 30 years by clinicians and researchers pertaining to laser use in dentistry has clearly demonstrated many advantages of laser surgery, as well as clear and imperative contraindications. Applications where laser use provides many advantages over conventional techniques include haemostasis and treatment of patients with haemorrhagic disorders, removal of soft tissue surface lesions, excision and biopsy, implant exposure, frenectomy, preprosthetic surgery, gingivectomy and gingivoplasty.

Because lasers used for soft tissue surgery achieve their effects mainly through thermal mechanisms, tissues lying under or adjacent to the surgical site will experience greater or lesser degrees of thermal alteration or damage. Thus, laser procedures must be performed with caution in proximity to heat-sensitive structures, specifically to avoid damage to osseous and dental/pulpal structures.

Fig. 3. Typical incision profile in oral soft tissue using a CO₂ laser at 1 W average power, 100 W peak power, 300 μs pulse duration and 10 Hz. Incision is shallow and narrow, and collateral damage is minimal



Discussion

In approaching this topic, an unusual combination of excitement and reluctance is generated: excitement at the true potential that lasers have for improving on many conventional techniques in oral soft tissue surgery; reluctance because lasers need to be used in an informed and appropriate fashion to avoid the very real potential for negative side effects in our patients. Moreover, with a relatively costly, high-tech device such as a laser system, the temptation to convert this modality into a universal panacea is great – and inappropriate.

Thus, dental clinicians are encouraged to maximize the great, beneficial potential of laser soft tissue surgery for the welfare of their patients by developing a thorough understanding of basic laser mechanisms and by obtaining good, clinical instruction in all the laser techniques and systems they wish to use.

References

- [1] WILDER-SMITH P, ARRASTIA AM, LIAW L-H, GRILL G, BERNIS MW (1995) Thermal and microstructural effects of Nd:YAG laser irradiation and root planing on root surface. *J Periodontol* 66: 1032–1039
- [2] SCHILKE R, GEURTSSEN W (1994) REM Analyse von Zahnoberflaechen nach Bearbeitung mit einem Er:YAG Laser. *Dtsch Zahnarzt Z* 49: 160–162
- [3] GOPIN BW, COBB CM, RapGley JW, KILLOY WJ (1997) Histologic evaluation of soft tissue attachment to CO₂ laser-treated root surfaces: an in vivo study. *Int J Periodont Restor Dent*, in press
- [4] MORLOCK BJ, PIPPIN DJ, COBB CM, KILLOY WJ, RAPLEY JW (1992) The effect of Nd:YAG laser exposure on root surfaces when used as an adjunct to root planing: an in vitro study. *J Periodontol* 63: 637–641
- [5] THOMAS D, COBB C, RAPLEY J, SPENCER P, KILLOY WJ (1994) Effects of the Nd:YAG laser and combined treatments on in vitro fibroblast attachment to root surfaces. *J Clin Periodontol* 21: 38–44
- [6] TUCKER D, RAPLEY JW, COBB CM, KILLOY WJ (1996) Morphologic changes following in vitro CO₂ laser treatment of calculus laden root surfaces. *Lasers Surg Med* 18: 150–156
- [7] COFFELT DW, COBB CM, MACNEILL S, RAPLEY JW, KILLOY WJ (1997) Determination of energy density threshold for laser ablation of bacteria: an in vitro study. *J Clin Periodontol* 24: 1–7
- [8] SPENCER P, TRYLOVICH DJ, COBB CM (1992). Chemical characterization of lased root surface using Fourier transform infrared photoacoustic spectroscopy. *J Periodontol* 63: 633–636
- [9] TRYLOVICH DJ, COBB CM, PIPPIN DJ, SPENCER P, KILLOY WJ (1992) The effects of the Nd:YAG laser on in vitro fibroblast attachment to endotoxin-treated root surfaces. *J Periodontol* 63: 626–632
- [10] SIEVERS M, FRENTZEN M, KOORT HJ (1994) Reflexion infraroter CO₂ Laserstrahlung an Fuellungswerkstoffen. *ZWR* 103: 288–290
- [11] PICK R, POGREL A, LOH HS (1995) Clinical applications of the CO₂ laser . In: MISERENDINO L, PICK R (eds) *Lasers in dentistry*. Quintessenz, Chicago, pp 145–160
- [12] IIDA K, KATO M, YOSHIDA K, KuritGa K, TATEMATSU M (1999) Promotional effects of CO₂ laser on DMBA-induced buccal cheek pouch carcinogenesis. *Laser Surg Med* 24: 360–367
- [13] WILDER-SMITH P, DANG J, KUROSAKI T (1997) Investigating the range of surgical effects on soft tissue produced by a carbon dioxide laser. *JADA* 128: 583–588