

UC Davis

Dermatology Online Journal

Title

Getting to the point: a case of a sewing needle retrieved from the thigh

Permalink

<https://escholarship.org/uc/item/64t4z1fk>

Journal

Dermatology Online Journal, 20(1)

Authors

Brezinski, Elizabeth A
Eisen, Daniel B
Burrall, Barbara

Publication Date

2014

DOI

10.5070/D3201021254

Copyright Information

Copyright 2014 by the author(s). This work is made available under the terms of a Creative Commons Attribution-NonCommercial-NoDerivatives License, available at <https://creativecommons.org/licenses/by-nc-nd/4.0/>

Peer reviewed

Case Presentation

Getting to the point: a case of a sewing needle retrieved from the thigh

Elizabeth A Brezinski BA, Daniel B Eisen MD, Barbara Burrall MD

Dermatology Online Journal 20 (1): 13

University of California, Davis, Department of Dermatology

Correspondence:

Barbara Burrall, MD
3301 C Street, Suite 1400
Sacramento, CA 95816
Email: Barbara.Burrall@ucdmc.ucdavis.edu

Abstract

Foreign bodies are rarely retained in the skin after puncture wounds or impalement injuries and are even less commonly initially detected several months after penetration. Sewing needles are most frequently reported in the literature as foreign bodies in cases of ingestion, inoculation of the cranium and heart, and penetration of the knee. Herein we describe a case of a middle-aged man who presented to the outpatient dermatology clinic with an 8-month history of a nodule in his left thigh; he had noted recent onset of mild pain. On examination he was found to have a sharp needle-like point palpable below the skin of his left lateral thigh. Plain radiographs of the left thigh showed a fractured sewing needle overlying the same area. During local incision, two fragments of a sewing needle were removed from the lateral thigh.

Key Words: Foreign body, sewing needle, plain radiography

Introduction

Penetrating trauma with metallic objects may result in retained foreign bodies in either whole or fragmented forms. Sewing needles have been discovered in various anatomic locations including the gastrointestinal tract, cranium, and heart after ingestion, traumatic placement, or impalement. One case report described an infant who presented with a painful linear inflammatory skin eruption of the forearm from a sewing needle introduced over 17 months prior to its extraction [1]. Early identification and excision of a metallic foreign body is necessary to prevent the development of complications such as infection or foreign-body granuloma formation. Various imaging modalities exist for localizing metallic foreign bodies that are not adequately visible on exam. We report a case of an inadvertent penetrating needle injury that went unrecognized by the patient for many months before it was finally identified.

Case synopsis

A 47-year-old man presented to the University of California Davis dermatology clinic for evaluation of a firm nodule within the left lateral thigh. Although the nodule had been present for 8 months, he only recently developed mild pain in the area and decided to seek consultation for possible thrombosis. Upon interview, the patient reported that the skin lump was the result of an injury while performing a back bend during a floor game (Twister) at a party. However, retrospectively he was able to recall sewing up his pants pocket 8 months prior to presentation. He arose from his workspace on the couch and returned later to find the sewing needle missing. On exam, a sharp needle-like object was easily palpated through the skin in the lateral thigh and with further manipulation, projected out of the skin and pricked the examining physician (**Figure 1**). A plain radiograph of the left thigh was obtained to further evaluate for a foreign body and the patient was found to have a fractured needle located in the subcutaneous plane of the lateral thigh (**Figure 2**).

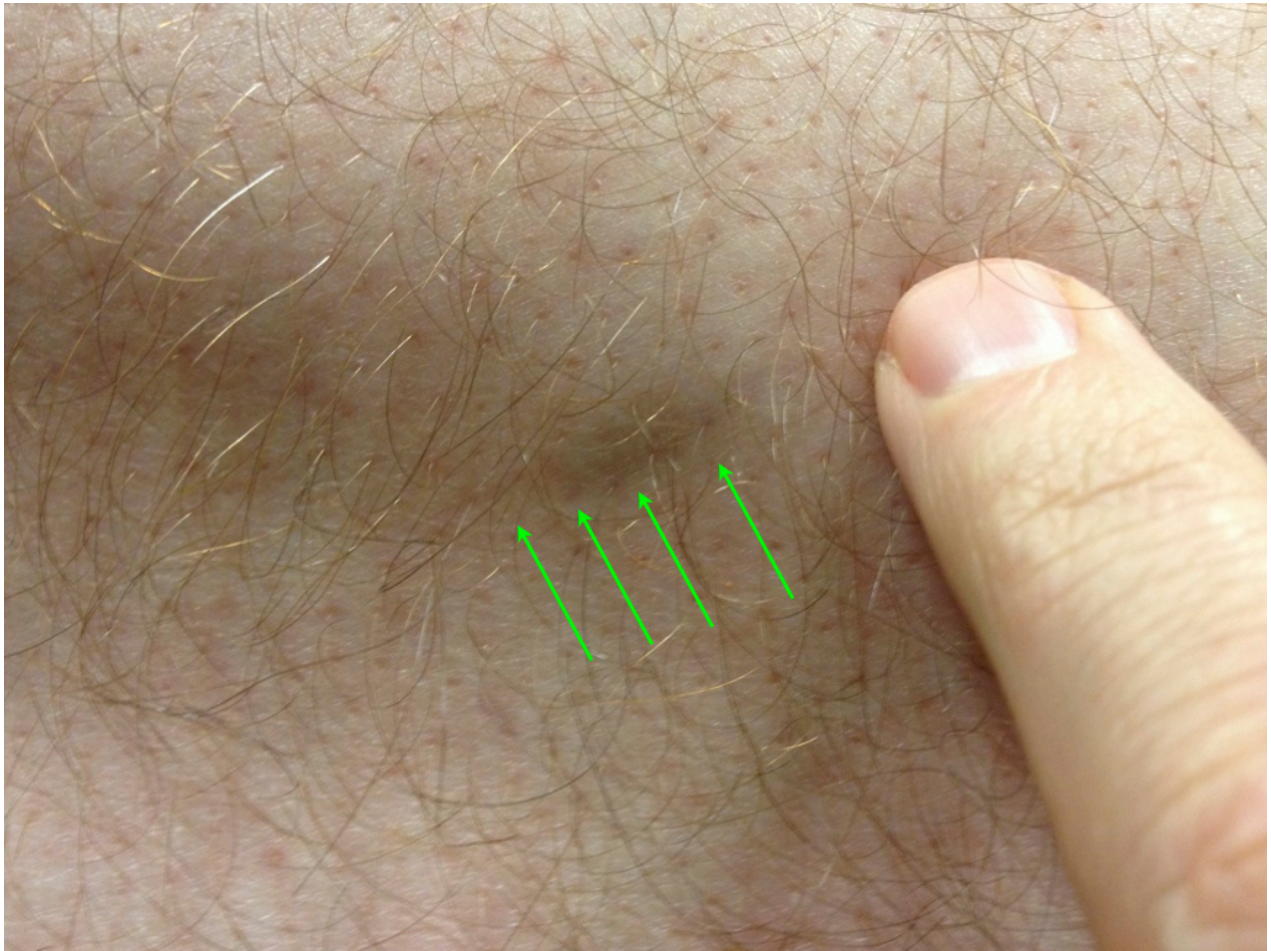

Figure 1. Sewing needle palpable below the skin

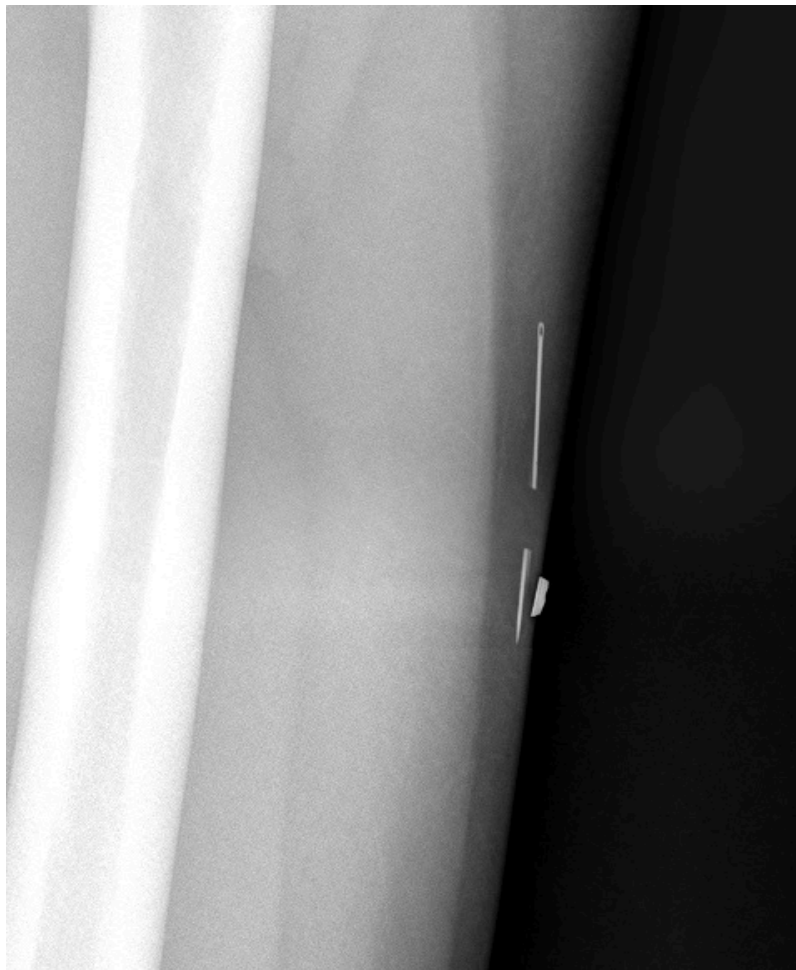

Figure 2. Lateral radiograph of the left thigh. Lead marker over skin where the foreign body was detected by palpation

Under local anesthesia, a small linear partial thickness skin incision was made and the two segments of the sewing needle were extracted with a needle driver (**Figure 3**). The specimen was submitted for histopathologic examination, which confirmed two fragments of a needle (**Figure 4**).

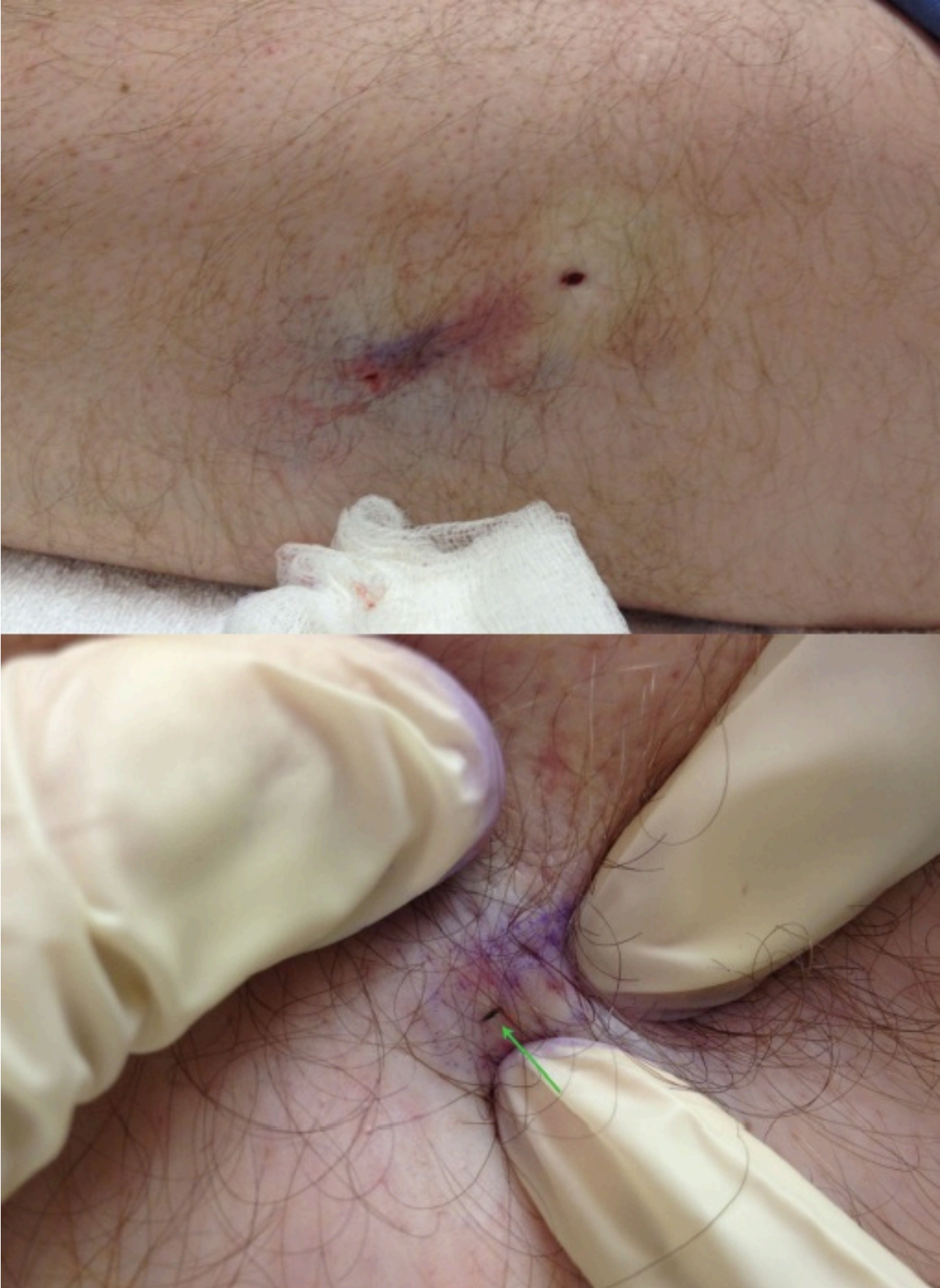

Figure 3. Exposure of the fractured needle through the skin during surgical removal




Figure 4. Fractured sewing needle after retrieval with a needle driver

Discussion

Early case reports of sewing needles incidentally found after penetration into the soft tissues of the extremities include needles retained at the site of foot trauma and a case of a sewing needle that had migrated to the heart from the upper arm over a period of two weeks [2, 3]. Since then, sewing needle foreign bodies have been described in case reports related to ingestion, deliberate

placement, and impalement. The incidental finding of a sewing needle in the subcutaneous tissue several months after the time of inoculation is not often reported in the adult dermatologic literature.

Puncture wounds with metallic foreign bodies may result in retained skin and soft tissue fragments that can be further identified by various imaging modalities including plain radiographs, xerography, computed tomography, and ultrasonography [4]. The use of a magnet to localize and extract metallic foreign body fragments is a novel technique that has been reported in the literature [5, 6]. In our case, the needle was found to have fractured into two pieces that were not distinguishable by palpation. Foreign bodies that are the result of old injuries are often difficult to differentiate on exam owing to scarring or granulomatous tissue deposition. Plain radiography was the appropriate imaging modality to detect the placement of this retained metallic instrument. Retrieval of the sewing needle was warranted in this case to prevent the foreign body from serving as a nidus for infection or foreign-body granuloma. In addition, migration to vital organs is a hazard that can be prevented by removal [2, 7].

References

1. Al-Jasmi F, Al-Khenaizan S. Cutaneous foreign bodies: elusive presentation. Case report and review of the literature. *Int J Dermatol* 2002 May; 41(5): 293-5. [PMID:12100709]
2. Yu J, Cheng K. Migration of broken sewing needle from left arm to heart. *Chest* 1975 May; 67(5): 626-7. [PMID:1126214]
3. Popkin G, Brodie S. The wandering sewing needle. Report of a case. *Arch Dermatol* 1964 Jun; 89: 821-2. [PMID:14164966]
4. Ginsburg M, Ellis G, Flom L. Detection of soft-tissue foreign bodies by plain radiography, xerography, computed tomography, and ultrasonography. *Ann Emerg Med* 1990 Jun; 19(6): 701-3. [PMID:2188542]
5. Aldrich N, Brodell R. Confirmation of Cutaneous Metallic Foreign Bodies with a Magnet. *Arch Dermatol* 2011 May; 147(5): 623-4. [PMID:21576588]
6. Chin J, Davies S, Sandler JP. Retrieval of a metallic foreign body in the neck with a rare earth magnet. *J Accid Emerg Med* 2000 Sept; 17(15): 383-4. [PMID:11005421]
7. Nishimoto Y, Suita S, Taguchi T, Noguchi S, Jeiri S. Hepatic foreign body - a sewing needle - in a child. *Asian J Surg* 2003 Oct; 26(4): 231-3. [PMID:14530112]