

UCSF

UC San Francisco Previously Published Works

Title

Daratumumab-induced transient myopic shift.

Permalink

<https://escholarship.org/uc/item/6563105h>

Authors

Mavrommatis, Maria

Jung, Hoon

Chari, Ajai

et al.


Publication Date

2019-03-01

DOI

10.1016/j.ajoc.2018.12.017

Peer reviewed



Case report

Daratumumab-induced transient myopic shift

Maria A. Mavrommatis^{a,*}, Hoon Jung^b, Ajai Chari^c, Bart Barlogie^c, James G. Chelnis^d^a Icahn School of Medicine at Mount Sinai, 1468 Madison Ave, New York, NY, 10029, USA^b Department of Ophthalmology, University of Washington, Box 259608 325 Ninth Avenue, Seattle, WA, 98104, USA^c Department of Hematology-Oncology, Mount Sinai Medical Center, 1468 Madison Ave, New York, NY, 10029, USA^d Department of Ophthalmology, Mount Sinai Medical Center, 1468 Madison Ave, New York, NY, 10029, USA

ARTICLE INFO

Keywords:

Transient myopia
Myopic shift
Multiple myeloma
Daratumumab

ABSTRACT

Purpose: To describe an unprecedented case of transient myopic shift induced by a chemotherapeutic agent, daratumumab.

Observations: A 43-year-old emmetropic female with multiple myeloma experienced sudden onset of myopic shift during her first intravenous dose of daratumumab, an increasingly common FDA-approved chemotherapeutic agent. Her myopia was corrected with -4D lenses in both eyes, and the patient reports cessation of symptoms and disuse of lenses after two days.

Conclusions and importance: A number of medications have been documented to induce transitory myopic shift, and this report now includes daratumumab among such agents. Further clinical findings regarding the mechanism and frequency of daratumumab-induced myopic shift are needed to further develop our understanding of its tangential effect on the eye.

1. Introduction

Sudden onset of transient myopia is a rare consequence of both systemic and topical use of certain medications, including topiramate, chlorthalidone, sulfonamides, and isotretinoin.^{1–5} This case study describes a unique case of drug-induced transient myopia in a patient being treated with daratumumab (Darzalex), an increasingly common medication for patients with multiple myeloma.⁶

2. Case report

A 43-year old female with a history of multiple myeloma presented to the clinic with sudden onset of symmetrical decrease in distance uncorrected visual acuity (UCVA). She had received her first dose of single-agent intravenous daratumumab, an increasingly common FDA-approved chemotherapy drug for multiple myeloma, the day before her visit at the maximum infusion rate of 200ml/hr with continuous blood glucose monitoring.⁶ The patient reported dizziness, mild blurred vision, and headache during the infusion without any significant change in blood glucose. She noticed an improvement in her headache, but a persistence of blurred vision, after pausing the infusion for 3 hours. Daratumumab was then continued at 50ml/hr for 30 minutes, and the patient returned home after completion of the infusion in no apparent

distress. She indicates that the blurred vision continued through her second dose of daratumumab at an infusion rate of 100 ml/hr, which was delivered the morning afterward, only hours before she presented to the clinic for an ophthalmologic evaluation. Daratumumab was discontinued for the next week, with plans to resume in the future.

Daratumumab was the patient's only new medication at the time. In addition to the chemotherapy, chronic medication use included cyanocobalamin, turmeric, acetylcarnitine, acyclovir, sertraline hydrochloride, ondansetron, cholecalciferol, and B complex vitamins. The patient was not pregnant, nor diabetic. Upon evaluation, the patient's distance UCVA was 20/400 in the right eye and 20/200 in the left. Best corrected visual acuity (BCVA) of 20/25 in the right eye and 20/20 in the left was achieved with -4.00D sphere in each eye. The patient has never worn glasses or contacts in the past, and instructions on contact lens use was provided. Intraocular pressure was within normal limits (15 mmHg OD, 16 mmHg OS), and examination was significant for anterior chambers of moderate depth. Temporary refractive correction with -3.75D spherical soft contact lenses was prescribed with instructions to return immediately with symptoms of worsening vision, eye pain or redness.

At six-day follow up visit, the patient reported progressive improvement in UCVA over three days and had stopped contact lens use after two days due to noticeably improved vision. An anterior segment

* Corresponding author.

E-mail addresses: maria.mavrommatis@icahn.mssm.edu (M.A. Mavrommatis), hoon.jung.md@gmail.com (H. Jung), ajai.chari@mountsinai.org (A. Chari), bart.barlogie@mssm.edu (B. Barlogie), james.chelnis@mssm.edu (J.G. Chelnis).

<https://doi.org/10.1016/j.ajoc.2018.12.017>

Received 6 June 2018; Received in revised form 19 November 2018; Accepted 17 December 2018

Available online 18 December 2018

2451-9936/ © 2018 Published by Elsevier Inc. This is an open access article under the CC BY-NC-ND license (<http://creativecommons.org/licenses/by-nc-nd/4.0/>).

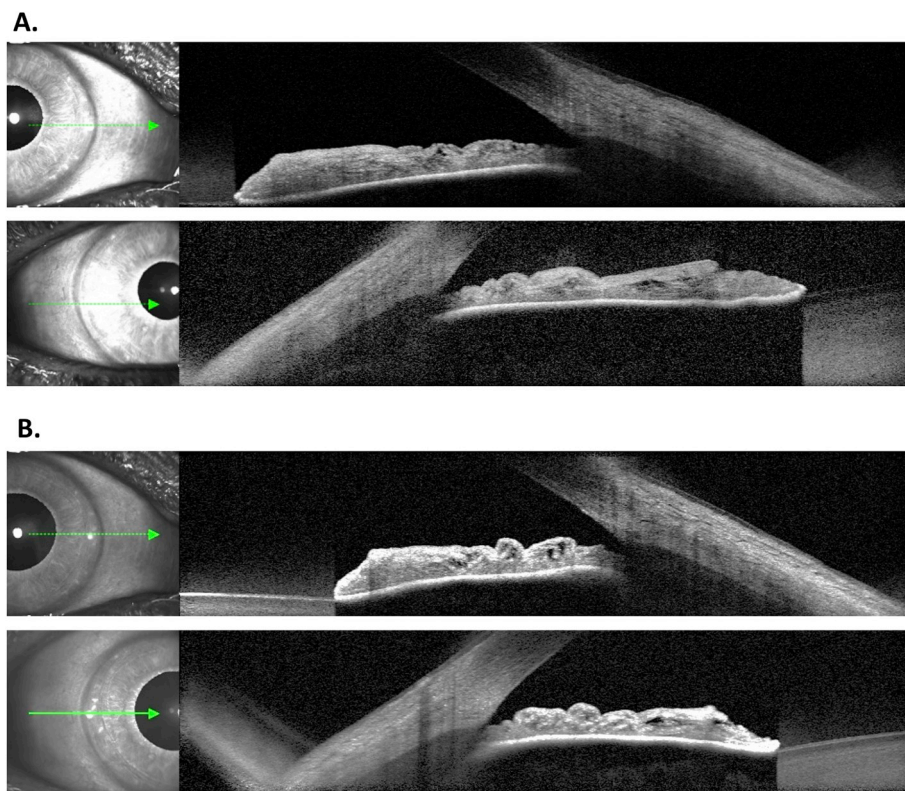


Fig. 1. Anterior segment OCT of the patient's right (panel A) and left (panel B) eyes showing normal angles and positions of the iris.

optical coherence tomography (OCT) scan showed an open angle with normal physiological position of the iris in both eyes (Fig. 1A and B, respectively). Ultrasound biomicroscopy (UBM) allowed visualization of the ciliary body and lens-diaphragm complex without effusion or mass. The angle was measured as 24.0° in the right eye at T7 and 35.5° in the left at T8 (Fig. 2A and B, respectively). Due to instrument unavailability, neither UBM nor OCT was performed at the initial time of myopic shift.

3. Discussion

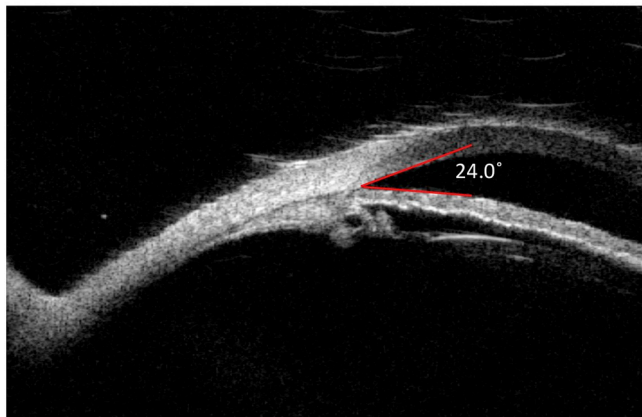
Idiosyncratic drug complications resulting in transient myopia are well described. An array of case reports document systemic medications associated with transient myopic shift including topiramate, chlorthalidone, sulfonamides, and isotretinoin, but chemotherapy agents are currently absent from this list.^{2–5} Mechanistically, different sources have been identified, such as forward movement of the ciliary body-lens complex due to effusion or mass effect, changes in the corneal refractive surface, and changes in the lens hydration status. Acute attention to

clinical history and use of adjunct imaging can help delineate amongst the various causes. One limitation of our report is the lack of UBM or OCT at the time of the patient's presentation with myopic shift. We recommend these modalities to confirm any suspicion of drug-induced myopic shift. As newer medications continue to be developed, sustained reporting of potential causative agents and their unanticipated side effects remains the predominant source of increasing awareness in the clinical arena.

4. Conclusion

The case presented here documents a previously undescribed immediate complication of daratumumab, an increasingly common multiple myeloma treatment. While the symptoms in this case were self-limiting, the ocular side effects of daratumumab necessitate further study at large, and in particular to characterize their potential to produce myopic shift.

A.



B.

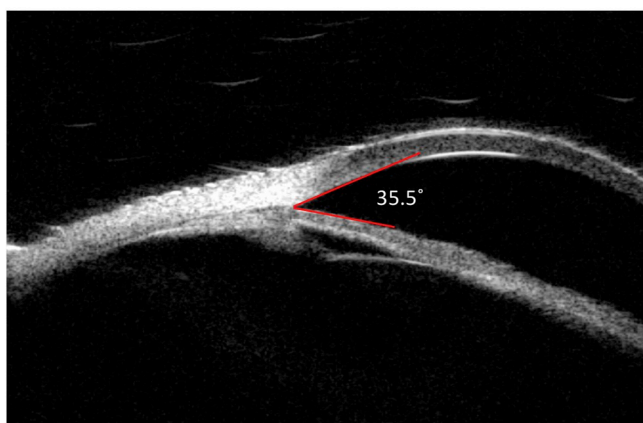


Fig. 2. UBM of the patient's right eye at T7 (panel A) and left eye at T8 (panel B) showing ciliary bodies and lens-diaphragm complexes without effusion or mass.

Patient consent

Consent to publish the case report was not obtained. This report does not contain any personal information that could lead to the identification of the patient.

Funding

No funding or grant support.

Conflicts of interest

None of the authors have financial disclosures (MAM, HJ, AC, BB, JGC).

Authorship

All authors attest that they meet the current ICMJE criteria for Authorship.

Acknowledgements

None.

Appendix A. Supplementary data

Supplementary data to this article can be found online at <https://doi.org/10.1016/j.ajoc.2018.12.017>.

References

- Grant WM, Schuman JS. *Toxicology of the Eye*. IL: Springfield; 1993.
- Abtahi MA, Abtahi SH, Fazel F, et al. Topiramate and the vision: a systematic review. *Clin Ophthalmol*. 2012;6:117–131.
- Mahesh G, Giridhar A, Saikumar SJ, Fegde S. Drug-induced acute myopia following chlorthalidone treatment. *Indian J Ophthalmol*. 2007;55:386–388.
- Panday VA, Rhee DJ. Review of sulfonamide-induced acute myopia and acute bilateral angle-closure glaucoma. *Compr Ophthalmol Update*. 2007;8:271–276.
- Martínez-González MC, García-Silva J, Sánchez MA, et al. Acute myopia while on oral isotretinoin treatment. *J Eur Acad Dermatol Venereol*. 2007;21:977–978.
- Bhatnagar V, Gormley NJ, Luo L, et al. FDA approval summary: daratumumab for treatment of multiple myeloma after one prior therapy. *Oncologist*. 2017;22:1–7.