

UC Davis

UC Davis Previously Published Works

Title

Cerebrospinal Fluid Levels of Phosphorylated Neurofilament Heavy as a Diagnostic Marker of Canine Degenerative Myelopathy.

Permalink

<https://escholarship.org/uc/item/66n4j526>

Journal

Journal of veterinary internal medicine, 31(2)

ISSN

0891-6640

Authors

Toedebusch, CM
Bachrach, MD
Garcia, VB
[et al.](#)

Publication Date

2017-03-01

DOI

10.1111/jvim.14659

Peer reviewed

Standard Article

J Vet Intern Med 2017;31:513–520**Cerebrospinal Fluid Levels of Phosphorylated Neurofilament Heavy as a Diagnostic Marker of Canine Degenerative Myelopathy**

C.M. Toedebusch, M.D. Bachrach, V.B. Garcia, G.C. Johnson, M.L. Katz, G. Shaw, J.R. Coates, and M.L. Garcia

Background: No definitive, antemortem diagnostic test for canine degenerative myelopathy (DM) is available. Phosphorylated neurofilament heavy (pNF-H) is a promising biomarker for nervous system diseases.

Hypothesis/Objective: Cerebrospinal fluid (CSF) and serum pNF-H is a detectable biological marker for diagnosis of canine DM.

Animals: Fifty-three DM-affected, 27 neurologically normal, 7 asymptomatic at-risk, and 12 DM mimic dogs.

Methods: Archived CSF and serum pNF-H concentrations were determined by a commercially available ELISA. A receiver-operating characteristic (ROC) curve was generated with CSF values.

Results: Compared with old control dogs, median CSF pNF-H concentration was increased in all stages of DM; old dogs 5.1 ng/mL (interquartile range [IQR] 1.4–9.3) versus DM stage 1 23.9 ng/mL (IQR 20.8–29.6; $P < .05$) versus DM stage 2 36.8 ng/mL (IQR 22.9–51.2; $P < .0001$) versus DM stage 3 25.2 ng/mL (IQR 20.2–61.8; $P < .001$) versus DM stage 4 38.0 ng/mL (IQR 11.6–59.9; $P < .01$). Degenerative myelopathy stage 1 dogs had increased median CSF pNF-H concentrations compared with asymptomatic, at-risk dogs (3.4 ng/mL [IQR 1.5–10.9; $P < .01$]) and DM mimics (6.6 ng/mL [IQR 3.0–12.3; $P < .01$]). CSF pNF-H concentration >20.25 ng/mL was 80.4% sensitive (confidence interval [CI] 66.09–90.64%) and 93.6% specific (CI 78.58–99.21%) for DM. Area under the ROC curve was 0.9467 (CI 0.92–0.9974). No differences in serum pNF-H concentration were found between control and DM-affected dogs.

Conclusions and Clinical Importance: pNF-H concentration in CSF is a sensitive biomarker for diagnosis of DM. Although there was high specificity for DM in this cohort, further study should focus on a larger cohort of DM mimics, particularly other central and peripheral axonopathies.

Key words: Amyotrophic lateral sclerosis; Biomarker; Dog; Neurodegenerative disease.

Canine degenerative myelopathy (DM) is a late-onset progressive neurodegenerative disease affecting many pure and mixed-breed dogs.^{1–4} The clinical spectrum of DM is homogeneous within and across breeds. Four stages of disease progression have been defined (Table 1).^{5,a} Clinical signs are the result of multisystem neurodegeneration, resulting from progressive axonal degeneration of the central and peripheral nervous systems.^{1,5–9} Superoxide dismutase 1 gene (*SOD1*)

Abbreviations:

ALS	amyotrophic lateral sclerosis
CI	confidence interval
CSF	cerebrospinal fluid
CV	coefficient of variability
DM	degenerative myelopathy
IQR	interquartile range
pNF-H	phosphorylated neurofilament heavy
ROC	receiver-operating characteristic
SOD1	superoxide dismutase-1

From the Department of Veterinary Medicine and Surgery, College of Veterinary Medicine, (Toedebusch, Coates); Division of Biological Sciences, Bond Life Sciences Center, (Garcia, Bachrach, Garcia); Department of Veterinary Pathobiology, College of Veterinary Medicine, (Johnson); Mason Eye Institute, School of Medicine, University of Missouri-Columbia, Columbia, MO (Katz); and the EnCor Biotechnology Inc, Gainesville, FL (Shaw).

Presented in part at the 26th international symposium on ALS/MND, Orlando, FL, USA, December, 2016 and the ACVIM Forum, Denver, CO, USA, June, 2016.

Corresponding authors: M.L. Garcia, Division of Biological Sciences, Bond Life Sciences Center, University of Missouri, 340C C.S Bond Life Sciences Center, 1201 E. Rollins St., Columbia, MO 65211; e-mail: garciaml@missouri.edu and J.R. Coates, Department of Veterinary Medicine and Surgery, College of Veterinary Medicine, University of Missouri, Columbia, MO 65211; e-mail: coatesj@missouri.edu

Submitted September 23, 2016; Revised December 5, 2016; Accepted December 22, 2016.

Copyright © 2017 The Authors. *Journal of Veterinary Internal Medicine* published by Wiley Periodicals, Inc. on behalf of the American College of Veterinary Internal Medicine.

This is an open access article under the terms of the Creative Commons Attribution-NonCommercial License, which permits use, distribution and reproduction in any medium, provided the original work is properly cited and is not used for commercial purposes.

DOI: 10.1111/jvim.14659

mutations (*SOD1:c.118A*, *SOD1:c.52T*) are risk factors for DM, with most cases resulting from autosomal recessive inheritance.^{2,3,10} The disease is considered to be similar in cause, progression, and prognosis to human amyotrophic lateral sclerosis (ALS).

A definitive diagnosis of DM can only be made post-mortem by spinal cord histopathology.^{1,6} Because *SOD1* mutations are incompletely penetrant, genetic screening is insufficient for diagnosis. Currently, a presumptive clinical diagnosis is based on the following criteria: (1) compatible history and clinical signs, (2) *SOD1* mutation(s), and (3) exclusion of other spinal cord and peripheral nerve diseases that can mimic DM. However, acquired spinal cord diseases can coexist with DM, confounding the clinical diagnosis. Thus, identification of a biomarker specific to DM is necessary to facilitate appropriate patient management.

Phosphorylated neurofilament heavy (pNF-H), an abundant structural protein of myelinated motor axons,¹¹ is a promising fluid biomarker of canine^{12,13} and human^{14–18} nervous system damage and disease

Table 1. Classification scheme for disease severity of canine degenerative myelopathy.

Stage	Neurological Signs
1	Asymmetric, general proprioceptive ataxia and spastic paresis in pelvic limbs Intact spinal reflexes
2	Non-ambulatory paraparesis, paraplegia Reduced to absent pelvic limb spinal reflexes Pelvic limb muscle atrophy ±urinary/fecal incontinence
3	Flaccid paraplegia, thoracic limb paresis Absent spinal reflexes Severe pelvic limb muscle atrophy Urinary/fecal incontinence
4	Flaccid tetraplegia Absent spinal reflexes Severe generalized muscle atrophy Urinary/fecal incontinence Dysphagia, dysphonia, respiratory difficulty

states. Phosphorylated lysine–serine–proline (KSP) repeats within the carboxy terminus of pNF-H are immunogenic^{19,20} and increase the stability of the NF-H protein.²¹ These factors, coupled with the high level of expression, enable detection of pNF-H in cerebrospinal fluid (CSF)²² and serum²³ upon axonal injury. Increased serum pNF-H concentration has been associated with an unsuccessful outcome in dogs with acute, severe spinal cord injury secondary to thoracolumbar Hansen type 1 intervertebral disk herniation.^{12,13} Moreover, increased pNF-H concentrations in blood^{15,24} and CSF^{16,24,25} have shown high diagnostic performance and association with disease progression in patients diagnosed with ALS. Given the progressive central and peripheral axonal loss observed in DM, we hypothesize that pNF-H is readily detectable in CSF and serum of DM-affected dogs and can be used as a diagnostic biomarker for DM.

Materials and Methods

Case Selection

We evaluated CSF and serum samples collected between July 2012 and March 2016 from dogs recruited for various DM-related studies. All pet owners signed an informed consent form (approved by the University of Missouri Animal Care and Use Committee, protocol #8339). Samples were obtained both from dogs at the University of Missouri Veterinary Health Center and from collaborating primary care and neurology specialty veterinarians as mail-in samples. We also collected a subset of the control samples from young purpose-bred research dogs housed at the University of Missouri in compliance with the National Institutes of Health Guide for the Care and Use of Laboratory Animals and approved by the University of Missouri Animal Care and Use Committee (protocol #8339).

Samples from DM-affected dogs were included if the following criteria were met: (1) clinical history and neurological examination consistent with DM, with assignment to disease stage based on a clinical grading scale (Table 1⁴), (2) homozygosity for 118G>A *SOD1* mutation,² (3) histopathological diagnosis of DM by a board-certified veterinary pathologist (GJC) confirming axonal

degeneration and astroglial proliferation most severe in the dorsal portion of the lateral funiculus and dorsal funiculi of the caudal thoracic spinal cord,^{1,6} and (4) SOD1-immunoreactive aggregates within ventral horn motor neurons.^{9,26}

We evaluated multiple control groups in this study. To assess an effect of age on the concentration of pNF-H in biological fluid, we evaluated samples from young and old neurologically normal dogs. Samples from dogs that were 1–7 years of age with a normal neurological examination and wild-type *SOD1* genotype were included in the young control group. The old control group included samples from dogs that were ≥8 years of age with a normal neurological examination, wild-type *SOD1* genotype, and normal histopathology of the caudal thoracic spinal cord. A third control group consisted of dogs ≥8 years of age with a normal neurological examination that were homozygous for the *SOD1c.118A* allele (asymptomatic, at-risk). To assess the specificity of increased CSF pNF-H to DM, we analyzed samples from the latter group and from dogs with chronic, progressive myelopathy from acquired spinal cord diseases that mimic DM (DM mimics). The DM mimic group included samples from dogs that were ≥8 years of age with a clinical history and neurological examination consistent with a chronic, progressive myelopathy. Furthermore, identification of thoracolumbar Hansen type 2 intervertebral disk herniation at necropsy or histopathological diagnosis of non-DM-associated myelopathy or neuropathy was required for inclusion. All *SOD1* genotypes were included in this group.

Sample Collection and Testing

Cerebrospinal fluid samples were collected from the cerebellomedullary cistern at the time of neurodiagnostic testing, immediately post-euthanasia, or both. When available, results of CSF total nucleated cell count, differential cellularity, and total protein concentration were recorded. Aliquots of CSF were immediately frozen at –80°C. Whole blood was collected into a plain glass tube containing no anticoagulants or preservatives. After clotting at room temperature for at least 30 minutes, samples were centrifuged for 10 minutes at 1278 g's. Serum and CSF samples were stored at –80°C until analysis.

We measured serum and CSF pNF-H concentration with a commercially available ELISA kit (catalog# ELISA-pNF-H version 2.2^b) according to the manufacturer's instructions. Samples underwent 2 freeze-thaw cycles before analysis, once for aliquoting into smaller volumes and once for analysis. Standards and samples were evaluated in triplicate. To maintain optical densities within the linear range of the standard curve, samples were diluted as follows: control CSF 1:10, DM-affected CSF 1:20, control, and DM-affected serum 3:5.

For quality control, we assessed intra- and interassay coefficients of variability (CV). Intra-assay CV, calculated from the optical densities of plate standards from 5 independent experiments, was 6.3% (range 4.5–7.6%). Five test samples, run on 3 independent experiments, yielded an interassay CV of 12.6% (range 6–21%).

Stability Testing

We compared the stability and variability of CSF pNF-H concentration between 2 handling conditions. Specifically, we tested samples that received standard laboratory treatment and those that were treated to simulate shipment from collaborators. We tested samples from 1 dog/group for the following groups: aged control, asymptomatic, at-risk, and DM stage 1. Each sample collected was divided into aliquots that were either immediately frozen at –80°C or stored overnight at –20°C, placed in a cooler at room temperature with an ice pack for 24–48 hours, and then

frozen at -80°C . Each pair of samples was then compared over 4 independent experiments.

Statistical Analysis

Cerebrospinal fluid and serum pNF-H concentrations were stratified by study group and tested for normality. Normally distributed data were compared via unpaired, 2-tailed Student's *t*-test and presented as the mean \pm standard deviation. Non-normally distributed data were analyzed by Kruskal–Wallis ANOVA on ranks with posthoc multivariate analyses and presented as the median with interquartile range. Correlation between CSF pNF-H concentration and DM disease stage was calculated by Spearman rank correlation. Receiver-operating characteristic (ROC) curve analysis was performed to determine the accuracy of CSF pNF-H concentration to detect DM.¹² All calculations and graphics were made by GraphPad Prism 6.0 software^c.

Results

Clinical Features

Cerebrospinal fluid, serum, or both samples from 53 DM-affected dogs were evaluated. There were 4 sexually intact females, 21 spayed females, 7 sexually intact males, and 21 castrated males. Median age of stage 1 dogs ($n = 11$) was 9.6 years (range 7–12.9 years), stage 2 ($n = 13$) 11.2 years (range 8–13 years), stage 3 dogs ($n = 18$) 12 years (range 10–15 years), and stage 4 ($n = 11$) 13.3 years (range 10.5–15 years). Breeds included Boxer (stage 1 $n = 5$, stage 2 $n = 3$, stage 3 $n = 5$, stage 4 $n = 2$), Pembroke Welsh Corgi (stage 1 $n = 2$, stage 2 $n = 5$, stage 3 $n = 10$, stage 4 $n = 6$), Chesapeake Bay Retriever (stage 1 $n = 3$, stage 2 $n = 1$), mixed-breed dog (stage 3 $n = 2$, stage 4 $n = 3$) and 1 each of Airedale Terrier (stage 3), Australian Shepherd (stage 2), Bernese Mountain Dog (stage 2), Duck Tolling Retriever (stage 2), German Shepherd Dog (stage 1), and Wire-hair Fox Terrier (stage 2).

Cerebrospinal fluid, serum, or both samples from 13 young, neurologically normal dogs included 7 sexually intact females, 2 spayed females, and 4 sexually intact males with a median age of 2 years (range 1.6–5.5 years). Breeds included Boxer ($n = 2$), Golden Retriever ($n = 1$), and mixed-breed dogs ($n = 10$). Samples from 14 old, neurologically normal dogs included 5 sexually intact females, 6 spayed females, 1 sexually intact male, and 2 castrated males with a median age of 10 years (range 8–16 years). Breeds included Beagle ($n = 4$), Rhodesian Ridgeback ($n = 2$), mixed-breed dogs ($n = 2$), and 1 each of Airedale Terrier, Basenji, Bernese Mountain dog, Pembroke Welsh Corgi, Standard Schnauzer, and Weimaraner. Samples from 7 asymptomatic, at-risk dogs included 4 intact females, 2 spayed females, and 1 intact male with a median age of 12.5 years (range 8.5–14.2 years). Breeds included Boxer ($n = 3$) and Pembroke Welsh Corgi ($n = 4$). Samples from 12 DM mimic dogs included 2 sexually intact females, 2 spayed females, 2 sexually intact males, and 6 castrated males with a median age of 12.3 years (range 8–16 years). Breeds included German Shepherd dog ($n = 2$), Pembroke Welsh Corgi ($n = 2$), Standard

Schnauzer ($n = 2$), and 1 each of Afghan Hound, English Cocker Spaniel, Golden Retriever, Labrador Retriever, Golden Retriever, and Rhodesian Ridgeback. Diagnosis of DM mimics included Hansen type 2 intervertebral disk herniation ($n = 7$), chronic fibrocartilaginous embolism with syringohydromyelia and fibrosis ($n = 1$), axonal dystrophy ($n = 1$), diffuse white matter and peripheral nerve degeneration ($n = 1$), radiculopathy with neurogenic atrophy of pelvic limb muscles ($n = 1$), and adult onset neuropathy in English Cocker Spaniels ($n = 1$).

Cerebrospinal Fluid Analysis

Cerebrospinal fluid analysis of DM-affected dogs ($n = 21$) revealed a median nucleated cell count of 1 cell/ μL (range, 0–19 cells/ μL), median CSF red blood cell count of 3 cells/ μL (range, 0–2,834 cells/ μL), and median protein concentration of 26 mg/dL (range, 18–100). Three dogs had CSF pleocytosis, which were classified as mixed cell in all dogs. Cerebrospinal fluid protein concentration was above the reference interval (≥ 25 mg/dL) in 10 dogs.

Young and old control dogs ($n = 9$) had a median nucleated cell count of 1 cell/ μL (range, 0–4 cells/ μL), median CSF red blood cell count of 2 cells/ μL (range, 0–36 cells/ μL), and median protein concentration of 17 mg/dL (range, 13–43). Cerebrospinal fluid protein concentration was above the reference interval in 2 dogs. Asymptomatic, at-risk dogs ($n = 3$) had a median nucleated cell count of 3 cells/ μL (range, 1–4 cells/ μL), median Cerebrospinal fluid red blood cell count of 239 cells/ μL (range, 3–70,000 cells/ μL), and median

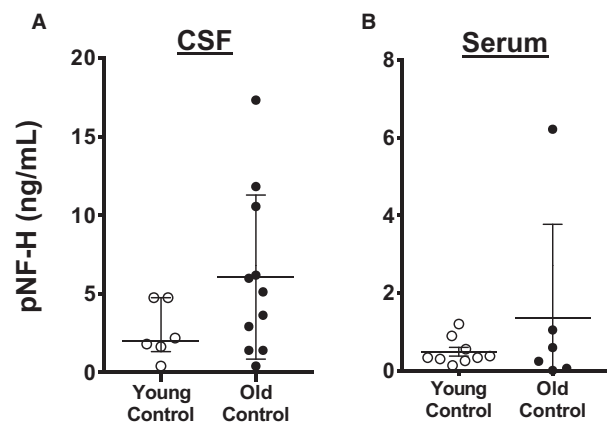


Fig 1. Phosphorylated neurofilament heavy (pNF-H) concentration in cerebrospinal fluid (CSF) and serum does not change with age. (A) Mean CSF concentration of pNF-H was not different between young dogs (≤ 7 years, $n = 9^*$) and aged dogs (≥ 8 years, $n = 12^*$); $P = .1385$. (B) Mean serum pNF-H concentration was not different in young dogs ($n = 12^*$) and aged dogs ($n = 9^*$); $P = .4321$. Comparisons based on unpaired *t*-test; bars represent group mean and standard deviation. *pNF-H was below detectable limits in some samples evaluated (CSF: young $n = 3$, old $n = 1$; serum young $n = 3$, old $n = 3$).

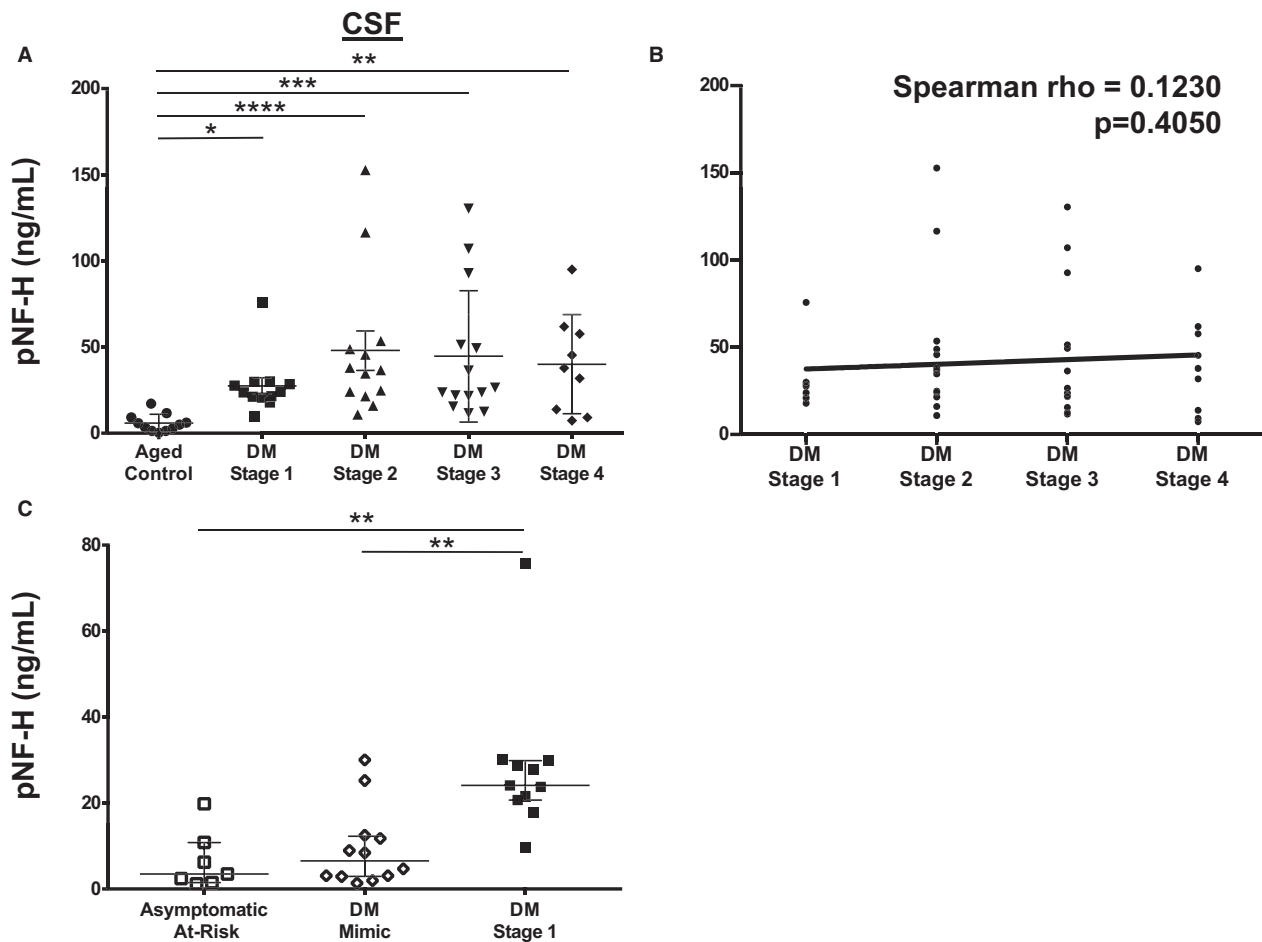


Fig 2. Phosphorylated neurofilament heavy (pNF-H) is increased in cerebrospinal fluid (CSF) of degenerative myelopathy (DM)-affected dogs (A) Compared with control dogs ($n = 12$), median CSF pNF-H was increased in DM-affected dogs at all disease stages (stage 1 $n = 10$, $P < .05$; stage 2 $n = 13$, $P < .0001$; stage 3 $n = 14$, $P < .001$; stage 4 $n = 9$, $P < .01$). Comparisons based on a Kruskal–Wallis ANOVA on ranks with posthoc Dunn’s method; bars represent group median and interquartile range. (B) There was no correlation between CSF pNF-H concentration and DM disease stage ($P = .4050$). (C) DM stage 1 dogs have increased CSF pNF-H concentration compared with asymptomatic at-risk dogs ($n = 7$, $P < .01$) and DM mimics ($n = 12$, $P < .01$). Comparisons based on a Kruskal–Wallis ANOVA on ranks with posthoc Dunn’s method; bars represent group median and interquartile range.

protein concentration of 26 mg/dL (range, 21–72). Cerebrospinal fluid protein concentration was above the reference interval in 2 dogs. DM mimic dogs ($n = 6$) had median nucleated cell count of 1.5 cells/ μ L (range, 0–11 cells/ μ L), median CSF red blood cell count of 3.5 cells/ μ L (range, 0–634 cells/ μ L), and median protein concentration of 27 mg/dL (range, 19–29). One dog had a large mononuclear pleocytosis. Four dogs had protein concentrations above the reference interval.

Phosphorylated Neurofilament Heavy Concentration in Biological Fluid

The mean CSF pNF-H concentration was not significantly different between young and old control dogs (Fig 1A; 2.6 ± 1.8 ng/mL versus 6.1 ± 5.2 ng/mL, $P = .1385$). The variance in concentrations was higher among the old than the young dogs ($P = .02$). Cerebrospinal fluid pNF-H was below the limit of detection in 3 young dogs and 1 old dog. Similarly, there was no

significant difference in mean serum pNF-H concentration between young and old control dogs (Fig 1B; 0.5 ± 0.3 ng/mL versus 1.4 ± 2.4 ng/mL, $P = .417$). The variance in serum pNF-H concentrations was higher among the old dogs ($P < .0001$). Serum pNF-H was below the limit of detection in 3 dogs of each group tested.

Compared with old control dogs, median CSF pNF-H concentration was increased at all DM stages (Fig 2A; 5.1 ng/mL [IQR 1.4–9.3] versus 23.9 ng/mL [IQR 20.8–29.6; $P < .05$] versus 36.8 ng/mL [IQR 22.9–51.2; $P < .0001$] versus 25.2 ng/mL [IQR 20.2–61.8; $P < .001$] versus 38.0 ng/mL [IQR 11.6–59.9; $P < .01$]). No significant differences in median CSF pNF-H concentration were observed between DM stages. To evaluate the specificity of increased CSF pNF-H concentration to DM, we compared asymptomatic, at-risk dogs and DM mimics to early DM-affected dogs (stage 1). While there was no difference between asymptomatic, at-risk dogs and DM mimics, median CSF

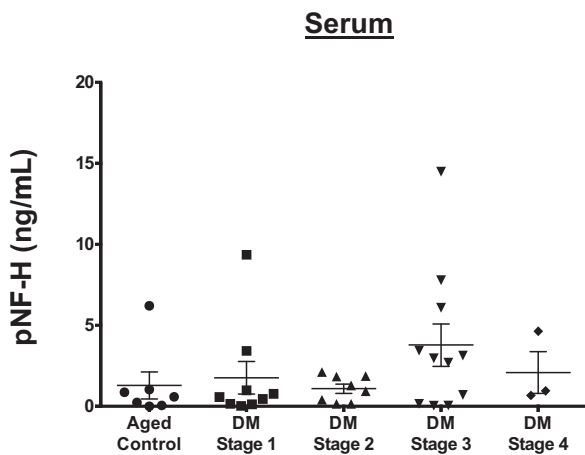


Fig 3. Phosphorylated neurofilament heavy (pNF-H) is not increased in serum of degenerative myelopathy (DM)-affected dogs. Serum pNF-H concentration was not different between aged control dogs ($n = 9^*$) and DM-affected dogs of all disease stages (stage 1 $n = 8^*$, stage 2 $n = 8^*$, stage 3 $n = 10$, stage 4 $n = 4^*$; $P = .3095$). Comparisons based on a Kruskal–Wallis ANOVA on ranks with posthoc Dunn’s method; bars represent group median and interquartile range. *Serum pNF-H was below detectable limits in some samples evaluated (aged control dogs $n = 3$, stage 1 $n = 1^*$, stage 2 $n = 2^*$, stage 4 $n = 2$).

pNF-H concentration was increased in DM stage 1 dogs relative to both control groups (Fig 2C; 3.4 ng/mL [IQR 1.5–10.9] versus 6.6 ng/dL [IQR 3.0–12.3] versus 24.1 ng/dL [IQR 20.1–30.0; $P < .01$]). There was no difference in median serum pNF-H concentration between old control dogs and DM-affected dogs at any stage (Fig 3A; $P = .5151$).

To evaluate the diagnostic performance of this assay, a ROC curve was generated. A pNF-H cutoff concentration above 20.25 ng/mL yielded the optimal discrimination between DM stage 1, asymptomatic, at-risk, and DM mimic dogs, with a sensitivity of 90.0% (confidence interval, CI 55.5–99.75%) and specificity of 89.5% (Fig 4A; CI 66.86–98.70%). The calculated area under the curve (AUC) was 0.9263 (CI 0.8270–1.026). CSF pNF-H concentration significantly correlated with a diagnosis of DM in this cohort ($P = .0002$). Applying this cutoff to include all other DM-affected and old control dogs, diagnostic sensitivity was 80.4% (CI 66.09–90.64%) with 93.6% specificity (Fig 4B; CI 78.58–99.21%). The calculated area under the curve (AUC) was 0.9467 (CI 0.898–0.996; $P < .0001$).

Stability Testing

Delayed deep-freezing did not affect CSF pNF-H concentration (Fig 5A–C); old control dogs, immediate freezing versus delayed freezing: 10.6 \pm 2.5 ng/mL versus 15.3 \pm 3.0 ng/mL ($P = .1037$); asymptomatic, at-risk, 8.8 \pm 2.1 ng/dL versus 8.7 \pm 3.0 ng/dL ($P = .9434$); DM stage 1, 38.3 \pm 0.8 ng/dL versus 40.0 \pm 1.7 ng/dL ($P = .4337$).

Discussion

The results of this study show that pNF-H is increased in the CSF, but not in serum of DM-affected dogs relative to control groups. Comparing all groups, CSF pNF-H concentration >20.25 ng/mL is 80.4% sensitive (CI 66.09–90.64%) and 95.0% specific (CI 83.08–99.39%) to identify DM. Moreover, the positive likelihood ratio for CSF pNF-H >20.25 ng/mL to

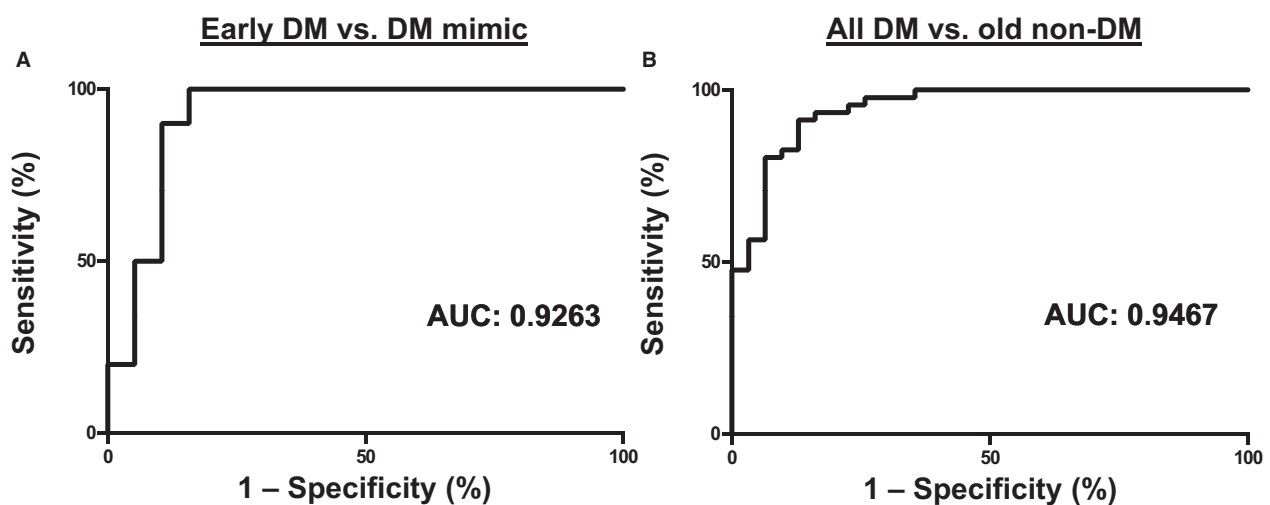


Fig 4. Increased phosphorylated neurofilament heavy (pNF-H) in cerebrospinal fluid (CSF) is a sensitive and specific disease marker for degenerative myelopathy (DM). (A) ROC curve comparing CSF pNF-H concentration of early DM-affected dogs (stage 1, $n = 10$) to DM mimics ($n = 12$) and asymptomatic at-risk dogs ($n = 7$). Area under the curve (AUC) was 0.9263. pNF-H >20.25 ng/mL yielded a 90% sensitivity and 89.47% specificity for DM. (B) Receiver-operating characteristic curve for analysis of CSF pNF-H concentration comparing all DM-affected dogs ($n = 46$) to all old non-DM dogs ($n = 31$). AUC was 0.9467. pNF-H concentration >20.25 ng/mL yielded an 80.43% sensitivity and 93.6% specificity for identification of DM.

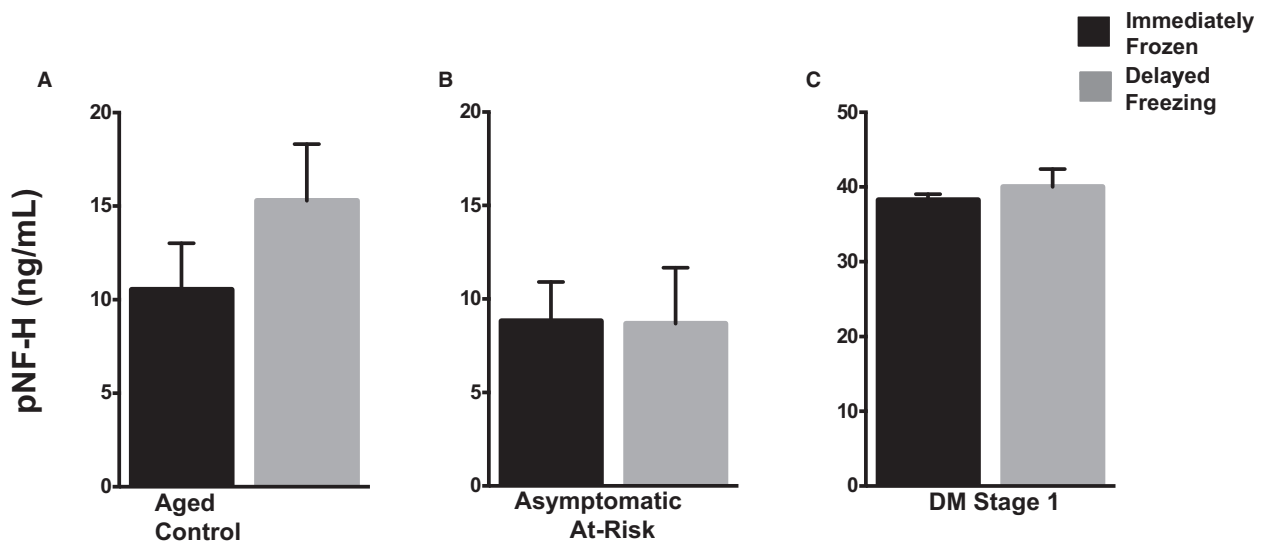


Fig 5. Detectable cerebrospinal fluid phosphorylated neurofilament heavy (pNF-H) does not change with delayed -80°C freezing. Delay in -80°C freezing resulted in no change in detectable pNF-H concentration in (A) aged control ($n = 1$, $P = .1622$), (B) asymptomatic at-risk ($n = 1$, $P = .9434$), and (C) degenerative myelopathy-affected stage 1 ($n = 1$, $P = .4337$) dogs. Comparisons based on unpaired, 2-tailed t -test; error bars represent standard deviation.

diagnose DM is 16:1, a value consistent with conclusive probability of diagnosis.²⁷ Taken together, quantification of CSF pNF-H has potential as an accurate diagnostic test for SOD1^{E40K}-associated canine DM.

While CSF protein constituents have been increased in DM-affected dogs, none have shown specificity for DM.^{28,29} Diagnosis of DM is most challenging in dogs with a genetic predisposition for DM and concurrent acquired myelopathy. As the majority of dogs in the DM mimic cohort had clinical signs secondary to Hansen type 2 intervertebral disk herniation, the high specificity of increased CSF pNF-H concentration to DM is large in comparison with compressive myelopathy. Thus, this test may provide a novel discrimination between chronic, compressive myelopathy and primary axonal degenerative disease, which can be used to guide clinical recommendations and client expectations. However, further study should focus on larger DM mimic cohorts, which include a variety of primary axonal diseases to further evaluate the specificity of increased CSF pNF-H to DM.

Serum evaluation of pNF-H did not reveal detectable differences between DM and control dogs. This was unexpected, as pNF-H is readily detectable in the serum of dogs with acute, severe spinal injury,^{12,13} and ALS patients.^{15,24} The lack of detectable differences is likely due to the variability of serum pNF-H within all groups. Axons are highly sensitive to metabolic and mechanical stress,³⁰ thus raising the question of concurrent, unidentified axonopathy in a subset of these control dogs. Electrodiagnostic examinations were not performed in all cases to exclude this possibility. However, the ease of serum sample acquisition relative to CSF warrants further investigation with increased sample size to determine the utility of serum pNF-H for diagnosis and disease monitoring in DM.

Interestingly, there was no significant correlation between DM disease stage and CSF pNF-H concentration. The pNF-H protein, a major structural component of large, myelinated axons, has proven a useful surrogate measure of axonal damage.^{23,31,32} It is tempting to predict that progressive axonal damage in a homogeneous disease such as DM would result in steady increases in CSF pNF-H that would correlate with disease stage. However, we report a broad range of pNF-H concentrations within each disease stage. Similarly, human ALS patients have a wide variability in CSF pNF-H concentrations, which are weakly associated with the ALS function rating scale (ALSFRS-R).^{16,24} Disease-related alterations in neurofilament subunit (NF) regulation may underlie this finding. Like ALS patients,^{33,34} DM-affected dogs have early and progressive ectopic phosphorylation of NF-H within neuronal perikarya, without a significant decline in total pNF-H protein in the lumbar spinal cord (C.M. Toedebusch, unpublished data). While the mechanisms are not completely understood, disease-specific alterations in NF synthesis, turnover, and axonal transport have been implicated in NF accumulation and likely to influence detectable CSF levels throughout disease.^{11,35–38} Thus, longitudinal studies within individual dogs may be necessary to determine increases with disease progression.

A limitation of this study is the available sample size per group for serum analysis. To evaluate whether our non-significant results were due to lack of statistical power, we conducted a posthoc power analysis by Sigmaplot 11 software^d with power ($1-\beta$) set at 0.80 and $\alpha = 0.05$. These findings indicated a total sample population of 550 (or 110/group) would be necessary to reach significance with $P < .05$.

An additional limitation of this study is the limited variety of neurological diseases evaluated in the DM mimic cohort. A DM mimic case diagnosed with diffuse central and peripheral axonopathy had a CSF pNF-H concentration consistent with DM dogs (30 ng/mL). While our data suggest a clear distinction in CSF pNF-H concentration between compressive myelopathy and DM, it is possible that primary axonal diseases may not be distinguishable from each other. Therefore, further investigation with larger, more inclusive cohorts is necessary to fully elucidate the relationship of CSF pNF-H concentration and underlying neurological disease.

In conclusion, the results from this present study indicate that quantification of CSF pNF-H concentration is a promising antemortem diagnostic tool for DM. Further study of a larger cohort of DM mimic dogs is necessary to validate the overall specificity of increased CSF pNF-H to DM.

Footnotes

^a Kanazono S, Coates JR, Pithua, P, Johnson GC, Johnson, GJ, O'Brien DP. Clinical progression of canine degenerative myelopathy. Proc. 31st ACVIM Forum, Seattle 2013;24(3).

^b Encor Biotechnology, Inc, Gainesville, FL

^c GraphPad Software, Inc La Jolla, CA

^d Systat Software Inc, San Jose, CA

Acknowledgments

The authors acknowledge the Animal Molecular Genetic Disease Laboratory for assistance with genotyping.

Grant support: This work was supported by the AKC Canine Health Foundation Grant #2165, American Boxer Charitable Foundation.

Conflict of Interest Declaration: Authors declare no conflict of interest.

Off-label Antimicrobial Declaration: Authors declare no off-label use of antimicrobials.

References

1. Averill DR. Degenerative myelopathy in the aging German Shepherd dog: Clinical and pathologic findings. *J Am Vet Med Assoc* 1973;15:1045–1051.
2. Awano T, Johnson GS, Wade CM, et al. Genome-wide association analysis reveals a SOD1 mutation in canine degenerative myelopathy that resembles amyotrophic lateral sclerosis. *Proc Natl Acad Sci USA* 2009;106:2794–2799.
3. Zeng R, Coates JR, Johnson GC, et al. Breed distribution of SOD1 alleles previously associated with canine degenerative myelopathy. *J Vet Intern Med* 2014;28:515–521.
4. Coates JR, Winger FA. Canine degenerative myelopathy. *Vet Clin North Am Small Anim Pract* 2010;40:929–950.
5. Shelton GD, Johnson GC, O'Brien DP, et al. Degenerative myelopathy associated with a missense mutation in the superoxide dismutase 1 (SOD1) gene progresses to peripheral neuropathy in Pembroke Welsh Corgis and Boxers. *J Neurol Sci* 2012;318:55–64.

6. March PA, Coates JR, Abyad RJ, et al. Degenerative myelopathy in 18 Pembroke Welsh Corgi dogs. *Vet Pathol* 2009;46:241–250.

7. Braund KG, Vandeveld M. German Shepherd dog myelopathy—a morphologic and morphometric study. *Am J Vet Res* 1978;39:1309–1315.

8. Coates JR, March PA, Oglesbee M, et al. Clinical characterization of a familial degenerative myelopathy in Pembroke Welsh Corgi dogs. *J Vet Intern Med* 2007;21:1323–1331.

9. Morgan BR, Coates JR, Johnson GC, et al. Characterization of intercostal muscle pathology in canine degenerative myelopathy: A disease model for amyotrophic lateral sclerosis. *J Neurosci Res* 2013;91:1639–1650.

10. Winger FA, Zeng R, Johnson GS, et al. Degenerative myelopathy in a Bernese Mountain Dog with a novel SOD1 missense mutation. *J Vet Intern Med* 2011;25:1166–1170.

11. Friede RL, Samorajski T. Axon caliber related to neurofilaments and microtubules in sciatic nerve fibers of rats and mice. *Anat Rec* 1970;167:379–387.

12. Nishida H, Nakayama M, Tanaka H, et al. Evaluation of serum phosphorylated neurofilament subunit NF-H as a prognostic biomarker in dogs with thoracolumbar intervertebral disc herniation. *Vet Surg* 2014;43:289–293.

13. Mashita T, Kamishina H, Nakamoto Y, et al. Combination of serum phosphorylated neurofilament heavy subunit and hyperintensity of intramedullary T2W on magnetic resonance imaging provides better prognostic value of canine thoracolumbar intervertebral disc herniation. *J Vet Med Sci* 2015;77:433–438.

14. Gatson JW, Barillas J, Hynan LS, et al. Detection of neurofilament-H in serum as a diagnostic tool to predict injury severity in patients who have suffered mild traumatic brain injury. *J Neurosurg* 2014;121:1232–1238.

15. Boylan K, Yang C, Crook J, et al. Immunoreactivity of the phosphorylated axonal neurofilament H subunit (pNF-H) in blood of ALS model rodents and ALS patients: Evaluation of blood pNF-H as a potential ALS biomarker. *J Neurochem* 2009;111:1182–1191.

16. Steinacker P, Feneberg E, Weishaupt J, et al. Neurofilaments in the diagnosis of motoneuron diseases: A prospective study on 455 patients. *J Neurol Neurosurg Psychiatry* 2015;87:12–20.

17. Gresle MM, Liu Y, Dagley LF, et al. Serum phosphorylated neurofilament-heavy chain levels in multiple sclerosis patients. *J Neurol Neurosurg Psychiatry* 2014;85:1209–1213.

18. Ahadi R, Khodaghali F, Daneshi A, et al. Diagnostic value of serum levels of GFAP, pNF-H, and NSE compared with clinical findings in severity assessment of human traumatic spinal cord injury. *Spine* 2015;40:E823–E830.

19. Lee VM, Otvos L, Carden MJ, et al. Identification of the major multiphosphorylation site in mammalian neurofilaments. *Proc Natl Acad Sci USA* 1988;85:1998–2002.

20. Shaw G, Osborn M, Weber K. Reactivity of a panel of neurofilament antibodies on phosphorylated and dephosphorylated neurofilaments. *Eur J Cell Biol* 1986;42:1–9.

21. Goldstein ME, Sternberger NH, Sternberger LA. Phosphorylation protects neurofilaments against proteolysis. *J Neuroimmunol* 1987;14:149–160.

22. Petzold A, Keir G, Green AJ, et al. A specific ELISA for measuring neurofilament heavy chain phosphoforms. *J Immunol Methods* 2003;278:179–190.

23. Shaw G, Yang C, Ellis R, et al. Hyperphosphorylated neurofilament NF-H is a serum biomarker of axonal injury. *Biochem Biophys Res Commun* 2005;336:1268–1277.

24. Boylan KB, Glass JD, Crook JE, et al. Phosphorylated neurofilament heavy subunit (pNF-H) in peripheral blood and CSF as a potential prognostic biomarker in amyotrophic lateral sclerosis. *J Neurol Neurosurg Psychiatry* 2013;84:467–472.

25. Brettschneider J, Petzold A, Sussmuth SD, et al. Axonal damage markers in cerebrospinal fluid are increased in ALS. *Neurology* 2006;66:852–856.
26. Morgan BR, Coates JR, Johnson GC, et al. Characterization of thoracic motor and sensory neurons and spinal nerve roots in canine degenerative myelopathy, a potential disease model of amyotrophic lateral sclerosis. *J Neurosci Res* 2014;92:531–541.
27. Deeks JJ, Altman DG. Diagnostic tests 4: Likelihood ratios. *BMJ* 2004;329:168–169.
28. Oji T, Kamishina H, Cheeseman JA, et al. Measurement of myelin basic protein in the cerebrospinal fluid of dogs with degenerative myelopathy. *Vet Clin Pathol* 2007;36:281–284.
29. Shafie IF, McLaughlin M, Burchmore R, et al. The chaperone protein clusterin may serve as a cerebrospinal fluid biomarker for chronic spinal cord disorders in the dog. *Cell Stress Chaperones* 2014;19:311–320.
30. Buki A, Povlishock JT. All roads lead to disconnection?—traumatic axonal injury revisited. *Acta Neurochir (Wien)* 2006;148:181–193; discussion 193–184.
31. Petzold A, Shaw G. Comparison of two ELISA methods for measuring levels of the phosphorylated neurofilament heavy chain. *J Immunol Methods* 2007;319:34–40.
32. Anderson KJ, Scheff SW, Miller KM, et al. The phosphorylated axonal form of the neurofilament subunit NF-H (pNF-H) as a blood biomarker of traumatic brain injury. *J Neurotrauma* 2008;25:1079–1085.
33. Hirano A, Donnenfeld H, Sasaki S, et al. Fine structural observations of neurofilamentous changes in amyotrophic lateral sclerosis. *J Neuropathol Exp Neurol* 1984;43:461–470.
34. Rouleau GA, Clark AW, Rooke K, et al. SOD1 mutation is associated with accumulation of neurofilaments in amyotrophic lateral sclerosis. *Ann Neurol* 1996;39:128–131.
35. Bergeron C, Beric-Maskarel K, Muntasser S, et al. Neurofilament light and polyadenylated mRNA levels are decreased in amyotrophic lateral sclerosis motor neurons. *J Neuropathol Exp Neurol* 1994;53:221–230.
36. Julien JP, Beaulieu JM. Cytoskeletal abnormalities in amyotrophic lateral sclerosis: Beneficial or detrimental effects? *J Neurol Sci* 2000;180:7–14.
37. Shea TB, Paskevich PA, Beermann ML. The protein phosphatase inhibitor okadaic acid increases axonal neurofilaments and neurite caliber, and decreases axonal microtubules in NB2a/d1 cells. *J Neurosci Res* 1993;35:507–521.
38. Gong CX, Wang JZ, Iqbal K, et al. Inhibition of protein phosphatase 2A induces phosphorylation and accumulation of neurofilaments in metabolically active rat brain slices. *Neurosci Lett* 2003;340:107–110.