

UC Davis

UC Davis Previously Published Works

Title

Effect of distal ulnar ostectomy on carpal joint stability during weight bearing in the dog

Permalink

<https://escholarship.org/uc/item/6827t423>

Journal

Veterinary Surgery, 46(8)

ISSN

0161-3499

Authors

Amsellem, Pierre M
Young, Aisha N
Muirhead, Tammy L
[et al.](#)

Publication Date

2017-11-01

DOI

10.1111/vsu.12721

Peer reviewed

ORIGINAL ARTICLE

Effect of distal ulnar ostectomy on carpal joint stability during weight bearing in the dog

Pierre M. Amsellem, Docteur Vétérinaire, Diplomate ACVS and ECVS¹ |

Aisha N. Young, DVM, Diplomate ACVR¹ | Tammy L. Muirhead, DVM² |

LeeAnn Pack, DVM, Diplomate ACVR¹ | Peter Moak, DVM¹ |

Andrea R. Matthews, DVM, Diplomate ACVR³ |

Denis J. Marcellin-Little, DEDV, Diplomate ACVS, Diplomate ACVSMR⁴

¹Department of Companion Animals, Atlantic Veterinary College, University of Prince Edward Island, Charlottetown, PE, Canada

²Department of Biomedical Sciences, Atlantic Veterinary College, University of Prince Edward Island, Charlottetown, PE, Canada

³ANTECH Imaging Services, Los Angeles, California

⁴Department of Clinical Sciences, College of Veterinary Medicine, North Carolina State University, Raleigh, North Carolina

Correspondence

Pierre M. Amsellem, Department of Companion Animals, Atlantic Veterinary College, University of Prince Edward Island, 550 University Avenue, Charlottetown, PE, Canada C1A 3S6. Email: pamsellem@upepei.ca

Funding information

Companion Animal Trust Fund, Atlantic Veterinary College, University of Prince Edward Island, Charlottetown, PE, Canada

Abstract

Objective: To assess the influence of a 50% distal ulnectomy on mediolateral carpal stability in the dog.

Study design: Canine cadaveric study.

Sample population: Seven canine thoracic limbs

Methods: Thoracic limbs were placed in a jig to mimic weight bearing with a load representing 30% of body weight. Carpal extension angle was standardized at $190^\circ \pm 5^\circ$. Frontal plane carpal angles were measured with the limb loaded on cranio-caudal radiographs before and after ulnectomy. Valgus and varus stress radiographs with the limb loaded were acquired before and after ulnectomy. The limbs were palpated and were subjectively graded for valgus or varus instability by 2 investigators before and after ulnectomy.

Results: Mean (\pm SD) valgus angulation increased after ulnectomy ($2.1^\circ \pm 1.7^\circ$; $P = .017$; $CI_{95} = 0.5^\circ$ - 3.7°) when the limb was loaded without valgus or varus stress applied. Mean valgus angulation increased after ulnectomy ($2.7^\circ \pm 2.8^\circ$; $P = .032$; $CI_{95} = -0.2^\circ$ - 5.5°) when valgus stress was applied to the loaded limb. Varus angulation was unchanged after ulnectomy ($0.6^\circ \pm 4.6^\circ$; $P = .383$; $CI_{95} = -4.2^\circ$ - 5.3°) when varus stress was applied to the loaded limb. Palpation detected increased valgus score after ulnectomy.

Conclusion: Distal ulnectomy with excision of the lateral styloid process induces a slight increase in valgus in canine cadaver carpi. The clinical consequences of that valgus on carpal function and health should be assessed in clinical patients.

1 | INTRODUCTION

Canine osteosarcoma accounts for up to 85% of skeletal tumors in dogs.¹ The majority of osteosarcomas affect the thoracic limbs, with 2.6% affecting the ulna.² In one study, 90% of ulnar osteosarcomas involved the distal portion of the bone.³ Distal ulnar osteosarcoma may be amenable to

limb-sparing surgery rather than amputation.^{4,5} Excision of a distal ulnar tumor usually requires excision of the ulnar styloid process to obtain surgical margins free of tumor cells. The ulnar styloid process is the site of origin of the short lateral collateral, the radioulnar, and the palmar ulnocarpal ligaments.⁶ Consequently, one could be concerned that excision of the ulnar styloid process would result in carpal instability,

lameness, and subsequent osteoarthritis. Ulnar osteosarcoma with excision of the styloid process without pancarpal arthrodesis has been reported in 3 dogs.⁵ Subjectively, 2 of these dogs showed no lameness at the time of evaluation 2-3 months after surgery. Information about postoperative limb function was not available for the third case.⁵ In the author's experience, limb function is good after partial ulnectomy, despite excision of the ulnar styloid process. However, carpal stability and limb function after ulnar ostectomy and excision of the ulnar styloid process have not been objectively evaluated. Pancarpal arthrodesis has also been performed in some dogs after distal ulnectomy.⁴

The objective of this study was to assess valgus and varus range of motion (ROM) of the canine carpal joint after distal ulnar ostectomy during weight bearing, using stress radiographs in a cadaveric model. We hypothesized that carpal varus increases after 50% distal ulnectomy due to loss of lateral collateral ligament support across the ulnar carpal joint. We also hypothesized that ulnectomy does not influence carpal valgus.

2 | MATERIAL AND METHODS

2.1 | Inclusion criteria

Dogs, weighing > 20 kg, euthanatized for reasons unrelated to the current study were eligible for inclusion. Cadaveric limbs were excluded if the dogs were chondrodystrophic, skeletally immature, or if pathological or conformational abnormalities were identified on palpation or radiographs.

2.2 | Specimen preparation

The cadaveric limbs were palpated for evidence of deformity or other abnormalities by one of the author (PA) and were disarticulated at the level of the scapula. The limbs were fresh frozen at -21°C and thawed in a water bath at room temperature approximately 8 hours prior to the testing. Orthogonal radiographs of the radius and ulna that included the elbow and carpus were acquired. The soft tissues were transected circumferentially just proximal to the humeral epicondyles and the humerus was osteotomized using an oscillating saw. An approach to the caudal aspect of the proximal ulna was performed.⁷ The antebrachial fascia was incised. The flexor carpi ulnaris was partially elevated to expose the caudal aspect of the proximal ulna. The limb was temporarily secured to a custom-made 20° angled acrylic support using a linear external skeletal fixator (IMEX Veterinary, Longview, Texas). The purpose of the external fixator was to allow repositioning of the limb relative to the acrylic support until a true radiographic craniocaudal (CC) of the carpus was acquired. A 20° angled acrylic support was chosen to follow



FIGURE 1 Picture of a cadaveric forelimb loaded at 30% of the dog's body weight. The 20° acrylic supports can be seen connecting the testing jig to the caudal ulna. The angled support was chosen to follow the natural orientation of the caudal aspect of the ulna and allow for near-vertical loading of the limb

the natural orientation of the caudal aspect of the ulna and allow for near-vertical loading of the limb (Figure 1). The fixator was secured to the distal radius and ulna with 1 full pin in the distal portion of the radius and 1 or 2 additional half-pins in the radius or ulna. The fixator was secured to the acrylic support using a 3-mm diameter pin placed through a premade hole in the acrylic support. Additional stability was obtained by placing the acrylic support flat on the radiographic table. Rotational alignment of the support with the limb was assessed on a CC radiograph. The back of the acrylic support was placed on the table-top cassette and a CC radiograph was acquired (Figure 2). The fixator and the position of the support were modified as needed to achieve a CC radiograph of the carpus was obtained with the back of the support flat on the radiographic cassette. In the frontal plane, the acrylic support was aligned with the long axis of the antebrachium. Frontal plane alignment of the support with the antebrachium was then assessed on radiographs based on the method described by Goodrich et al to assess frontal

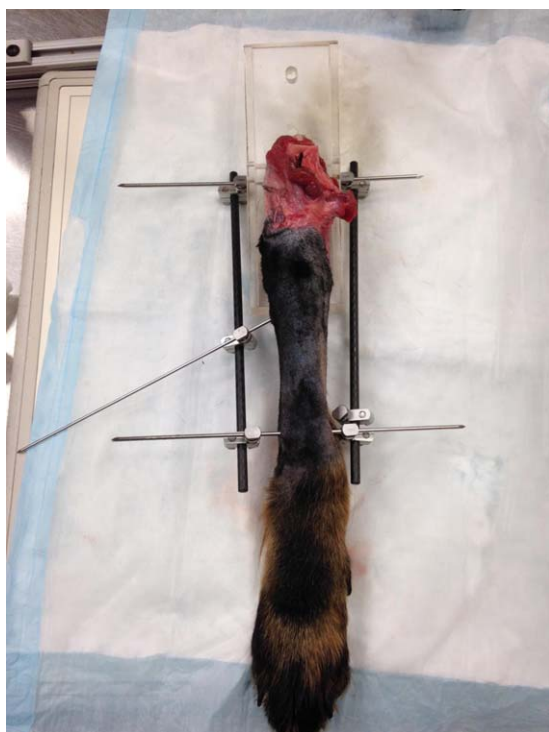

FIGURE 2 Picture of a cadaveric forelimb during initial set up. The limb was temporarily secured to a custom-made 20° angled acrylic support using a linear external skeletal fixator (IMEX Veterinary, Longview, Texas). The fixator was secured to the acrylic support using a 3-mm pin placed through a premade hole in the acrylic support. The purpose of the external fixator was to allow repositioning of the limb relative to the acrylic support until a true radiographic CC of the carpus was acquired. The fixator was removed before testing

plane limb alignment on radiographs.⁸ In our study, the limb was loaded through the acrylic support and not the humerus, therefore, we modified the measurement technique, using the axis of the acrylic support in lieu of the humeral axis described by Goodrich et al.⁸ The acrylic support was then secured to the caudal aspect of the proximal portion of the ulna using four 3.5-mm cortical screws. The external fixator was removed. Radiographs were made to ensure the screws did not penetrate the radius to avoid a potential interference with pronation and supination. The specimen and acrylic support were connected to a weight-bearing jig using 2 screws and washers (Figure 1). The custom-made testing jig was made of T-slotted aluminum tubing (80/20, Columbia City, Indiana). The jig stabilized the limb and allowed weights to be placed on top of it, simulating weight bearing. The manus was placed on a slip-resistant mat. The limb was loaded to 30% of the dog's body weight. The weight calculation accounted for the weight of the apparatus (1.2 kg).

2.3 | Radiographs

The radiographs were made using a horizontal beam cross table with a portable cassette (CXDI-50G, Canon USA,

Melville, New York). The cassette was placed against the caudal aspect of the limb (Figure 3A). The film focus distance was standardized at 1 m and checked before each radiograph. The specimen was secured to the testing jig, the limb was loaded in a standing position with the carpus at approximately 190° and radiographs were acquired. The 190° angle, confirmed using a goniometer, was selected to simulate the initiation of the stance phase in a trotting dog.⁹ Radiographs included the elbow joint and the distal aspect of the metacarpals. Radiographic positioning was assessed based on previous publications aiming at straight lateral or CC radiographs of the carpus.¹⁰ A mediolateral radiographic view was made to measure the carpal extension angle. Carpal extension angle on radiographs was measured by one of the author (AY) using anatomical landmarks described by Jaeger et al.¹¹ Limb positioning was considered acceptable if the carpal extension was $190^\circ \pm 5^\circ$. Two 50-mm long 1.1-mm diameter Kirschner wires (K-wires) were placed roughly parallel to each other (Figure 3A). The K-wires were angled from cranio-latero-proximally to caudo-medio-distally. One was placed in the distal portion of the radius and the other in the third or fourth metacarpal bone (Figure 3B).

CC radiographs included neutral (ie, without varus or valgus stress applied), varus stress, and valgus stress views. Carpal extension was reevaluated after each radiograph using a plastic goniometer to ensure that it was unchanged. Carpal valgus and varus angles were measured on CC radiographic views. The antebrachial axis was drawn between the medial coronoid process and the medial styloid process of the radius. The metacarpal axis was drawn between the long axes of metacarpal bones III and IV (Figure 3B).¹¹

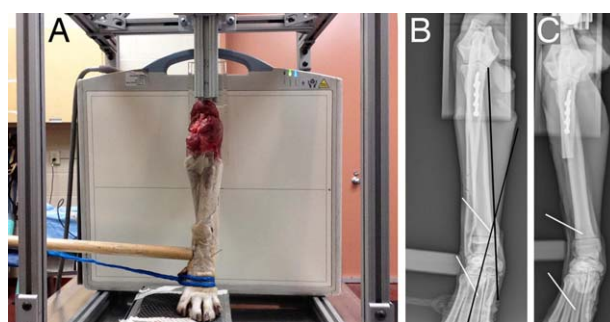


FIGURE 3 A, Picture of a loaded cadaveric forelimb during varus stress radiography. A wooden instrument was centered over the carpal joint. A nylon rope was placed around the phalanges and tension was applied manually by one operator (AY). Two 50-mm long K-wires are visible approximately parallel to each other; one in the radius and one in the third or fourth metacarpal. B, Craniocaudal (CC) radiograph of a pre-ulnectomy loaded specimen during valgus stress. The antebrachial axis was drawn between the medial coronoid process and the medial styloid of the radius. The metacarpal axis was drawn between the long axes of metacarpal bones III and IV. C, CC radiograph of a post-ulnectomy loaded specimen during valgus stress

For stress views, a wooden instrument was centered over the carpal joint. A nylon rope was placed around the phalanges. Tension was applied manually by one operator (AY) medially or laterally, depending on the view (Figure 3A). Force was applied until maximum angulation was subjectively achieved. A force meter (PS 2000 PASPort, PASCO Scientific, Roseville, California) attached to the nylon rope was used to record the force applied at maximal angulation. The same force (measured using the force meter) was then applied on all of the subsequent stressed radiographs for the limb. During stress views, carpal extension, assessed using a plastic goniometer, was maintained at 190° .

Carpal rotation induced during valgus or varus stress of the joint was calculated for all CC radiographs after calibration. To do this, the rotation of each K-wire around the axis of the limb was calculated using the formula:

$$\varphi = \text{Absolute value } \cos^{-1}(\sqrt{(L_1/L_0 - \sin^2\theta)}/\cos \theta)$$

where φ is the rotation of the K-wire around the antebrachial axis as defined above, L_1 is the measured projection of the K-wire on the radiograph in millimeter, L_0 is the true length of the K-wire (50 mm), and θ is the measured angle (Figure 4). The relative rotation of the pins in the radius and in the metacarpal around the limb axis was used to calculate the rotation induced during the stress radiographs. That rotation was compared to the rotation present in the neutral view.

2.4 | Surgical technique and post-ulnectomy radiographs

A 50% distal ulnectomy was performed after removing the specimen from the jig. The screws connecting the support to the jig were removed. The acrylic support and K-wires were left affixed to the limb during the ulnectomy. Partial ulnectomy was performed with the proximal osteotomy just distal to the interosseous ligament and disarticulation of the lateral styloid process, removing approximately 50% of the ulna. An approach to the distal shaft and styloid process of the ulna was performed.⁷ The ulnar periosteum was incised caudal to the ulnaris lateralis tendon, which was preserved. The flexor reticulum was preserved. The interosseous membrane was incised to separate the ulna from the radius and the plane of tissue was followed distally to isolate the distal portion of the ulna while staying as close to the bone as possible. Distally, the joint capsule, the lateral collateral, the radioulnar, and the palmar ulnocarpal ligaments were transected near the lateral styloid process and the ulna was disarticulated and removed.

Following ulnectomy, the support and limb were reattached to the jig in the same position by replacing the screws connecting the support to the jig. This technique maintained the limb position on the jig before and after ulnectomy

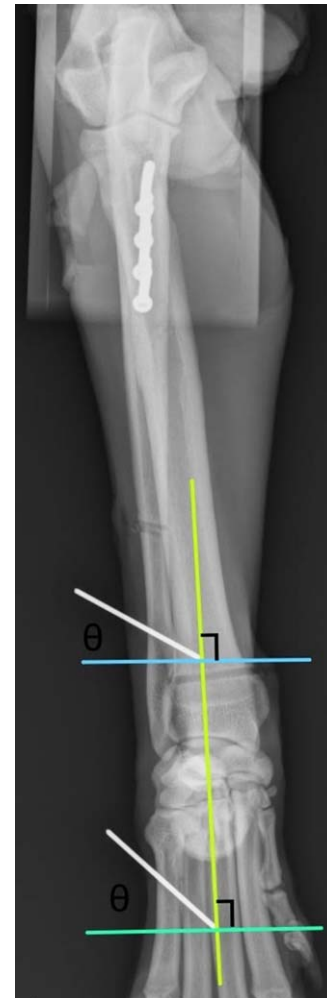

FIGURE 4 Craniocaudal radiograph of a pre-ulnectomy loaded specimen during testing without varus or valgus stress applied (neutral view). The relative rotation of the K-wires in the radius and in the metacarpal around the limb axis were used to calculate the carpal rotation induced during the stress radiographs

(Figure 3C). Carpal extension was reevaluated to be $190^\circ \pm 5^\circ$ using a lateral radiograph. The 3 CC radiographic views described above were repeated after replacing the support on the jig and loading the limb as described above. Carpal angle measurements were made in duplicate by one operator (AY) on all radiographic views and their mean value was used in the analyses.

2.5 | Palpation for ROM in valgus and varus

The limbs were palpated for valgus and varus ROM at maximal extension before and after ulnectomy. ROM was graded based on a 0-2 scale with 0 being palpably normal ROM, 1 mildly increased ROM, and 2 severely increased ROM. Grading was done independently by 2 observers. Observers were not blinded due to the obvious lack of ulna after distal ulnectomy.

2.6 | Data analysis

The results were recorded in a prefabricated datasheet (Excel 2010, Microsoft, Redmond, Washington) and analyzed using a statistical software (JMP 12, SAS, Cary, North Carolina). A paired 2-tailed *t* test was used when comparing pre- and post-ulnectomy neutral testing. A paired 1-tailed *t* test was used to compare pre- and post-ulnectomy when valgus or varus stress was applied. *P* values < .05 were considered significant.

3 | RESULTS

One dog was excluded because of the presence of open physes and 2 dogs were excluded due to abnormal conformation with significant external rotation of the distal portion of the limb. In one dog, the wooden spoon used during post-ulnectomy stress views was placed too distal and these views were excluded. Seven forelimbs (4 left and 3 right limbs) from 6 dogs were included in the study. Median body weight was 28.5 kg (range, 23-41 kg).

The frontal plane angle between the acrylic support and the radius/ulna was measured using the landmarks reported by Goodrich et al for the mechanical axis of the radius/ulna.⁸ The mean \pm SD varus angle between the long axis of the acrylic support and the mechanical axis of the radius ulna in the frontal plane was $4.6^\circ \pm 1.7^\circ$.

Partial ulnectomy was performed without complication except for one dog where the flexor retinaculum was partially cut during the dissection. That retinaculum was sutured prior to testing. Mean valgus angulation increased by $2.1^\circ \pm 1.7^\circ$ after ulnectomy ($P = .017$, $CI_{95} = 0.5^\circ$ - 3.7°) when limbs were loaded without valgus or varus stress applied. When valgus stress was applied to the loaded limbs, mean valgus angulation increased after ulnectomy by $2.7^\circ \pm 2.8^\circ$ ($P = .032$, $CI_{95} = -0.2^\circ$ to 5.5°). When varus stress was applied to loaded limbs after ulnectomy, mean varus angulation did not change significantly ($0.6^\circ \pm 4.6^\circ$, $P = .383$, $CI_{95} = -4.2^\circ$ to 5.3°). Mean carpal rotation induced was $6^\circ \pm 5^\circ$ during valgus stress views and was $6^\circ \pm 6^\circ$ during varus stress views. The rotation induced by valgus stress and varus stress did not differ statistically ($P = .580$, $CI_{95} = -5.0^\circ$ to 6.1°).

Palpation was performed by observer 1 in all 7 limbs and by observer 2 in 5/7 cases. No evidence of varus or valgus was detected in limbs before ulnectomy (score, 0 for all specimens). After ulnectomy, mean \pm SD valgus score increased to 0.9 ± 0.7 ($P = .017$, $CI_{95} = -1.5^\circ$ to -0.2°) and 1.6 ± 0.5 ($P = 0.003$; $CI_{95} = -2.3^\circ$ to -0.9°), respectively, for each observer. No increase in varus was detected during palpation after ulnectomy. The number of observations was too small to compute interobserver agreement.

4 | DISCUSSION

The purpose of this study was to determine the influence of a 50% distal ulnectomy on carpal stability. We designed a testing station to simulate a weight-bearing canine forelimb under load. In standing healthy dogs, each forelimb supports approximately 30% of body weight, although this value varies with the position of the neck.¹² We selected 30% of body weight to load the limbs. Weight-bearing forces in dog forelimbs are transmitted from the humerus through the elbow joint with the radius and ulna each resisting approximately 50% of the load.¹³ Optimally, we would have loaded the humerus to replicate physiologic loading. However, this would be challenging, as the elbow angle varies during testing. We elected to remove the variability associated with the elbow angle and motion by loading the ulna directly. Another possibility of loading the antebrachium would have been to embed the proximal radius and ulna in acrylic, as previously reported.¹⁴ However, we intended to preserve pronation and supination. Loading patterns may differ when comparing antebrachia with an intact ulna to antebrachia with ulnectomy. Indeed, with the distal portion of the ulna missing, loads are likely transmitted through the elbow joint capsule and interosseous ligament to the radius, whereas with an intact ulna, some of the load might be transmitted through the ulna directly to the carpus. It is unclear how this change in loading pattern influences the findings of the current study.

We selected a carpal angle of $190^\circ \pm 5^\circ$ to mimic the carpal angle at foot strike⁹ in a trotting dog since the clinical impact of carpal instability would likely be perceived at the beginning of the stance phase rather than later during stance or during the swing phase of gait. Indeed, if the limb is unstable at foot strike, the animal will likely not load it fully and will develop a lameness. Our initial goal was to test the limbs with weights that would simulate a dog standing, walking, and trotting. Unfortunately, the testing jig was deemed too weak to accommodate the weights simulating a walk or trot. We therefore used weights corresponding to loads resisted by a forelimb when standing only, but maintained the carpal extension angle at the trot to simulate stance. Although this seems conflicting, there is no report of normal carpal angle at a stance in dogs. Furthermore, carpal angle of 190° - 192° has been recommended for pancarpal arthrodesis and thus $190^\circ \pm 5^\circ$ seems adequate for our study.

As part of the surgical approach to the caudal aspect of the ulna to secure the acrylic support, the flexor carpi ulnaris was partially elevated. This approach could lead to carpal hyperextension. However, as the carpal angle was standardized for testing, elevation of this muscle should not have affected our results. Bitton et al¹⁵ reported that carpal extension results in proximal displacement and internal rotation of

the radius in relation to the ulna. In the current study, carpal extension angle was standardized, controlling the radio-ulnar motion that would be resulted from increased extension. In the current loading model, the frontal plane angle between the acrylic support and the mechanical axis of the radius/ulna ($4.6^\circ \pm 1.7^\circ$ of varus) was comparable to the angle at the intersection of the humerus using standing frontal plane radiography in normal Labradors reported by Goodrich et al ($9.1^\circ \pm 2.7^\circ$ of varus). Therefore, the loading angle in our testing platform in the frontal plane was close to the standing angle of standing live dogs. Antebrachial torsion has been shown to affect radiographic measurement of valgus and varus.¹⁶ Piras et al reported that antebrachial rotation of less than 15° resulted in $\leq 5^\circ$ change in valgus measurements.¹⁶ In our study, we attempted to minimize carpal torsion during testing. We elected to place 50-mm long K-wires in the radius and the metacarpals to measure carpal rotation induced during stress views. During our testing, the rotation induced by the stress views as compared to the neutral view was $\leq 15^\circ$ for all results. Consequently, carpal rotation during stress views is unlikely to have affected our results.

Dogs stand with mild carpal valgus.⁸ In our study, we measured a carpal valgus of $2.5^\circ \pm 2.5^\circ$ before ulnectomy. That value is close to the $5.0^\circ \pm 2.5^\circ$ value reported by Goodrich in standing live dogs.⁸ Ulnectomy resulted in a small increase of 2.1° in valgus at a stance that is likely due to the loss of buttress of the ulnar styloid process. When valgus stress was applied after ulnectomy carpal valgus increased 0.6° further. That difference was small and probably without clinical significance. Palpation, although subjective and not blinded, confirmed the presence of valgus instability after ulnectomy. One could have anticipated that ulnectomy with removal of the styloid process and loss of the lateral collateral ligament, would result in an increased in varus. However, increase in varus ROM was not detected after ulnectomy in our model of a standing dog. Similarly, palpation of our specimens did not detect any increase in varus ROM after ulnectomy. It is, however, important to understand that our results were obtained in a model mimicking a standing dog and cannot be extrapolated to the much higher physiologic loads of walking or trotting in live dogs.¹⁷ Our results should thus be interpreted with caution. The lack of significant increase in varus ROM after ulnectomy could also be due to low statistical power, as the sample size was small. Furthermore, there was wider variation in mean varus angulation change (standard deviation = 4.6°) as compared to mean valgus angulation change (standard deviation = 2.8°) after ulnectomy. This could have contributed to the lack of significance in varus testing.

In our study, carpal angle was maintained at $190^\circ \pm 5^\circ$ during testing. In one study, transection of the lateral collateral ligaments resulted in hyperextension of approximately

2° compared to the intact carpus.¹⁴ Ulnectomy with styloid excision essentially results in excision of the lateral collateral ligaments of the carpus and thus is also likely to cause slight hyperextension of the carpus. Additional research could evaluate the influence of carpal extension on frontal plane stability. If carpal extension indeed increases after a distal ulnectomy, it could be useful to increase carpal extension when performing the post-ulnectomy testing to better replicate a clinical situation.

A 50% ulnectomy was performed to simulate a clinical situation of a dog with distal ulnar osteosarcoma. More proximal ulnectomies could result in caudal rotation of the ulna and additional stabilization between the radius and the ulna would possibly be needed. In all cases here, the interosseous ligament was preserved and there caudal tilt of the ulna was not observed. Further research is needed to determine how much proximal ulna can be excised without stabilization.

Our study showed that 50% ulnectomy, including the lateral styloid process, resulted in slight increase in carpal valgus ROM. This could create slight carpal instability in vivo, which could lead to a change in cartilage contact areas in the joint and development of osteoarthritis.¹⁸ Subjectively, limb function has been reported to be adequate in the short term following distal ulnectomy including the styloid process.⁵ However, objective evaluation and long-term assessment have not been reported. Objective lameness evaluation of dogs following partial ulnectomy in dogs using force plate testing would be optimal to correlate our findings with a clinical situation.

ACKNOWLEDGMENT

The authors thank Henrik Stryhn from the University of Prince Edward Island for assistance with statistical analyses.

CONFLICT OF INTEREST

The authors declare no conflict of interest related to this report.

REFERENCES

- [1] Ehrhart NP, Ryan SD, Fan TM. Tumors of the skeletal system. In: Withrow SJ, Vail DM, Page RL, eds. *Withrow and MacEwen's Small Animal Clinical Oncology*. 5th ed. St. Louis, MO: W.B. Saunders Company; 2013:463-503.
- [2] Goldschmidt MH, Thrall DE. Malignant bone tumors in the dog. 1985. Available at http://cal.vet.upenn.edu/projects/saortho/chapter_74/74mast.htm. Accessed August 23, 2017.
- [3] Kistler KR. Canine osteosarcoma: 1462 cases reviewed to uncover patterns of height, weight, breed, sex, age and site involvement. In: Phi Zeta Awards; 1981.
- [4] Massari F, Romanelli G. Limb sparing for distal ulnar osteosarcoma with ulnectomy and pancarpal arthrodesis: 5 cases. In: ECVS Annual Scientific Meeting; 2009.

- [5] Sivacolundhu RK, Runge JJ, Donovan TA, et al. Ulnar osteosarcoma in dogs: 30 cases (1992-2008). *J Am Vet Med Assoc*. 2013;243:96-101.
- [6] Evans E, de Lahunta A. Arthrology. *Miller's Anatomy of the Dog*. 4th ed. St. Louis, MO: W.B. Saunders Company; 2013:158-184.
- [7] Piermattei DL, Johnson KA. The forelimb. *An Atlas of Surgical Approaches to the Bones and Joints of the Dog and Cat*. 5th ed. St. Louis, MO: Elsevier; 2004:268-271.
- [8] Goodrich ZI, Norby B, Eichelberger BM, et al. Thoracic limb alignment in healthy Labrador Retrievers: evaluation of standing versus recumbent frontal plane radiography. *Vet Surg*. 2014;43:791-803.
- [9] Brady RB, Sidiropoulos AN, Bennett HJ, Rider PM, Marcellin-Little DJ, Devita P. Evaluation of gait-related variables in lean and obese dogs at a trot. *Am J Vet Res*. 2013;74:757-762.
- [10] Thrall DE, Robertson ID. The thoracic limb. *Atlas of Radiographic Anatomy and Anatomic Variants in the Dog & Cat*. 1st ed. St. Louis, MO: Elsevier; 2011:69-98.
- [11] Jaegger G, Marcellin-Little DJ, Levine D. Reliability of goniometry in Labrador Retrievers. *Am J Vet Res*. 2002;63:979-986.
- [12] Roy WE. Examination of the canine locomotor system. *Vet Clin North Am*. 1971;1:53-70.
- [13] Mason DR, Schulz KS, Fujita Y, Kass PH, Stover SM. In vitro force mapping of normal canine humeroradial and humeroulnar joints. *Am J Vet Res*. 2005;66:132-135.
- [14] Milgram J, Milshtein T, Meiner Y. The role of the antebrachio-carpal ligaments in the prevention of hyperextension of the antebrachio-carpal joint. *Vet Surg*. 2012;41:191-199.
- [15] Bitton E, Joseph R, Portman L, et al. The effect of extension and loading of the carpus on radial rotation. *Vet Surg*. 2013;42:909-917.
- [16] Piras LA, Peirone B, Fox D. Effects of antebrachial torsion on the measurement of angulation in the frontal plane: a cadaveric radiographic analysis. *Vet Comp Orthop Traumatol*. 2012;25:89-94.
- [17] Rumph PF, Lander JE, Kincaid SA, Baird DK, Kammermann JR, Visco DM. Ground reaction force profiles from force platform gait analyses of clinically normal mesomorphic dogs at the trot. *Am J Vet Res*. 1994;55:756-761.
- [18] Peterson B, Szabo RM. Carpal osteoarthritis. *Hand Clin*. 2006;22:517-528.

How to cite this article: Amsellem PM, Young AN, Muirhead TL, et al. Effect of distal ulnar ostectomy on carpal joint stability during weight bearing in the dog. *Veterinary Surgery*. 2017;00:000-000. <https://doi.org/10.1111/vsu.12721>