

# UC San Diego

## UC San Diego Previously Published Works

### Title

Operative versus non-operative management of pediatric medial epicondyle fractures: a systematic review

### Permalink

<https://escholarship.org/uc/item/6865q30c>

### Journal

Journal of Children's Orthopaedics: Official Journal of the European Paediatric Orthopaedic Society (EPOS), 3(5)

### ISSN

1863-2548

### Authors

Kamath, Atul F.  
Baldwin, Keith  
Horneff, John  
et al.

### Publication Date

2009-10-01

### DOI

10.1007/s11832-009-0192-7

Peer reviewed

# Operative versus non-operative management of pediatric medial epicondyle fractures: a systematic review

Atul F. Kamath · Keith Baldwin · John Horneff ·  
Harish S. Hosalkar

Received: 5 May 2009 / Accepted: 8 July 2009 / Published online: 15 August 2009  
© The Author(s) 2009. This article is published with open access at Springerlink.com

## Abstract

**Purpose** There is ongoing debate about the management of medial epicondyle fractures in the pediatric population. This systematic review evaluated non-operative versus operative treatment of medial epicondyle fractures in pediatric and adolescent patients over the last six decades.

**Methods** A systematic review of the available literature was performed. Frequency-weighted mean union times were used to compare union rates for closed versus open treatments. Moreover, functional outcomes and range-of-motion variables were correlated with varying treatment modalities. Any complications, including ulnar nerve symptoms, pain, instability, infection, and residual deformity, were cataloged.

**Results** Fourteen studies, encompassing 498 patients, met the inclusion/exclusion criteria. There were 261 males and 132 female patients; the frequency-weighted average age was 11.93 years. The follow-up range was 6–216 months. Under the cumulative random effects model, the odds of union with operative fixation was 9.33 times the odds of union with non-operative treatment ( $P < 0.0001$ ). There was no significant difference between operative and non-operative treatments in terms of pain at final follow-up ( $P = 0.73$ ) or ulnar nerve symptoms ( $P = 0.412$ ).

**Conclusions** Operative treatment affords a significantly higher union rate over the non-operative management of medial epicondyle fractures. There was no difference in pain at final follow-up between operative and non-operative treatments. As surgical indications evolve, and the functional demands of pediatric patients increase, surgical fixation should be strongly considered to achieve stable fixation and bony union.

**Keywords** Children · Pediatric · Medial epicondyle humerus fracture(s) · Pediatric elbow fracture · Treatment humerus fracture · Union · Systematic review

## Introduction

Humeral medial epicondyle fracture management in the pediatric population continues to remain a topic of debate. Epidemiologically speaking, they account for nearly 12% of all elbow fractures [1] and are, therefore, not uncommon injuries.

A sub-section of these injuries need operative intervention. The indications for these are well documented and include open fractures and intra-articular incarceration of fractured fragments with an often subluxated elbow [1]. Relative surgical indications include associated ulnar nerve dysfunction and gross elbow instability [2, 3]. What intrigues most clinicians are cases that do not clearly meet the above distinct surgical indications. There is no question that the existing literature, in many ways, is responsible for this dispute. Traditional teaching has been that medial epicondyle fractures may be successfully managed non-operatively with good or excellent functional results, even when healed with fibrous union [4]. In recent years, there is

---

A. F. Kamath · K. Baldwin · J. Horneff  
Department of Orthopaedic Surgery, Hospital of the University  
of Pennsylvania, 3400 Spruce Street, 2nd Floor,  
Silverstein Building, Philadelphia, PA 19104, USA

H. S. Hosalkar (✉)  
Rady Children's Hospital, UCSD,  
3030 Children's way, Suite 410,  
San Diego 92123, CA, USA  
e-mail: hhosalkar@rchsd.org

growing consensus that those fractures that exhibit greater displacement ( $>2$  mm) may benefit from open reduction and internal fixation [5–7], while fractures that are non- or minimally displaced (generally  $<2$  mm) may be treated non-operatively [1, 8] with good functional outcomes. Interestingly, there are several studies which report that the results are not significantly different with surgical and non-surgical modalities of treatment [9–12].

The athletic and functional demands that adolescents and teenagers place on their elbows continue to rise in most parts of the world. Anatomical reduction, early mobilization, and quick, full functional restoration is almost an undeclared expectation from patients, parents, and athletic trainers. Increasingly, patients with high-functional or athletic demands and displaced epicondylar fractures may represent another potential operative indication [1, 13].

Although our understanding of the elbow anatomy and role of its primary and secondary stabilizers has dramatically improved in the past few decades, several questions related to the management of medial epicondyle fractures in the pediatric population remain unanswered: what are the long-term outcomes of treating these fractures with non-operative methods versus operative stabilization? Is there any difference in the rates of bony union with these methods, and, if so, does it really matter? Does the degree of displacement and associated instability matter in decision-making? Are there any specific complications related to either treatment methodologies, and, if so, do they matter in the decision-making?

In the face of technical advancements, evolving surgical indications, and societal pressures, there is little concrete data demonstrating the superiority of either operative or non-operative treatment. Interestingly, from an academic standpoint, this topic begs for a prospective, randomized controlled study. The purpose of this study was to critically examine the outcomes of operative and non-operative treatment of medial epicondyle fractures and to present an evidence-based synthesis of the available literature. We hypothesize that operative fixation of medial humeral epicondyle fractures will be associated with greater union rates than non-operative treatment. We also hypothesize that functional and pain measures from both methods will be acceptable. We suspect, based on the rising interest in this topic, that an increasing trend exists towards the operative treatment of these injuries.

## Methods

We searched the Medline, EMBASE, and Cochrane computerized literature databases from January 1950 to March 2009 for articles using the following search terms: medial epicondyle fracture(s); medial epicondylar fracture(s);

medial apophyseal fracture(s). Reference lists from the articles retrieved were further scrutinized as well to identify any additional studies of interest. All studies from the above-mentioned searches were then reviewed.

Studies were included in this systematic review if they met the following criteria: (1) they were in English, (2) they had a level I–IV study design by *The Journal of Bone and Joint Surgery* criteria (because the majority of studies in the clinical orthopedic literature are retrospective studies of level III–IV evidence, our goal was to be inclusive), (3) patients in the study had a medial epicondyle fracture, (4) there were a minimum of 14 medial epicondyle fracture patients in the study, (5) all patients included in the study were less than 18 years old, or those younger than 18 years if age could be individually analyzed, (6) there was a distinct treatment and/or outcome, and (7) studies were published in or after 1950. Two authors performed the initial search (AK, JH) and three of the authors (AK, KB, JH) independently reviewed the results and selected the appropriate studies based on the above criteria.

We obtained 93 articles from Medline, six from Cochrane, and 110 from EMBASE. Ninety-seven studies were found to be in duplicate among the database searches. This left 112 articles of potential interest. Thirty-six articles were excluded because they did not fulfill the inclusion criteria of having at least 14 pediatric subjects undergoing treatment for medial epicondyle fracture, including case reports and technical articles without extractable data regarding medial epicondyle treatment [9, 14–48]. Twenty-six articles were review articles or epidemiologic or other studies without a primary treatment arm, or were otherwise unable to extract treatment data regarding medial epicondyle fractures [4, 8, 49–72]. Twenty-five articles were excluded for chronic injuries or injuries unrelated to medial epicondyle fractures [73–97]. Seven papers were excluded because they did not fulfill the pediatric population criteria [2, 98–103]. Five articles were primary radiographic articles with no focus on the treatment of medial epicondyle fractures [104–108].

A review of the bibliographies of the 14 remaining studies [3, 5–7, 10–12, 109–115] was done by the reviewing authors, who selected articles to be further evaluated for potential inclusion. Nineteen additional publications were identified via this method and the text of each paper was subsequently reviewed; none of the articles found in this second-level search were able to fulfill the inclusion criteria. Four of these 19 papers were excluded for being review articles [115–118]. Six were excluded because of their publication prior to 1950 [119–124]. Five of these papers had less than 14 subjects in a medial epicondyle treatment group [125–129]. Three of these papers had data that was unable to be extracted for medial epicondylar fractures and were excluded [130–132]. One article

focused on chronic epicondylar fracture management and was excluded [133]. Once all of these exclusions were performed, we were again left with 14 articles that fulfilled all of the inclusion criteria [3, 5–7, 10–12, 109–115].

#### Treatment of fractures

Nine studies included non-operative treatment, which consisted of immobilization, with or without closed reduction of the fragment [3, 5, 10–12, 110–113]. One study managed patients exclusively with closed techniques [11]. A total of 156 patients were treated by non-operative methods. Eight studies had patients treated both by operative as well as non-operative treatment [3, 5, 10, 12, 110–113]. Five studies had patients treated only with operative means [6, 7, 108, 109, 114]. Operative treatments included Kirschner wires [5–7, 10, 12, 108–110, 112–114], screw fixation [5, 7, 12, 109, 111, 112, 114], suture [5, 12, 109–111], excision of the fragment and suturing of the soft tissue to the periosteum of the medial elbow [10], tension band wiring [109, 112], Palmer pins [7, 110], closed reduction and percutaneous pinning [6], or open reduction alone [3]. In total, 321 patients received some type of operative treatment.

#### Indications for surgery

Indications for surgery were varied among the studies investigated. Nine studies did not specify operative indications [3, 5–7, 10–12, 110, 111]. Lee et al. [109] had indications which included fractures with >5 mm of displacement, a positive stress test under anesthesia, or a patient who required a stable elbow for participation in their sport. Two studies performed surgery when the medial epicondyle fracture was associated with dislocation of the humero-ulnar joint [113, 114]. Four studies performed surgery on significantly displaced fractures [11, 108, 112, 113], though significant displacement was variable in its definition. One used ulnar nerve symptoms as an indication for surgery [108]. Fowles et al. [5] did not mention what their indications were, but concluded that surgery was indicated only for patients with intra-articular entrapment of the fragment or significant displacement after closed reduction. While associated elbow dislocation was cataloged in a number of the studies, due to the inconsistent identification of which particular patients suffered dislocations, we were unable to perform subgroup analysis.

#### Statistical analysis

We considered pseudarthrosis, fibrous union, or fibrous non-union as a non-united fracture. Yates' Chi-square test

was used to determine if there were differences in the pooled union rates or pain rates at final follow-up when operative treatment was compared to non-operative treatment. Frequency-weighted means were used to determine the average ages of the patients involved in the study. Ulnar nerve symptoms, deformity, and functional outcomes were analyzed descriptively. Ulnar nerve symptoms were given as an indication for surgery in several studies [e.g., 114], and, hence, it would be inappropriate to apply meta-analytic statistical analysis to them (because, by definition, they would occur more often in the operative group). Deformity was often poorly described and inconsistently documented; as such, we described the findings of the individual studies in our results. Many different definitions of 'excellent' or 'good' outcomes were described for clinical scoring. As such, it would have been inappropriate to pool this data for the purposes of analysis. Funnel plots were also created to assess for publication bias; reasonably symmetric plots were found, so we concluded that no significant publication bias by small study effects existed. We also regressed the number of operative and non-operative patients by year of publication to assess for publication bias by year; this regression found no significant publication bias by year ( $P = 0.890$  and  $0.104$ , respectively), though there was subjectively a decreasing number of patients treated operatively in later years. Methods of fixation, length of follow-up, and other variables were significantly variable between studies; therefore, a random effects model was constructed using the DerSimonian and Laird model to assess the difference in union rates between operative and non-operative patients in studies which included both types, and pain in operative versus non-operative patients in studies which included both types. Meta-analytic statistics were calculated with MIX software (Kitasato Research Center, Sagamihara, Kanagawa, Japan) [134–136]; other statistics were calculated with the SPSS package (version 15.0, SPSS Inc., Chicago, IL).

## Results

### Demographics

We found 14 studies that met all of our inclusion criteria and none of our exclusion criteria. Overall, there were 498 patients with a medial epicondyle fracture. Of those 498, there were 459 who were followed up and had enough data to be included in the individual studies. Table 1 highlights the demographics of the patients in the studies. There were 261 males and 132 female patients; the frequency-weighted average age was 11.93 years. The average follow-up in the various studies ranged between 6 and 216 months.

**Table 1** Demographic characteristics of each study's population

| Authors                          | Year of publication | Total <i>n</i> ( <i>n</i> with adequate f/u)      | Females/males      | Average age, years (range)                 | Average follow-up, months (range)    | Operative treatment (type)   | Non-operative treatment |
|----------------------------------|---------------------|---|--------------------|--|--------------------------------------|--|-------------------------|
| Ip and Tsang [112]               | 2007                | 24 (24)   | 9/15               | 13 (9–17)                                  | 27.4 (22–42)                         | 6 (K-wire, 2 parallel)<br>8 (screw + anti-rotation KW)<br>6 (TBW + 2 parallel KW)                    | 4                       |
| Haxhija et al. [108]             | 2006                | 25 (14)   | 10/15 <sup>a</sup> | 12 (7–15) <sup>a</sup>                     | 36 (12–96) <sup>b</sup>              | 25 (K-wire)  | 0                       |
| Lee et al. [109]                 | 2005                | 25 (25)   | 7/18               | 13.7 (7.5–17.4)                            | 27.2 (19–35)                         | 7 (K-wire)<br>14 (screw ± washer)<br>2 (suture)<br>2 (tension band)                                  | 0                       |
| Farsetti et al. [10]             | 2001                | 42 (42)   | 15/27              | 12 (8–15)                                  | 408 (360–732)                        | 17 (K-wire or T-nail)<br>6 (fragment excision, then suture)  | 19                      |
| Pimpalnerkar et al. [114]        | 1998                | 14 (14)   | 2/12               | 9.7 (6–16)                                 | 17.2 (12–24)                         | 5 (K-wire)<br>7 (screw)  | 0                       |
| Duun et al. [7]                  | 1994                | 33 (33)   | 17/16              | 12 (7–15)                                  | 96 (24–180)                          | 23 (K-wire)<br>1 (screw)<br>3 (suture)<br>6 (Palmer pins)  | 0                       |
| Skak et al. [110]                | 1994                | 23 pts, 24 fxs (23 patients, 24 fxs) <sup>c</sup> | 11/13              | 10.3 (4–14)                                | 86.4 (24–156)                        | 6 (K-wire)<br>5 (suture)<br>10 (Palmer pins) <sup>d</sup>  | 3                       |
| Fowles et al. [5]                | 1990                | 32 (28)   | 5/27 <sup>a</sup>  | 12 (6–16) <sup>a</sup>                     | Non-op.: 17.9 (7–30); op.: 20 (6–28) | 9 patients treated with a screw, suture, or K-wire <sup>c</sup>                                      | 19                      |
| Wilson et al. [12]               | 1988                | 57 (43)   | 17/26              | Non-op.: 11.8 (7–16.2); op.: 12 (7.3–16.1) | 55.2 (18–108)                        | 10 (K-wire)<br>9 (screw)<br>4 (suture)   | 20                      |
| Hines et al. [6]                 | 1987                | 41 (31)   | No data            | 12.7 (7–16)                                | 49.2 (no range)                      | 27 (K-wire)<br>7 (CRPP k-wire)<br>7 [IF (K-wire) s/p arthrotomy for fragment excision <sup>a</sup> ] | 0                       |
| Dias et al. [11]                 | 1987                | 20 (20)   | 14/6               | 13.0 (9–16)                                | 42 (12–84)                           | 0  | 20                      |
| van Niekerk and Severijnen [111] | 1985                | 20 (20)   | 10/10              | 10   | 24 (6–84)                            | 9 (K-wire)<br>1 (suture)   | 9 <sup>f</sup>          |
| Papavasiliou and Crawford [113]  | 1982                | 91 (91)   | 15/76 <sup>g</sup> | 11.5 (5–17)                                | Range 36–216 (no mean given)         | 63 (K-wire)  | 28                      |
| Bede et al. [3]                  | 1975                | 50 (50)   | No data            | 12.5 (6–17.9)                              | 31 (no range)                        | 16 (open reduction only)   | 34                      |
| Summary statistics               |                     | 498/459   | 132/261            | 11.93                                      | 6–216                                | 321  | 156                     |

<sup>a</sup> From initial cohort of patients<sup>b</sup> From final cohort of patients with follow-up<sup>c</sup> Unclear from text how many received each treatment<sup>d</sup> Transepiphyseal (Salter–Harris type II) fracture treated with Palmer nails<sup>e</sup> Twenty-three epicondyle fractures (one chronic) and one distal humeral epiphyseal (Salter–Harris type II) fracture<sup>f</sup> Only 19 of 20 patients had information about treatment<sup>g</sup> No specific numbers given; listed as 5:1 ratio of male to female patients

**Bony union**

Table 2 highlights the findings of each individual study. Two hundred and sixty of 281 (92.5%) patients who received operative treatment had bony union at final follow-up. This was as compared to 60 of 122 (49.2%) patients treated non-operatively. This was statistically significant ( $P < 0.001$ ). Pimpalnerkar et al. found the lowest rate of union in operatively treated fractures. Only six of 14 fractures (43%) went on to union; it is unclear why this was the case in this study. All other union rates for operatively treated medial epicondyle fractures were between 84.6 and 100% [5–7, 10, 12, 109–111, 113]. Non-operatively treated medial epicondyle fractures were associated with union rates of between 0 and 90% [3, 5, 10–12, 110, 111, 113]. Seven studies [5, 10, 12, 110–113] were eligible for pooling, because they had both operative and non-operative patients. Under the cumulative random effects model, the odds of union with operative fixation

was 9.33 (2.54, 34.29) times the odds of union with non-operative treatment ( $P < 0.0001$ ; see Fig. 1).

**Pain**

Thirty-seven of 246 (15%) patients who were operatively treated had pain or tenderness at final follow-up. This compares to ten of 115 (8.7%) patients who were treated non-operatively. The pooled difference in pain post-treatment was not significant ( $P = 0.140$ ). Farsetti et al. had a subgroup of patients treated with excision of the osseous fragment and re-approximation of the soft tissues. Four out of six of these patients had persistent pain and two had osteoarthritis of the elbow [10]. Five studies [5, 10, 12, 111, 113] had both operative and non-operative patients and data about pain at final follow-up. A random effects model was constructed around these five studies. The odds of pain at final follow-up for patients treated operatively was 1.87 (0.21, 16.37) times the odds of those

**Table 2** Union rates and pain post treatment with operative versus non-operative treatment

| Authors                          | Year of publication | Number of patients evaluated | Union op. (n)/total op.       | Union non-op. (n)/total non-op. | Pain at final f/u op.         | Pain at final f/u non-op.       |
|----------------------------------|---------------------|------------------------------|-------------------------------|---------------------------------|-------------------------------|---------------------------------|
| Ip and Tsang [112]               | 2007                | 24                           | 17/20 (85%)                   | 3/4 <sup>c</sup> (75%)          | No data                       | No data                         |
| Haxhija et al. [108]             | 2006                | 14                           | 14/14                         | N/A all had op.                 | 0/14                          | N/A all had op.                 |
| Lee HH et al. [109]              | 2005                | 25                           | 25/25 (100%)                  | N/A all had op.                 | 0/25                          | N/A all had op.                 |
| Farsetti et al. [10]             | 2001                | 42                           | 17/17 <sup>a</sup> (100%)     | 2/19 (10.5%)                    | 5/23                          | 1/19                            |
| Pimpalnerkar et al. [114]        | 1998                | 14                           | 6/14 (43%)                    | N/A all had op.                 | 0/14                          | N/A all had op.                 |
| Duun et al. [7]                  | 1994                | 33                           | 30/33 (91%)                   | N/A all had op.                 | 10/33                         | N/A all had op.                 |
| Skak et al. [110]                | 1994                | 24                           | 20/21 (95%)                   | 0/3 (0%)                        | No data                       | No data                         |
| Fowles et al. [5]                | 1990                | 28                           | 8/9 (89%)                     | 13/19 (68.4%)                   | 0/9                           | 0/19                            |
| Wilson et al. [12]               | 1988                | 43                           | 20/23 (87%)                   | 11/20 (55%)                     | 9/23                          | 1/20                            |
| Hines et al. [6]                 | 1987                | 31                           | 30/31 (97%)                   | N/A all had op.                 | 8/31 <sup>b</sup>             | N/A all had op.                 |
| Dias et al. [11]                 | 1987                | 20                           | N/A all had non-op.           | 0/20 (0%)                       | N/A all had non-op.           | 1/20                            |
| van Niekerk and Severijnen [111] | 1985                | 20                           | 10/11 (91%)                   | 8/9 (89%)                       | 5/11                          | 2/9                             |
| Papavasiliou and Crawford [113]  | 1982                | 91                           | 63/63 (100%)                  | 23/28                           | 0/63                          | 5/28                            |
| Bede et al. [3]                  | 1975                | 50                           | No data <sup>d</sup>          | No data <sup>d</sup>            | No data <sup>d</sup>          | No data <sup>d</sup>            |
| Summary statistics               |                     |                              | 260/281 (92.5%)               | 60/122 (49.2%)                  | 37/246 (15.0%)                | 10/115 (8.7%)                   |
| Adjusted statistics              |                     |                              | DerSimonian Laird OR (95% CI) | 9.33 (2.54, 34.29) <sup>e</sup> | DerSimonian Laird OR (95% CI) | 1.87 (0.21, 16.37) <sup>f</sup> |

<sup>a</sup> The six patients who were treated with excision of the fragment were eliminated because union was not a goal for this surgery and there was nothing to unite

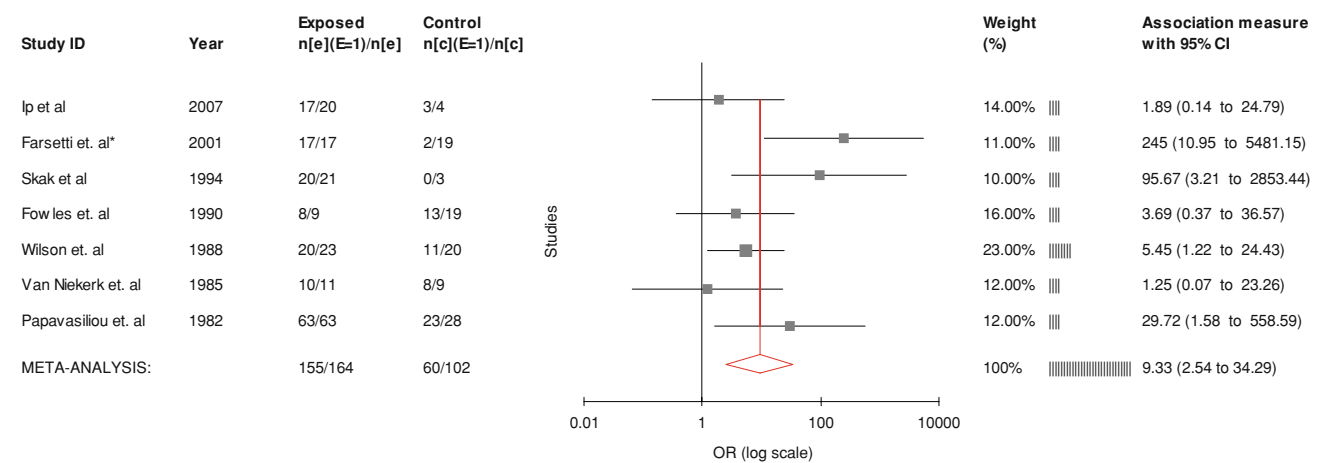
<sup>b</sup> Twelve patients in this study were not examined in person, but instead filled out questionnaires

<sup>c</sup> One patient was initially assigned to the operative group based on displacement but refused surgery

<sup>d</sup> 51.6% of patients had non-union, but were not broken down into operative and non-operative. 2% of patients had tenderness; no data for pain

<sup>e</sup> Based on seven studies that had both operative and non-operative patients with union data, random effects cumulative model

<sup>f</sup> Based on five studies that had data, random effects model



**Fig. 1** DerSimonian and Laird random effects cumulative odds of union with operative treatment versus non-operative treatment. \*Did not include fracture excision patients as union of the fracture was not a goal of treatment

**Table 3** Ulnar nerve symptoms following medial epicondyle fracture

| Authors                          | Ulnar nerve symptoms total (all groups) pre-intervention | Ulnar nerve symptoms total pre-operative | Ulnar nerve symptoms total pre-non-operative | Ulnar nerve symptoms total (all groups) at final follow-up | Ulnar nerve symptoms total at final follow-up, operative | Ulnar nerve symptoms total at final follow-up, non-operative |
|----------------------------------|--|--|--|--|--|--|
| Ip and Tsang [112]               | 1/24   | 1/20                                     | 0/4  | 1/24   | 0/20   | 1/4  |
| Haxhija et al. [108]             | 4/14   | 4/14                                     | All op.                                      | 0/14   | 0/14   | All op.  |
| Lee et al. [109]                 | 0/25   | 0/25                                     | All op.                                      | 0/25   | 0/25   | All op.  |
| Farsetti et al. [10]             | Not specified  | Not specified                            | Not specified                                | 6/42   | 5/23   | 1/19   |
| Pimpalnerkar et al. [114]        | 3/14   | 3/14                                     | All op.                                      | 1/14   | 1/14   | All op.  |
| Duun et al. [7]                  | Not specified  | Not specified                            | All op.                                      | 1/33   | 1/33   | All op.  |
| Skak et al. [110]                | 0/24   | 0/21                                     | 0/3  | 2/24   | 1/21   | 1/3  |
| Fowles et al. [5]                | 5/28   | 5/9                                      | 0/19   | 1/28   | 1/9  | 0/19   |
| Wilson et al. [12]               | 3/43   | 3/23                                     | 0/20   | 0/43   | 0/23   | 0/20   |
| Hines et al. [6]                 | 4/31   | 4/31                                     | All op.                                      | 3/31   | 3/31   | All op.  |
| Dias et al. [11]                 | 2/20   | All non-op.                              | 2/20   | 0/20   | All non-op.  | 0/20   |
| van Niekerk and Severijnen [111] | 1/20   | 1/11                                     | 0/9  | 1/20   | 1/11   | 0/9  |
| Papavasiliou and Crawford [113]  | 4/91   | 4/63                                     | 0/28   | 0/91   | 0/63   | 0/28   |
| Bede et al. [3]                  | 10/50  | Not specified                            | Not specified                                | Not specified  | Not specified  | Not specified  |
| Summary statistics               | 37/384 (9.6%)  | 25/231 (10.8%)                           | 2/103 (1.9%)                                 | 16/409 (3.9%)  | 13/287 (4.5%)  | 3/122 (2.5%)   |

treated non-operatively; this was not statistically significant ( $P = 0.73$ ).

**Ulnar nerve symptoms**

Table 3 highlights the ulnar nerve symptoms reported in each study. For studies which followed ulnar nerve symptoms and specified pre-operative nerve status [3, 5, 6, 11, 12, 108, 109, 111, 113, 114], 37 of 384 (9.6%) patients had ulnar nerve symptoms. Twenty-five of 231 (10.8%) patients

treated operatively had ulnar nerve symptoms pre-operatively; two of 103 (1.9%) patients treated non-operatively had ulnar nerve symptoms pre-operatively. At final follow-up, 16 of the 409 (3.9%) total number of patients, 13 of 287 (4.5%) patients treated operatively, and three of 122 (2.5%) patients treated non-operatively had ulnar nerve symptoms. The difference was not statistically significant ( $P = 0.412$ ). Some authors treated patients with ulnar nerve transposition intra-operatively [5], while others did not routinely perform this treatment.

## Functional outcomes

Eight studies reported functional outcomes in either outcome scores or by categorizing patients as ‘excellent,’ ‘good,’ ‘fair,’ or ‘poor’ based on various criteria. Haxhija et al. [108] used the criteria of axial deviation less than 9°, range-of-motion deficiency of less than 19°, minimal strength or functional loss, and no pain as their criteria for a good or excellent outcome; all patients in their study underwent open reduction and internal fixation with K-wires. Lee et al. used the Elbow Assessment Score of the Japanese Orthopedic Association, a 100-point score where 100 points corresponds to the best possible score. At final follow-up, the average score was 96.2 points (89–100). These authors used K-wires, screws, tension band wire, or suture to fix their fractures [109]. Farsetti et al. used the criteria of no symptoms, no atrophy, no osteoarthritis, negative valgus stress, and less than 10° motion loss as their criteria for good or excellent results. Sixteen of 19 non-operative patients and 15 of 17 operative patients had a good result. The remainder of the patients in these two groups had a fair result. Six patients were treated with excision of the osseous fragment and the repair of soft tissues. This was associated with two of six fair results and four of six poor results [10]. Bede et al. [3] classified results as good if, subjectively, the elbow was functional, pain-free, and free from instability or deformity, and, objectively, the range of motion was limited by 15° or less, there was less than 6° of cubitus valgus, and no ulnar neuritis. If these criteria were not met, the result was considered to be poor. Bede et al. [3] found that ten of 16 patients who had operative treatment had good results, compared to 27 of 34 patients who had non-operative treatment. The remainder of the results was poor. Hines et al. also used Bede’s criteria. However, they found 23 of 24 of their operatively treated patients to have experienced good outcomes [6]. The patient who did not have a good outcome was reported to have had a painful non-union [6]. Skak et al. [110] defined excellent outcomes as full range of motion, normal appearance, and no symptoms; good outcome as less than 15° of range of motion loss, minor deformity, and no arthritic or neurologic symptoms; poor outcome included disabling loss of motion, noticeable deformity, or any arthritic or neurologic symptoms. Eighteen of 21 of their operatively treated patients and two of three of non-operatively treated patients had good or excellent outcomes. The outcome was poor in the remainder of the patients [110]. The poor results were due to ulnar neuritis in two patients, an extension lag in one patient, and deformity due to a concomitant lateral condyle fracture [110]. Ip and Tsang [112] used the Mayo Clinic Score, which has 45 points for pain, 10 points for stability, 20 points for range of motion, and 25 points for activities of daily living. Four patients were treated conservatively; their

Mayo scores at follow-up ranged from 90 to 100 (average 96.25). Overall, patients who underwent operative treatment had Mayo scores that ranged from 80 to 100 (average 93) [112].

## Range of motion or strength restriction

Haxhija et al. [108] had two operative patients with flexion deficits of 5° at 1 year and one with 10° of flexion deficit; two patients had slight loss of strength. Bede et al. [3] reported 71% of patients with limited range of motion, though what was specifically meant by this was not indicated. The series by Fowles et al. [5] noted that eight of 19 patients treated non-operatively lost an average of 15° of elbow range of motion, and six of nine patients lost an average of 37° of range of motion. Dias et al. [11] found that eight of 20 patients lost less than 20° of flexion or extension and one lost more than 20°. Wilson et al. [12] found that two of 23 of their operative patients and six of 20 of their non-operative patients lost greater than 10° of extension, though this was not significantly different. Papavasiliou and Crawford [113] reported no loss of range of motion or strength in any patient. Hines et al. [6] only noted loss of motion (of less than 15°) in patients who required arthrotomy to remove the osseous fragment; the remainder of their operative and non-operative patients did not lose significant motion. Farsetti et al. [10], in their long-term follow-up, found two non-operative patients with limitations of elbow extension of 5 and 10°, two internal fixation patients with limitations of 5 and 20°, and one patient who had excision of their fragment with loss motion of 30° of extension. One of these non-operative patients had 1.5 cm of forearm atrophy; four patients who had excision of the fragment had 1–3.5 cm of forearm atrophy, and three lost grip strength [10]. In the van Niekerk and Severijnen [111] series, two non-operatively treated patients lost 5° of extension, and three patients had a loss of strength. Seven operative patients lost between 4 and 18° of motion, and three lost strength. Pimpalnerkar et al. [114] found that nine of 14 operative patients lost 5–15° of extension (mean 6.4°) at a mean follow-up of 17.2 months. Lee et al. [109] reported only one patient who had decreased motion post-operatively (arc of motion 110°). Duun et al. [7] reported that seven of their operatively treated patients lost extension (5–25°), one lost supination (10°), and two lost flexion (5°). Ip and Tsang [112] reported no loss in motion or strength in either operatively treated or non-operatively treated patients.

## Deformity

Haxhija et al. [108] had one patient with slight valgus deformity of 14° compared to the contralateral elbow (11°).



Bede et al. [3] reported 35.5% cubitus valgus, though the specific parameters for this deformity were not indicated. Wilson et al. [12] found no cubitus valgus in any patient treated operatively or non-operatively. Hines et al. [6] had two of 19 patients with significant valgus deformity (15–20°) post-operatively; both of these patients required excision of the intra-articular osseous fragment, followed by internal fixation. Farsetti et al. [10], in their long-term follow-up, found two patients with a valgus deformity. Of interest, only two of 19 non-operative fractures united; one resulted in a carrying angle of 32°. Skak et al. reported on a variety of deformities, which ranged from radiologic findings such as double-contoured epicondyle, ulnar sulcus, pseudarthrosis, hypoplasia, or hyperplasia. Only one of these was classified as severe and was due to avascular necrosis of the trochlea. This patient had a concomitant lateral condyle fracture [110]; the investigators were unable to correlate the deformity to a specific treatment. Lee et al. [109], Pimpalnerkar et al. [114], Papavasiliou and Crawford [113], and van Niekerk and Severijnen [111] did not report any valgus deformities. Ip and Tsang [112] reported one patient treated with K-wires who developed cubitus varus and a patient with a displaced fracture who refused surgery who developed cubitus valgus. In the Duun et al. [7] series of operatively managed medial epicondyle fractures, one patient had a valgus deformity of 5°.

### Complications

Eight studies reported no complications related to the treatment of the medial epicondyle fracture which were not previously discussed in other sections of this paper [7, 11, 108–111, 113, 114]. Bede et al. [3] reported one patient with septic arthritis post-operatively and one patient with myositis ossificans. Wilson et al. [12] had two wound infections in their operative group and one keloid scar. One patient in Hines et al.'s [6] series of operatively treated fractures had pins which missed the fracture fragment; this patient had valgus instability post-operatively. Three patients in the same series had pin-tract infections that resolved with antibiotics and local wound care [6]. One patient from the Ip and Tsang [112] series had tension band wire and K-wires that developed a superficial wound infection.

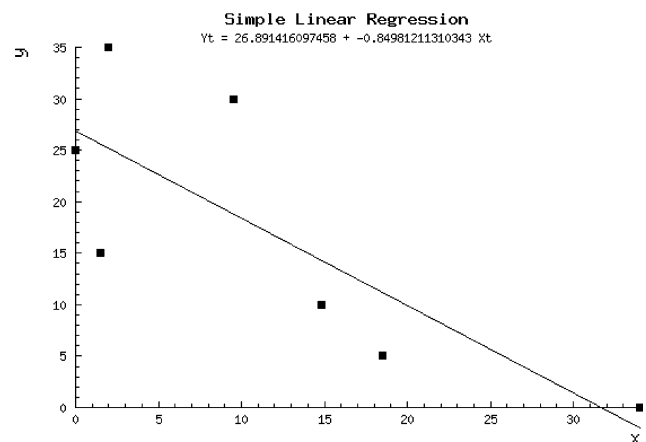
### Discussion

The management of medial epicondyle fractures in the pediatric population continues to be a topic of deliberation. We embarked on this systematic review to synthesize the available data and to aid the clinician's decision-making process based on existing evidence. The purpose of this

study was to answer the following questions: What are the long-term outcomes of treating these fractures with non-operative methods versus operative stabilization? Is there any difference in the rates of bony union with these methods, and, if so, does it really matter? Does the degree of displacement and associated instability matter in decision-making? Are there any specific complications related to either treatment methodologies, and, if so, do they matter in the decision-making?

Non-operative management of these fractures has reported problems, including unrecognized incarcerated fragment, ulnar nerve dysfunction (10–16%, but up to 50% with an incarcerated fragment), tardy ulnar neuritis, malunion, loss of terminal extension, and discord between the patient and family expectations for high-functional activity and ultimate functional result [1, 13, 45]. Operative fixation has increased in most centers despite the lack of particular scientific evidence that patients do better with anatomic reduction. Anatomic, stable fixation remains a possible, albeit not yet proven, advantage in athletics and sports with heavy demand on the dominant elbow. Ironically, in spite of the scarcity of data, there exists a trend of decreasing numbers of non-operative cases/published series per 5-year period since the Bede study in the 1970s (Fig. 2).

One possible explanation for this is that, under the cumulative random effects model in this study, the odds of union with operative fixation was 9.33 times the odds of union with non-operative treatment ( $P < 0.0001$ ). Anatomic reduction is ensured with open reduction and internal fixation; therefore, it is not surprising that bony union was significantly different between operative and non-operative treatment. What is the significance of superior bony union afforded by surgical intervention? From the available data,



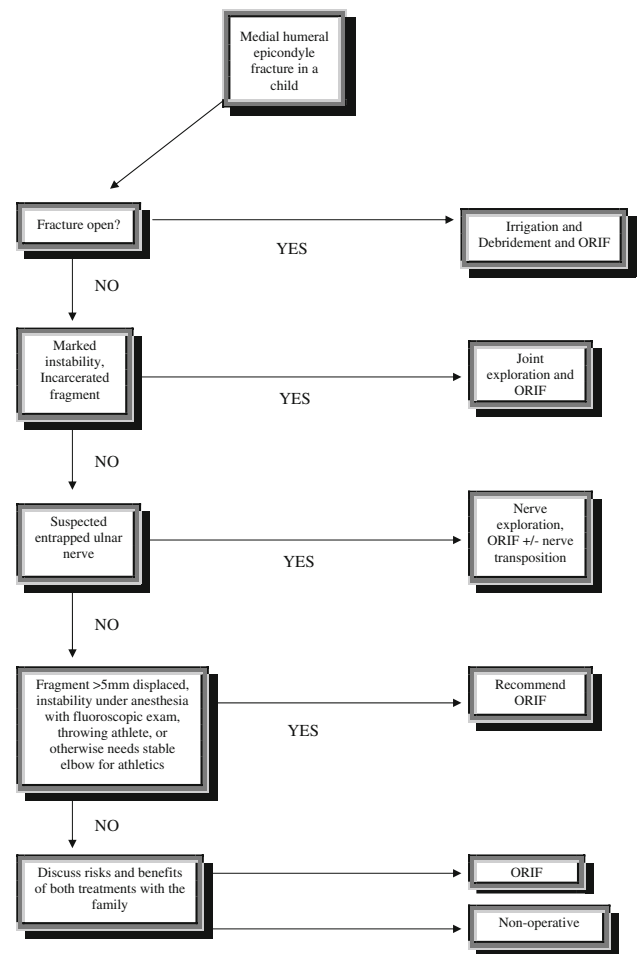
**Fig. 2** Year of publication regressed against the number of non-operative patients over the number of studies for each 5-year period. x-axis = year of publication; y-axis = number of patients/number of studies

one can only hypothesize that operative fixation may impart advantages from direct fracture reduction, restoration of the elbow anatomy and soft-tissue tension, protecting vital structures, including the ulnar nerve, and minimizing the risks of early or late re-displacement of the fracture fragment.

Historically, the purported benefits of closed treatment were satisfactory functional outcome without necessary bony union. Fibrous union alone provided satisfactory functional results in some studies [4], while other studies mention the occurrence of painful non-unions in these fractures. Proponents of surgical fixation, therefore, might point to patient dissatisfaction with late deformity, persistent stiffness, or recurrent instability as reasons for early surgical intervention. Importantly, operative fixation was found to provide a higher union rate, while both pain symptoms and ulnar nerve complications were not significantly different between the non-operative and operative groups.

Undoubtedly, there is subtle variation between study populations that may account for heterogeneous union rates, even among similar operative treatment modalities. Moreover, there is a baseline risk (that is not zero) of mal- or non-union, even with anatomic intra-operative bony apposition. Nevertheless, it is important to ask, then, why some non-unions resulted from operative treatment among the included studies. One possible explanation is that the use of K-wires or smooth pins for fixation could not achieve adequate compression in these failed cases (as this is mainly an avulsion injury that has a continued distractive muscular force across the fracture at all times). One can only hypothesize that those cases may have done better with compression fixation in terms of union.

One of the difficulties with discerning the treatment of this injury is the disparate classifications. Smith [130] originally described five types: 1: not apparent on X-ray, 2: minimally displaced, 3: significantly displaced, 4: incarcerated, and 5: a fracture of the medial humeral epicondyle in adults. Papavasiliou and Crawford [113] used a classification which is more often used today: Type 1: small degree of avulsion, Type 2: avulsed fragment at the level of the joint but not entrapped, Type 3: the fragment is incarcerated in the joint, and Type 4: associated with elbow dislocation. Since this classification system is somewhat unclear, the definition of type 1 and type 2 fractures varies between studies. This makes synthesis of the literature difficult, and also makes the indication of ‘displaced fracture’ somewhat confusing. Because of the lack of prospective comparative data, and the perceived benefit of increased elbow stability with bony union, the most plausible indications for surgical fixation seem to be ones suggested by Lee et al. [109]: fractures with >5 mm of displacement, a positive stress test under anesthesia, or a



**Fig. 3** Proposed management algorithm for medial humeral epicondyle fractures

patient who requires a stable elbow for participation in their sport (Fig. 3).

Over the last several decades, our understanding of the complexities of elbow anatomy and medial epicondyle injuries/fractures has changed dramatically. Medial epicondyle injuries were traditionally considered as benign and insignificant extra/peri-articular fractures of the distal humerus. As we have furthered our understanding about elbow stability and the importance of full range of motion in elbow biomechanics, perspectives towards the treatment and management of these injuries are changing and will continue to change. Functional demand and athletic performance, which is increasingly the norm of today, were not clearly considered in many of the earlier studies. The intensity and duration of modern day sporting activities that push the functional demand of the elbow and shoulder to its maximum necessitate stable mechanics for optimal performance. The goals with operative fixation certainly are to maximize the possibility of early return to full function and high-level activity, and to minimize late

deformity and the likelihood of stiffness (as with prolonged cast immobilization).

There are limitations in this study. We did not have access to much of the raw data for each study, which, in some ways, limited our analysis or prevented further stratification, including outcome according to operative treatment type. A systematic review of this nature is inherently limited by the heterogeneity of the individual studies in terms of range of motion analysis, outcome scoring systems, and cataloging of complications. Furthermore, problems with inference, including bias, confounding, and random chance inherent to the individual observational studies utilized in this review are not improved by pooling the data. Previous studies disagreed on how much displacement was acceptable, which makes it difficult to comment on the degree of displacement itself as an indication for surgery.

In summary, while the treatment of pediatric medial epicondyle fractures with open injuries, incarcerated fragments, and unstable elbows is not in question, further studies are necessary to determine the optimal treatment for patients with displaced and non-displaced fractures. Long-term data from the Farsetti et al. [10] study point to devastating results with medial epicondyle fragment excision. Our understanding of the role of the medial epicondylar fragment in overall elbow stability continues to evolve, and the effect of painful, symptomatic non-union is a real, although poorly understood, phenomenon.

Although we provide an algorithm based on this systematic review (Fig. 3), it is based on level III–IV evidence. Because there is ongoing debate over what constitutes the optimal treatment for type I and II fractures, a randomized controlled trial is both ethical and indicated. Operative treatment offers a superior rate of bony union when compared to non-operative care. In the pooled data, there was no difference in pain at final follow-up between both the operative and non-operative groups. Likewise, there was no statistically significant increase in the incidence of ulnar nerve complications with operative management. As the functional demands of young patients increase, the relative indications for surgical fixation must be carefully weighed.

**Conflict of interest statement** There were no grants or external sources of funding utilized for this study.

**Open Access** This article is distributed under the terms of the Creative Commons Attribution Noncommercial License which permits any noncommercial use, distribution, and reproduction in any medium, provided the original author(s) and source are credited.

## References

1. Wilkins KE (1991) Fractures involving the medial epicondylar apophysis. In: Rockwood CA Jr, Wilkins KE, King RE (eds) *Fractures in Children*, 3rd edn. JB Lippincott, Philadelphia
2. Woods GW, Tullos HS (1977) Elbow instability and medial epicondyle fractures. *Am J Sports Med* 5:23–30
3. Bede WB, Lefebvre AR, Rosman MA (1975) Fractures of the medial humeral epicondyle in children. *Can J Surg* 18:137–142
4. Josefsson PO, Danielsson LG (1986) Epicondylar elbow fracture in children. 35-year follow-up of 56 unreduced cases. *Acta Orthop Scand* 57:313–315
5. Fowles JV, Slimane N, Kassab MT (1990) Elbow dislocation with avulsion of the medial humeral epicondyle. *J Bone Joint Surg Br* 72:102–104
6. Hines RF, Herndon WA, Evans JP (1987) Operative treatment of medial epicondyle fractures in children. *Clin Orthop Relat Res* 223:170–174
7. Duun PS, Ravn P, Hansen LB, Buron B (1994) Osteosynthesis of medial humeral epicondyle fractures in children. 8-year follow-up of 33 cases. *Acta Orthop Scand* 65:439–441
8. Schwab GH, Bennett JB, Woods GW, Tullos HS (1980) Biomechanics of elbow instability: the role of the medial collateral ligament. *Clin Orthop Relat Res* 146:42–52
9. Case SL, Hennrikus WL (1997) Surgical treatment of displaced medial epicondyle fractures in adolescent athletes. *Am J Sports Med* 25:682–686
10. Farsetti P, Potenza V, Caterini R, Ippolito E (2001) Long-term results of treatment of fractures of the medial humeral epicondyle in children. *J Bone Joint Surg Am* 83-A(9):1299–1305
11. Dias JJ, Johnson GV, Hoskinson J, Sulaiman K (1987) Management of severely displaced medial epicondyle fractures. *J Orthop Trauma* 1:59–62
12. Wilson NI, Ingram R, Rymaszewski L, Miller JH (1988) Treatment of fractures of the medial epicondyle of the humerus. *Injury* 19:342–344
13. Hutchinson MR, Ireland ML (2003) Overuse and throwing injuries in the skeletally immature athlete. *Instr Course Lect* 52:25–36
14. Partio EK, Hirvensalo E, Böstman O, Rokkanen P (1996) A prospective controlled trial of the fracture of the humeral medial epicondyle—how to treat? *Ann Chir Gynaecol* 85(1):67–71
15. Mäkelä EA, Böstman O, Kekomäki M, Södergård J, Vainio J, Törmälä P, Rokkanen P (1992) Biodegradable fixation of distal humeral physeal fractures. *Clin Orthop Relat Res* 283:237–243
16. Kilfoyle RM (1965) Fractures of the medial condyle and epicondyle of the elbow in children. *Clin Orthop Relat Res* 41:43–50
17. Rasool MN (2004) Dislocations of the elbow in children. *J Bone Joint Surg Br* 86(7):1050–1058
18. Hope PG, Williamson DM, Coates CJ, Cole WG (1991) Biodegradable pin fixation of elbow fractures in children. A randomised trial. *J Bone Joint Surg Br* 73(6):965–968
19. Chim H, Yam AK, Teoh LC (2007) Elbow ganglion arising from medial epicondyle pseudarthrosis. *Hand Surg* 12(3):155–158
20. Schwartz ML, Thornton DD, Larrison MC, Cain EL, Aaron DG, Wilk KE, Andrews JR (2008) Avulsion of the medial epicondyle after ulnar collateral ligament reconstruction: imaging of a rare throwing injury. *AJR Am J Roentgenol* 190(3):595–598
21. Bajracharya S, Singh MP, Singh GK, Nepal P (2007) Complex elbow dislocation with ipsilateral segmental fracture of radius and ulna in a young boy: a complex injury with multiple fractures. *JNMA J Nepal Med Assoc* 46(165):36–39
22. Darlis NA, Kotsovolos ES, Zalavras CG, Mavrodiondis AN (2004) Ipsilateral radial shaft, head, and medial epicondyle fractures. *J Orthop Trauma* 18(4):238–240
23. Gilchrist AD, McKee MD (2002) Valgus instability of the elbow due to medial epicondyle nonunion: treatment by fragment excision and ligament repair—a report of 5 cases. *J Shoulder Elbow Surg* 11(5):493–497
24. Sinha S, Naik M, Rai RK, Rifai R, Campbell AC (2002) A new technique for treatment of medial epicondyle fracture with displacement into the elbow joint. *Injury* 33(3):269–270

25. Takeishi H, Oka Y, Ikeda M (2001) Reconstructing an unstable medial elbow complicated by medial epicondyle non-union: case report. *Tokai J Exp Clin Med* 26(2):77–80
26. May DA, Disler DG, Jones EA, Pearce DA (2000) Using sonography to diagnose an unossified medial epicondyle avulsion in a child. *AJR Am J Roentgenol* 174(4):1115–1117
27. Kobayashi Y, Oka Y, Ikeda M, Munasada S (2000) Avulsion fracture of the medial and lateral epicondyles of the humerus. *J Shoulder Elbow Surg* 9(1):59–64
28. Spinner RJ, O'Driscoll SW, Davids JR, Goldner RD (1999) Cubitus varus associated with dislocation of both the medial portion of the triceps and the ulnar nerve. *J Hand Surg Am* 24(4):718–726
29. Clarke MD, Hobbs CM, Bowyer GW (1998) Greatly delayed complication of medial epicondyle injury. *Injury* 29(8):636–639
30. Ogawa K, Ui M (1996) Fracture-separation of the medial humeral epicondyle caused by arm wrestling. *J Trauma* 41(3):494–497
31. al-Qattan MM, Zuker RM, Weinberg MJ (1994) Type 4 median nerve entrapment after elbow dislocation. *J Hand Surg Br* 19(5):613–615
32. Nyska M, Peiser J, Lukiec F, Katz T, Liberman N (1992) Avulsion fracture of the medial epicondyle caused by arm wrestling. *Am J Sports Med* 20(3):347–350
33. Low BY, Lim J (1991) Fracture of humerus during armwrestling: report of 5 cases. *Singapore Med J* 32(1):47–49
34. Lokiec F, Velkes S, Engel J (1991) Avulsion of the medial epicondyle of the humerus in arm wrestlers: a report of five cases and a review of the literature. *Injury* 22(1):69–70
35. Hendel D, Aghasi M, Halperin N (1985) Unusual fracture dislocation of the elbow joint. *Arch Orthop Trauma Surg* 104(3):187–188
36. Pritchett JW (1984) Entrapment of the median nerve after dislocation of the elbow. *J Pediatr Orthop* 4(6):752–753
37. Moon MS, Kim I, Han IH, Suh KH, Hwang JD (1980) Arm wrestler's injury: report of seven cases. *Clin Orthop Relat Res* 147:219–221
38. Matev I (1976) A radiological sign of entrapment of the median nerve in the elbow joint after posterior dislocation. A report of two cases. *J Bone Joint Surg Br* 58(3):353–355
39. Gupta JD, Jackson M, Neitzschman HR (2006) Radiology case of the month: increasing elbow pain and swelling in a 14-year-old baseball pitcher. Medial humeral epicondylar avulsion fracture. *J La State Med Soc* 158(4):169–170
40. Kikuchi Y, Horiuchi Y, Ichikawa T (2004) Unrecognized fracture of the medial epicondylar apophysis of the humerus. *J Shoulder Elbow Surg* 13(3):356–361
41. Buckley SC, Patil P, Allerton K (2000) Spontaneous reduction of a fractured medial epicondylar fragment. *Injury* 31(2):119–120
42. Tayob AA, Shively RA (1980) Bilateral elbow dislocations with intra-articular displacement of the medial epicondyles. *J Trauma* 20(4):332–335
43. McCarthy TA, Mullett H, McMahon B (2001) An unusual lump at the elbow. *Eur J Orthop Surg Traumatol* 11(2):127–128
44. Haugegaard M, Rasmussen SW, Jensen P (1993) Avulsion fracture of the medial humerus epicondyle in young wrestlers. *Scand J Med Sci Sports* 3(3):178–181
45. Fowles JV, Kassab MT, Moula T (1984) Untreated intra-articular entrapment of the medial humeral epicondyle. *J Bone Joint Surg Br* 66(4):562–565
46. Dangles C, Tylkowski C, Pankovich AM (1982) Epicondylar fracture of the humerus before appearance of the ossification center. A case report. *Clin Orthop Relat Res* 171:161–163
47. Kolar I, Keretic D (2006) Osteosynthesis with biodegradable polydioxanon pins versus metal K-wires in displaced fractures of lateral condyle, medial epicondyle and medial condyle in the child's elbow. A prospective randomised study. *J Bone Joint Surg Br* 88:121 (abstract)
48. Szymańska E (1997) Evaluation of AO kit screw fixation of medial condyle and epicondyle distal humeral epiphyseal fractures in children. *Ann Acad Med Stetin* 43:239–253
49. Shrader MW (2008) Pediatric supracondylar fractures and pediatric physeal elbow fractures. *Orthop Clin North Am* 39(2):163–171 (v. review)
50. Hughes PE, Paletta GA Jr (2003) Little leaguer's elbow, medial epicondyle injury, and osteochondritis dissecans. *Sports Med Arthrosc Rev* 11(1):30–39
51. Cain EL Jr, Dugas JR, Wolf RS, Andrews JR (2003) Elbow injuries in throwing athletes: a current concepts review. *Am J Sports Med* 31(4):621–635 (review)
52. Kocher MS, Waters PM, Micheli LJ (2000) Upper extremity injuries in the paediatric athlete. *Sports Med* 30(2):117–135 (review)
53. Papandrea R, Waters PM (2000) Posttraumatic reconstruction of the elbow in the pediatric patient. *Clin Orthop Relat Res* 370:115–126 (review)
54. Ring D, Jupiter JB, Gulotta L (2003) Articular fractures of the distal part of the humerus. *J Bone Joint Surg Am* 85-A(2):232–238
55. Silberstein MJ, Brodeur AE, Graviss ER, Luisiri A (1981) Some vagaries of the medial epicondyle. *J Bone Joint Surg Am* 63(4):524–528
56. Micheli LJ, Santore R, Stanitski CL (1980) Epiphyseal fractures of the elbow in children. *Am Fam Physician* 22(5):107–116
57. Loomer RL (1982) Elbow injuries in athletes. *Can J Appl Sport Sci* 7(3):164–166
58. Tashjian RZ (2007) Adolescent elbow injuries. *Curr Opin Orthop* 18(4):403–410
59. Fowles JV, Rizkallah R (1976) Intra-articular injuries of the elbow: pitfalls of diagnosis and treatment. *Can Med Assoc J* 114(2):125–131
60. Townsend DJ, Bassett GS (1996) Common elbow fractures in children. *Am Fam Physician* 53(6):2031–2041 (review)
61. Gicquel P, Giacomelli MC, Karger C, Clavert JM (2005) Treatment of epiphyseo-metaphyseal fractures in children with an original implant. The threaded pin with an adjustable lock (Fixano). *Oper Orthop Traumatol* 17(1):51–65 (English, German)
62. John SD, Wherry K, Swischuk LE, Phillips WA (1996) Improving detection of pediatric elbow fractures by understanding their mechanics. *Radiographics* 16(6):1443–1460 (quiz 1463–4)
63. Sponseller PD (1994) Problem elbow fractures in children. *Hand Clin* 10(3):495–505
64. Henrikus WL (2006) Elbow disorders in the young athlete. *Oper Tech Sports Med* 14(3):165–172
65. Kocher MS, Andersen J (2006) MCL reconstruction in the pediatric athlete's elbow. *Tech Orthop* 21(4):299–310
66. Tien YC, Chen JC, Fu YC, Chih TT, Huang PJ, Wang GJ (2006) Supracondylar dome osteotomy for cubitus valgus deformity associated with a lateral condylar nonunion in children. Surgical technique. *J Bone Joint Surg Am* 88(Suppl 1 Pt 2):191–201
67. Klingele KE, Kocher MS (2002) Little league elbow: valgus overload injury in the paediatric athlete. *Sports Med* 32(15):1005–1015
68. Gerwin M, Hotchkiss RN, Weiland AJ (1996) Alternative operative exposures of the posterior aspect of the humeral diaphysis: with reference to the radial nerve. *J Bone Joint Surg Am* 78(11):1690–1695

69. Biyani A, Gupta SP, Sharma JC (1993) Determination of medial epicondylar epiphyseal angle for supracondylar humeral fractures in children. *J Pediatr Orthop* 13(1):94–97
70. Landin LA, Danielsson LG (1986) Elbow fractures in children. An epidemiological analysis of 589 cases. *Acta Orthop Scand* 57(4):309–312
71. Chessare JW, Rogers LF, White H, Tachdjian MO (1977) Injuries of the medial epicondylar ossification center of the humerus. *AJR Am J Roentgenol* 129(1):49–55
72. Carlouz H, Abols Y (1984) Posterior dislocation of the elbow in children. *J Pediatr Orthop* 4(1):8–12
73. Fahey JJ, O'Brien ET (1971) Fracture-separation of the medial humeral condyle in a child confused with fracture of the medial epicondyle. *J Bone Joint Surg Am* 53(6):1102–1104
74. Grobler GP (1996) Unusual cause of ulnar nerve palsy. *Clin Orthop Relat Res* 323:192–193
75. Rao SB, Crawford AH (1995) Median nerve entrapment after dislocation of the elbow in children. A report of 2 cases and review of literature. *Clin Orthop Relat Res* (312):232–237
76. Ikram MA (1996) Ulnar nerve palsy: a complication following percutaneous fixation of supracondylar fractures of the humerus in children. *Injury* 27(5):303–305
77. Pasquina PF, O'Connor FG (1999) Olecranon fracture sustained in arm wrestling. *Phys Sports Med* 27(4):81–87
78. Pouliart N, De Boeck H (2002) Posteromedial dislocation of the elbow with associated intraarticular entrapment of the lateral epicondyle. *J Orthop Trauma* 16:153–156
79. Bruijn JD, Koning J (1992) Compression of the ulnar nerve by an aneurysm. A case of late complication after a supracondylar fracture. *Acta Orthop Scand* 63(2):223–224
80. Carl AL, Ain MC (1994) Complex fracture of the radial neck in a child: an unusual case. *J Orthop Trauma* 8(3):255–257
81. Yasuda M, Masada K, Iwakiri K, Takeuchi E (2003) Rotational radioulnar dissociation: a case report and review of the literature. *J Orthop Trauma* 17(8):585–587 (review)
82. De Jesus R, Dellon AL (2003) Historic origin of the “Arcade of Struthers”. *J Hand Surg Am* 28(3):528–531
83. Foead A, Penafort R, Saw A, Sengupta S (2004) Comparison of two methods of percutaneous pin fixation in displaced supracondylar fractures of the humerus in children. *J Orthop Surg (Hong Kong)* 12(1):76–82
84. Tien Y-C, Chen J-C, Fu Y-C, Chih T-T, Hunag P-J, Wang G-J (2005) Supracondylar dome osteotomy for cubitus valgus deformity associated with a lateral condylar nonunion in children. *J Bone Joint Surg Am* 87(7):1456–1463
85. Arora RK (2004) A different method of pinning of displaced extension type supracondylar fracture of humerus in children. *JK Sci* 6(1):28–30
86. Benz G, Kallieris D, Seeböck T, McIntosh A, Daum R (1994) Bioresorbable pins and screws in paediatric traumatology. *Eur J Pediatr Surg* 4(2):103–107
87. Ishii T, Miyagawa S, Hayashi K (1994) Traction apophysitis of the medial malleolus. *J Bone Joint Surg Br* 76(5):802–806
88. McCarthy SM, Ogden JA (1982) Radiology of postnatal skeletal development. V. Distal humerus. *Skeletal Radiol* 7(4):239–249
89. Abe M, Ishizu T, Shirai H, Okamoto M, Onomura T (1995) Tardy ulnar nerve palsy caused by cubitus varus deformity. *J Hand Surg Am* 20(1):5–9
90. Doornberg JN, Ring DC (2006) Fracture of the anteromedial facet of the coronoid process. *J Bone Joint Surg Am* 88(10):2216–2224
91. McCance SE, DeSignore JL (1998) Chronic displaced medial epicondyle fracture. *Orthopedics* 21(8):904–906
92. Stiehl JB (2007) Transepicondylar distal femoral pin placement in computer assisted surgical navigation. *Comput Aided Surg* 12(4):242–246
93. Noyes FR, Albright JC (2006) Reconstruction of the medial patellofemoral ligament with autologous quadriceps tendon. *Arthroscopy* 22(8):904.e1–904.e7
94. Rasool MN (1998) Ulnar nerve injury after K-wire fixation of supracondylar humerus fractures in children. *J Pediatr Orthop* 18(5):686–690
95. Sperry K, Pfalzgraf R (1990) Inadvertent clavicular fractures caused by “chiropractic” manipulations in an infant: an unusual form of pseudoabuse. *J Forensic Sci* 35(5):1211–1216
96. Skak SV, Olsen SD, Smaabrekke A (2001) Deformity after fracture of the lateral humeral condyle in children. *J Pediatr Orthop B* 10(2):142–152
97. Imatani J, Ogura T, Morito Y, Hashizume H, Inoue H (2005) Custom AO small T plate for transcondylar fractures of the distal humerus in the elderly. *J Shoulder Elbow Surg* 14(6):611–615
98. Forthman C, Henket M, Ring DC (2007) Elbow dislocation with intra-articular fracture: the results of operative treatment without repair of the medial collateral ligament. *J Hand Surg Am* 32(8):1200–1209
99. Sjöden GOJ, Lundberg A, Blomgren GA (1995) Late results of the Souter–Strathclyde total elbow prosthesis in rheumatoid arthritis: 6/19 implants loose after 5 years. *Acta Orthop Scand* 66(5):391–394
100. Potter D, Claydon P, Stanley D (2003) Total elbow replacement using the Kudo prosthesis. Clinical and radiological review with five- to seven-year follow-up. *J Bone Joint Surg Br* 85(3):354–357
101. Pompe W, Bender J (1975) Partial loss of function of the ulnar nerve resulting from a fracture of the medial humeral epicondyle in an adult. *Int Surg* 60(4):233–235
102. Khan SA, Zahid M (2002) Dislocation of the elbow with intra-articular entrapment of the medial epicondyle in adults. Report of two cases. *Acta Orthop Belg* 68(1):83–86
103. [No authors listed] (1983) Avulsion of the medial epicondyle into the elbow joint (radiograph). *Aust Fam Physician* 12(9):654
104. Fritz RC, Steinbach LS (1996) Magnetic resonance imaging of the musculoskeletal system: Part 3. The elbow. *Clin Orthop Relat Res* 324:321–339
105. Gore RM, Rogers LF, Bowerman J, Suker J, Compere CL (1980) Osseous manifestations of elbow stress associated with sports activities. *AJR Am J Roentgenol* 134(5):971–977
106. Harrison RB, Keats TE, Frankel CJ, Anderson RL, Youngblood P (1984) Radiographic clues to fractures of the unossified medial humeral condyle in young children. *Skeletal Radiol* 11(3):209–212
107. Resnik CS, Hartenberg MA (1986) Ossification centers of the pediatric elbow: a rare normal variant. *Pediatr Radiol* 16(3):254–256
108. Haxhija EQ, Mayr JM, Grechenig W, Höllwarth ME (2006) Treatment of medial epicondylar apophyseal avulsion injury in children. *Oper Orthop Traumatol* 18(2):120–134
109. Lee HH, Shen HC, Chang JH, Lee CH, Wu SS (2005) Operative treatment of displaced medial epicondyle fractures in children and adolescents. *J Shoulder Elbow Surg* 14(2):178–185
110. Skak SV, Grossmann E, Wagn P (1994) Deformity after internal fixation of fracture separation of the medial epicondyle of the humerus. *J Bone Joint Surg Br* 76(2):297–302
111. van Niekerk JL, Severijnen RS (1985) Medial epicondyle fractures of the humerus. *Neth J Surg* 37(5):141–144
112. Ip D, Tsang WL (2007) Medial humeral epicondylar fracture in children and adolescents. *J Orthop Surg (Hong Kong)* 15(2):170–173
113. Papavasiliou VA, Crawford AH (1982) Fracture-separation of the medial epicondylar epiphysis of the elbow joint. *Clin Orthop Relat Res* 171:172–174

114. Pimpalnerkar AL, Balasubramaniam G, Young SK, Read L (1998) Type four fracture of the medial epicondyle: a true indication for surgical intervention. *Injury* 29(10):751–756
115. Wilson JN (1960) The treatment of fractures of the medial epicondyle of the humerus. *J Bone Joint Surg Br* 42:778–781
116. Maylahn DJ, Fahey JJ (1958) Fractures of the elbow in children; review of three hundred consecutive cases. *J Am Med Assoc* 166:220–228
117. Keon-Cohen BT (1966) Fractures at the elbow. *J Bone Joint Surg Am* 48:1623–1639
118. Ireland ML, Andrews JR (1988) Shoulder and elbow injuries in the young athlete. *Clin Sports Med* 7:473–494
119. Aitken AP, Childress HM (1938) Intra-articular displacement of the internal epicondyle following dislocation. *J Bone Joint Surg* 20:161–166
120. Fairbank HAT, Buxton SJD (1934) Displacement of the internal epicondyle into the elbow joint. *Lancet* 227(ii):218
121. Granger B (1818) On a particular fracture of the inner condyle of the humerus. *Edinburgh Med Surg J* 14:196–201
122. Higgs SL, Cantab BCh (1936) Fractures of the internal epicondyle of the humerus. *Br Med J* 2:666–667
123. Roberts NW (1934) Displacement of the internal epicondyle into the joint. *Lancet* 2:78–79
124. Smith FM (1946) Displacement of medial epicondyle of humerus into the elbow joint. *Ann Surg* 124:410–425
125. McIntyre WM, Wiley JJ, Charette RJ (1984) Fracture-separation of the distal humeral epiphysis. *Clin Orthop Relat Res* 188:98–102
126. Mizuno K, Hirohata K, Kashiwagi D (1979) Fracture-separation of the distal humeral epiphysis in young children. *J Bone Joint Surg Am* 61:570–573
127. Collins R, Lavine SA (1964) Fractures of the medial epicondyle of the humerus with ulnar nerve paralysis. *Clin Proc Child Hosp Dist Columbia* 20:274–277
128. Cothay DM (1967) Injury to the lower medial epiphysis of the humerus before development of the ossific centre. Report of a case. *J Bone Joint Surg Br* 49:766–767
129. de Jager LT, Hoffman EB (1991) Fracture-separation of the distal humeral epiphysis. *J Bone Joint Surg Br* 73:143–146
130. Smith FM (1950) Medial epicondyle injuries. *J Am Med Assoc* 142:396–402
131. Conn J, Wade PA (1961) Injuries of the elbow: a 10-year review. *J Trauma* 1:248–268
132. DeLee JC, Wilkins KE, Rogers LF, Rockwood CA (1980) Fracture-separation of the distal humeral epiphysis. *J Bone Joint Surg Am* 62:46–51
133. Pappas AM (1982) Elbow problems associated with baseball during childhood and adolescence. *Clin Orthop Relat Res* 164:30–41
134. Bax L, Yu LM, Ikeda N, Tsuruta H, Moons KGM (2008) MIX: comprehensive free software for meta-analysis of causal research data version 1.7. Home page at: <http://www.mix-for-meta-analysis.info/>
135. Bax L, Yu LM, Ikeda N, Tsuruta H, Moons KGM (2006) Development and validation of MIX: comprehensive free software for meta-analysis of causal research data. *BMC Med Res Methodol* 6:50
136. Broberg MA, Morrey BF (1987) Results of treatment of fracture-dislocations of the elbow. *Clin Orthop Relat Res* 216:109–119