

UCSF

UC San Francisco Previously Published Works

Title

Endovascular treatment strategy, technique, and outcomes for dural arteriovenous fistulas of the marginal sinus region.

Permalink

<https://escholarship.org/uc/item/68f953j9>

Journal

Journal of neurointerventional surgery, 14(2)

ISSN

1759-8478

Authors

Caton, Michael Travis
Narsinh, Kazim H
Baker, Amanda
[et al.](#)

Publication Date

2022-02-01

DOI

10.1136/neurintsurg-2021-017476

Peer reviewed



Published in final edited form as:

J Neurointerv Surg. 2022 February ; 14(2): 155–159. doi:10.1136/neurintsurg-2021-017476.

Endovascular treatment strategy, technique, and outcomes for dural arteriovenous fistulas of the marginal sinus region

Michael Travis Caton¹, Kazim H Narsinh¹, Amanda Baker¹, Steven W Hetts¹, Daniel L Cooke¹, Randall T Higashida^{1,2}, Christopher F Dowd^{1,2}, Van V Halbach^{1,2}, Matthew R Amans¹

¹Department of Radiology and Biomedical Imaging, University of California San Francisco, San Francisco, California, USA

²Departments of Neurological Surgery, Neurology, and Anesthesiology, University of California San Francisco, San Francisco, CA, USA

Abstract

Background—Dural arteriovenous fistulas (AVF) of the foramen magnum region (FMR) are technically challenging lesions to treat. Transvenous (TV), transarterial (TA), and surgical approaches have been described, but the optimum treatment strategy is not defined.

Objective—To report treatment strategies and outcomes for FMR-AVF at a single, high-volume referral center.

Methods—A retrospective review from January 2010 to August 2020 identified patients with FMR-AVF at a single referral center. Angiographic features, treatment (observation, endovascular, surgical), and follow-up of angiographic and clinical results were recorded. The technical aspects of TV embolization are then presented in detail.

Results—29 FMR-AVF were identified in 28 patients. Of these, 24/29 (82.8%) were treated and 5/29 (17.2%) were observed. Treatment was endovascular in 21/24 (87.5%), combined (endovascular+surgical) in 2/24 (8.3%), and surgical in 1/24 (4.2%). Endovascular treatments were 76.2% TV, 14.3% TA, and 9.5% combined TV/TA. Sufficient follow-up data were available for 20/28 (71.4%) with mean follow-up of 16.8 months. No AVF recurrence was seen for TA/TV, combined endovascular/surgical, or surgical groups, and there was one recurrence (7.1%) in the TV group. Symptomatic improvement was seen in all groups: TV (71.4% complete, 28.6% partial), TA (66.7% complete, 33.3% no follow-up), TV+TA (100% partial), endovascular/surgical (100% complete), and surgical (100% partial). Minor non-neurologic complications included 1/14 (7.1%) in the TV group and 1/3 (33.3%) in the TA/TV group.

Correspondence to: Dr Michael Travis Caton, Department of Radiology and Biomedical Imaging, University of California San Francisco, San Francisco, California, USA; travis.caton@gmail.com, **Twitter** Michael Travis Caton [@traviscaton](https://twitter.com/traviscaton).

Contributors MTC and MRA: conception and design of the work; initial drafting of the work. KHN, AB, SWH, DLC, CFD, RTH, VVH: substantial contributions to the conception or design of the work; or the acquisition and interpretation of data for the work; revising the work critically for important intellectual content. All authors: Final approval of the version submitted. Agreement to be accountable for all aspects of the work in ensuring that questions related to the accuracy or integrity of any part of the work are appropriately investigated and resolved.

Competing interests None declared.

Ethics approval This study was approved by local (UCSF) institutional review board # 10–00936.

Conclusion—Endovascular treatment is safe and effective for most FMR-AVF. TV embolization has a high cure rate with few complications.

INTRODUCTION

Arteriovenous fistulas (AVF) of the foramen magnum region are rare and complex lesions with a highly variable natural history.¹ This group of fistulas includes shunts of the anterior, lateral, and posterior condylar veins, condylar confluence, and marginal sinus.² This network of interconnected sinuses and emissary veins is highly variable across individuals³⁻⁵; the marginal sinus itself comprises a ring-like structure lining the foramen magnum. Its function has been suggested as an evolutionary accommodation to changes in cranial venous drainage as bipedalism evolved in humans.^{6,7} The condylar veins, in conjunction with the suboccipital cavernous sinus, serve as a switchboard between the jugular veins and the vertebral venous plexus, which shift in normal physiology with changes in body position.^{4,8,9} The nature of AVF involving these related venous structures is therefore complex. Moreover, the vascular structures of the posterior skull base are often superimposed in conventional angiographic views, making diagnosis and treatment a considerable challenge.¹⁰ The natural history of foramen magnum AVF is variable and not well-studied; lower-grade lesions frequently cause pulsatile tinnitus (>75%) or congestive orbitopathy, but the presence of high-risk venous drainage carries a substantial risk of congestive myelopathy, hypoglossal palsy, or hemorrhage.¹¹ Less aggressive lesions may still warrant treatment to deal with persistent symptoms, including pulsatile tinnitus (PT) and ocular symptoms.¹²

The optimal treatment strategy for foramen magnum region AVF remains undefined. Open neurosurgical approaches to the foramen magnum are feasible but are technically demanding and carry substantial procedural risk; endovascular treatment is therefore generally favored as the primary choice when indicated.¹¹ Clinical and angiographic success has been reported with both transvenous (TV) and transarterial (TA) approaches,¹³⁻¹⁶ but the efficacy and safety of both techniques has not been thoroughly studied.

The purpose of this study is to describe treatment and angiographic and clinical outcomes in a single-center series of patients with condylar and marginal sinus AVF. A technical discussion of the TV approach employed at our institution is presented in greater depth.

METHODS AND MATERIALS

We carried out a retrospective review of a neurointerventional database with approval from the local institutional review board, spanning January 2010 through July 2020. Candidates, identified based on description of lesions in neuroangiographic reports and digital subtraction angiograms (DSA), were reviewed by the senior author (MRA) to confirm the presence and location of the shunt. Initial angiographic cure status was defined by the presence or absence of residual shunting at conclusion of the initial procedure. A delayed postprocedural treatment result was defined by the presence/absence of shunting on DSA >3 months after the initial treatment. Additional clinical details were extracted from the medical record.

RESULTS

We identified 28 patients diagnosed with either marginal sinus or condylar vein AVF during the study period. One patient had discrete, bilateral marginal sinus (MS) fistulas; therefore, the total number of lesions was 29. Of these, 24/29 (82.8%) underwent treatment. Of the remaining patients who were not treated (5/29, 17.2% of the total), 1/5 (20%) had a low risk shunt which could not be successfully accessed via a TV approach and the lesion was found to spontaneously thrombose on a subsequent angiogram; 1/5 (20%) was lost to clinical follow-up despite the initial plan for future treatment, and 3/5 (60%) did not undergo treatment because they were co-diagnosed with separate, higher-risk fistulas (ie, sigmoid sinus, torcular, and superior petrosal sinus), which were the primary driver of risk and/or symptoms and all of which were prioritized for endovascular treatment. One of these patients had persistent PT after treatment of higher-risk torcular fistula and is set to return for planned TV treatment of the marginal sinus AVF.

Treatment strategies and outcomes are summarized in table 1. Clinical and angiographic follow-up data were available for 26/28 (92.9%) patients and the mean duration of follow-up was 16.8 months (IQR 4.9–19.4 months) following initial DSA. Both patients without available follow-up data were external referrals to our hospital (one patient had angiographic cure following TV treatment and the other patient received no treatment).

Endovascular treatment

Endovascular treatment was performed in 72.4% of all cases, comprising 87.5% of all treatments performed. Endovascular technique was exclusively TV in 16/21 (76.2%), TA in 3/21 (14.3%), and combined TA/TV in 2/21 (9.5%). Two patients (1 TV, 1 TA/TV) had unsuccessful attempted TA embolization at outside institutions prior to evaluation at our center.

Transvenous approach—Exclusive TV coil embolization resulted in complete immediate angiographic obliteration of the fistula in 100% of cases (figure 1). One patient (1/16, 6.3%) was treated in a two-procedure staged approach (over 2 days); the remaining patients (15/16, 93.8%) were treated in a single session. Delayed post-treatment DSA was available in 14/16 (87.5%). Angiographic cure was persistent in 13/14 (92.9%) with recurrent shunting in 1/14 (7.1%). One patient in this group (6.3%) developed an unrelated, de novo cervical epidural AVF at follow-up, which required additional endovascular treatment. The initial presenting symptoms (eg, PT, ocular symptoms) resolved completely in 10/14 (71.4%) and improved in the remaining 4/14 (28.6%). One complication was recorded in the TV group (1/14, 7.1%: occlusion of the superficial femoral artery on the side of femoral access, diagnosed 1 month after the procedure).

Transvenous embolization: technical note—The authors employ an *arteriography-guided transvenous approach*, which is discussed in greater detail here (figures 2 and 3). On the venous side, a shallow curved 7Fr or 8Fr guide catheter is positioned near the jugular bulb with tip directed anteriomedially (toward the anterior condylar confluence). Frequently used guide catheters were the MPA 1 (Cordis, Santa Clara, California, USA, 66.7%)—particularly useful for accessing the anterior condylar vein, MPD (Codman Neuro,

Raynham, Massachusetts, USA, 11.2%), and VBL (Cordis, Santa Clara, California, USA, 22.2%)—particularly useful for accessing the lateral condylar vein. A triaxial system was used in 77.8% of cases; intermediate catheter selection was the 044 DAC in 50.0% and 038 DAC in 14.3% (Stryker Neurovascular, Fremont, California, USA), or 5Fr DAV in 21.4% (Cook Medical, Bloomington, Indiana, USA) of cases. The Prowler Select LP ES (Codman Neuro, Raynham, Massachusetts, USA) was used in 77.8% of cases and the Headway Duo (Microvention/Terumo, Aliso Viejo California, USA) was used in 11.1%, typically advanced over a Synchro 2 Standard microwire (77.8%) or Transend EX Platinum (16.7%, Stryker Neurovascular, Fremont, California, USA). The intermediate catheter was used to provide stability, and the microcatheter was navigated into the recipient venous pouch (eg, MS, anterior condylar vein (ACV), etc). Schematic depiction of catheter system positioning and coiling is shown in figure 1D–F. Proper microcatheter positioning was evaluated by selective venography followed by arteriography in the same projection (figures 2C–E and 3B,C).

In each case, a diagnostic catheter (5Fr Berenstein III, Codman Neuro, Raynham, Massachusetts, USA) is positioned for pre- and mid-embolization angiography and roadmapping, such that the most distal arterial feeder can be reliably visualized. The most frequent diagnostic arterial catheter position was the common carotid artery in 11/18 (61.1%) cases (63.6% contralateral and 36.4% ipsilateral) followed by the ascending pharyngeal artery (5/18, 27.8% of cases; 80% and 20% ipsilateral relative to fistula site). Overall, diagnostic arterial catheter position was more frequently on the contralateral side to the fistula (10/18, 55.6% of cases). Working projections were maintained throughout the embolization process using blank roadmapping to delineate coil position and to avoid coil displacement. Biplane projections were varied based on arterial supply, but the authors frequently use a slight ipsilateral oblique Water's and reverse Schuller's high magnification view to best visualize the overlapping venous structures of the posterior fossa. Partial herniation of coils into common final arterial channels (figure 1D) was frequent and indicative of proper microcatheter positioning within the fistulous pouch.

Transarterial approach—Exclusive TA treatment was performed in 3/28 (10.7%) patients. Overall, complete post-treatment angiographic obliteration of the shunt was achieved in 2/3 (67%) patients with trace persistent shunting in the third (1/3, 33%). One patient had an intermediate-risk lateral condylar vein (LCV) fistula, which demonstrated reflux into the inferior petrosal sinus and bridging veins of the prepontine cistern. This LCV fistula was treated indirectly during targeted endovascular treatment of a separate, high-risk fistula (source of hemorrhage) of the transverse sinus. Onyx embolization of the middle meningeal artery resulted in complete occlusion of the transverse sinus shunt and partial treatment of the LCV fistula. However, the patient died owing to pneumonia in the postembolization hospital course. The second patient presented with subarachnoid hemorrhage and was treated using the TA approach via transmastoid branches of the occipital artery using Onyx, which permeated to the draining vein, resulting in immediate angiographic cure. The third patient presented with PT and was diagnosed with a posterior condylar vein AVF supplied chiefly by the ipsilateral ascending pharyngeal artery. This was treated using a TA coiling technique whereby the recipient pouch was accessed via the enlarged hypoglossal branch artery and the fistula was cured using coils. No procedural

complications were documented in the TA-only group. Angiographic cure was durable in the two patients (100%) for whom delayed follow-up DSA was performed. These patients also had complete neurologic recovery and no residual symptoms at follow-up.

Transarterial/transvenous combined treatment

Combination TA/TV treatment was performed in 2/29 (6.9%) AVF and was reserved for symptomatic, complex lesions. In both cases, treatment was staged over two or more sessions and the marginal sinus fistula was present as part of a larger, complex, multi-hole AVF (involving the entire basal clival plexus in one patient and involving two adjacent sigmoid sinus fistulas in the other patient). Both patients had post-treatment resolution of shunting (following three staged treatments in one patient, two in the other). Angiographic cure of the target fistula was durable at follow-up DSA in both cases and clinical symptoms improved but did not resolve. One complication (rupture of middle meningeal artery) was immediately treated, with no postprocedural sequelae. One patient developed a de novo anterior ethmoidal fistula (unrelated to marginal sinus AVF) during subsequent follow-up angiography.

Surgical and combined surgical/endovascular treatments

Open surgical treatment was undertaken in 1/29 (3.4%) cases and performed in tandem with partial endovascular treatment in an additional 2/29 (6.9%) cases. In the case of exclusive surgical clipping, the patient presented with high-risk features including cervical myelopathy and perimedullary venous engorgement on DSA. Endovascular treatment was deferred in the setting of iatrogenic embolus to the distal (P3) posterior cerebral artery branch, treated with intravenous eptifibatid (with no deficits following the procedure). The patient underwent successful ligation using a far-lateral craniotomy approach.

Both patients who underwent combined endovascular/surgical treatment presented initially with subarachnoid hemorrhage of uncertain etiology on CT angiography; given the uncertainty and presence of posterior fossa blood, both were initially scheduled for surgical management and preoperative diagnostic angiography. In the first patient DSA revealed a large varix associated with MS-AVF. After multidisciplinary discussion, palliative transarterial obliteration of the dominant feeder (transmastoid branch of occipital artery) was performed using polyvinyl alcohol particles (500–700 μm) and a detachable coil to reduce pressurization of the varix. Far-lateral approach clip ligation was performed the following day. The second patient underwent polyvinyl alcohol/coil embolization of the hypoglossal branch of the ascending pharyngeal artery; further transarterial embolization was not performed as the jugal branch demonstrated communication with the vertebral artery via the odontoid arcade and residual shunting was present. The patient underwent uneventful surgical ligation of the fistula using a far-lateral approach.

In all three cases, repeat angiography was performed on postoperative day 1, confirming complete resolution of the arteriovenous shunting. No patients experienced postoperative complications. The two patients who presented with subarachnoid hemorrhage had complete neurologic recovery postsurgery and the third patient's myelopathic symptoms resolved.

DISCUSSION

The authors present a large, single institutional experience of treatment strategies for AVF of the marginal sinus and condylar veins. This series includes representative cases in which TV, TA, TV/TA, and surgical treatments were employed and thus reflects a balanced and diverse set of scenarios likely to be encountered in practice.

In this series, transvenous embolization was both safe and effective, supporting findings from previous smaller studies.^{1 17 18} Immediate embolization resolution of shunting was 100% and recurrent shunting occurred in only 1/14 (7.1%). Importantly, the presenting clinical symptom abated completely (71.4%) or partially (28.6%) in all patients; similar to rates reported by Choi *et al* who used a TV approach for 90% of their cases.¹⁹ Our results also corroborate a 2015 systematic review of 68 TV cases, which reported angiographic and clinical cure rates of 92.7% and 91%, respectively.¹¹ A solitary postprocedural, femoral access-related complication (1/14, 7.1%) was observed. The authors therefore believe this to be a safe, first-line therapeutic option when performed with judicious planning. Although not encountered in our patients, one potential complication reported with TV embolization is ‘overpacking’ and resultant mass effect on adjacent cranial nerve fibers, which can manifest as hypoglossal nerve palsy.^{15 16} Intraprocedural cone beam CT may mitigate this complication, which can occur when the ACV, which runs parallel to CN XII in the hypoglossal canal (figure 1A), is distended with coils.²⁰ Cone beam CT may also clarify the precise location of the shunt relative to the microcatheter, which can reduce the need for repeat angiographic runs and potentially lower the cumulative radiation dose.²¹

From a technical standpoint, successful TV coil embolization can be achieved using a biaxial or triaxial transvenous catheter system, guided by selective intermittent arteriography, thus requiring simultaneous arterial/venous access, typically from a transfemoral approach, facilitating easy manipulation of both arterial and venous catheter systems.²² In the authors’ experience, optimal arteriography was paradoxically achieved from *contralateral* dural branches in over half (55.5%) of cases, as has been previously recommended by Ernst *et al*.¹³ Ultimately, the goal of the described arteriography-guided TV approach is to ensure that the most ‘distal’ (typically the most medial) arterial insertion sites are occluded during initial coil deployment; failure to do so can result in persistent shunting, thereby precluding further TV treatment.

Although performed less frequently by our group, TA obliteration of fistulas of the foramen magnum region are well described in the literature.²³ This approach is particularly important when sinus stenosis or occlusion of the ipsilateral jugular system precludes access to the shunt.¹⁷ TA embolization therefore remains an important alternative tool, although some authors favor TA as a first-line maneuver.²⁴ If TA embolization is undertaken, the authors reiterate the need for comprehensive preoperative diagnostic angiography, including superselective interrogation of external carotid artery branches to prevent non-target embolization via pre-existing anastomoses or injury to the lower cranial nerves.^{25 26} In a meta-analysis of 18 TA treatments with liquid embolic agents, Spittau *et al* estimated a sizable complication rate, resulting in permanent morbidity of 16.7%.¹¹ Nevertheless, the ascending pharyngeal artery, a near-ubiquitous feeder artery to the MS and condylar vein

AVF, can be safely embolized with proper pretreatment anatomic surveillance.^{27 28} Some operators prefer n-butyl cyanoacrylate, which may afford greater control in experienced hands, as was described in a recent series of 12 ACV AVF, with good results.²⁴ The true efficacy of TA embolization is difficult to assess; two patients (7.1%) in our series had residual or recurrent shunting following attempted Onyx embolization by outside operators. Spittau reported a lower rate of clinical cure compared with TV embolization (58.8% vs 91%) despite similar rates of reported angiographic occlusion (94.4% vs 92.7% for TA, TV respectively). The discrepancy between clinical and 'reported' angiographic cure in the literature remains unclear but suggests that residual shunting after TA embolization is relatively frequent (and possibly under-reported). One use of TA embolization which is less frequently described is to reduce shunt fraction as adjuvant preparation for definitive TV or surgical embolization.^{16 29}

Primary microsurgical treatment has been advocated for Cognard V fistulas of the foramen magnum region (those harboring perimedullary congestion).³⁰ The far-lateral craniotomy approach to the foramen magnum, performed in all instances in our series, has emerged as the preferred operative approach.³¹ In 15 cases reviewed by Spittau, lesions which were treated surgically had an angiographic occlusion rate of 90% and symptomatic improvement in 73.3% with a permanent treatment morbidity rate of 13.3%.¹¹ Given the relative technical complexity and associated risks of open surgical ligation, we agree with other authors that this technique should be reserved for high-risk lesions (eg, progressive myelopathy and/or hemorrhage) with inaccessible angioarchitecture.^{2 11 17}

Several limitations of the current study merit additional discussion. First, AVF of the foramen magnum region are rare (from 1.5% to 4.5% of all cranial AVF).^{1 17 32} The current cohort, although the largest single-center series to date, still cannot provide robust statistical evidence supporting one treatment method over another. A related limitation is the retrospective nature of this analysis and the non-random allocation of treatment strategy to each case, further limiting direct comparison of safety and efficacy between techniques. Lastly, the long-term outcomes of patients with treated foramen magnum/MS/condylar vein fistulas remains uncertain. Two patients in this cohort developed de novo AVF during relatively short-term follow-up, therefore it is plausible that this patient population may be at higher risk of recurrence than the general population.

In summary, this study describes the strengths and weaknesses of various approaches to treatment for AVF of the condylar veins and marginal sinus. When feasible, the TV approach appears both safe, efficient, and durable. A reproducible technique for arteriography-guided TV embolization is depicted. Transarterial, combined TA/TV endovascular, and surgical approaches are appropriate alternatives in select clinical scenarios.

Funding

This work was supported in part by National Heart Lung, and Blood Institute of the National Institutes of Health under award No. R56HL149124-01.

REFERENCES

1. McDougall CG, Halbach VV, Dowd CF, et al. Dural arteriovenous fistulas of the marginal sinus. *AJNR Am J Neuroradiol* 1997;18:1565–72. [PubMed: 9296201]
2. Li C, Yu J, Li K, et al. Dural arteriovenous fistula of the lateral foramen magnum region: a review. *Interv Neuroradiol* 2018;24:425–34. [PubMed: 29726736]
3. Tanoue S, Kiyosue H, Sagara Y, et al. Venous structures at the craniocervical junction: anatomical variations evaluated by multidetector row CT. *Br J Radiol* 2010;83:831–40. [PubMed: 20647517]
4. de Oliveira E, Rhoton AL, Peace D. Microsurgical anatomy of the region of the foramen magnum. *Surg Neurol* 1985;24:293–352. [PubMed: 4023912]
5. Okudera T, Huang YP, Ohta T, et al. Development of posterior fossa dural sinuses, emissary veins, and jugular bulb: morphological and radiologic study. *AJNR Am J Neuroradiol* 1994;15:1871–83. [PubMed: 7863937]
6. Falk D Evolution of cranial blood drainage in hominids: enlarged occipital/marginal sinuses and emissary foramina. *Am J Phys Anthropol* 1986;70:311–24. [PubMed: 3092672]
7. Tubbs RS, Ammar K, Liechty P, et al. The marginal sinus. *J Neurosurg* 2006;104:429–31.
8. San Millán Ruíz D, Gailloud P, Rüfenacht DA, et al. The craniocervical venous system in relation to cerebral venous drainage. *AJNR Am J Neuroradiol* 2002;23:1500–8. [PubMed: 12372739]
9. Lachkar S, Kikuta S, Iwanaga J, et al. The condylar canal and emissary vein—a comprehensive and pictorial review of its anatomy and variation. *Childs Nerv Syst* 2019;35:747–51. [PubMed: 30900022]
10. Caton MT, Callen AL, Copelan AZ, et al. Jugular venous reflux can mimic posterior fossa dural arteriovenous fistulas on MRI-MRA. *AJR Am J Roentgenol* 2021:1–8.
11. Spittau B, Millán DS, El-Sherifi S, et al. Dural arteriovenous fistulas of the hypoglossal canal: systematic review on imaging anatomy, clinical findings, and endovascular management. *J Neurosurg* 2015;122:883–903. [PubMed: 25415064]
12. Turner RD, Gonugunta V, Kelly ME, et al. Marginal sinus arteriovenous fistulas mimicking carotid cavernous fistulas: diagnostic and therapeutic considerations. *AJNR Am J Neuroradiol* 2007;28:1915–8. [PubMed: 17898196]
13. Ernst R, Bulas R, Tomsick T, et al. Three cases of dural arteriovenous fistula of the anterior condylar vein within the hypoglossal canal. *AJNR Am J Neuroradiol* 1999;20:2016–20. [PubMed: 10588137]
14. Kiyosue H, Okahara M, Sagara Y, et al. Dural arteriovenous fistula involving the posterior condylar canal. *AJNR Am J Neuroradiol* 2007;28:1599–601. [PubMed: 17846219]
15. Takemoto K, Tateshima S, Rastogi S, et al. Onyx embolization of anterior condylar confluence dural arteriovenous fistula. *J Neurointerv Surg* 2014;6:e13. [PubMed: 23482712]
16. Miyachi S, Ohshima T, Izumi T, et al. Dural arteriovenous fistula at the anterior condylar confluence. *Interv Neuroradiol* 2008;14:303–12. [PubMed: 20557728]
17. Choi JW, Kim BM, Kim DJ, et al. Hypoglossal canal dural arteriovenous fistula: incidence and the relationship between symptoms and drainage pattern. *J Neurosurg* 2013;119:955–60. [PubMed: 23724984]
18. Okahara M, Kiyosue H, Tanoue S, et al. Selective transvenous embolization of dural arteriovenous fistulas involving the hypoglossal canal. *Interv Neuroradiol* 2007;13:59–66. [PubMed: 20566131]
19. Choi HS, Kim DI, Kim BM, et al. Endovascular treatment of dural arteriovenous fistula involving marginal sinus with emphasis on the routes of transvenous embolization. *Neuroradiology* 2012;54:163–9. [PubMed: 21369779]
20. Okamura A, Nakaoka M, Ohbayashi N, et al. Intraoperative cone-beam computed tomography contributes to avoiding hypoglossal nerve palsy during transvenous embolization for dural arteriovenous fistula of the anterior condylar confluence. *Interv Neuroradiol* 2016;22:584–9. [PubMed: 27288404]
21. Crockett MT, Chiu AHY, Singh TP, et al. Transvenous coil embolization with intra-operative cone beam CT assistance in the treatment of hypoglossal canal dural arteriovenous fistulae. *J Neurointerv Surg* 2019;11:179–83. [PubMed: 30054318]

22. Starke RM, Snelling B, Al-Mufti F, et al. Transarterial and transvenous access for neurointerventional surgery: report of the SNIS Standards and Guidelines Committee. *J Neurointerv Surg* 2020;12:733–41. [PubMed: 31818970]
23. Tanoue S, Goto K, Oota S. Endovascular treatment for dural arteriovenous fistula of the anterior condylar vein with unusual venous drainage: report of two cases. *AJNR Am J Neuroradiol* 2005;26:1955–9. [PubMed: 16155141]
24. Motebejjane MS, Choi IS. Foramen magnum dural arteriovenous fistulas: clinical presentations and treatment outcomes, a case-series of 12 patients. *Oper Neurosurg* 2018;15:262–9.
25. Kakizaki S, Ishibashi T, Kato N, et al. Complete obliteration of a foramen magnum dural arteriovenous fistula by microsurgery after failed endovascular treatment using Onyx: case report and literature review. *World Neurosurg* 2020;144:43–9. [PubMed: 32805464]
26. Hacein-Bey L, Daniels DL, Ulmer JL, et al. The ascending pharyngeal artery: branches, anastomoses, and clinical significance. *AJNR Am J Neuroradiol* 2002;23:1246–56. [PubMed: 12169487]
27. Gross BA, Albuquerque FC, Moon K, et al. The road less traveled: transarterial embolization of dural arteriovenous fistulas via the ascending pharyngeal artery. *J Neurointerv Surg* 2017;9:97–101. [PubMed: 27581042]
28. Spiotta AM, Hughes G, Masaryk TJ, et al. Balloon-augmented Onyx embolization of a dural arteriovenous fistula arising from the neuromeningeal trunk of the ascending pharyngeal artery: technical report. *J Neurointerv Surg* 2011;3:300–3. [PubMed: 21990848]
29. Manabe S, Satoh K, Matsubara S, et al. Characteristics, diagnosis and treatment of hypoglossal canal dural arteriovenous fistula: report of nine cases. *Neuroradiology* 2008;50:715–21. [PubMed: 18437370]
30. Reinges MH, Thron A, Mull M, et al. Dural arteriovenous fistulae at the foramen magnum. *J Neurol* 2001;248:197–203. [PubMed: 11355153]
31. Lanzino G, Paolini S, Spetzler RF. Far-lateral approach to the craniocervical junction. *Neurosurgery* 2005;57:ONS-367–ONS-371.
32. Cognard C, Gobin YP, Pierot L, et al. Cerebral dural arteriovenous fistulas: clinical and angiographic correlation with a revised classification of venous drainage. *Radiology* 1995;194:671–80. [PubMed: 7862961]

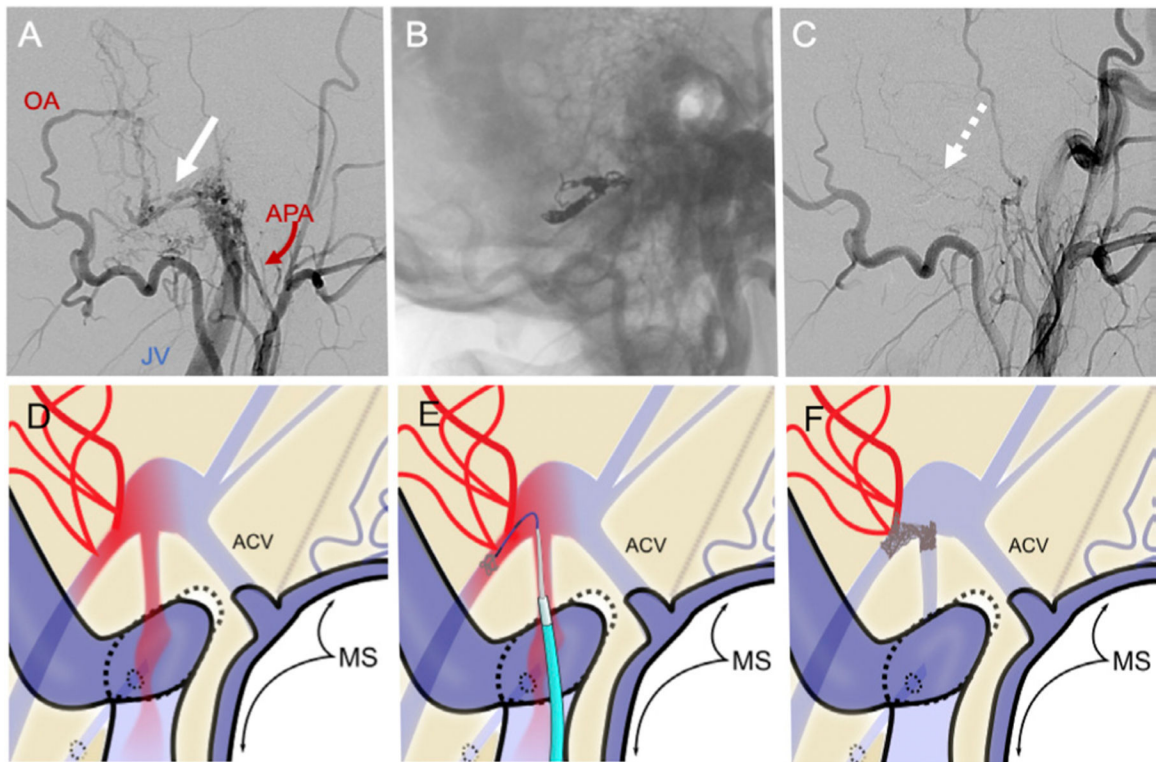


Figure 1.

Pretreatment left external carotid artery injection (A, lateral projection) shows lateral condylar vein dural arteriovenous fistula (white arrow) supplied by the occipital artery (OA) and branches of the ascending pharyngeal artery (APA) with early filling of the jugular vein (JV). The fistula was treated with transvenous embolization of the venous pouch (B). Post-treatment angiogram (C) shows complete resolution of the fistula (dashed arrow). (D–F) Schematic depiction of triaxial transvenous (TV) approach to the foramen magnum region-dural arteriovenous fistula (FMR-AVF): Part D shows salient anatomy of an FMR-AVF (arterial blood=red), including the marginal sinus (MS) and anterior condylar vein (ACV); the direction of antegrade flow in low-risk AVF. Catheter positioning for TV coil embolization is shown in (E), and postembolization angiographic cure is depicted in (F).

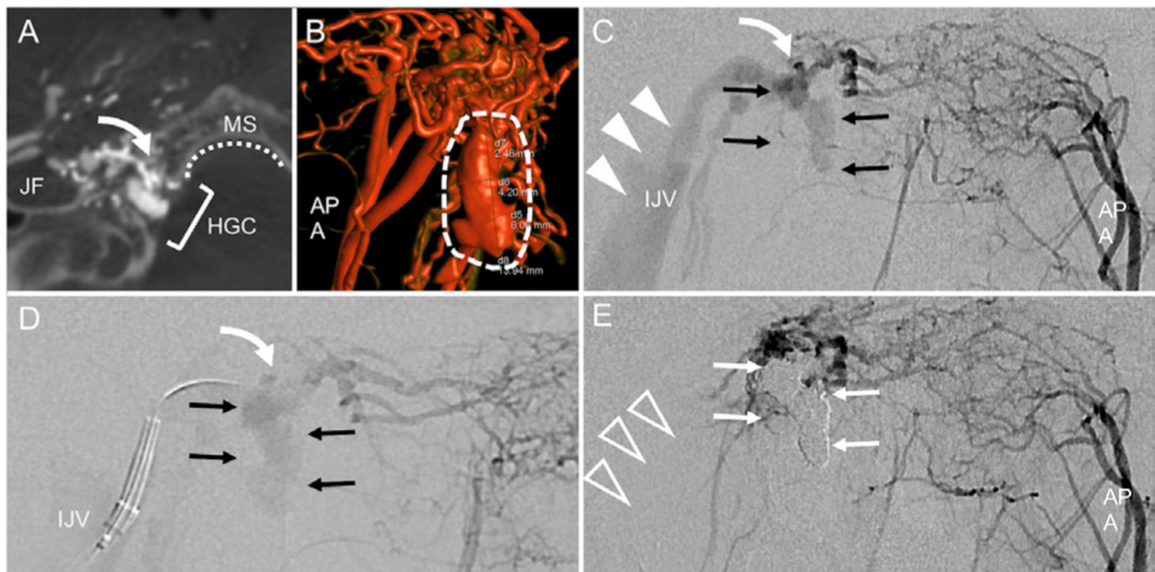


Figure 2. Anterior condylar vein arteriovenous fistula. Dyna-CT angiography with injection of the right ascending pharyngeal artery (APA) shows anatomy of the shunt (curved arrow) within the hypoglossal canal (HGC), adjacent to the marginal sinus (MS) and jugular foramen (JF). 3D re-formation shows that the fistulous pouch (dashed arrows) extends caudally into the MS. Panels C-E show sequential steps of arteriography-guided transvenous embolization: Water's/anteroposterior (AP) view of left APA injection shows the fistula (white curved arrow) and venous pouch (black arrows) with the ipsilateral jugular vein (IJV, white arrowheads). In D, a guide catheter is positioned in the IJV with microcatheter directed toward the fistula and pouch. From this position the fistula is embolized with coils. Postembolization left APA injection (E) shows resolution of shunting to IJV (clear arrowheads) and coil occlusion of venous pouch (white arrows).

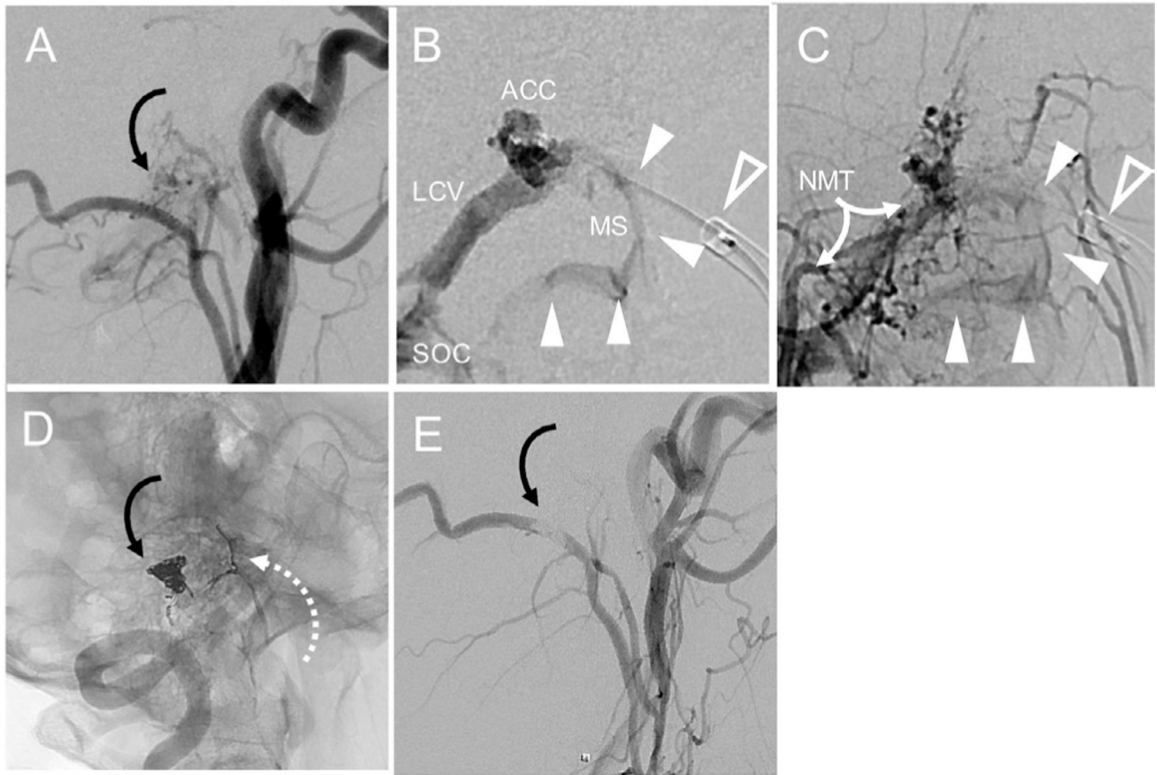


Figure 3. A marginal sinus (MS) arteriovenous fistula shown (A, curved arrow), supplied by branches of the neuromeningeal trunk (NMT). Selective venography shows position of guide catheter (B, clear arrowhead) and microcatheter positioned near the fistula; white arrowheads show ‘wash-in’ from arteriovenous shunting. Selective ascending pharyngeal arteriography (C) shows NMT supply to fistula and confirms the position of the shunt (white arrowheads) from the venogram, facilitating targeted coil embolization. Postembolization unsubtracted image (D) shows configuration of coils in the MS region and evidence of unsuccessful prior Onyx embolization (dashed arrow) from another institution. Complete resolution of the shunt (black curved arrow) is shown on post-treatment angiogram (E). ACC, anterior condylar confluence; LCV, lateral condylar vein; SOC, Suboccipital cavernous sinus.

Author Manuscript

Author Manuscript

Author Manuscript

Author Manuscript

Table 1
Summary of treatment strategies and outcomes for foramen magnum arteriovenous fistulas

	Treatment technique	No of cases (n=29)	No with sufficient follow-up data (n=26)	Clinical presentation	Immediate post-treatment cure rate	Durable cure rate (>3 month angiogram)	Clinical improvement	Complications
Endovascular treatment (21/29, 72.4%)	TV	16/29 (55.2%)	14/16 (87.5%)	PT (n=15) Ocular symptoms (n=5)	16/16 (100.0%)	13/14 (92.9%)	Complete 10/14 (71.4%) partial 4/14 (28.6%)	1/14 (7.1%)
	TA	3/29 (10.3%)	2/3 (66.%)	SAH (n=2) PT (n=1)	Complete 2/3 (66.7%) Partial 1/3 (33.3%)	2/2 (100%)	2/2 (100%)	0/3*
	TA/TV	2/29 (6.9%)	2/2 (100%)	PT (n=2) PT+ocular symptoms (n=1)	Complete 2/2 (100%)	Complete 2/2 (100%)	Complete 0/2 (0.0%) Partial 2/2 (100%)	1/3 (33.3%)
Surgical or endovascular+surgical treatment		3/29 (10.3%)	3/3 (100%)	Myelopathy (n=1) SAH (n=1) PT (n=1)	Complete 3/3 (100%)	Complete 3/3 (100%)	Complete 3/3 (100%)	1/3† (33%)
No treatment		5/29 (17.2%)	4/5 (80.0%)	Asymptomatic (n=1) PT (n=4)	Spontaneous cure (n=1) No follow-up (n=1) Treatment deferred or forthcoming (n=3)	NA	Complete (n=1) Unknown (n=2) Ongoing/multiple AVF (n=3)	N/A

* One patient died of unrelated causes several weeks after treatment.

† Complication (distal branch occlusion) occurred during diagnostic angiography, no clinical sequelae were evident.

AVF, arteriovenous fistula; PT, pulsatile tinnitus; SAH, subarachnoid hemorrhage; TA, transarterial; TV, transvenous.