

# UC Davis

## UC Davis Previously Published Works

### Title

Final report of the phase II NEXT/CNS-GCT-4 trial: GemPOx followed by marrow-ablative chemotherapy for recurrent intracranial germ cell tumors.

### Permalink

<https://escholarship.org/uc/item/697946jz>

### Journal

Neuro-Oncology Practice, 11(2)

### ISSN

2054-2577

### Authors

Shatara, Margaret

Blue, Megan

Stanek, Joseph

et al.

### Publication Date

2024-04-01

### DOI

10.1093/nop/npad067

Peer reviewed

## Final report of the phase II NEXT/CNS-GCT-4 trial: GemPOx followed by marrow-ablative chemotherapy for recurrent intracranial germ cell tumors

Margaret Shatara<sup>o</sup>, Megan Blue, Joseph Stanek<sup>o</sup>, Yin A. Liu, Daniel M. Prevedello, Pierre Giglio<sup>o</sup>, Vinay K. Puduvalli<sup>o</sup>, Sharon L. Gardner, Jeffrey C. Allen, Kenneth K. Wong, Marvin D. Nelson, Floyd H. Gilles, Roberta H. Adams, Jasmine Pauly, Katrina O'Halloran, Ashley S. Margol, Girish Dhall<sup>o</sup>, and Jonathan L. Finlay<sup>†</sup>

All author affiliations are listed at the end of the article

**Corresponding Author:** Margaret Shatara, MD, Assistant Professor of Pediatrics, Pediatric Neuro-Oncology Program, Division of Pediatric Hematology/Oncology, Washington University School of Medicine, in St. Louis, 660 South Euclid Avenue—Campus Box 8116, St. Louis, MO 63110, USA ([shatara@wustl.edu](mailto:shatara@wustl.edu)).

<sup>†</sup>This author contributed as a senior author to this work.

### Abstract

**Background.** Patients with relapsed intracranial germinoma can achieve durable remission with standard chemotherapy regimens and/or reirradiation; however, innovative therapies are required for patients with relapsed and/or refractory intracranial nongerminomatous germ cell tumors (NGGCTs) due to their poor prognosis. Improved outcomes have been reported using reinduction chemotherapy to achieve minimal residual disease, followed by marrow-ablative chemotherapy (HDCx) with autologous hematopoietic progenitor cell rescue (AuHPCR). We conducted a phase II trial evaluating the response and toxicity of a 3-drug combination developed for recurrent intracranial germ cell tumors consisting of gemcitabine, paclitaxel, and oxaliplatin (GemPOx).

**Methods.** A total of 9 patients with confirmed relapsed or refractory intracranial GCT were enrolled after signing informed consent, and received at least 2 cycles of GemPOx, of which all but 1 had relapsed or refractory NGGCTs. One patient with progressive disease was found to have pathologically confirmed malignant transformation to pure embryonal rhabdomyosarcoma (without GCT elements), hence was ineligible and not included in the analysis. Patients who experienced sufficient responses proceeded to receive HDCx with AuHPCR. Treatment response was determined based on radiographic tumor assessments and tumor markers.

**Results.** A total of 7 patients achieved sufficient response and proceeded with HDCx and AuHPCR, and 5 subsequently received additional radiotherapy. A total of 2 patients developed progressive disease while receiving GemPOx. Myelosuppression and transaminitis were the most common treatment-related adverse events. With a mean follow-up of 44 months, 4 patients (3 NGGCTs, 1 germinoma) are alive without evidence of disease.

**Conclusions.** GemPOx demonstrates efficacy in facilitating stem cell mobilization, thus facilitating the feasibility of both HDCx and radiotherapy.

### Keywords

GemPOx | long-term survival | objective response rate | outcomes | relapsed intracranial GCTs

Primary intracranial germ cell tumors (GCTs) are rare heterogeneous tumors accounting for 3%–5% of all central nervous system (CNS) tumors in children and young adults, with an

overall incidence rate of 0.1 per 100 000 person-years in the United States. These tumors are classified as germinoma or nongerminomatous germ cell tumors (NGGCTs), with

germinoma accounting for two-thirds of all CNS-GCT cases.<sup>1-4</sup> Histologically, NGGCTs include yolk sac tumor (YST), embryonal carcinoma (EC), choriocarcinoma (CHC), and mixed malignant tumors in various combinations, often with teratoma or germinoma components.<sup>3,5</sup>

The overall cure rate for germinoma is more than 90% using either irradiation radiotherapy (RT) alone or reduced dose and volume irradiation preceded by responses to chemotherapy, such as carboplatin and etoposide.<sup>6-11</sup> However, patients with NGGCTs have poorer outcomes despite using multiagent neoadjuvant intensive chemotherapy regimens followed by full-dose craniospinal irradiation and focal boost. Overall survival (OS) rates have been reported ranging between 40% and 70%,<sup>5,12-16</sup> although with improved 5-year progression-free survival (PFS) and OS according to the most recent North American trial ACNS0122 and the Société Internationale d'Oncologie Pédiatrique (SIOP) GCT-96 trials.<sup>5,13</sup> Patients who experience relapse after initial therapy or those who progress during preradiotherapy (pre-RT) chemotherapy have only rarely been salvageable.<sup>17,18</sup> The use of high-dose marrow-ablative chemotherapy remains the most promising strategy for relapsed or refractory patients after achieving minimal residual disease with some form of reinduction strategy.<sup>3,18,19</sup> In order to achieve a state of minimal residual tumor prior to single-cycle marrow-ablative chemotherapy with autologous hematopoietic progenitor cell rescue (AuHPCR), it is imperative to identify new drugs or drug combinations that have the best chance of achieving such a tumor response.

Several studies have reported the efficacy of the novel reinduction regimen gemcitabine, paclitaxel, and oxaliplatin (GemPOx) in recurrent systemic GCTs.<sup>20-23</sup> We investigated the efficacy, tolerability, and outcomes of the GemPOx regimen in patients with confirmed relapsed or refractory intracranial GCTs, followed by single-cycle marrow-ablative chemotherapy using thiotepa, etoposide, and carboplatin with AuHPCR, in GemPOx-responsive patients (NCT01270724). We report the responses, adverse reactions, and survival rates with this combination regimen.

## Materials and Methods

### Patients Eligibility and Study Design

Between December 2009 and October 2019, patients of any age with relapsed or refractory primary CNS germinoma or NGGCTs, including endodermal sinus tumor YST, EC, CHC, and mixed germ cell tumors were eligible for the study. Patients with mature/immature teratoma were only eligible if they had tumor marker elevations consistent with malignant GCT elements. Eligibility was determined based on histologic confirmation and/or abnormal tumor markers (serum and/or cerebrospinal fluid [CSF]). Patients must either have a recurrence of CNS-GCT or should be refractory to initial therapy. In the absence of histological confirmation, patients were eligible with the following tumor marker elevations: serum and/or human chorionic gonadotropin beta (HCG- $\beta$ ) of more than 100 mIU/ml or any elevation of  $\alpha$ -fetoprotein (AFP) above 10 ng/ml and/or above

institutional norms in the serum, and CSF AFP greater than 2 ng/ml and/or above institutional norms. Patients without previous histological confirmation and without elevation of serum and/or CSF tumor markers (as defined above) were required to undergo surgery to confirm the diagnosis. Patients who received previously HDCx + AuHPCR or those who have received gemcitabine, oxaliplatin, and/or paclitaxel were not eligible.

The study initially employed a Simon 2-stage Minimax design with a 10% Type I error rate where the null and alternative response rates were 50% and 70%, respectively. That is, a response rate of 50% would be evidence that the study treatment is not promising whereas a response rate of 70% would indicate that the treatment is encouraging and warrant further study. First, 15 patients with relapsed GCT would be enrolled, treated, and assessed. If 8 or more patients exhibited a sufficient response after up to 4 cycles of reinduction treatment, then an additional 13 patients would be enrolled and treated. If a sufficient number of responses were observed at the end of the first stage, a total number of 28 patients with GCTs would be needed to enroll to attain 80% power. If the regimen were truly not effective, that is, if it induced sufficient responses only in 50% of NGGCT patients, then there is only a 9% chance that this design would reject the null in favor of the alternative hypothesis and an average of only 22 NGGCT patients would be treated with the regimen. On the other hand, if the regimen were truly effective, for example, if it induced sufficient responses in 70% of NGGCT patients, then there is an 80% chance that this design would conclude that the study treatment is promising and an average of 28 NGGCT patients would be enrolled ([Supplementary Figure 1](#)).

The protocol was approved by the institutional review board of the participating institutions, and informed consent was obtained at enrollment prior to the initiation of the treatment protocol.

### Study Endpoints and Response Definitions

The primary endpoint was the achievement of sufficient response allowing the patient to proceed to HDCx and AuHPCR after up to 4 cycles of reinduction chemotherapy. Responses were determined based on radiographic tumor assessments and tumor markers, as shown in [Table 1](#). Radiographic tumor responses were assessed in 3D using either T1 or T2-weighted images. Tumor markers were classified as normal levels, abnormal but not rising, or rising.

A radiographic sufficient response to treatment was defined as radiographic complete response (CR), partial response (PR), or stable disease (SD). We defined sufficient overall response as CR, partial response 1 (PR<sup>1</sup>), partial response 2 (PR<sup>2</sup>), or SD without dexamethasone dependency.

Complete response (CR) was defined as the disappearance of all target lesions and normalization of tumor markers. PR<sup>1</sup> was defined as  $\geq 65\%$  decrease in the sum of the products of the 3 perpendicular diameters of all target lesions and normalization of tumor markers, PR<sup>2</sup> was defined as CR or PR with abnormal but not rising tumor markers (ie, the levels of tumor markers were higher than the institution norms, but not showing a consistent up-trend or higher values when compared with the values at

**Table 1.** Overall Response Assessment

Target lesions	Nontarget lesions	New lesions	Markers	Overall response
			Normal/abnormal/rising	
CR	CR	No	Normal	CR
CR	Non-PD	No	Normal	PR <sup>1</sup>
PR	Non-PD	No	Normal	PR <sup>1</sup>
CR or PR	Non-PD	No	Abnormal—not rising	PR <sup>2</sup>
SD	Non-PD	No	Normal/abnormal—not rising	SD
Any	Any	Any	Abnormal-rising	PD
SD	Non-PD	Yes	Any	PD
PD	Any	Any	Any	PD
Any	PD	Any	Any	PD
Any	Any	Yes	Any	PD

Note: CR = complete response; PR = partial response; SD = stable disease; PD = progressive disease; PR<sup>1</sup> = partial response with normal markers; PR<sup>2</sup> = partial response with abnormal (but not rising) markers.

relapse). SD was defined as neither sufficient decrease to qualify as PR nor sufficient increase to qualify as progressive disease (PD), with either normal or abnormal but not rising tumor markers.

Progressive disease (PD) was defined as the development of a new disease or progression in any established lesions 40% or more increase in the product of perpendicular diameters, taking as reference the smallest product observed since the start of treatment, the appearance of one or more new lesions, or rising tumor markers.

Secondary endpoints included PFS and OS.

## Treatment

All patients received 2 cycles of the reinduction GemPOx chemotherapy regimen, and only those who failed to achieve a sufficient response and without PD proceeded with 2 additional cycles for a maximum of 4 reinduction cycles. The treatment regimen consisted of paclitaxel 170 mg/m<sup>2</sup> intravenous (IV) over 3 h, followed by gemcitabine 800 mg/m<sup>2</sup> IV infused over 1 h and oxaliplatin 100mg/m<sup>2</sup> IV over 2 h, on Day 1 of each cycle. Premedications with dexamethasone, ranitidine, and diphenhydramine were prescribed 30 min prior to paclitaxel infusion. Each cycle was defined as 14 days unless there was a delay in bone marrow recovery (absolute neutrophil count ANC  $\geq$  750/mm<sup>3</sup> and platelets  $\geq$ 75 000/mm<sup>3</sup>), but no more than 28 days of delay were allowed. Leukapheresis was completed after 2 induction cycles. Filgastrim (G-CSF 5 mcg/kg/day subcutaneously or intravenously) was only given for patients experiencing a delay in beginning the next cycle for 7 days or longer.

The consolidation phase consisted of a single cycle of marrow-ablative chemotherapy with carboplatin (AUC of 7/day  $\times$  3 days), thiotepa (300 mg/m<sup>2</sup>/day  $\times$  3 days), and etoposide (250 mg/m<sup>2</sup>/day  $\times$  3 days), followed by AuHPCR. The treatment protocol is shown in Figure 1.

For patients with germinoma who achieved sufficient response, further therapy was left to the discretion of the

treating physician; such patients could continue on the study to receive consolidation or be removed and treated with RT. For patients with intracranial NGGCTs, a “second look surgery” was strongly recommended for those who failed to achieve sufficient radiographic response (radiographic CR, PR, and SD) after 2–4 induction cycles, prior to proceeding to the consolidation phase. Patients with PD were to be taken off the study therapy.

Radiation therapy (RT) was permitted after recovery from consolidation and was particularly encouraged for patients who were RT-naïve, having progressed on initial chemotherapy. The volume and the field of RT were determined by the treating physician.

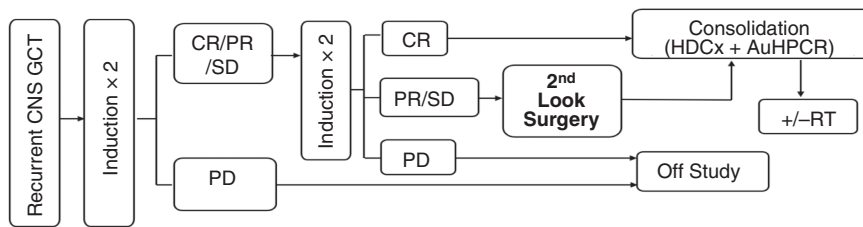
## Statistical Analysis

Data were summarized with standard descriptive statistics. PFS and OS estimates and corresponding 95% confidence intervals (CI) were calculated using the Kaplan–Meier method. Survival was measured from the time of enrollment in the study to the time of event (death or progression) or to the time of censoring. Patients without an event were considered censored at the date of last contact. Statistical analyses were completed using SAS software, version 9.4 (SAS Institute, Cary, NC, USA).

## Results

### Patients

A total of 9 patients with relapsed or refractory intracranial GCTs were enrolled in the NEXT/CNS-GCT-4 Consortium trial and received up to 4 cycles of reinduction chemotherapy with GemPOx. One *additional* patient had pathologically confirmed metastatic transformation from NGGCT to pure embryonal rhabdomyosarcoma, without any GCT elements and was not included in the analysis (Figure 2).



<b>Induction: up to 4 cycles</b>			
Paclitaxel	170 mg/m <sup>2</sup> IV over 3 hours	Day 1	Every 14 days
Gemcitabine	800 mg/m <sup>2</sup> IV over 1 hour	Day 1	Every 14 days
Oxaliplatin	100 mg/m <sup>2</sup> IV over 2 hours	Day 1	Every 14 days
<b>Consolidation</b>			
Days -8 to -6	Carboplatin	500 mg/m <sup>2</sup> or calculated by Calvert Formula (the smaller value of the two was utilized)	
Days -5 to -3	Thiotepa	300 mg/m <sup>2</sup> or 10 mg/kg (If < 36 months old)	
Days -5 to -3	Etoposide	250 mg/m <sup>2</sup> or 8.3 mg/kg (if < 36 months old)	
Days -2 and -1	Rest day		
Day 0	AuHPCR		
<b>Radiation Therapy</b>			
The volume and field of RT determined by the treating physician			

CNS GCT, central nervous system germ cell tumor; CR, complete response; PR, partial response; SD, stable disease; PD, progressive disease; RT, radiation therapy; HDCx, marrow-ablative chemotherapy; IV, intravenous; AuHPCR, autologous hematopoietic progenitor cell rescue.

**Figure 1.** The treatment protocol for GemPOx strategy for recurrent CNS GCTs. Reinduction regimen consisted of paclitaxel followed by gemcitabine then oxaliplatin given on Day 1, in a 14-day cycles, for a maximum of 4 induction cycles. Patients who achieved sufficient responses proceeded to receive the consolidation phase.

For the 9 patients, ages at enrollment ranged from 13 to 46 years (mean 20.1 years). Eight patients (88.9%) were male; the single germinoma patient was woman. Pathology was confirmed by histology and/or tumor markers, and complete workup. One patient had relapsed germinoma in the basal ganglia, and 8 patients had NGGCTs. The most common locations of relapsed tumors were the pineal region ( $n = 7$ , 77.8%). Four patients (44.4%) had metastatic disease at enrollment. Patient demographics and characteristics are shown in [Table 2](#).

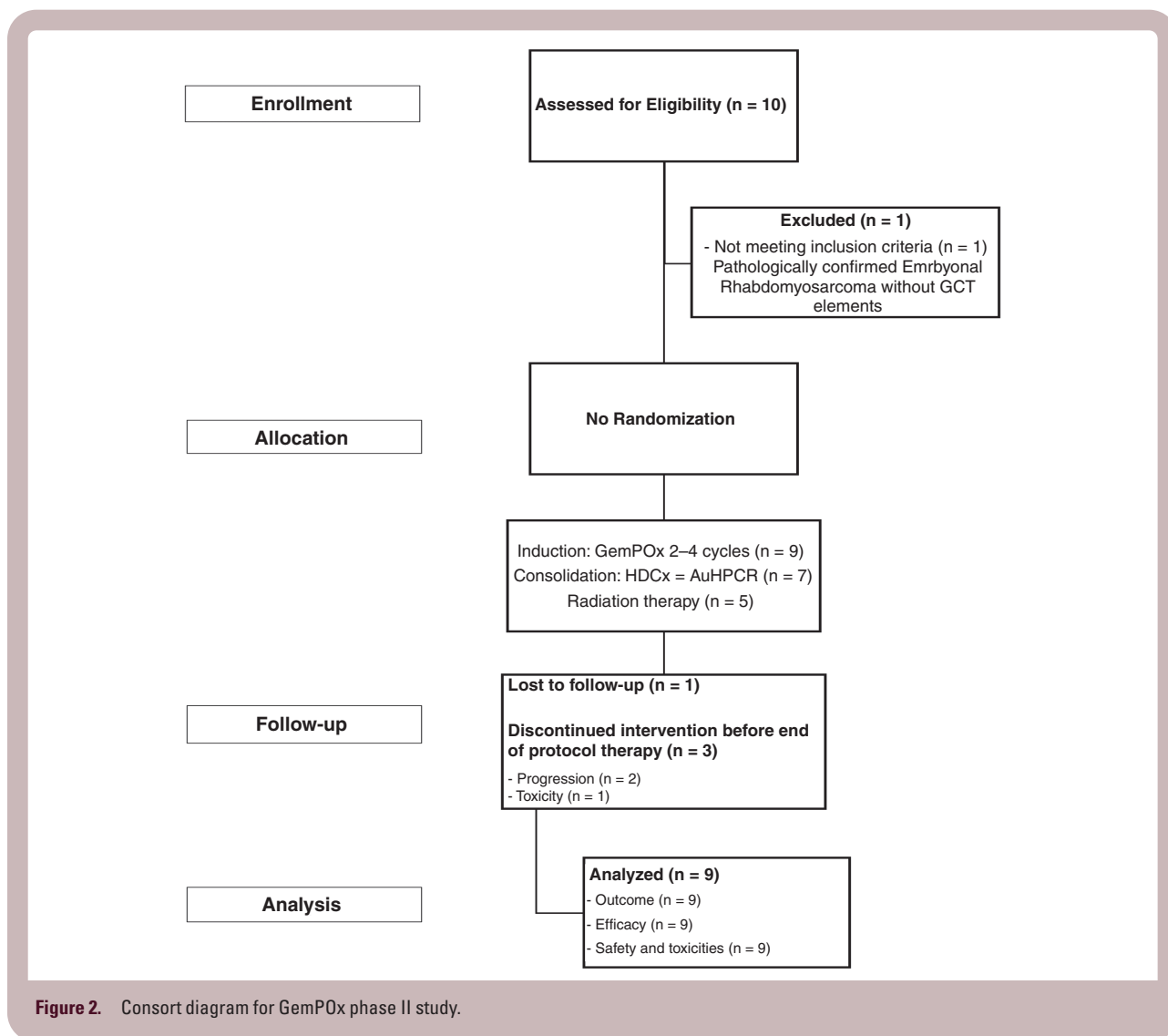
## Response

All 9 patients received at least 2 cycles of the GemPOx reinduction chemotherapy regimen. Leukapheresis was only completed after 2 cycles if the patient achieved sufficient response. The collection of peripheral hematopoietic progenitor cells was performed after the completion of the second induction cycle and before the beginning of the third or fourth cycle. Radiological responses to the reinduction

regimen in 7 patients were as follows: 3 patients achieved PRs, and 4 patients had SD. Response evaluations to reinduction regimen taking into account both radiographic and tumor marker response in those 7 patients were as follows: 3 patients achieved a PR with normalization of tumor markers (PR<sup>1</sup>), and 4 patients had SD with abnormal tumor markers but not rising ([Table 3](#), [Figure 2](#)).

Two patients (22.2%) developed PD during the induction regimen, of which one withdrew following 2 cycles for severe paclitaxel neurotoxicity followed by rapid tumor progression and death, while the second patient, with pure pineal CHC, progressed after the third GemPOx cycle, and ultimately died from tumor progression.

All 7 patients without disease progression on GemPOx subsequently underwent HDCx with AuHPCR, of whom 5 proceeded to receive some form of RT ([Table 3](#)). Of note, the patient who had relapsed germinoma received 4 cycles of induction regimen with GemPOx and then received tandem HDCx with AuHPCR off-study. One patient progressed during consolidation, while 2 patients progressed after completing RT, and ultimately died from tumor



progression. None of the patients underwent second-look surgery after completing GemPOx reinduction, before proceeding into the consolidation phase.

### Radiation Therapy

Data regarding the history of prior RT were available for 6 patients. Five patients underwent RT as part of initial treatment, before experiencing relapse and enrolling in this study. Within this group, 2 patients (designated as Patients 1 and 3) received ventricular field irradiation with boost, while 3 patients (Patients 7, 8, and 9) did receive RT but the specific dose and field details were unknown. Three patients (Patients 4, 5, and 6) did not receive RT due to the detection of disease progression (through radiographic and/or tumor markers) during induction chemotherapy as used in the Children's Oncology Group study ACNS0122 (ClinicalTrials.gov identifier: NCT00047320). One patient (Patient 2) did not receive any form of RT prior to enrollment in this study, and the rationale for this omission is unclear (Table 3).

Following completion of the consolidation phase, 5 patients received RT, 3 patients did not receive any form of RT and 1 patient died during consolidation. Of those who received RT, 2 patients progressed, 1 ultimately died of tumor progression, and 1 was lost to follow-up. Only 1 patient who did not receive RT is alive with no evidence of disease at the last follow-up. Due to the small sample size, meaningful statistical analysis could not be undertaken.

### Survival Outcomes

The mean follow-up was 44 months (range: 1–86 months). The 2-year, 3-year, and 5-year PFS for the whole cohort were 66.7% (CI: 28.2–87.9%), 55.6% (20.4–80.5%), and 44.4% (13.6–71.9%), respectively. Whereas, the 2-year, 3-year, and 5-year OS were 66.7% (CI: 28.2–87.9%), 66.7% (CI: 28.2–87.9%), and 55.6% (CI: 20.4–80.5%), respectively (Table 4, Supplementary Figure 2). Four patients were alive and without evidence of disease at the last follow-up, including the only patient with germinoma. Four patients



**Table 2:** Patient Demographics and Characteristics

Patients demographics and characteristics			
Characteristics	No.	%	
Eligible patients	9		
Age, mean (range), y	16.5 (7–49)		
Sex			
	Male	8	88.9%
	Female	1	11.1%
Primary tumor location			
	Pineal	8	88.9%
	Suprasellar	1	11.1%
Localized or metastatic			
	Localized	6	66.7%
	Metastatic	3	33.3%

died of disease, while 1 patient was lost to follow-up (Supplementary Figure 3 represents the Swimmer Plot graph for all treated patients).

### Correlation of Outcomes with Tumor Markers

Serum tumor markers (AFP and HCG- $\beta$ ) were collected at enrollment, following 4 cycles of reinduction with GemPOx, following HDCx with AuHPCR, and during follow-up. CSF tumor markers, on the other hand, were not obtained from every patient enrolled (Table 3). Three patients had serum AFP > 25 ng/ml at study enrollment, of whom all died of disease progression. One patient with intermediate elevation of serum AFP (between 10 and 25 ng/ml) ultimately relapsed following completion of the study protocol with very high serum AFP (>1000 ng/ml). All 4 patients who were alive at the last follow-up had normal serum AFP values at relapse (<10 ng/ml and/or below institutional norms), including the patient with relapsed germinoma. However, definitive conclusions could not be reached due to the small sample size (Supplementary Figure 4).

### Toxicity

Toxicity was reported using the Common Terminology Criteria for Adverse Events Version 4.0. No deaths were attributed to the study treatment. Overall, there were 25 Grade 3 and 4 hematologic toxicities and 38 nonhematologic adverse events during induction. The most common Grade 3 and 4 toxicities during the induction phase were neutropenia, thrombocytopenia, and transaminitis. One patient had an allergic reaction to paclitaxel (Grade 4) and one developed Grade 3 hyperglycemia during GemPOx treatment. During consolidation, Grade 3 and 4 toxicities included neutropenia, thrombocytopenia, and mucositis. One patient developed Grade 4 respiratory failure, sepsis, and kidney failure following stem cell infusion, followed by rapid clinical deterioration and ultimately death due to disease progression.

## Discussion

Despite the improved OS of patients with intracranial germ cell tumors with combination therapies,<sup>5,11,13,24</sup> the prognosis of patients who relapse following combined chemotherapy and RT remains poor. Currently, there are no standard salvage regimens considered optimally effective for these patients, and to date, the best results have been reported, either anecdotally or in retrospective studies, by employing a 2-stage approach: initial intensive reinduction chemotherapy to achieve minimal residual tumor, followed by HDCx with AuHPCR.<sup>18,19,25–27</sup> This is the first prospective trial yet conducted for patients with refractory and relapsed intracranial germ cell tumors. The study induction regimen of GemPOx was well tolerated with acceptable toxicities.

Patients with intracranial germinoma have a higher likelihood of achieving remission at recurrence with a variety of known active chemotherapy agents. On the other hand, relapsed or progressive intracranial NGGCTs are difficult to treat when occurring after combined chemotherapy and RT.<sup>9</sup> Furthermore, there are very few studies that have addressed the treatment in such patients, largely due to the rarity of this disease.<sup>27–29</sup> Novel salvage chemotherapy regimens are needed to achieve durable response in patients with recurrent or progressive CNS germ cell tumors, especially when combined with high-dose, marrow-ablative chemotherapy.<sup>18,19,27,30</sup> It is imperative that new drug combinations be evaluated that will have the best chance at achieving tumor response, and ultimately improve survival.<sup>9,27,31</sup> The clinical data in recurrent systemic germ cell tumors have provided a strong rationale for evaluating the combination of GemPOx and have shown to be effective in the treatment of recurrent systemic GCT arising outside the CNS.<sup>20,21,32</sup>

The German Testicular Cancer Study Group conducted a multicenter phase II clinical trial with the combination of gemcitabine, oxaliplatin, and paclitaxel in patients with platinum-refractory or multiply relapsed systemic GCT,<sup>20</sup> with an OS of 21% at 2 years.<sup>21,32</sup> Grade 3/4 myelosuppression was the most commonly encountered toxicity, which was also the most commonly observed adverse event in our cohort.

Perez-Somarriba et al. treated 3 patients with relapsed NGGCTs with a GemPOx reinduction regimen (off-study).<sup>33</sup> All patients demonstrated remarkable tumor response with normalization of tumor markers. One patient received consolidation treatment with HDCx and AuHPCR followed by craniospinal irradiation and remained in CR at 7 months following relapse. Wong et al. reported on 2 patients with recurrent pineal NGGCTs who were enrolled in the GemPOx trial.<sup>34</sup> Both patients achieved sufficient responses to reinduction with GemPOx per the study definition, followed by HDCx with AuHPCR and reirradiation: one patient was treated with Gamma Knife stereotactic radiosurgery of 18 Gy, while the second patient developed rising serum CSF AFP after he received standard of care chemotherapy and before his planned RT, prompting enrollment on the GemPOx trial. Following completion of treatment per protocol, he received CSI (36 Gy) with a boost to 54 Gy.

Table 3. Outcomes of Patients Enrolled on the Study

Patient	Age (y)	Sex	Pathology/Location	Prior RT	Pre-GemPOx serum markers	Pre-GemPOx CSF markers	Number of GemPOx cycles	GemPOx Radiographic response	Post-GemPOx serum markers	Post-GemPOx CSF markers	GemPOx Overall response
1.	16	M	NGGCT/ pineal (M0)	Yes, Ventricular field RT 30 Gy with boost to 45 Gy	Not elevated	AFP elevated [11.4 ng/ml]	4	PR	Not elevated	Not elevated [ $<0.9$ ng/ml]	PR1
2.	17	M	NGGCT/ Pineal (M2)	No	Not elevated	Not elevated	4	PR	Not elevated	Not elevated	PR1
3.	18	M	Suprasellar Pure YST/SS (M0)	Yes, Ventricular field RT 30 Gy with boost to 45 Gy	AFP elevated [1200 ng/ml]	Not evaluated	4	SD	AFP abnormal but not rising [28.7 ng/ml]	AFP abnormal but not rising [3.2 ng/ml]	SD
4.	17	M	NGGCT/ pineal (M0)	No (progression while receiving initial therapy per ACNS0122)	AFP elevated [19.3 ng/ml]	AFP elevated [26.5 ng/ml]	4	SD	Not elevated	AFP abnormal but not rising [5.2 ng/ml]	SD
5.	13	M	NGGCT/ Pineal + frontal (M2)	No (progression while receiving initial therapy per ACNS0122)	Not elevated	HCG- $\beta$ elevated [63 mIU/L]	4	SD	Not elevated	HCG- $\beta$ abnormal but not rising [10 mIU/L]	SD
6.	16	M	Pure CC/ Pineal (M2)	No (progression while receiving initial therapy per ACNS0122)	HCG- $\beta$ elevated [24.3 mIU/L]	Not evaluated	3	PD	Not evaluated	Not evaluated	PD
7.	21	F	Germinoma (M3)	Yes (UKN dose and field)	Not elevated	Not elevated	4	PR	Not evaluated	Not evaluated	PR1
8.	24	M	NGGCT/ Pineal (M0)	Yes (UKN dose and field)	AFP elevated [50.3 ng/ml] HCG- $\beta$ elevated [137 mIU/L]	AFP elevated [58 ng/ml] HCG- $\beta$ elevated [1588 mIU/L]	4	SD	AFP abnormal but not rising [11.8 ng/ml] HCG- $\beta$ not elevated [2mIU/L]	Not evaluated	SD
9.	46	M	Pure YST/ Pineal (M0)	Yes (UKN dose and field)	AFP elevated [43.6 ng/ml]	Not evaluated	2	PD	Not evaluated	Not evaluated	PD
Patient	AuHPCR	Post-AuHPCR serum markers	Post-AuHPCR CSF markers	Overall response	Post-HDC Adjuvant therapy	Follow-up (months)	Outcomes				
1.	Yes	Not elevated	Not elevated [AFP $<0.9$ ng/ml]	CR	Yes—Gamma Knife	71	NED				
2.	Yes	Not elevated	Not elevated	PR1	Yes—CSI 36 Gy + boost	65	NED				
3.	Yes	AFP abnormal but not rising [28.8 ng/ml]	Not elevated [AFP 1.4 ng/ml]	SD	Yes—Focal	52	DOD				
4.	Yes	Not elevated	AFP abnormal but not rising [6.8 ng/ml]	SD	Yes—CSI 36 Gy + boost	65	Lost to follow-up				
5.	Yes	Not elevated	Not elevated [HCG- $\beta$ $<8$ mIU/L]	PR1	Yes—CSI 36 Gy + boost	80	NED				
6.	No	Not evaluated	Not evaluated	N/A	No	11	DOD				
7.	Yes (but tandem/ off-study)	Not evaluated	Not evaluated	N/A	No	86	NED				
8.	Yes—PD during consolidation	Not evaluated	Not evaluated	PD	No	5	DOD				
9.	No	Not evaluated	Not evaluated	N/A	No	1	DOD				

Note: AuHPCR = autologous hematopoietic progenitor cell rescue; CC = choriocarcinoma; CSI = craniospinal irradiation; DOD = dead of disease; GemPOx = gemcitabine, paclitaxel and oxaliplatin; NGGCT = nongerminomatous germ cell tumor; NED = no evidence of disease; N/A = not available; PD = progressive disease; PR = partial response; RT = radiation therapy; SD = stable disease; UKN = unknown; YST = yolk sac tumor.



**Table 4.** The PFS and OS for the Whole Cohort

Year	PFS (95% CI)	OS (95% CI)
2-y	66.7% (28.2–87.9%)	66.7% (28.2–87.9%)
3-y	55.6% (20.4–80.5%)	66.7% (28.2–87.9%)
5-y	44.4% (13.6–71.9%)	55.6% (20.4–80.5%)

Note: CI = confidence intervals; OS = overall survival; PFS = progression-free survival.

In spite of the lack of a standard treatment approach, the survival rate of patients with relapsed CNS GCTs, especially those with NGGCTs, is improved when reinduction chemotherapy is followed by HDCx and AuHPCR.<sup>19,27,30,35</sup> Alkylating agents are active against both CNS and systemic GCTs.<sup>17</sup> Thiotepa crosses the blood–brain barrier efficiently.<sup>36,37</sup> The combination of carboplatin, etoposide, and thiotepa has been used in malignant brain tumors and proven to be well tolerated.<sup>38</sup> Modak et al. assembled the largest experience with thiotepa-based HDCx regimens followed by AuHPCR in the treatment of high-risk patients with recurrent GCTs.<sup>19</sup> With a median follow-up of 35 months, 7 of the 9 patients with recurrent germinomas were alive, while 4 of the 12 NGGCTs patients were alive. Of the 8 patients who achieved a CR with salvage protocols before consolidation with HDCx, 5 survived without assessable disease 6–48 months after HDCx.

Furthermore, the efficacy of HDCx with AuHPCR depends on the ability to mobilize hematopoietic stem cells successfully,<sup>39</sup> a process considered of great challenge, especially in patients with prior exposure to bone marrow-suppressive intensive chemotherapy regimens and/or full-dose craniospinal irradiation.<sup>40</sup> The ideal regimen for stem cell mobilization is typically disease-specific and should have the ability to reduce tumor burden and enhance mobilization.<sup>41</sup> In our cohort, 8 patients had successful stem cell mobilization and collection after 2 cycles of reinduction with GemPOx, while achieving sufficient responses and disease stabilization.

Patients with recurrent germinoma tend to have encouraging salvage rates with only standard-dose chemotherapy and/or reirradiation. Murray et al. reported the outcomes of 11 patients with relapsed germinoma following initial treatment with the European SIOP-CNS-GCT-96 trial protocol. The outcomes were similar regardless of therapy received at relapse (standard-dose chemotherapy vs HDCx with AuHPCR).<sup>18</sup> On the other hand, Kubota et al. suggested that the use of HDCx may eliminate the need for reirradiation in patients with recurrent germinoma who achieved CR with reinduction chemotherapy.<sup>25</sup> Nevertheless, the OS is improved in patients who achieved CR with reinduction regimens.<sup>25,26</sup>

Unlike germinomas, patients with relapsed NGGCTs do not have an encouraging prognosis. Murray et al reported a 5-year OS of only 9% in patients who received HDCx with AuHPCR followed by reirradiation.<sup>18</sup> Callec et al. reported similar results with a retrospective analysis of relapsed intracranial GCTs from pooled clinical trials (including the SFOP-TGM-TC 90/92, the SIOP-GCT-96), and the National Childhood

Solid Tumor Registry.<sup>27</sup> Twenty-five patients with relapsed NGGCTs were identified, of whom 13 of the 18 patients who received HDCx survived, while none of the 4 patients who received neither HDCx nor reirradiation were alive.

Moreover, response to reinduction therapy influences the overall outcomes in patients with relapsed disease.<sup>25,27,42,43</sup> Abu Arja et al. demonstrated that the presence of high-risk or poor prognostic histology and a short time to relapse may adversely affect the response rate to reinduction regimens.<sup>9</sup> Furthermore, achieving CR to reinduction chemotherapy and receiving HDCx with AuHPCR were associated with improved survival in patients with relapsed NGGCT.<sup>43</sup> However, data suggest that patients with PR and without overt progression may still be salvageable as well.<sup>44</sup> In our cohort, 7 patients (77.8%) proceeded to receive HDCx with AuHPCR, after achieving sufficient responses to the GemPOx reinduction chemotherapy regimen. Three patients achieved radiographic PR with an overall response of PR1, and 4 patients achieved radiographic and overall responses of SD.

The prognostic value of elevated tumor markers in patients with relapsed GCTs remains unclear. However, higher serum or CSF AFP levels may be associated with poorer survival.<sup>5,43</sup> While our sample size was too small to draw any conclusions, it is of note that all 4 survivors, including the patient with relapsed germinoma, had serum AFP values of less than 10 ng/ml at study enrollment (Supplementary Figure 4). Furthermore, the absence of CSF AFP data for certain patients precludes the correlation of serum AFP levels with treatment outcomes.

Despite the predefined study design and planned duration of the clinical trial, the study enrollment was not fully achieved which contributed to a major limitation of the study. This is likely attributed to the rarity of this tumor type, highlighting the difficulties in completing such prospective trials without international collaborations. Furthermore, heterogeneity in presentation, post-transplant therapy, and the small sample size posed challenges in establishing conclusive biostatistical analysis.

The rapid advancement of genomic technologies has significantly advanced our understanding of the molecular mechanisms underlying iGCTs, potentially providing valuable insights into prognosis and innovative treatment strategies. CNS GCTs commonly exhibit mutations in the MAPK and PI3K pathways, with the KIT mutation being particularly prevalent. Notably, overexpression of KIT serves as a marker for germinoma, supporting the hypothesis that migrating primordial germ cells are the cell of origin in germinomas and highlighting KIT as a potential therapeutic target.<sup>45–48</sup>

Moreover, transcriptomic analysis has further revealed distinct biological characteristics of intracranial germ cell tumors (iGCTs), including significant heterogeneity within the tumor microenvironment. These findings hold promise in informing future clinical trials. Interestingly, immune-cell infiltration is enhanced in nongerminomatous germ cell tumors (NGGCTs), characterized by an immune-suppressive phenotype. This observation may help explain the treatment resistance observed in NGGCTs and also presents an opportunity for immune-based therapies.<sup>48</sup>

MicroRNAs (miRNAs) have been implicated in the pathogenesis of iGCTs and may play a role as biomarkers for early diagnosis and the detection of relapse. However, further prospective studies are warranted to validate the role of miRNAs in iGCTs and their potential clinical applications.<sup>49,50</sup>

Overall, the integration of genomic advancements, characterization of key molecular alterations, exploration of the tumor microenvironment, and investigation of miRNAs provide promising avenues for improving our understanding of pediatric CNS GCTs and may facilitate the development of personalized and targeted therapeutic strategies.

In conclusion, the current study still represents the only prospective clinical trial yet conducted assessing the efficacy and tolerability of a novel reinduction chemotherapy regimen followed by HDCx with AuHPCR in patients with relapsed or refractory intracranial GCTs. Our results, despite the small number of patients enrolled, demonstrate that the GemPOx regimen is safe, tolerable, and effective in stem cell mobilization, hence, may be considered a reinduction regimen in patients with relapsed or refractory intracranial GCTs, when followed with HDCx and RT.

## Supplementary Material

Supplementary material is available online at *Neuro-Oncology* (<https://academic.oup.com/neuro-oncology>).

### Conflict of interest statement

All authors reported no conflict of interest.

### Funding

This trial was supported and funded by The NEXT Consortium. J.L.F. acknowledges the receipt of a grant from “The Childhood Brain Tumor Foundation” (2008–2010) in support of the study development and conduct. S.L.G. received funding from “Making Headway Foundation” for administrative support.

### Authorship statement

J.L.F., Y.A.L., D.M.P., P.G., V.K.P., S.L.G., J.C.A., R.H.A., K.O., and A.S.M. were the investigators of the clinical trial, and were involved in data collection. In addition, M.B. and J.P. were involved in the data collection. K.K.W. and M.D.N. completed the central radiology and radiotherapy review. F.H.G. completed the pathology review. M.S. and J.S. performed the statistical analysis and wrote the first draft of the manuscript. All the authors have been involved in the revision of the manuscript, and have read and approved the final version.

### Previous presentation of the material at a meeting, workshop or other event

Preliminary results were presented at the following meetings: The Third International CNS Germ Cell Tumor Symposium in Cambridge, UK 2013; The Twentieth International Conference on Brain Tumor Research and Therapy, in California, USA 2014; The Third Biennial Conference on Pediatric Neuro-oncology Basic and Translational Research, in California, USA 2015; The Fourth International CNS-GCT Symposium, Happono-En, Tokyo, Japan 2015; The Annual Meeting of the British Neuro-oncology Society, Nottingham, UK 2015; The Nineteenth International Symposium on Pediatric Neuro-oncology, Karuizawa, Japan 2020.

### Data availability

The authors confirm that the data supporting the findings of this study are available within the articles and its [Supplementary Materials](#). Original deidentified eligibility checklist, laboratory results, imaging reports, toxicity reports, and clinical notes are stored in a secured Box server and a secured link will be available from the corresponding author (M.S.) on request.

### Affiliations

Division of Hematology and Oncology, St. Louis Children's Hospital, Washington University School of Medicine, St. Louis, Missouri, USA (M.S.); Division of Hematology, Oncology, Blood and Marrow Transplant, Nationwide Children's Hospital and Ohio State University College of Medicine, Columbus, Ohio, USA (M.B., J.S., J.L.F.); Departments of Ophthalmology, Neurology, and Neurosurgery, University of California, Davis, Sacramento, California, USA (Y.A.L.); Department of Neurological Surgery, Ohio State University Wexner Medical Center, Columbus, Ohio, USA (D.M.P.); Division of Neuro-Oncology, Ohio State University Wexner Medical Center, James Cancer Center, Columbus, Ohio, USA (P.G.); Department of Neuro-oncology, MD Anderson Cancer Center, Houston, Texas, USA (V.K.P.); Department of Pediatrics, New York University Grossman School of Medicine, New York, New York, USA (S.L.G., J.C.A.); Division of Hematology and Oncology, Cancer and Blood Disease Institute, Children's Hospital Los Angeles and Keck School of Medicine of University of Southern California, Los Angeles, California, USA (K.K.W., K.O'H., A.S.M.); Department of Radiation Oncology, University of Southern California, Los Angeles, California, USA (K.K.W.); Department of Radiology, Children's Hospital of Los Angeles, Los Angeles, California, USA (M.D.N.); Department of Pathology, Children's Hospital of Los Angeles, Los Angeles, California, USA (F.H.G.); Phoenix Children's Center for Cancer & Blood Disorders, University of Arizona School of Medicine—Phoenix, and Mayo Clinic, Arizona, USA (R.H.A.); Division of Hematology and Oncology, Cancer and Blood Disease Institute, Children's Hospital Los Angeles, California, USA (J.P.); Division of Pediatric Hematology/Oncology, Children's Hospital of Alabama and the University of Alabama at Birmingham, Birmingham, Alabama, USA (G.D.)

## References

- Gittleman H, Cioffi G, Vecchione-Koval T, et al. Descriptive epidemiology of germ cell tumors of the central nervous system diagnosed in the United States from 2006 to 2015. *J Neurooncol*. 2019; 143(2):251–260.
- McCarthy BJ, Shibui S, Kayama T, et al. Primary CNS germ cell tumors in Japan and the United States: an analysis of 4 tumor registries. *Neuro Oncol*. 2012; 14(9):1194–1200.
- Murray MJ, Bartels U, Nishikawa R, et al. Consensus on the management of intracranial germ-cell tumours. *Lancet Oncol*. 2015; 16(9):e470–e477.
- Thakkar JP, Chew L, Villano JL. Primary CNS germ cell tumors: current epidemiology and update on treatment. *Med Oncol*. 2013; 30(2):496.
- Calaminus G, Frappaz D, Kortmann RD, et al. Outcome of patients with intracranial non-germinomatous germ cell tumors—lessons from the SIOP-CNS-GCT-96 trial. *Neuro Oncol*. 2017; 19(12):1661–1672.
- Bamberg M, Kortmann RD, Calaminus G, et al. Radiation therapy for intracranial germinoma: results of the German cooperative prospective trials MAKEI 83/86/89. *J Clin Oncol*. 1999; 17(8):2585–2592.
- Calaminus G, Kortmann R, Worch J, et al. SIOP CNS GCT 96: final report of outcome of a prospective, multinational nonrandomized trial for children and adults with intracranial germinoma, comparing craniospinal irradiation alone with chemotherapy followed by focal primary site irradiation for patients with localized disease. *Neuro Oncol*. 2013; 15(6):788–796.
- Alapetite C, Brisse H, Patte C, et al. Pattern of relapse and outcome of non-metastatic germinoma patients treated with chemotherapy and limited field radiation: the SFOP experience. *Neuro Oncol*. 2010; 12(12):1318–1325.
- Abu Arja MH, Stanek JR, Finlay JL, AbdelBaki MS. Re-induction chemotherapy regimens in patients with recurrent central nervous system mixed malignant germ cell tumors. *Childs Nerv Syst*. 2018; 34(11):2179–2186.
- Tagliarieni LAJ, Kretschmar C, Donahue B, Sands S. Outcomes of radiotherapy alone vs. chemotherapy followed by response-based radiotherapy for newly diagnosed primary CNS germinoma (COG ACNS 0232). *Blood Cancer*. 2012;59:965–1152. <https://doi.org/10.1002/pbc.24295>
- Bouffet E, Baranzelli MC, Patte C, et al. Combined treatment modality for intracranial germinomas: results of a multicentre SFOP experience. *Br J Cancer*. 1999; 79(7–8):1199–1204.
- Robertson PL, DaRosso RC, Allen JC. Improved prognosis of intracranial non-germinoma germ cell tumors with multimodality therapy. *J Neurooncol*. 1997; 32(1):71–80.
- Goldman S, Bouffet E, Fisher PG, et al. Phase II trial assessing the ability of neoadjuvant chemotherapy with or without second-look surgery to eliminate measurable disease for nongerminomatous germ cell tumors: a children's oncology group study. *J Clin Oncol*. 2015; 33(22):2464–2471.
- Fangusaro J, Wu S, MacDonald S, et al. Phase II trial of response-based radiation therapy for patients with localized CNS nongerminomatous germ cell tumors: a children's oncology group study. *J Clin Oncol*. 2019; 37(34):3283–3290.
- Echevarria ME, Fangusaro J, Goldman S. Pediatric central nervous system germ cell tumors: a review. *Oncologist*. 2008; 13(6):690–699.
- Baranzelli MC, Patte C, Bouffet E, et al. An attempt to treat pediatric intracranial alphaFP and betaHCG secreting germ cell tumors with chemotherapy alone SFOP experience with 18 cases Societe Francaise d'Oncologie Pediatrique. *J Neurooncol*. 1998; 37(3):229–239.
- Allen JC, Bosl G, Walker R. Chemotherapy trials in recurrent primary intracranial germ cell tumors. *J Neurooncol*. 1985; 3(2):147–152.
- Murray MJ, Bailey S, Heinemann K, et al. Treatment and outcomes of UK and German patients with relapsed intracranial germ cell tumors following uniform first-line therapy. *Int J Cancer*. 2017; 141(3):621–635.
- Modak S, Gardner S, Dunkel IJ, et al. Thiotepa-based high-dose chemotherapy with autologous stem-cell rescue in patients with recurrent or progressive CNS germ cell tumors. *J Clin Oncol*. 2004; 22(10):1934–1943.
- Bokemeyer C, Oechsle K, Honecker F, et al.; German Testicular Cancer Study Group. Combination chemotherapy with gemcitabine, oxaliplatin, and paclitaxel in patients with cisplatin-refractory or multiply relapsed germ-cell tumors: a study of the German Testicular Cancer Study Group. *Ann Oncol*. 2008; 19(3):448–453.
- Seidel C, Oechsle K, Lorch A, et al. Efficacy and safety of gemcitabine, oxaliplatin, and paclitaxel in cisplatin-refractory germ cell cancer in routine care—Registry data from an outcomes research project of the German Testicular Cancer Study Group. *Urol Oncol*. 2016; 34(4):167.e21–167.e28.
- Sadeghi S, Quinn DI, Tsao-Wei DD, et al. Phase II study of gemcitabine, oxaliplatin, and paclitaxel (GOT) on a 2-weekly schedule in patients (pts) with refractory germ cell tumor (rGCT): Final results. *J Clin Oncol*. 2013; 31(Suppl 15):4531–4531.
- Necchi A, Nicolai N, Mariani L, et al. Combination of paclitaxel, cisplatin, and gemcitabine (TPG) for multiple relapses or platinum-resistant germ cell tumors: long-term outcomes. *Clin Genitourin Cancer*. 2014; 12(1):63–69.e1.
- da Silva NS, Cappellano AM, Diez B, et al. Primary chemotherapy for intracranial germ cell tumors: results of the third international CNS germ cell tumor study. *Pediatr Blood Cancer*. 2010; 54(3):377–383.
- Kubota H, Umeda K, Kagehiro K, et al. High-dose chemotherapy with autologous stem cell transplantation spares re-irradiation for recurrent intracranial germinoma. *Pediatr Blood Cancer*. 2018; 65(8):e27104.
- Baek HJ, Park HJ, Sung KW, et al. Myeloablative chemotherapy and autologous stem cell transplantation in patients with relapsed or progressed central nervous system germ cell tumors: results of Korean Society of Pediatric Neuro-Oncology (KSPNO) S-053 study. *J Neurooncol*. 2013; 114(3):329–338.
- Callec L, Lardy-Cleaud A, Guerrini-Rousseau L, et al. Relapsing intracranial germ cell tumours warrant retreatment. *Eur J Cancer*. 2020; 136:186–194.
- Sawamura Y, Ikeda JL, Tada M, Shirato H. Salvage therapy for recurrent germinomas in the central nervous system. *Br J Neurosurg*. 1999; 13(4):376–381.
- Hu YW, Huang PI, Wong TT, et al. Salvage treatment for recurrent intracranial germinoma after reduced-volume radiotherapy: a single-institution experience and review of the literature. *Int J Radiat Oncol Biol Phys*. 2012; 84(3):639–647.
- Bouffet E. The role of myeloablative chemotherapy with autologous hematopoietic cell rescue in central nervous system germ cell tumors. *Pediatric Blood Cancer*. 2010; 54(4):644–646.
- Faure-Contier C, Orbach D, Cropet C, et al. Salvage therapy for refractory or recurrent pediatric germ cell tumors: the French SFCE experience. *Pediatr Blood Cancer*. 2014; 61(2):253–259.
- Oechsle K, Kollmannsberger C, Honecker F, et al.; German Testicular Cancer Study Group. Long-term survival after treatment with gemcitabine and oxaliplatin with and without paclitaxel plus secondary surgery in patients with cisplatin-refractory and/or multiply relapsed germ cell tumors. *Eur Urol*. 2011; 60(4):850–855.
- Perez-Somarrriba M, Moreno-Tejero ML, Rozas MI, et al. Gemcitabine, paclitaxel, and oxaliplatin (GEMPOX) in the treatment of relapsed/refractory intracranial nongerminomatous germ cell tumors. *Pediatr Blood Cancer*. 2020; 67(2):e28089.
- Wong K, Opimo AB, Olch AJ, et al. Re-irradiation of recurrent pineal germ cell tumors with radiosurgery: report of two cases and review of literature. *Cureus*. 2016; 8(4):e585–e585.

35. Osorio DS, Dunkel LJ, Cervone KA, et al. Tandem thiotepa with autologous hematopoietic cell rescue in patients with recurrent, refractory, or poor prognosis solid tumor malignancies. *Pediatr Blood Cancer*. 2018; 65(1):e26776.
36. Strong JM, Collins JM, Lester C, Poplack DG. Pharmacokinetics of intraventricular and intravenous N,N',N''-triethylenethiophosphoramidate (thiotepa) in rhesus monkeys and humans. *Cancer Res*. 1986; 46(12 Pt 1):6101–6104.
37. Heideman RL, Cole DE, Balis F, et al. Phase I and pharmacokinetic evaluation of thiotepa in the cerebrospinal fluid and plasma of pediatric patients: evidence for dose-dependent plasma clearance of thiotepa. *Cancer Res*. 1989; 49(3):736–741.
38. Mason WP, Grovas A, Halpern S, et al. Intensive chemotherapy and bone marrow rescue for young children with newly diagnosed malignant brain tumors. *J Clin Oncol*. 1998; 16(1):210–221.
39. Porfyriou E, Letsa S, Kosmas C. Hematopoietic stem cell mobilization strategies to support high-dose chemotherapy: A focus on relapsed/refractory germ cell tumors. *World J Clin Oncol*. 2021; 12(9):746–766.
40. Necchi A, Miceli R, Pedrazzoli P, et al. Predictors of CD34+ cell mobilization and collection in adult men with germ cell tumors: implications for the salvage treatment strategy. *Clin Genitourin Cancer*. 2014; 12(3):196–202.e1.
41. Hopman RK, DiPersio JF. Advances in stem cell mobilization. *Blood Rev*. 2014; 28(1):31–40.
42. Abu-Arja MH, Osorio DS, Stanek JR, Finlay JL, AbdelBaki MS. GCT-40 prognostic factors for patients with relapsed central nervous system (CNS) non-germinomatous germ cell tumors (NGGCTs). *Neuro-Oncol*. 2020; 22(Supplement\_3):iii335–iii336.
43. Abu-Arja MH, Osorio DS, Lassaletta A, et al. Prognostic factors for patients with relapsed central nervous system nongerminomatous germ cell tumors. *Pediatr Blood Cancer*. 2022; 69(1):e29365.
44. Panosyan EH, Ikeda AK, Chang VY, et al. High-dose chemotherapy with autologous hematopoietic stem-cell rescue for pediatric brain tumor patients: a single institution experience from UCLA. *J Transplant*. 2011; 2011:740673.
45. Ichimura K, Fukushima S, Totoki Y, et al.; Intracranial Germ Cell Tumor Genome Analysis Consortium. Recurrent neomorphic mutations of MTOR in central nervous system and testicular germ cell tumors may be targeted for therapy. *Acta Neuropathol*. 2016; 131(6):889–901.
46. Wang L, Yamaguchi S, Burstein MD, et al. Novel somatic and germline mutations in intracranial germ cell tumours. *Nature*. 2014; 511(7508):241–245.
47. Kamakura Y, Hasegawa M, Minamoto T, Yamashita J, Fujisawa H. C-kit gene mutation: common and widely distributed in intracranial germinomas. *J Neurosurg*. 2006; 104(3 Suppl):173–180.
48. Takami H, Elzawahry A, Mamatjan Y, et al. Transcriptome and methylome analysis of CNS germ cell tumor finds its cell-of-origin in embryogenesis and reveals shared similarities with testicular counterparts. *Neuro Oncol*. 2022; 24(8):1246–1258.
49. Murray MJ, Ajithkumar T, Harris F, et al. Clinical utility of circulating miR-371a-3p for the management of patients with intracranial malignant germ cell tumors. *Neurooncol Adv*. 2020; 2(1):vdaa048.
50. Schönberger S, Mohseni MM, Ellinger J, et al. MicroRNA-profiling of miR-371–373- and miR-302/367-clusters in serum and cerebrospinal fluid identify patients with intracranial germ cell tumors. *J Cancer Res Clin Oncol*. 2023; 149(2):791–802.