

UCSF

UC San Francisco Previously Published Works

Title

Encephalitis of Unclear Origin Diagnosed by Brain Biopsy : A Diagnostic Challenge

Permalink

<https://escholarship.org/uc/item/69h0z8qq>

Journal

JAMA Neurology, 72(1)

ISSN

2168-6149

Authors

Gelfand, Jeffrey M

Genrich, Gillian

Green, Ari J

et al.

Publication Date

2015

DOI


10.1001/jamaneurol.2014.2376

Peer reviewed

Original Investigation

Encephalitis of Unclear Origin Diagnosed by Brain Biopsy A Diagnostic Challenge

Jeffrey M. Gelfand, MD, MAS; Gillian Genrich, MD, MPH; Ari J. Green, MD, MAS; Tarik Tihan, MD, PhD;
Bruce A. C. Cree, MD, PhD, MAS

 CME Quiz at
jamanetworkcme.com

IMPORTANCE Brain biopsy specimens that exhibit encephalitis without specific histopathologic features pose a diagnostic challenge to neuropathologists and neurologists. Such cases are generally referred to pathologically as encephalitis, not otherwise specified (ENOS). A systematic approach to diagnostic evaluation in such patients is challenging, and currently there is no generally accepted algorithm.

OBJECTIVE To examine ultimate diagnostic outcomes in patients with ENOS diagnosed by brain biopsy.

DESIGN, SETTING, AND PARTICIPANTS This retrospective case series at the University of California, San Francisco, Medical Center, a tertiary care urban neurosciences center, studied patients with encephalitis diagnosed by brain biopsy from January 1, 1983, through December 31, 2011.

EXPOSURES Brain biopsy.

MAIN OUTCOMES AND MEASURES Clinical and neuropathologic diagnosis.

RESULTS Among 58 patients who met the inclusion criteria for the study, the original pathologic diagnosis was ENOS in 49 patients (84%). The median age was 40 years (interquartile range, 27-53 years), 35 patients were male, and 13 had known human immunodeficiency virus or AIDS. Median time from onset of symptoms to brain biopsy was 66 days (interquartile range, 18-135 days). For the 29 patients in whom material for pathologic analysis was still available, additional neuropathologic review led to a more specific categorization in 10 (34%). Clinical detail and follow-up information was available for 42 patients, and a specific diagnosis was reached with the help of ancillary testing and/or clinical follow-up in 12 patients. Despite a comprehensive neuropathologic review with additional studies and information, 27 patients still had to be classified in the ENOS category at the end of the study.

CONCLUSIONS AND RELEVANCE ENOS is the most common initial type of encephalitis diagnosed by brain biopsy. In such patients, it may be worth having the biopsy materials reviewed again in a comprehensive fashion by a neuropathologist because additional review led to a more specific categorization in one-third of our cases. Ancillary testing, clinical correlation, and clinical follow-up establish more specific diagnoses in some patients. ENOS still remains a diagnostic challenge after all these efforts in many cases. Current algorithms are of limited value. More advanced methods and better diagnostic algorithms are needed to characterize these patients.

JAMA Neurol. 2015;72(1):66-72. doi:10.1001/jamaneurol.2014.2376
Published online November 3, 2014.

Author Affiliations: Multiple Sclerosis and Neuroinflammation Center, Department of Neurology, University of California, San Francisco (Gelfand, Green, Cree); Department of Pathology, University of California, San Francisco (Genrich, Tihan).

Corresponding Author: Jeffrey M. Gelfand, MD, MAS, Multiple Sclerosis and Neuroinflammation Center, Department of Neurology, University of California, San Francisco, 675 Nelson Rising Ln, PO Box 3206, San Francisco, CA 94158-3206 (jeffrey.gelfand@ucsf.edu).

Encephalitis is a neurologic syndrome characterized by variable neurologic dysfunction that is accompanied by inflammation of the brain parenchyma.^{1,2} Encephalitis can have several potential causes, including infectious, primary inflammatory, neoplastic, and paraneoplastic origins. Despite major advances in the diagnosis of infectious diseases³ and increasing recognition of antibody-associated encephalitic syndromes,^{4,5} the cause of encephalitis remains unknown in 40% to 70% of cases.⁶⁻⁹

Although considered the criterion standard for some causes of encephalitis,¹⁰⁻¹³ brain biopsy is typically a diagnostic modality of last resort. Prior clinical practice guidelines for encephalitis recommend that a brain biopsy be considered when the diagnosis is unclear or there is rapid clinical deterioration.^{1,2,14} In neuropathologic practice, brain biopsies that reveal encephalitis but do not yield additional insight into the origin are reported as encephalitis, not otherwise specified (pathologic ENOS). Some patients with ENOS diagnosed by biopsy also have clinical ENOS. Some patients suspected of having other diseases, such as neoplasms or demyelinating or degenerative diseases, are also sometimes diagnosed as having ENOS by brain biopsy. Patients who are pathologically and clinically considered to have ENOS pose a challenge in management. As such, ENOS is a vexing entity for neurologists and pathologists, and a systematic approach to diagnostic evaluation in such patients is needed.

In this retrospective case series from a large urban academic medical center, we performed a systematic review of all patients diagnosed as having ENOS by brain biopsy. The main goal of the study was to examine diagnostic outcomes in these patients to help improve management of future cases.

Methods

The University of California, San Francisco, Committee on Human Research approved the study protocol and approved a waiver of informed consent for this retrospective review. The Department of Pathology, University of California, San Francisco, electronic database was searched by 2 of the authors (G.G. and T.T.) for all cases from January 1, 1983, through December 31, 2011, in which the term *encephalitis* was included in the final pathology report. One of the authors (J.M.G.) reviewed available paper and electronic medical records and abstracted clinical, laboratory, and radiologic details using a standardized data collection form. Two study pathologists (G.G. and T.T.), initially masked to clinical follow-up, again reviewed available slides and original pathologic material, including additional special stains and immunohistochemical stains when necessary.

For statistical analyses, the χ^2 test was used to analyze associations between abnormal contrast enhancement on magnetic resonance imaging (MRI) and final diagnosis and year of biopsy and final diagnosis. $P < .05$ was considered statistically significant. STATA statistical software, version 12.0 (StataCorp), was used for these analyses.

Results

From January 1, 1983, through December 31, 2011, we found 128 patients for whom the term *encephalitis* was identified in the final pathology report (Figure). Of those, 31 autopsy cases were excluded from analysis because the pathologic diagnosis of encephalitis was established only at autopsy. The causes of encephalitis in the autopsy group included the following: human immunodeficiency virus (HIV), 7 patients; cytomegalovirus, 5 patients; herpes simplex virus, 4 patients; paraneoplastic disease, 3 patients; *Aspergillus*, 2 patients; tuberculosis, 1 patient; rabies, 1 patient; *Pseudallescheria boydii*, 1 patient; amebiasis, 1 patient; and West Nile virus, 1 patient. In the remaining 5 patients, the cause could not be determined by autopsy and after review of clinical records, and the diagnosis was ENOS. Among the remaining 97 patients with brain biopsy specimens in which encephalitis was observed, 39 patients receiving outside consultation were excluded because of insufficient tissue and/or clinical information.

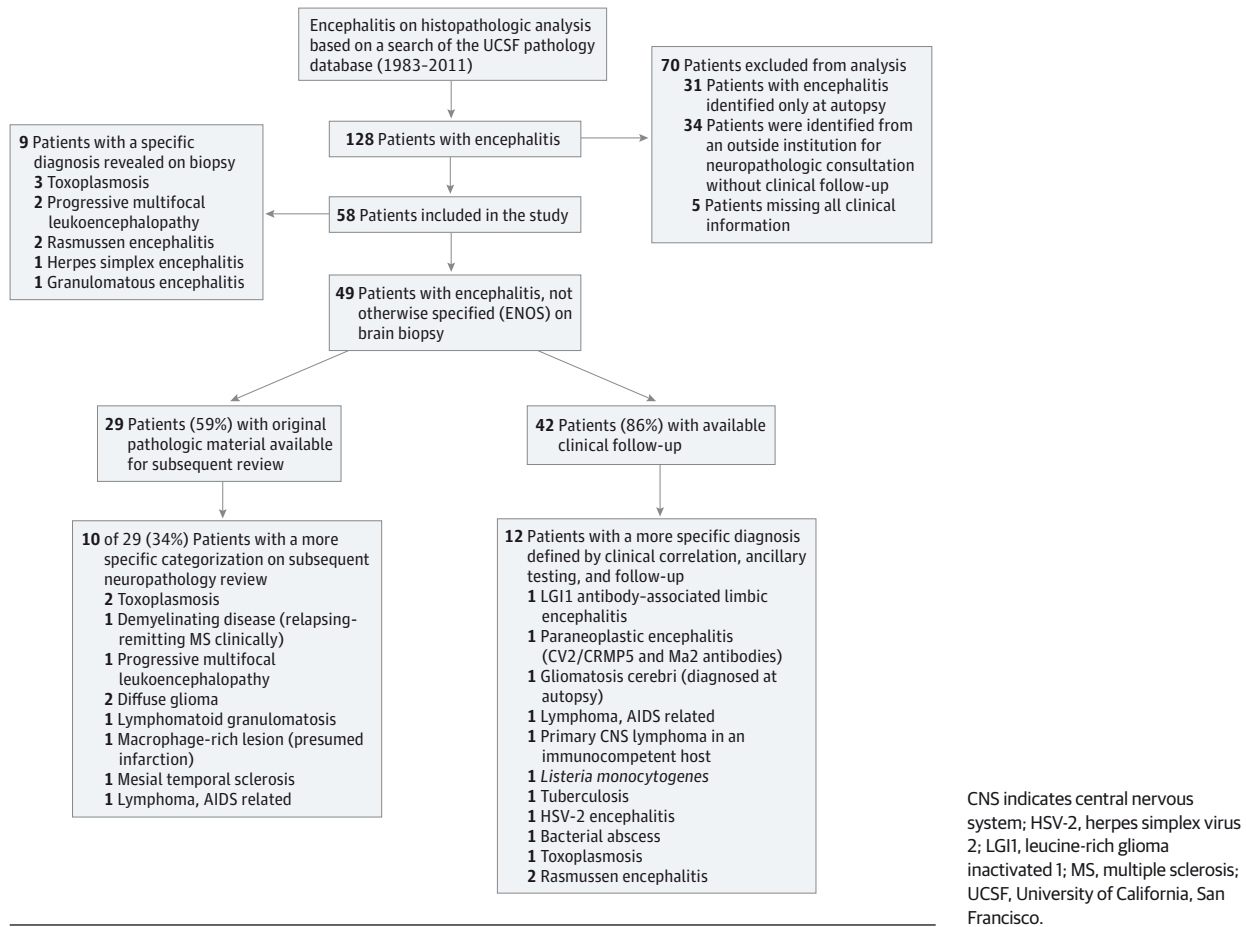
Fifty-eight patients met the inclusion criteria and were included in the study. Among the 58 patients (23 females and 35 males) who met inclusion criteria, the median age was 40 years (interquartile range, 23-52 years; range, 0-82 years), and 13 (22%) had known HIV/AIDS.

Thirty-five patients underwent stereotactic biopsy, 11 patients underwent open biopsy, and 10 patients underwent resection. Operative data on the type of surgery were missing for 2 patients. There was no association between biopsy type and identification of a more specific cause of encephalitis on brain biopsy ($P = .44$). Data about contrast enhancement at the biopsy site were available for 50 patients. The biopsy site revealed contrast enhancement on MRI or computed tomography in 31 (62%) of all 50 biopsies and 26 (76%) of 34 stereotactic biopsies. The biopsy site was contrast enhancing in 22 of 36 patients (61%) who underwent preoperative brain MRI and 10 of 15 patients (67%) who underwent only preoperative head computed tomography.

The initial pathologic diagnosis was ENOS in 49 patients. The remaining 9 patients had specific diagnoses, which included the following: toxoplasmosis, 3 patients; progressive multifocal leukoencephalopathy, 2 patients; Rasmussen encephalitis, 2 patients; herpes simplex virus encephalitis, 1 patient; and granulomatous encephalitis, 1 patient. Among the 49 patients (22 females and 27 males) with pathologic ENOS, the median age was 40 years (interquartile range, 27-53 years), and 9 (18%) had known HIV/AIDS. The median time from symptom onset to biopsy was 66 days (interquartile range, 18-135 days).

Original pathologic material was available for review for 29 patients (59%) and was unavailable or of insufficient quantity or quality for reanalysis in 20 patients (41%). Subsequent neuropathologic review led to a more specific categorization in 10 of the 29 patients (34%). These diagnoses included the following: demyelinating disease, 1 patient; progressive multifocal leukoencephalopathy, 1 patient; diffuse glioma, 2 patients; lymphomatoid granulomatosis, 1 patient; toxoplasmosis, 2 patients; a macrophage-rich lesion compatible with

Figure. Study Design



ischemia, 1 patient; mesial temporal sclerosis, 1 patient; and AIDS-associated central nervous system lymphoma, 1 patient. The remaining 19 patients were still classified as having ENOS after additional neuropathologic review. Among the 10 patients whose conditions were reclassified after pathologic review, additional immunohistochemical analyses were useful in reclassifying the diagnosis in 5. In the remaining patients, additional sections from the blocks obtained for review purposes were compatible with the specific diagnoses rather than ENOS, and such features had not been appreciated in the original sections or may not have been present in the original material.

We were not able to demonstrate a statistically significant association between contrast enhancement at the biopsy site and the ability to render a specific cause of encephalitis histopathologically ($P = .79$), but all 4 stereotactic biopsies that led to a more specific diagnosis had contrast enhancement at the biopsy target.

Clinical records and postbiopsy clinical follow-up information were available for 42 patients with pathologic ENOS at a median of 1 year (range, 0–21 years). Among these patients, 26 (62%) presented with multifocal active lesions on brain imaging, 6 (14%) had a solitary mass lesion, 6 (14%) had focal encephalopathy (of whom 5 had clinical and

radiographic features of limbic encephalopathy), 2 (5%) exhibited seizures with unihemispheric abnormalities or atrophy, and 2 (5%) had a global encephalopathy with non-specific imaging features. Among the 19 patients who still had ENOS after additional neuropathologic review as part of this study, a definite diagnosis was evident in 6 (32%) based on ancillary testing, subsequent clinical information, and clinical follow-up (Table). These diagnoses included the following: primary central nervous system lymphoma, 2 patients; Rasmussen encephalitis, 2 patients; paraneoplastic encephalitis (CV2/CRMP5 and Ma2), 1 patient; and *Listeria monocytogenes*, 1 patient. Of these 19 patients, 3 were lost to follow-up, and the cause was still not apparent in 10 patients.

Of 20 patients with ENOS in which the original pathologic material was unavailable for review, follow-up clinical information was available for 11 patients (55%). A more specific clinical diagnosis was apparent in 6 of these 11 patients (55%) (Table). The diagnoses included tuberculosis, herpes simplex virus 2, toxoplasmosis, bacterial abscess, and leucine-rich glioma inactivated 1 encephalitis. The sixth patient was subsequently diagnosed as having gliomatosis cerebri on autopsy. The remaining 5 patients were still classified as having ENOS.

Table. Patients With Pathologic ENOS With a More Specific Diagnosis on Ancillary Testing and Clinical Correlation

Patient No./Sex/ Age, y	Clinical Presentation	Imaging	CSF Examination Findings	Initial Pathologic Diagnosis by Brain Biopsy	Pathologic Diagnosis on Subsequent Review of Slides	Final Diagnosis	Ancillary Data That Contributed to Final Diagnosis
1/F/45	Progressive ophthalmoplegia, hemiparesis, ataxia, memory loss, diabetes insipidus	MRI: Multifocal T2 hyperintensities in the frontal and temporal lobes and brainstem (some had abnormal diffusion initially)	Elevated IgG index; 2 OCBs	ENOS	ENOS	Paraneoplastic encephalitis	Serum CRMP5 and Ma2 antibodies (Athena Diagnostics)
2/F/67	Subacute weakness	MRI: Subacute weakness, numbness, multiple cranial neuropathies	1 OCB, other study results normal	ENOS	ENOS	Primary CNS lymphoma	Lymphomatous vitritis; ultimately treated with high-dose IV methotrexate with improvement
3/F/61	AIDS in pre-HAART era, subacute weakness and sensory loss, 16-kg weight loss	MRI: Multifocal enhancing lesions in the frontal lobes, periventricular white matter, and subependyma	42/μL WBCs, total protein level of 183 mg/dL, normal glucose level, 2 OCBs	ENOS	ENOS	Primary CNS lymphoma, AIDS associated	Clinical and radiologic follow-up; treated with radiotherapy and chemotherapy
4/F/50	Rapidly progressive gait instability for 2.5 weeks, 2 days of altered mental status	MRI: Multifocal ring-enhancing lesions	24 WBCs, normal glucose and total protein levels	ENOS	ENOS	<i>Listeria monocytogenes</i>	Blood culture and brain tissue culture; treated with IV sulfamethoxazole and glucocorticoids; no apparent neurologic deficits at 10 years of follow-up
5/M/8	Medically refractory epilepsy	Hemispheric abnormality	Unavailable	ENOS	ENOS	Rasmussen encephalitis	Clinical and radiologic follow-up; pathologic review of subsequent lobectomy
6/M/7	Medically refractory epilepsy, concern raised about astrocytoma	Hemispheric abnormality	Unavailable	ENOS	ENOS	Rasmussen encephalitis	Clinical and imaging follow-up; additional biopsy
7/F/55	Headaches, nausea, alexia, progressive neurologic decline	MRI: Heterogeneously infiltrating enhancing process in the left parietotemporal lobes with extension across the corpus callosum	Normal	ENOS	Unavailable	Gliomatosis cerebri	Patient underwent 3 additional brain biopsies of contrast-enhancing targets, which were favored to be CNS lymphoma or demyelinating disease; gliomatosis cerebri was diagnosed at autopsy
8/F/75	Rapidly progressive amnesia, facial-brachial dystonic seizures, hyponatremia	MRI: Left greater than right insular T2/FLAIR hyperintensities	4 OCBs	ENOS	Unavailable	LG11 antibody encephalitis	Serum VGKC complex and LG11 antibodies
9/F/term infant	Seizures, poor feeding on first day of life	CT: Diffuse bilateral low densities primarily in the right temporal lobe, diffuse brain edema	82/μL WBCs, total protein level of 170 mg/dL, glucose level of 51 mg/dL	ENOS	Unavailable	HSV-2 encephalitis	Viral culture; subsequently developed spastic quadriparesis, microcephaly, and developmental delay
10/M/48	Fever, altered mental status	MRI: >30 Ring-enhancing lesions	6/μL WBCs, normal glucose and protein levels, 1 OCB, IgG index of 0.76 (mildly elevated)	ENOS	Unavailable	Bacterial abscess	Subsequent development of a recurrent abscess in the cervical cord, cultures of which subsequently yielded <i>Streptococcus pneumoniae</i> , <i>Streptococcus viridans</i> , and <i>Propionibacterium</i> ; blood cultures positive for <i>S pneumoniae</i>
11/M/27	AIDS in pre-HAART era, headache, nausea	CT: Solitary ring-enhancing lesion	16/μL WBCs, normal glucose level, protein level of 80 mg/dL	ENOS	Unavailable	Toxoplasmosis	Serum serologic testing and response to therapy; during clinical follow-up, developed scrofula and PCP and died 13 months later
12/M/52	Memory loss, headache, weight loss, incontinence, hyponatremia, history of intravenous drug use, HIV negative	MRI: Bilateral frontal lobe T2 hyperintensities, leptomeningeal enhancement	90/μL WBCs, total protein level of 328 mg/dL, and glucose level of 28 mg/dL	ENOS	Unavailable	TB meningo-encephalitis	Subsequent CSF studies, including positive TB PCR result and improvement with 4-drug TB therapy

Abbreviations: CNS, central nervous system; CSF, cerebrospinal fluid; CT, computed tomography; ENOS, encephalitis, not otherwise specified; FLAIR, fluid-attenuated inversion recovery; HAART, highly active antiretroviral therapy; HIV, human immunodeficiency virus; HSV-2, herpes simplex virus 2; IV, intravenous; LG11, leucine-rich glioma inactivated 1; MRI, magnetic resonance imaging; OCB, oligoclonal band in CSF unmatched in a corresponding serum

sample; PCP, *Pneumocystis carinii* (*jiroveci*) pneumonia; PCR, polymerase chain reaction; TB, tuberculosis; VGKCc, voltage-gated potassium channel complex; WBC, white blood cell.

SI conversion factors: To convert protein to grams per liter, multiply by 10; glucose to millimoles per liter, multiply by 0.0555.

In summary, 22 of the 49 patients with an original diagnosis of ENOS could be classified into a more specific disease category that resulted in more informed, and sometimes better, management. The remaining 27 patients (55%) still had the nonspecific diagnosis of ENOS.

Discussion

There are several lessons from this study of patients with ENOS diagnosed by brain biopsy. First, ENOS was the most common initial histopathologic diagnosis among all types of encephalitis, implying that standard histologic evaluation is unlikely to yield specific causes unless additional analyses are performed. Second, in some patients, it may well be worth having the biopsy materials reviewed again by an expert neuropathologist with the use of currently available special tests because review led to reclassification of some of the cases after a more comprehensive neuropathologic analysis. Third, clinical correlation and follow-up coupled with targeted ancillary testing for neoplastic, paraneoplastic, and infectious causes of brain inflammation led to a more specific diagnosis in some patients. This finding suggests that it would be prudent to carefully follow up patients with an initial diagnosis of pathologic ENOS with regular reassessment and use of newly emerging diagnostic tests.

Encephalitis is a rare finding among patients undergoing brain biopsy. In a previous study¹⁵ at our institution on the diagnostic utility of brain biopsy in HIV-negative patients, encephalitis was the final diagnosis in 11% of the patients and was the third most common diagnosis among patients with rapidly deteriorating neurologic conditions (after malignant lymphoma and prion disease). However, a specific cause of encephalitis was identified in only a few such patients.¹⁵ In a later series that analyzed brain biopsy findings in rapidly progressive neurologic disease, encephalitis was identified in 4% of patients and “mild, nonspecific inflammatory changes” were observed in 20 of 51 patients (39%).¹⁶ Earlier series examining brain biopsy specimens for evaluation of multifocal brain lesions reported that presumed viral encephalitis was the final neuropathologic diagnosis in 3% of patients.¹⁷ In HIV-positive patients with mass lesions, encephalitis accounted for a few cases, and, although often presumed to be viral, no specific cause could be identified in many published series.^{18,19} These observations are consistent with our findings that ENOS is the rule rather than the exception for most patients with any type of encephalitis diagnosed by brain biopsy.

There are many potential explanations for the observation that a more specific diagnosis could not be rendered despite additional neuropathologic review and clinical follow-up in more than half of the patients with ENOS diagnosed by brain biopsy: (1) the causative pathologic mechanism could have been transient and the biopsy performed too late; (2) the biopsy may have been performed too early before specific lesions were established; (3) the biopsy may have been insufficient or biased by sampling; (4) the causative agent may not have been detectable using standard pathologic techniques; and/or (5) follow-up was too short or incomplete. In addition,

limited assessment in the pathology laboratory may also overlook a specific pathologic process, and an increasing number of more sophisticated analytical techniques may lead to revision of the diagnosis when subsequently reviewed. In our series, additional evaluation using current analytical techniques approximately a decade after most biopsy specimens had been collected led to a more specific or alternate diagnosis in some cases. When coupled with additional clinical information and follow-up, this effort yielded specific information in a substantial proportion of patients (45%).

In our series, a difference was found between the rates of ENOS diagnoses at autopsy (6%) vs brain biopsy (84%). This observation suggests that limited or insufficient sampling may also lead to a diagnosis of ENOS. One such example was the limited sampling in one of our patients who was subsequently diagnosed as having gliomatosis cerebri only at autopsy. Some of the patients with more specific diagnostic features on a representative biopsy specimen subsequently received a diagnosis with the aid of additional testing or clinical information, which also suggests that sampling could be an important problem for cases diagnosed as ENOS.

Evaluation of other organ systems at autopsy may also provide additional diagnostic data not clinically considered during the acute illness (such as discovery of a likely culprit tumor in probable paraneoplastic encephalitis cases). However, this discrepancy may also be explained by a selection bias due to the referral pattern and indication for autopsy and biopsy. For example, in this series, 7 patients with AIDS had evidence of HIV encephalitis at autopsy even though the encephalitis had not been the primary cause of death.

In large North American and European series that examined patients with a clinical presentation of encephalitis, a specific cause is identified in only 30% to 60% despite extensive evaluation. In these series, identified causes of encephalitis consisted almost entirely of infectious and primary inflammatory origins.⁶⁻⁹ The results from our analysis indicate that malignant tumors, particularly lymphoma and gliomatosis cerebri, should also be diagnostic considerations for pathologic ENOS. The presence of nonspecific inflammatory changes in tissue samples from patients with malignant tumors of the central nervous system may lead to the diagnosis of pathologic ENOS, only to confirm the specific diagnosis with subsequent representative sampling.²⁰

The importance of obtaining representative samples for accurate diagnosis is well known, especially for smaller samples. Neuropathologic and neurosurgical studies²¹⁻²⁴ have attempted to correlate sample location with radiologic abnormality with the site of biopsy, and there is good evidence that more directed sampling can increase diagnostic yield. However, we were not able to demonstrate that biopsy specimens obtained from enhancing sites had a better diagnostic yield than those that did not sample the enhancing lesions. The inability to demonstrate such an association may be related to the number of cases reviewed. Larger studies might demonstrate a better correlation between certain radiologic features and diagnostic yield in patients with encephalitis.

This study has important limitations. First, we identified encephalitis cases using a pathology database search and de-

financed ENOS pathologically. Patients with a clinical presentation of encephalitis who did not undergo brain biopsy were not captured in this data set, and this analysis is not meant to answer the question of diagnostic utility of brain biopsy for suspected encephalitis. Second, the number of cases in which a final diagnosis became apparent may have been underestimated because of missing data or limited clinical follow-up in a subset of cases. Additional reasons for not determining a final diagnosis may include the inability to generate new slides from fresh-frozen specimens or cut new blocks from fixed specimens for advanced immunohistochemistry studies that were not available at the time of biopsy.

This study also surveyed patients during a 30-year period in which many new diagnostic entities were identified, including blood and cerebrospinal fluid testing for antibodies targeting specific neuronal antigens, which may have helped to reveal a final diagnosis in some of the earlier ENOS cases.⁴ Nonetheless, this study provides a rationale for comprehensive neuropathologic assessment, subsequent follow-up, and

period inquiry about newly established tests for patients diagnosed as having ENOS. Prospective studies are needed to more fully characterize long-term clinical outcomes of patients with ENOS, and our results demonstrate the necessity of developing additional and more sophisticated analytical techniques and follow-up strategies to understand the cause of disease in patients who remain in the ENOS category even after comprehensive neuropathologic and laboratory analysis and clinical follow-up.

Conclusions

ENOS is the most common category of encephalitis diagnosed by brain biopsy. Ancillary testing, clinical correlation, and clinical follow-up establish more specific diagnoses in some patients. More advanced methods and better neuropathologic and clinical diagnostic algorithms are needed to characterize these patients.

ARTICLE INFORMATION

Accepted for Publication: July 7, 2014.

Published Online: November 3, 2014.
doi:10.1001/jamaneurol.2014.2376.

Author Contributions: Dr Gelfand had full access to all the data in the study and takes responsibility for the integrity of the data and the accuracy of the data analysis.

Study concept and design: All authors.

Acquisition, analysis, or interpretation of data: Gelfand, Genrich, Tihan, Cree.

Drafting of the manuscript: Gelfand.

Critical revision of the manuscript for important intellectual content: All authors.

Statistical analysis: Gelfand, Cree.

Administrative, technical, or material support: Genrich, Green.

Study supervision: Green, Tihan, Cree.

Conflict of Interest Disclosures: Dr Gelfand reported receiving compensation for medical legal consulting related to central nervous system inflammatory disease. Dr Green reported providing consulting services for Prana Pharmaceuticals, Novartis, Biogen, Roche, and Acorda Pharmaceuticals. He also reported serving on an end point adjudication committee for a Biogen-sponsored trial and providing expert legal advice for Mylan Pharmaceuticals. Dr Cree reported receiving personal compensation for consulting from Abbvie, Biogen Idec, EMD Serono, Genzyme/sanofi-aventis, MedImmune, Novartis, and Teva Neurosciences and contracted research support (including clinical trials) from Acorda, Avanir, Biogen Idec, EMD Serono, Hoffman La Roche, and Novartis. No other disclosures were reported.

Funding/Support: This study was supported by an American Academy of Neurology Clinical Research Training Fellowship (Dr Gelfand) and National Institutes of Health National Center for Advancing Translational Sciences grant KL2TR000143 (Dr Gelfand).

Role of the Funder/Sponsor: The funding sources had no role in the design and conduct of the study; collection, management, analysis, and interpretation of the data; preparation, review, or

approval of the manuscript; and decision to submit the manuscript for publication.

Additional Contributions: Sam Arnow, BA (University of California, San Francisco), assisted with data analysis and figure generation. He did not receive compensation.

REFERENCES

- Solomon T, Michael BD, Smith PE, et al; National Encephalitis Guidelines Development and Stakeholder Groups. Management of suspected viral encephalitis in adults: Association of British Neurologists and British Infection Association National Guidelines. *J Infect*. 2012;64(4):347-373.
- Tunkel AR, Glaser CA, Bloch KC, et al; Infectious Diseases Society of America. The management of encephalitis: clinical practice guidelines by the Infectious Diseases Society of America. *Clin Infect Dis*. 2008;47(3):303-327.
- Aurelius E, Johansson B, Sköldenberg B, Staland A, Forsgren M. Rapid diagnosis of herpes simplex encephalitis by nested polymerase chain reaction assay of cerebrospinal fluid. *Lancet*. 1991;337(8735):189-192.
- Lancaster E, Dalmau J. Neuronal autoantigens: pathogenesis, associated disorders and antibody testing. *Nat Rev Neurol*. 2012;8(7):380-390.
- Gable MS, Sheriff H, Dalmau J, Tilley DH, Glaser CA. The frequency of autoimmune N-methyl-D-aspartate receptor encephalitis surpasses that of individual viral etiologies in young individuals enrolled in the California Encephalitis Project. *Clin Infect Dis*. 2012;54(7):899-904.
- Glaser CA, Honarmand S, Anderson LJ, et al. Beyond viruses: clinical profiles and etiologies associated with encephalitis. *Clin Infect Dis*. 2006;43(12):1565-1577.
- Granerod J, Ambrose HE, Davies NW, et al; UK Health Protection Agency (HPA) Aetiology of Encephalitis Study Group. Causes of encephalitis and differences in their clinical presentations in England: a multicentre, population-based prospective study. *Lancet Infect Dis*. 2010;10(12):835-844.
- Huppatz C, Durrheim DN, Levi C, et al. Etiology of encephalitis in Australia, 1990-2007. *Emerg Infect Dis*. 2009;15(9):1359-1365.
- Mailles A, Stahl JP; Steering Committee and Investigators Group. Infectious encephalitis in France in 2007: a national prospective study. *Clin Infect Dis*. 2009;49(12):1838-1847.
- Kohl S, James AR. Herpes simplex virus encephalitis during childhood: importance of brain biopsy diagnosis. *J Pediatr*. 1985;107(2):212-215.
- Morawetz RB, Whitley RJ, Murphy DM. Experience with brain biopsy for suspected herpes encephalitis: a review of forty consecutive cases. *Neurosurgery*. 1983;12(6):654-657.
- Sköldenberg B, Forsgren M, Alestig K, et al. Acyclovir versus vidarabine in herpes simplex encephalitis: randomised multicentre study in consecutive Swedish patients. *Lancet*. 1984;2(8405):707-711.
- Whitley RJ, Alford CA, Hirsch MS, et al. Vidarabine versus acyclovir therapy in herpes simplex encephalitis. *N Engl J Med*. 1986;314(3):144-149.
- Kneen R, Michael BD, Menon E, et al; National Encephalitis Guidelines Development and Stakeholder Groups. Management of suspected viral encephalitis in children: Association of British Neurologists and British Paediatric Allergy, Immunology and Infection Group national guidelines. *J Infect*. 2012;64(5):449-477.
- Josephson SA, Papanastassiou AM, Berger MS, et al. The diagnostic utility of brain biopsy procedures in patients with rapidly deteriorating neurological conditions or dementia. *J Neurosurg*. 2007;106(1):72-75.
- Schuette AJ, Taub JS, Hadjipanayis CG, Olson JJ. Open biopsy in patients with acute progressive neurologic decline and absence of mass lesion. *Neurology*. 2010;75(5):419-424.
- Franzini A, Leocata F, Giorgi C, Allegranza A, Servello D, Broggi G. Role of stereotactic biopsy in multifocal brain lesions: considerations on 100 consecutive cases. *J Neurol Neurosurg Psychiatry*. 1994;57(8):957-960.

18. Hornef MW, Iten A, Maeder P, Villemure JG, Regli L. Brain biopsy in patients with acquired immunodeficiency syndrome: diagnostic value, clinical performance, and survival time. *Arch Intern Med*. 1999;159(21):2590-2596.
19. Viswanathan R, Ironside J, Bell JE, Brett RP, Whittle IR. Stereotaxic brain biopsy in AIDS patients: does it contribute to patient management? *Br J Neurosurg*. 1994;8(3):307-311.
20. Vates GE, Chang S, Lamborn KR, Prados M, Berger MS. Gliomatosis cerebri: a review of 22 cases. *Neurosurgery*. 2003;53(2):261-271.
21. Perez-Cruet MJ, Adelman L, Anderson M, Roth PA, Ritter AM, Saris SC. CT-guided stereotactic biopsy of nonenhancing brain lesions. *Stereotact Funct Neurosurg*. 1993;61(3):105-117.
22. Soo TM, Bernstein M, Provias J, Tasker R, Lozano A, Guha A. Failed stereotactic biopsy in a series of 518 cases. *Stereotact Funct Neurosurg*. 1995;64(4):183-196.
23. Tsermoulas G, Mukerji N, Borah AJ, Mitchell P, Ross N. Factors affecting diagnostic yield in needle biopsy for brain lesions. *Br J Neurosurg*. 2013;27(2):207-211.
24. Waters JD, Gonda DD, Reddy H, Kasper EM, Warnke PC, Chen CC. Diagnostic yield of stereotactic needle-biopsies of sub-cubic centimeter intracranial lesions. *Surg Neurol Int*. 2013;4(suppl 3):S176-S181.

Call for Papers

JAMA Neurology is announcing a new journal feature, Clinical Challenge, which will be published quarterly, under the section editorship of Lawrence S. Honig, MD, PhD. The goal of this feature is to present short clinical problems to challenge readers to arrive at the correct diagnosis from a small data set, including images. Readers will see a short clinical synopsis and relevant images or laboratory information allowing them to exercise their diagnostic skills. Actual correct diagnosis and a brief discussion will be available on the following page of the journal or on the Discussion tab online. The overall format of this feature will be like that of the current highly successful feature What is Your Diagnosis?, which has been running since January 2011, available on the web quarterly, only online. Clinical Challenge will be the successor to this feature but will be an integral journal section, viewable interactively online and in the print version of the journal, and indexed like other articles. *JAMA Neurology* welcomes submissions to this feature, for which any submission should include a maximum of up to 3 authors. The format must include (1) a paragraph introducing and describing the clinical case (no more than 250 words); (2) 1 to 3 figures including imaging, electrophysiological, and/or other laboratory data; (3) 4 multiple-choice potential answers for diagnosis; and (4) a paragraph of discussion (no more than 600 words) disclosing the actual diagnosis (confirmed by conclusive tissue pathology, genetic, or other test), and including up to 10 references. We invite submissions through the standard *JAMA Neurology* submissions process.
