

Lawrence Berkeley National Laboratory

Recent Work

Title

EVIDENCE FOR FUNCTION OF ABERRANT THYROID TISSUE IN THE THYMUS OF RATS

Permalink

<https://escholarship.org/uc/item/6bj9r8sq>

Authors

Asling, C. Willet
Durbin, Patricia W.
Parrott, Marshall W.
et al.

Publication Date

1956-11-01

UNIVERSITY OF
CALIFORNIA

*Radiation
Laboratory*

EVIDENCE FOR FUNCTION OF ABERRANT THYROID
TISSUE IN THE THYMUS OF RATS

TWO-WEEK LOAN COPY

*This is a Library Circulating Copy
which may be borrowed for two weeks.
For a personal retention copy, call
Tech. Info. Division, Ext. 5545*

This report was prepared as an account of Government sponsored work. Neither the United States, nor the Commission, nor any person acting on behalf of the Commission:

- A. Makes any warranty or representation, express or implied, with respect to the accuracy, completeness, or usefulness of the information contained in this report, or that the use of any information, apparatus, method, or process disclosed in this report may not infringe privately owned rights; or
- B. Assumes any liabilities with respect to the use of, or for damages resulting from the use of any information, apparatus, method, or process disclosed in this report.

As used in the above, "person acting on behalf of the Commission" includes any employee or contractor of the Commission to the extent that such employee or contractor prepares, handles or distributes, or provides access to, any information pursuant to his employment or contract with the Commission.

DISCLAIMER

This document was prepared as an account of work sponsored by the United States Government. While this document is believed to contain correct information, neither the United States Government nor any agency thereof, nor the Regents of the University of California, nor any of their employees, makes any warranty, express or implied, or assumes any legal responsibility for the accuracy, completeness, or usefulness of any information, apparatus, product, or process disclosed, or represents that its use would not infringe privately owned rights. Reference herein to any specific commercial product, process, or service by its trade name, trademark, manufacturer, or otherwise, does not necessarily constitute or imply its endorsement, recommendation, or favoring by the United States Government or any agency thereof, or the Regents of the University of California. The views and opinions of authors expressed herein do not necessarily state or reflect those of the United States Government or any agency thereof or the Regents of the University of California.

UCRL-3581
Health and Biology

UNIVERSITY OF CALIFORNIA

Radiation Laboratory
Berkeley, California

Contract No. W-7405-eng-48

EVIDENCE FOR FUNCTION OF ABERRANT THYROID TISSUE
IN THE THYMUS OF RATS

C. Willet Asling, Patricia W. Durbin, Marshall W. Parrott,
Muriel E. Johnston, and Joseph G. Hamilton

Division of Medical Physics, the Crocker Radiation Laboratory,
and the Departments of Medicine, Anatomy, and Radiology of the
University of California, Berkeley and San Francisco

November, 1956

EVIDENCE FOR FUNCTION OF ABERRANT THYROID TISSUE
IN THE THYMUS OF RATS

C. Willet Asling, Patricia W. Durbin, Marshall W. Parrott,
Muriel E. Johnston, and Joseph G. Hamilton

Division of Medical Physics, the Crocker Radiation Laboratory,
and the Departments of Medicine, Anatomy, and Radiology of the
University of California, Berkeley and San Francisco

November, 1956

Abstract

Aberrant thyroid follicles have been found in the thymi of female Sprague-Dawley rats. The accumulation of I^{131} by such follicles, shown autoradiographically, indicated their functional nature.

EVIDENCE FOR FUNCTION OF ABERRANT THYROID TISSUE IN THE THYMUS OF RATS

C. Willet Asling, Patricia W. Durbin, Marshall W. Parrott,
Muriel E. Johnston, and Joseph G. Hamilton

Division of Medical Physics, the Crocker Radiation Laboratory,
and the Departments of Medicine, Anatomy, and Radiology of the
University of California, Berkeley and San Francisco

November, 1956

In the course of a study on the long-term effects of massive doses of I^{131} in rats, aberrant thyroid tissue in the thymus was found in unexpectedly high incidence in the untreated controls.^{1, 2} In 21 normal female rats of the Sprague-Dawley strain whose ages ranged from 260 to 427 days, one or more thyroid follicles were found in routine sections of thymus of eight rats. Cords or sheets of epithelium resembling that of the thyroid were found in an additional four rats; in these four there was no follicular arrangement or association with colloid. An attempt has been made to demonstrate whether or not the thyroid follicles in the thymus take up radioiodine and incorporate it in colloid.

Methods

Female rats of the Sprague-Dawley strain received 50 μ c per gram of body weight of I^{131} when 55 days old and were autopsied 24 hours later. Histological sections were made of the thymus and autoradiographs were prepared on Eastman Kodak 10- μ NTA stripping film.

Results

Figure 1 illustrates the thymus of one of the rats at low magnification; thyroid follicles may be seen in the medulla. The tissue surrounding these follicles is characteristic of the thymic medulla. At higher magnification (Fig. 2) it is seen that these follicles possess a cuboidal epithelium and are filled with colloid. The colloid variably appears deeply eosinophilic and homogeneous or pale-staining and vacuolated--the latter suggests resorption. The follicles also vary in autoradiographic density (Fig. 3), but all show some radioiodine concentration. Thus, in structure and in iodine concentration these follicles are like those found in the thyroid gland proper.

¹ Asling, Durbin, Johnston, and Hamilton, Long-Term Sequelae of Massive Doses of Iodine-131, UCRL-3398, Apr. 1956.

² Durbin, Asling, Johnston, and Hamilton, Am. J. Roentgenol. Radium Therapy Nuclear Med., 1956, in press.

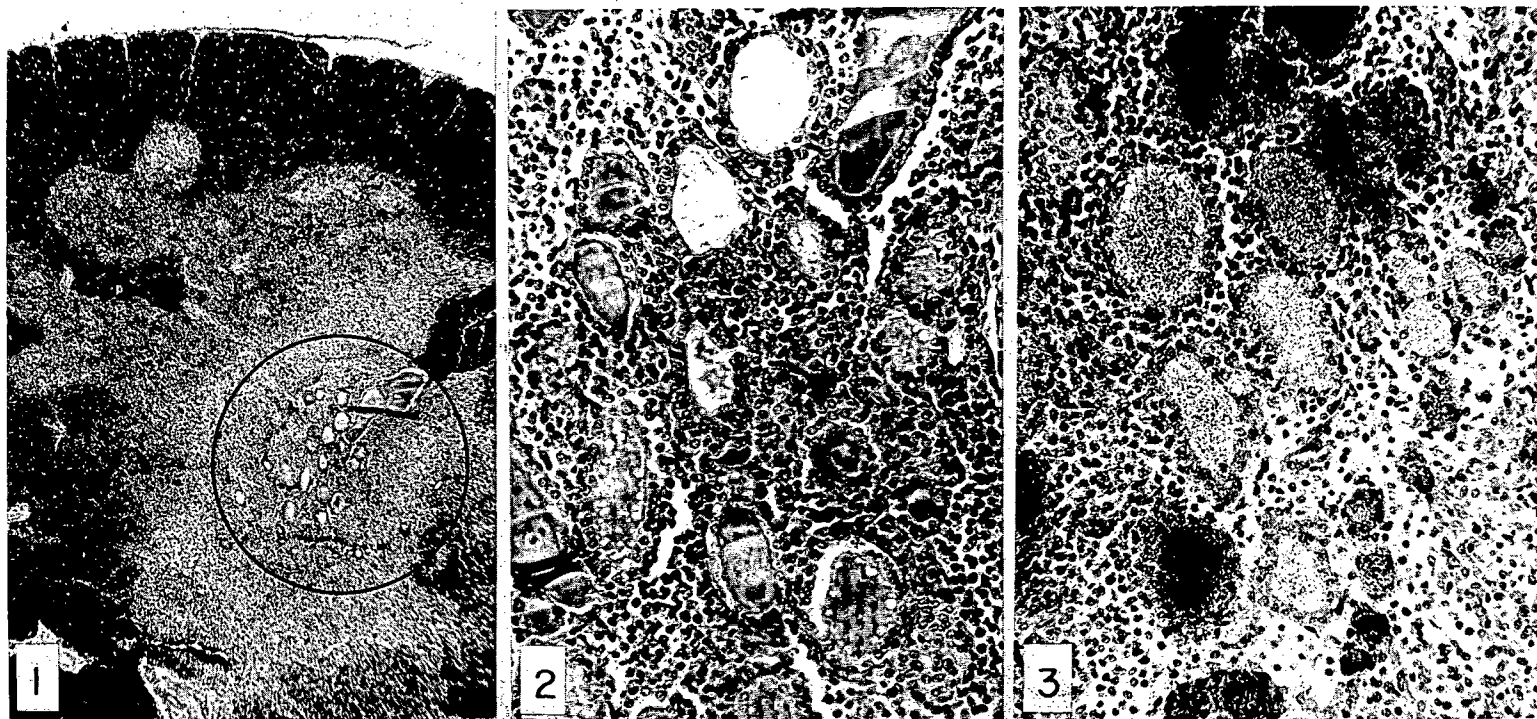


Fig. 1. Rat thymus; thyroid follicles in circled area. H and E x 20.

Fig. 2. Thyroid follicles from field in Fig. 1. H and E x 130.

Fig. 3. Autoradiograph of section of tissue neighboring that shown in Figs. 1 and 2. 10- μ NTA stripping film, 2-hour exposure. H and E x 130.

ZN-1640

Discussion

The possibility that accessory thyroids and aberrant thyroid tissue may occur, especially in the mediastinum, has been long recognized. Adequate embryological explanations may be derived by study of the development of the branchial pouches, which are the anlagen of both thyroid and thymus.³ It has been shown that administration of thiourea to Wisbar strain rats resulted in a high incidence of thyroid adenomata in the thymus.⁴ The objective of this communication is to point out a relatively high incidence of accessory thyroid tissue in an animal commonly employed in endocrinological experiments, and to show that this aberrant tissue may be functional rather than merely rudimentary. The findings have a bearing on experiments in which total thyroid ablation is critical; surgical thyroidectomy may not reach all the functional thyroid tissue, and may have to be followed routinely by radioiodine. It would, in fact, appear possible that following surgical thyroidectomy the resultant increase in pituitary output of thyrotropic hormone could stimulate aberrant thyroid tissue. This possibility has been recognized, for example, in the studies by Entenman *et al.*,⁵ in which surgical thyroidectomy was followed by hypophysectomy.

Critical studies are under way to compare the thymi of surgically thyroidectomized rats with those of rats in which thyroid ablation was accomplished by radioiodine. Already differences in the oxygen consumption in the two groups of rats have been demonstrated by metabolimetry.

This work was performed under the auspices of the U. S. Atomic Energy Commission and the Committee on Research, University of California.

³ J. H. Van Dyke, Arch. Path. 54, 248 (1952).

⁴ J. H. Van Dyke, ibid. 55, 412 (1953).

⁵ Entenman, Chaikoff, and Reichert, Endocrinol. 30, 802 (1942).