



Treatment of a laboratory-based model of shell disease in hatchery raised American lobsters (*Homarus americanus*)

¹ Anderson Cabot Center for Ocean Life, New England Aquarium Central Wharf, Boston, Massachusetts 02110.

² Scripps Institution of Oceanography, University of California San Diego, 9500 Gilman Drive, San Diego, California 92093-0244.

³ School for the Environment University of Massachusetts Boston, 100 Morrissey Blvd., Boston, Massachusetts 02125.

* Corresponding author email: <akim@neaq.org>.

Anita Kim ^{1*}
Charlotte Seid ^{1,2}
Aubrey McElhiney ¹
Michael Tlusty ^{1,3}

ABSTRACT.—Epizootic shell disease in American lobsters, *Homarus americanus* H. Milne-Edwards, 1837, has been of special concern since the mid-1990s due to its impact on fisheries. Numerous studies have led to the present understanding that this disease has a polymicrobial etiology. However, lacking in this research is exploration of the potential ways to ameliorate the disease. This is particularly important for public aquariums that have a strong focus on aesthetics and animal health. We performed two experiments to test short-term treatment methods on a laboratory-based model of shell disease on juvenile American lobsters. A preliminary experiment tested the effects of Hikari® Biobandage, a commercially available product used for treating fish lesions, on early- and late-stage shell disease. Another experiment examined resulting shell disease when lobsters were treated with distilled water, 10% povidone-iodine, d-alpha-tocopherol acetate (Vitamin E oil), formalin (100 ppm), and malachite green (5 ppm). We monitored the development of shell disease in both nonfacilitated and facilitated (in which the shell was damaged to induce disease) areas of the shell to determine effectiveness up to ecdysis. Biobandage was not effective at limiting nonfacilitated shell disease or facilitated wounds. Fresh water exacerbated facilitated wounds in comparison to animals treated with povidone-iodine, formalin, and malachite green. Formalin and malachite green treated lobsters showed the lowest severity of nonfacilitated shell disease. The study also showed that frequent handling alone (lobsters in control group) exhibited a higher amount of nonfacilitated shell disease. Identifying effective treatments in captive lobsters may provide unique solutions for studying shell disease.

11th International Conference and Workshop on Lobster Biology & Management · Portland, Maine 4–9 June, 2017

Guest Editors:
Kari Lavalli, Richard Wahle
Guest Section Editor:
Donald Behringer

Date Submitted: 17 July, 2017.
Date Accepted: 12 March, 2018.
Available Online: 25 May, 2018.

Shell disease in American lobsters, *Homarus americanus* H. Milne-Edwards, 1837, develops when the animal's shell integrity becomes compromised by the onslaught of bacteria in its environment and results in the formation of lesions, or pits in the shell, or in a worse-case scenario, death (Castro et al. 2012, Tlusty et al. 2014). The

trajectory of the disease has best been presented as an individual-health trajectory model (IHT; Tlusty et al. 2014), in which the lobster's health reduces over time and is affected by factors, such as presence of bacterial pathogens, bacterial abundance, portals of entry (passive and active), formation of disease lesions, and time to next molt, among others. Recovery from disease occurs only with molting, but the health status of the animal postmolt is at a lower health state than at the prior molt, leading to a decline in health over time (Tlusty et al. 2014).

Research on shell disease has focused heavily on the bacterial pathogenicity portion of the IHT, particularly on identifying a causative bacterium. Hess (1937) initially identified bacteria, and more specifically chitinivorous species, were linked to shell disease. Malloy (1978) also investigated chitin-degrading bacteria and found that a *Vibrio (Benecke)* type bacterium could create lesions in lobsters with induced damage (abraded shell). This was the first work to suggest a singular pathogenic species.

Nearly 30 yrs later, concomitant with an increase in sophistication of bacterial culture and identification, Chistoserdov et al. (2005) began to look beyond a singular species with an exploration of the bacterial community on shell disease lesions, yet still focused on a singular species, *Aquamarina homaria*, as the main causative agent. Controlled laboratory experiments continued to support *A. homaria* as the putative agent (Quinn et al. 2012). However, at this time, there was a vast improvement in sequencing depth used to identify microbes (Caporaso et al. 2012), and the broader realization of the importance of the microbiome (Gilbert et al. 2014). Lobster researchers began to acknowledge the potential for shell disease being a polymicrobial etiology (Chistoserdov et al. 2012), and a dysbiosis from a healthy state (Meres et al. 2012). Yet even with these analytical improvements, the polymicrobial etiology for shell disease remains incomplete given current findings of species-specific shell disease communities in the same experimental system (Whitten et al. 2014) and evidence of an ephemeral transition community preceding any physical appearance of shell disease (Feinman et al. 2017). Much of the work cited above has used a laboratory model of shell disease in juvenile lobsters. This has been beneficial because of the shorter molt cycles facilitating observations of shell disease, along with the ability to hold more animals and conduct statistically-rigorous studies in a limited volume holding space. The detailed observations that can be made in the laboratory can provide the basis for improving our understanding of bacterial-induced cuticular abnormalities, with the goal of adapting this understanding to the etiology and pathology of shell disease in lobsters in the wild.

The question of the causative bacteria to shell disease will continue to be an interesting topic of research, but the polymicrobial nature means it will be difficult to identify a singular cause with the hope of a singular cure. What has been missing in the shell disease research is a focus on the recovery portion of the IHT, and the means to ameliorate the disease and how to help symptomatic animals recover. Public aquariums pose a unique approach to the shell disease puzzle given that they hold individual animals for long periods of time and have the capability to treat ill animals. These institutions hold a number of crustacean species that exhibit various forms of shell disease, including other lobster species (Diggles 1999, Porter et al. 2001), crabs (Bullis et al. 1988, Noga et al. 1994, Vogan et al. 2002), shrimp (Goarant et al. 2000), and horseshoe crabs (Braverman et al. 2012). Regardless of differing etiologies from species to species or from the disease forms in the wild, shell disease creates external lesions on a crustacean's shell, and can affect molting frequency

(Laufer et al. 2005), molting success (Stevens 2009), and overall health (Castro et al. 2012, Tlustý et al. 2014). Within aquariums, the formation of lesions, or pits in the shell, create an unsightly appearance that is not ideal for exhibiting animals to paying visitors. The common form of dealing with this issue is to take the animal out of the exhibit and into a holding tank away from visitors' view. The animal is kept off-exhibit until it molts, which it may or may not succeed in performing, and then placed back in the exhibit, where the shell disease cycle is likely to begin again. With American lobsters, this process can take months to years depending on the age, size, and sex of the animal, and is not ideal for aquariums where holding space is limited and exhibit success is dependent on the animal collection. There is no current effective treatment, beyond molting, for shell disease in *H. americanus*. While tank cleanliness and filtration systems, such as ultraviolet light, may help limit disease severity, it is likely adult lobsters in captivity will develop a form of shell disease over time due to the relatively long period between molts.

In the present study, our objective was to test different treatments for shell disease on *H. americanus* in an attempt to identify an effective treatment course that could be used in public aquariums. We used juvenile *H. americanus* that are susceptible to a laboratory model of shell disease (LMSD). LMSD is common in captive lobsters, is likely due to chronic environmental stress (Feinman et al. 2017), and differs from epizootic shell disease, the prevalent form of shell disease seen in wild-caught *H. americanus*. We chose to study juvenile lobsters instead of adults as they provide an excellent model to study shell disease from early to late stages within a shortened time scale. We conducted two experiments: Study 1 was a pilot study to determine the effectiveness of a commercially available product on early-stage and advanced-stage shell disease, and Study 2 determined the effectiveness of various antiseptic techniques at limiting shell disease.

METHODS

STUDY ANIMALS.—For both experiments, hatchery-raised juvenile *H. americanus* were used. The New England Aquarium (Boston, Massachusetts) has a Lobster Research and Rearing Facility (LRRF), the only year-round American lobster hatchery. Ovigerous females were collected from Massachusetts and New Hampshire with appropriate permits and housed in designed hatch tanks (99 × 57 × 25 cm) within a 1705-L semi-closed recirculation system with water from Boston Harbor. Upon hatching, larvae were collected and moved to 40-L Hughes kreisels—upweller cylindrical tanks based on the design by Hughes et al. (1974)—and kept at a density of up to 50 larvae L⁻¹. At metamorphosis, stage IV postlarvae were moved to individual containers (4 cm height × 3 cm diameter) and transferred to shallow tanks (185 × 44 × 5 cm). Kreisels and juvenile tanks were maintained in the same recirculating system as the female hatch tank. As lobsters grew, they were moved into larger, appropriately-sized containers as needed.

These studies required lobsters robust enough to be handled regularly. Older juvenile lobsters were deemed appropriate for these studies as they are less likely to contend with complications, such as mortality or limb loss, compared to younger counterparts. Thus lobsters at least 3 yrs old were used in these experiments and maintained individually in perforated containers (13.5 × 13.5 × 11.5 cm). While the two experiments were conducted consecutively, the lobsters used for both

experiments were all siblings. Due to the requirement of 3+ yr old lobsters, sample sizes were constrained and based on animals available at the time in the facility.

TREATMENTS.—In Study 1, we tested the effectiveness of Hikari® Biobandage (Hayward, California), a commercially-available product, on early-stage and more advanced-stage shell disease. Biobandage is a liquid gel-based product containing neomycin sulfate, an antibiotic, and methylene blue, an antifungal and anti-parasitic agent, used for treating lesions, ulcers, and fin rot in fish. Biobandage was applied as directed by the manufacturer. An individual lobster was removed from its container, blotted with a towel to remove moisture, and Biobandage was applied dropwise onto the shell. The Biobandage was allowed 1 min to penetrate the shell before the lobster was immersed in a saltwater bath and then placed back into its container and its tank in the LRRF. Lobsters were assigned one of three treatment groups: early-treatment, late-treatment, and a control group ($n = 6$ each). Lobsters in the early-treatment group were treated with Biobandage at the start of the experiment; lobsters in the late-treatment group were treated with Biobandage only once the presence of shell disease lesions were observed; and those in the control group were treated similarly to the early-treatment group, but only received sterile seawater as their treatment. Once treatment began, it was applied daily (as directed), until the lobster molted (molt 1).

In Study 2, we intended to test treatments that would be user-friendly for aquarist staff by being relatively quick and easy to perform, inexpensive, and requiring only a short-term removal of the animal from its exhibit. Since shell disease is an external disease with no internal infection associated with the disease lesions (Chistoserdov et al. 2005, Smolowitz et al. 2005), an external application was determined as the most likely to be effective. Treatment options considered were: topical antiseptic application, adhesive bandaging, topical ointment application, short-term or long-term bath treatments, medicated feeds, or injections. Of these options, long-term bath treatments, medicated feeds, and injections do not meet the requirements listed above. Long-term (week-long or more) antibiotic bath treatments are likely to be effective in mitigating shell disease, but risk creating antibiotic resistance (J Cavin, New England Aquarium, pers comm; Fisher et al. 1978, Gardner and Northam 1997, Holmström et al. 2003, Defoirdt et al. 2007, Shields 2011). Short-term antibiotic treatments were not considered due to this same risk (J Cavin, New England Aquarium, pers comm).

Of the remaining options, adhesive bandaging and ointment applications were expected to have the least amount of success. Lobsters have a waxy epicuticle making ointments and adhesives difficult. Prior attempts at our facility to apply over-the-counter triple antibiotic ointment or adhesive bandages were unsuccessful and generally led to both treatments losing adhesiveness to the shell once the lobster was immersed back in its tank. Treatments were thus focused on topical antiseptic applications and short-term bath treatments.

In Study 2, six treatment types ($n = 8$ lobsters per treatment) were tested: (1) 10% povidone-iodine (PVP-I, Betadine® solution, Purdue Products L.P., Stamford, Connecticut), a topical antiseptic commonly used to eliminate bacteria from skin; (2) vitamin E oil (54,600 IU d-alpha tocopherol, Now Foods, Bloomington, Illinois), an antioxidant, shown to have some beneficial effects when provided in a lobster's diet (A Kim, unpubl data); (3) fresh water (distilled water); (4) formalin (10% buffered formalin phosphate, certified, Fisher Scientific, Pittsburgh, Pennsylvania), a common

aquatic veterinary treatment used in short duration and low concentration to remove ectoparasites and protozoans (Hadfield and Clayton 2011, Shamsuzzaman and Biswas 2012); (5) malachite green (0.38% malachite green zinc-free solution, Kordon LLC, Hayward, California), a documented treatment for shell disease in American lobster larvae (Fisher et al. 1978); and (6) a control group, where lobsters were handled only and no treatment was applied.

Formalin and malachite green treatments are generally conducted as short-term baths. Preliminary tests were conducted to determine appropriate dosage and found that 1-hr baths of 100 ppm of formalin and 5 ppm of malachite green were effective, but not lethal to juvenile lobsters. To be conservative, these treatments were conducted twice a week to avoid potential overexposure to each chemical (J Cavin and C Innis, New England Aquarium, pers comm). To perform bath treatments, the appropriate concentration bath was prepared and lobsters were removed from their containers and placed in the bath. Baths contained an airstone to provide aeration (and to assist in mixing the chemical) and were covered to minimize lobster stress, evaporation loss, and inactivation of malachite green, which is light sensitive. After 1 hr, the lobsters were removed and placed in a saltwater bath to rinse off any excess chemicals before being placed back into their containers and tanks.

Povidone-iodine, vitamin E, and freshwater treatments can be applied only topically and cannot be conducted as submersions. These were applied three times per week. Topical applications were performed as described for Study 1 except the treatments were applied gently over all shell surfaces with a Kimwipe. Lobsters in the control treatments were handled in the same manner except no Kimwipe application was performed. The handling time of control treatment lobsters was similar to the handling time of the other topical treatments.

DATA COLLECTION.—In both studies, the effectiveness of the treatments was determined by analyzing differences in (1) shell disease severity and (2) increase in the size of shell disease lesions (visible eroded areas of shell). The first parameter, shell disease severity, was determined by visual observations of nonfacilitated (naturally-occurring) shell disease. The second parameter, comparing size increase in lesions among lobsters, was hypothesized to be more difficult to examine as it can be confounded by a number of factors. Lobsters may or may not be susceptible to shell disease (Tlustý et al. 2007) and thus may or may not show disease symptoms in a given molt cycle. Shell disease forms spontaneously with no predictable pattern and shell thickness varies in different body areas; e.g. shells at the chelae are thicker than at the carapace (Davies et al. 2014), which may affect how the disease progresses, confounding comparisons between individuals with different affected body parts. To mitigate these variables, we facilitated shell disease by damaging the lobster's shell in the same place for all individuals in each study. In doing so, we exposed an area of the shell, allowing bacteria to settle and proliferate without the need to penetrate the shell first. Disease progression would be seen as a lateral expansion of the damaged area due to erosion of the shell from these bacteria. An effective treatment would show: (1) reduced expansion of the facilitated damaged area and (2) less nonfacilitated shell disease.

In Study 1, lobsters were initiated into the experiment on the same calendar date. Based on the molting data maintained at the LRRE, we chose animals that were estimated to be at 10%–50% of their molt cycle (time from one molt to the next). At the

start of the experiment, lobsters were measured for carapace length using Mitutoyo Absolute Digimatic (model # CD-6"CSX) digital calipers. Lobsters were analyzed for nonfacilitated shell disease (described below) and then shell disease was facilitated by abrading the surface of the lobster's dorsal carapace (Quinn et al. 2012, Davies et al. 2014, Whitten et al. 2014). Lobsters were removed from their tanks and rinsed with sterile seawater. Fine, 400-grit sandpaper was sterilized under ultraviolet light and used to abrade the dorsal carapace for 25 s. The lobsters were rinsed again with sterile seawater and then placed back into their containers and into their tanks. Lobsters were allowed 1 wk undisturbed in their tanks before treatments began for the control group and early-treatment group. Treatments focused on the abraded areas only. The late-treatment group was to begin treatment only once advanced stage lesions were observed in the abraded area. However, only one lobster in this treatment group developed lesions in the abraded area and thus, most of this treatment group received no Biobandage treatment. The experiment ceased once the lobsters molted (molt 1; Fig. 1).

The abraded areas for all groups were monitored weekly following abrasion (Fig. 1). Abraded areas were visually inspected and photographed using a Canon G12 PowerShot digital camera once a week. Lobsters were gently blotted then placed on a piece of waterproof paper. Full body images were taken along with close ups of the abraded area with a ruler placed alongside the lobster for scale.

Nonfacilitated (naturally-occurring) shell disease severity was determined by visual assessments at time of abrasion, and again at 2 mo postabrasion and every 2 wks until molt 1 (Fig. 1). Counting individual shell disease lesions has proven to be misleading, since lesions can increase in area over time, causing two individual lesions to merge together into a single larger lesion. Instead, the number of body areas affected with shell disease was analyzed. Lobsters were removed from their containers and gently blotted to remove excess moisture. Visual inspection was conducted on 34 dorsal and lateral body parts, including specific areas of chelae (claws), carapace, abdomen, and tail. The walking legs, antennae, eyes, and the ventral side of the animal were not included in this analysis to minimize lobster stress and handling. Each body area was inspected for presence or absence of shell disease lesions in which the shell was discolored and erosion of the shell was visible by eye (indicates bacteria are actively eroding the shell). Any nondisease related damage to the shell was noted, but the facilitated abraded area on the carapace was not included in this part of the analysis. As described above, digital images of shell disease on the lobsters were taken for the abraded area, full body, and close ups of each of specific body areas (each chela, carapace, abdomen, and tail).

In Study 2, lobsters entered the study at 2 wks postmolt (molt 0) to allow time for shell hardening before being initiated into the experiment. Since lobsters molt at varying times depending on age, diet, temperature, and a number of other factors, lobsters were initiated into the experiment asynchronously. At the time lobsters were initiated into the experiment, three measurements were collected. Carapace length was measured, and weight was measured by gently blotting the lobster to remove excess water and weighing the lobster using an Ohaus Galaxy 160 digital balance. The lobsters were analyzed for nonfacilitated shell disease and digital photos were taken as described for Study 1. The abrasions in Study 1 did not consistently develop lesions as expected, so for Study 2, to facilitate shell disease, one claw received a sterile puncture to induce disease instead (Davies et al. 2014, Whitten et al. 2014).

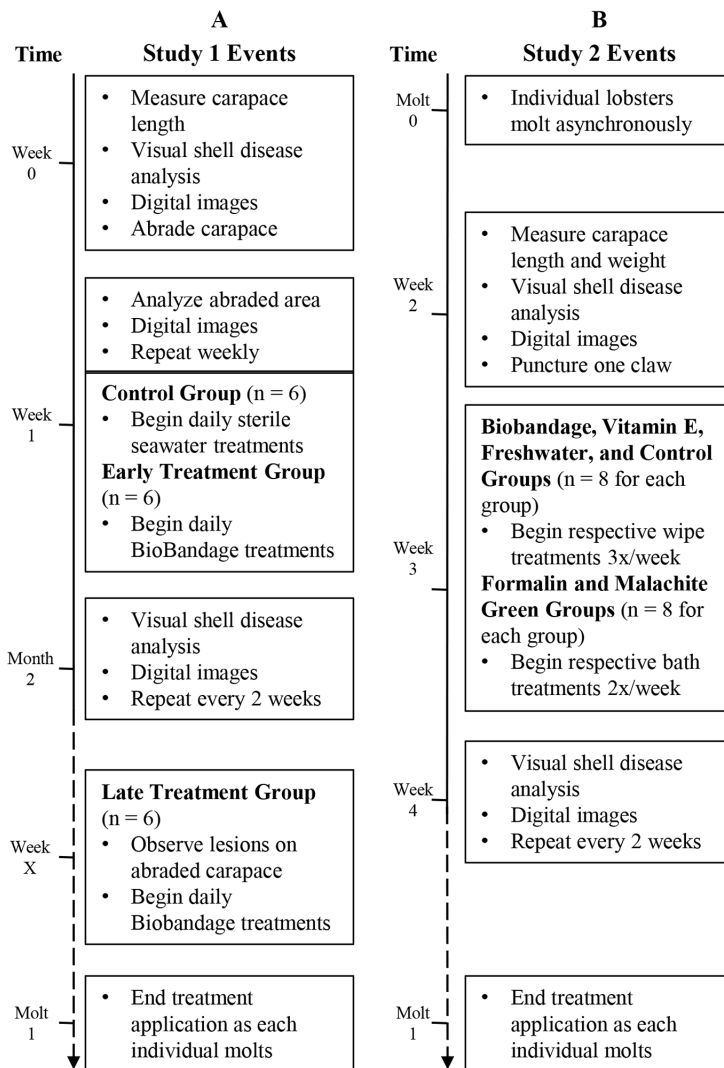


Figure 1. Timeline of procedures for (A) Study 1 and (B) Study 2. In Study 1, events occurred at the same chronological date for all lobsters, regardless of individual molt cycles. Week number indicates an unspecified date in which the listed event occurred. In Study 2, events occurred asynchronously based on the time frame when each individual molted. Solid line indicates a known time frame and is not to scale. Dashed line indicates an undefined time frame.

Similar to Study 1, the lobsters were given 1 wk to recover and were then re-analyzed for shell disease; digital photos were taken of both nonfacilitated shell disease and the claw puncture wound. Shell disease was analyzed and digital images were taken every 2 wks for lobsters in all treatment groups. Designated treatment regimen began at 1 wk postpuncture and continued until the lobster molted (Fig. 1). When the lobsters molted (molt 1), treatment ceased; and 2 wks postmolt, size measurements were taken, and lobsters were analyzed for shell disease and digital photos were taken. Additionally, the location of the puncture wound (now healed) was inspected. The molted lobsters were then removed from the study.

Lobsters in both experiments were checked daily for molts and mortalities. Lobsters were fed daily Mazuri® Aquatic Gel Diet for Crustaceans. For Study 1, at the start of the experiment, lobsters were all of similar size as determined by one-way analysis of variance (ANOVA) test ($F = 0.05$, $P > 0.05$) with an average carapace length (CL) of 34.37 (SE 0.51) mm. The lobsters for the three treatments were held in the same tank within the LRRF, and the experiment was conducted for 224 d. Mean water quality parameters during the experiment were: temperature = 12.76 (SE 0.015) °C, salinity = 31.27 (SE 0.13), and pH = 7.87 (SE 0.008). In Study 2, at the start of the experiment, lobsters averaged 38.94 (SE 0.86) mm CL and 48.37 (SE 2.08) g in weight. The lobsters were all of similar size; there was no difference in carapace length or weight of the lobsters in the six treatments as analyzed by two one-way ANOVA tests ($F < 0.5$, $P > 0.05$ for each test). The lobsters in Study 2 were held in two tanks within the LRRF in a block design and every 2 wks the lobsters were shifted to avoid tank effects. The experiment lasted for 450 d and mean water quality parameters during the experiment were: temperature = 12.9 (SE 0.1) °C, salinity = 31.84 (SE 0.09), and pH = 7.87 (SE 0.006). Total ammonia nitrates remained below 0.10 ppb throughout the course of both experiments. For all described manipulations, analyses, and measurements, lobsters were air exposed for only 1–2 min at a time and allowed to be resubmerged for a similar amount of time before continuing analyses. Lobsters showed no ill effects from air exposure and showed rapid recovery (righted themselves quickly, tail flipping, and active movement) during resubmersions.

DATA ANALYSIS.—Temperature has a strong influence on a lobster's biology, including molt cycle. Since shell disease is a progressive disease, molt cycle length has a direct effect on shell disease progress and severity (Tlusty and Metzler 2012). To correct for this discrepancy, time was measured as degree days for both experiments. Degree days were calculated as the sum of each daily temperature minus 5 °C for the total days in the time period. The value of 5 °C was chosen because lobsters exposed to water temperatures ≤ 5 °C may be prevented from molting (Aiken and Waddy 1980, Bergeron 2011). Unless otherwise indicated, for Study 1, degree days were calculated from the date carapaces were abraded to the last disease inspection date before molt 1. For Study 2, degree days were calculated from the prior molt (molt 0) to the last inspection date before molt 1. Degree days in each study were analyzed by one-way ANOVA tests.

Digital images were used to analyze the facilitated abraded carapaces or punctured claw wounds. ImageJ software v1.49 (Rasband WS, US National Institutes of Health, Bethesda, Maryland) was used first to scale the image using the ruler and then measure the area of the facilitated wound. The percent increase in size of the wound area was then calculated by subtracting the initial area measurement (measurement 1 wk after the facilitated wound was made) from the final area measurement (the last measurement taken before molt 1) and the subsequent value was divided by the initial measurement and multiplied by 100. A rate of area (lateral expansion) increase was then calculated by taking the percent increase in wound area size and dividing by the degree days for the given time frame.

Nonfacilitated shell disease lesions develop progressively, leading to more severe symptoms observed just before a lobster molts. We focused our analysis on this time frame: the last inspection date prior to molt 1. The severity of nonfacilitated shell disease lesions was calculated as the percent body areas affected by nonfacilitated

shell disease lesions, i.e., the total number of body areas affected with lesions divided by the total number of possible body areas: $(34 - \text{number of missing body parts, such as a chela or uropods}) \times 100$. A rate of development of nonfacilitated disease lesions was calculated by taking the percent body areas affected with nonfacilitated lesions and dividing by degree days.

For Study 2, growth in carapace length and weight was calculated as percent increase as described above, where the initial measurement was taken at the start of the experiment and the final measurement was taken after molt 1. A rate of growth was then calculated by dividing by degree days to correct for the individual's time in the experiment. Although growth and shell disease do not progress linearly, by calculating a rate based on degree days, we eliminate the variation in molt cycles and temperature regimens that each individual lobster was subjected to and which may affect shell disease severity.

In Study 1, results for rate of nonfacilitated shell disease lesion development and rate of area increase in abraded carapaces were examined for normality, and those with a skewness and kurtosis less than -2 or greater than $+2$ were z -score transformed (rate of area increase in abraded shells were transformed; Gravetter and Wallnau 2014). Data were then analyzed using a multivariate analysis of variance (MANOVA) test with a model fitted for each response and then jointly tested together in JMP with the Wilks' Lambda test on the whole model (JMP®, Version 13.2.1, SAS Institute Inc., Cary, North Carolina). In Study 2, results for rate of area increase of puncture wounds, rate of development of nonfacilitated disease lesions, and growth rates for carapace length and weight were tested for normality, transformed if not normal (rates of development of nonfacilitated lesions were transformed), and analyzed with a MANOVA test as described above. Significant variable effects were further analyzed with one-way ANOVA tests using a corrected P -value [Bonferroni P -value corrected for number of comparisons; Study 1: $P < 0.025$ (0.05/2 comparisons), Study 2: $P < 0.0125$ (0.05/4 comparisons)].

RESULTS

There were no mortalities nor was there any claw autotomy during the course of either experiment.

STUDY 1.—There were no significant differences in the response variables measured as rate of area increase (lateral expansion) of abraded carapaces or rate of nonfacilitated shell disease lesion development in the three treatment groups (MANOVA: Wilks' lambda = 0.52, $F_{6,26} = 1.6$, $P > 0.1$). Molt cycles (molt 0 to molt 1) for all the lobsters averaged 1212.13 degree days [SE 46.57, calculated from 155.44 (SE 5.81) d] and were not significantly different between treatments (ANOVA: $F_{2,15} = 0.17$, $P > 0.5$). While not significant, the general trend was that the lobsters in the early-stage treatment group (treatment began 1 wk postabrasion) showed the fastest rate of development in nonfacilitated disease lesions and had the fastest rate of area increase of abraded shells. Late-stage treated lobsters showed the lowest rate of nonfacilitated lesion development and had the lowest rate of area change in abraded carapaces.

STUDY 2.—The time for lobsters to undergo one molt cycle averaged 1164.99 degree days [SE 49.79, calculated from 150.65 (SE 6.37) d] and did not differ between the treatment groups (ANOVA: $F_{5,42} = 1.5$, $P = 0.2$). Lobsters showed significant responses

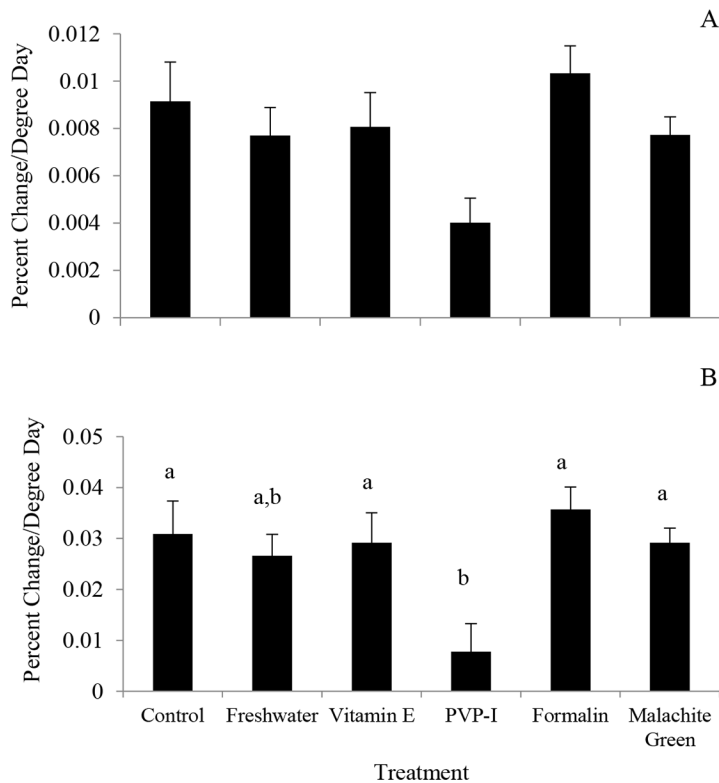


Figure 2. Growth rates as calculated as percent increase in (A) carapace length or (B) weight per degree day for lobsters in each of six treatments. Growth rates in carapace length were not found to be significant. Lobsters treated with vitamin E oil (d-alpha-tocopherol), malachite green, formalin, and those in the control group had significantly higher rates of growth in weight than those treated with PVP-I. Values are mean with SE. There are no differences in panel A, different letters in panel B indicate statistical differences.

to treatment (MANOVA: Wilks' lambda = 0.28, $F_{20,130} = 3.1$, $P < 0.001$). The carapace length (percent change per degree day) was not significant after Bonferroni correction (ANOVA: $F_{5,42} = 2.9$, $P = 0.024$), while the remaining three variables exhibited statistically significant treatment effects (presented below). Growth rate (weight, ANOVA: $F_{5,42} = 4.7$, $P < 0.002$) was the lowest for the lobsters treated with PVP-I and fresh water, with the carapace growth data exhibiting a similar trend (Fig. 2).

Claw puncture wounds generally increased in area and changed in color and texture in all lobsters except one in the PVP-I treatment group, which showed no change. These area, color, and texture changes were visibly noticeable (Fig. 3). Lobsters treated with fresh water had the greatest rate of area increase in the chela puncture wounds, while lobsters treated with malachite green, PVP-I, and formalin had the lowest rate in wound area change (ANOVA: $F_{5,42} = 5.2$, $P < 0.001$; Fig. 4). For all lobsters, the area of the puncture wound healed (shell regenerated, no opening in shell) after molting, but location of the wound was evident on the healed claw due to a visible difference in shell color, a slightly raised shell in that location, or both.

The rate of development of nonfacilitated shell disease lesions (percent body areas exhibiting disease lesions/degree days) was fastest in lobsters in the control group

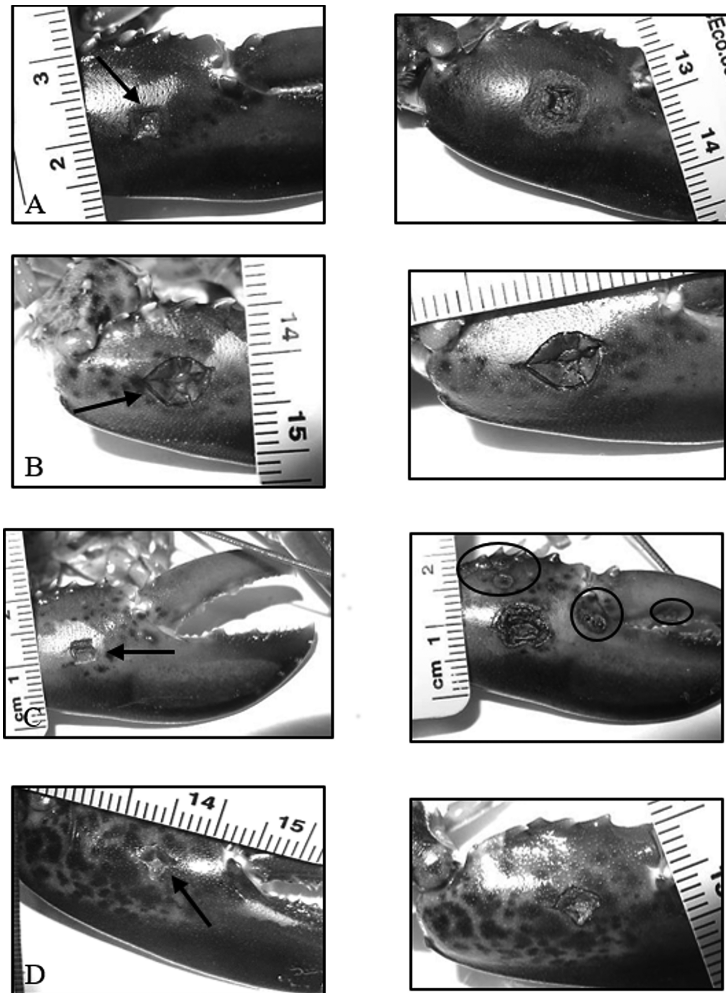


Figure 3. Examples of claw puncture wound area increase in four individual lobsters. Left hand column are images of the wound (arrows) taken 1 wk postpuncture (initial). Right hand column are images of the wound taken just before molt 1 (final) of the corresponding lobster and show the melanizing immune response. Images are of lobsters treated with: (A) PVP-I showing significant increase in puncture wound area; (B) malachite green showing little change in puncture wound area; (C) fresh water showing both a significant change in wound area and development of non-facilitated shell disease lesions (circled); and (D) vitamin E oil (d-alpha-tocopherol) showing some change in wound area along with a change in the texture of the wound that was often seen, in which the wound appears to form a crust in the more exposed areas.

(ANOVA: $F_{5,42} = 3.9$, $P < 0.005$; Fig. 5). Lobsters treated with malachite green or formalin had the slowest rate of lesion development. These differences were most likely due to the number of lobsters in each treatment group that developed nonfacilitated lesions over the course of the experiment. Only three lobsters in the malachite green treatment and five lobsters in the formalin treatment developed nonfacilitated lesions, while all eight of the lobsters in the control treatment developed lesions (Fig. 5).

The lobsters in all treatments exhibited variation in the rates of area increase of facilitated puncture wounds compared to rate of development of nonfacilitated shell disease. The poor correlation ($r^2 = 0.08$) indicates that lobsters may have had (1)

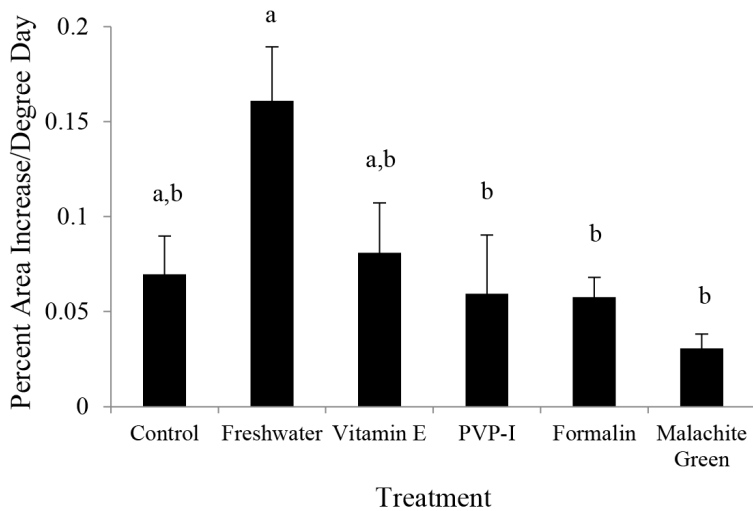


Figure 4. Rate of area increase of facilitated puncture wound on one chela for lobsters in each treatment. Rate was determined as the percent change in area of the puncture wound during the time in degree days from 1 wk postpuncture of the chela to the last inspection date prior to molt 1. Lobsters treated with fresh water had the highest rates of wound area increase, whereas lobsters treated with PVP-I, formalin, and malachite green showed the lowest rates. Values are mean with SE. Different letters above bars indicate statistical differences.

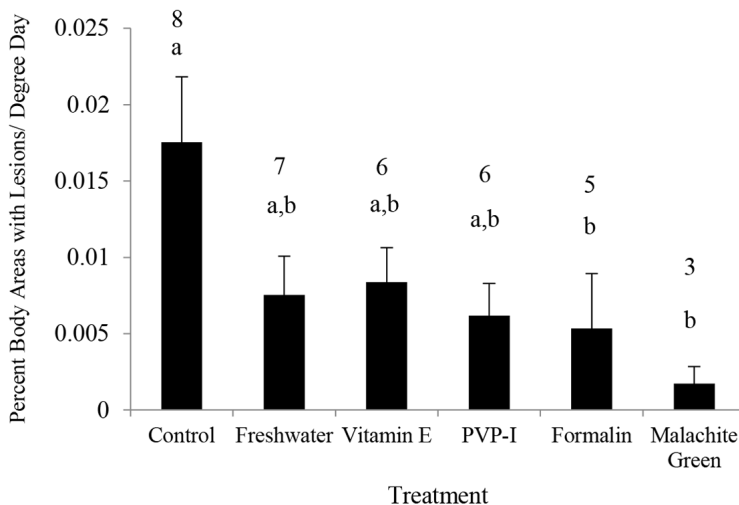


Figure 5. Non-facilitated shell disease severity shown as the percentage of body areas that developed lesions per degree day. Rate was determined by assessing the disease severity at the last inspection date prior to molt 1 and dividing by the degree days from molt 0 to that same time point. Values are mean with SE. Different letters above bars indicate statistical differences. Statistical tests were performed on transformed data, but untransformed data are presented for clarity. Numbers above bars indicate the number of lobsters in each treatment that developed non-facilitated lesions. Lobsters in the control group had the highest non-facilitated shell disease severity and all lobsters in this treatment developed lesions. Lobsters treated with formalin or malachite green had the lowest non-facilitated shell disease severity and had the lowest number of lobsters develop lesions.

minimal changes in the puncture wound and minimal nonfacilitated shell disease lesions occurring on their body, (2) minimal changes in the puncture wound with an increase in nonfacilitated shell disease on their body, (3) significant changes in the puncture wound area with minimal nonfacilitated shell disease, or (4) significant changes in the puncture wound area with significant nonfacilitated shell disease.

DISCUSSION

The focus of understanding lobster shell disease has been on the etiology (Chistoserdov et al. 2012, Meres et al. 2012, Whitten et al. 2014, Feinman et al. 2017) and impacts on overall animal health and survival (Laufer et al. 2005, Stevens 2009, Castro et al. 2012). Of less focus has been the development and demonstration of curative agents for lobsters expressing shell disease. Here, we applied a variety of therapeutants common within the public aquarium industry to examine their effectiveness at ameliorating a laboratory-based model of shell disease. Of the six treatments tested, only malachite green and formalin were observed to be effective at both limiting the formation of lesions and limiting the lateral expansion of existing lesions. In addition, we found a positive association between handling frequency and susceptibility to shell disease.

The malachite green and formalin treatments were observed to have fewer animals exhibiting nonfacilitated shell disease lesions with only three and five lobsters (respectively) exhibiting lesions compared to all eight lobsters in the control group. Malachite green and formalin were the most effective at limiting the rate of non-facilitated lesion development, while lobsters in the control treatment exhibited a significantly higher rate.

The antimicrobial properties of both malachite green and formalin were likely to be influential in the results seen in this study. Both malachite green and formalin can act as broad-spectrum antibacterial treatments for aquatic animals (Alderman 1985, Strohmeyer 2016). Formalin is a commonly used treatment in aquatic and marine veterinary medicine. It is used for treating against protozoans and trematodes, including freshwater ich (*Ichthyophthirius multifiliis* Fouquet, 1876), marine ich (*Cryptocaryon* species), and *Trichodina* species, among others, and kills parasites on gills, fins, and skin (Francis-Floyd 1996, Strohmeyer 2016). It can also be used against external fungal infections in fish and fish eggs and in Gram-positive bacterial infections (Wagner et al. 2008, Strohmeyer 2016). In crustaceans, formalin is used as a treatment against ciliates, protozoans, fouling diseases, and filamentous bacteria (McVey 1993). It can be used to remove fouling organisms from eggs on penaeid shrimp and giant river prawn *Macrobrachium* spp. (Wickins and Lee 2002), treat external parasites in penaeid shrimp (Noga et al 2012), and treat fungus on newly hatched larvae in mud and swimming crabs (Hamasaki and Hatai 1993). Formalin was successfully used to treat the ciliate parasite *Anophryoides haemophila* in American lobsters using 50 mg L⁻¹ in 1-hr baths (Speare et al. 1996). Formalin use to prevent bacterial infections is mentioned (McVey 1993, Strohmeyer 2016), but not promoted as a preferred method in treating external bacterial infections in fish (Francis Floyd 1996). However, the present study shows that it is effective in the external shell disease affliction in *H. americanus*. Since shell disease is a polymicrobial disease, the widespread effectiveness of formalin on bacteria, protozoans, and fungi may explain

its ability to both reduce symptom development (visual appearance) of new shell disease and limit the growth of established lesions.

Malachite green is an arylmethane dye that is a strong antimicrobial agent and broad-spectrum antifungal agent (Alderman 1985, Srivastava et al. 2004). It has a greater effect against Gram-positive bacteria than Gram-negative bacteria (Alderman 1985). It has been used to treat fungal infections in crustaceans, freshwater ich (*I. multifiliis*, a protozoan disease) in fish, external parasites in marine and freshwater fish (Alderman 1985, Strohmeyer 2016), and to prevent fungal infections in fish eggs (Sudova et al. 2007). In lobsters, Fisher et al. (1978) reported using malachite green to combat shell disease in American lobster larvae. Interestingly, commercially produced malachite green aquatic treatments only promote this dye as an anti-protozoan and not an anti-bacterial agent, and recommend using extreme caution on using the dye with marine invertebrates due to its unknown effects on these animals (Malachite [date unknown]). It is often sold as a combination solution with formalin; a combination known to be very effective against protozoans (Meyer and Jorgenson 1983, Strohmeyer 2016). Malachite green is prohibited for treatment of food fish by the Federal Drug Administration due to its potential carcinogenic and teratogenic properties (Srivastava et al. 2004, Anderson et al. 2005, Athanassopoulou et al. 2009, Hashimoto et al. 2011) and is generally used only for ornamental fish and by hobbyists at low treatment dosages (Sudova et al. 2007, Strohmeyer 2016).

While malachite green and formalin showed effectiveness in the present study against lobster shell disease, caution should be used before applying these treatments. Juvenile lobsters can be used as a model for shell disease, but it would still be prudent to further study whether these treatments are as effective in adult lobsters that exhibit LMSD or other forms of shell disease. Neither treatment, but particularly malachite green, has been tested in other crustacean species that may develop other forms of shell disease. The treatment may be toxic to other species (Culp 2004) or it may not be effective. The treatments utilized in our experiment are relatively time intensive, two 1-hr baths per week until molting. Given that adult lobsters only molt once per year or even less frequently, maintaining a perpetual treatment schedule may be difficult to maintain. For aquariums or other institutions that may have several adult or juvenile lobsters needing treatment, the time, space, and tank requirements to maintain this type of treatment may not be practical. It is possible that these treatments may still be effective if performed less frequently, particularly with adult lobsters, but this would require further investigation to verify. Regardless, there may be unknown effects of using malachite green long-term in crustaceans. Studies on fish have shown negative physiological effects from treating fish in malachite green baths for extended periods (Culp 2004). Both malachite green and formalin are known carcinogens; malachite green is a known teratogen and formalin is a suspected teratogen (Duong et al. 2011). Both treatments must be used with caution to the user. Since malachite green and formalin can be toxic to fish at certain levels, care must be made using these treatments to prevent exposure to other animals within the tank system. In this context, we do not suggest that our work in this recirculation aquarium study could be translated to a wild harvest setting. Lastly, while malachite green and formalin showed promise as a treatment for shell disease, there are other treatments that are less hazardous alternatives that have yet to be tested, such as chloramine-T (Spangenberg 2013).

Lobsters treated with PVP-I showed the lowest rate of growth in weight and carapace length compared to lobsters in the other treatments. There is no known documentation of povidone or excess iodine diminishing growth in lobsters, but iodine has been noted to be toxic to lobsters, and gills and mouthparts should be avoided for disinfection treatments (Browne et al. 2009). It is possible that minimal amounts of PVP-I entered the lobster's system and negatively affected their growth. No known studies have been performed to determine whether povidone or iodine have a detrimental effect on lobsters or interfere with any biochemical pathways that affect growth, as lobsters are not likely to encounter excess povidone or iodine in their natural environment.

Puncture wounds were adversely affected by treatments that did not utilize a known antiseptic or antimicrobial agent. The lobsters treated with fresh water, vitamin E, and those in the control treatment showed a faster area expansion in claw puncture wounds compared to those treated with PVP-I, malachite green, or formalin. In particular, the lobsters treated with fresh water had a significantly greater rate increase in wound size in comparison to those treated with PVP-I, malachite green, or formalin. Puncture wound size increase was a result of increased erosion at the perimeter of the wound and expanding across the lobster's claw shell. Shell disease is believed to be a polymicrobial disease with a changing microbial community (Bell et al. 2012, Meres et al. 2012). Such a continually evolving community means that initiating bacteria may be lost as lesions form and other bacteria become established. Diseased and asymptomatic areas of lobster shell have been shown to contain distinct bacterial communities, suggesting some bacterial species may be beneficial and others pathogenic (Whitten et al. 2014). The freshwater treatment may alter the microbial community to aid in bacteria that can laterally spread the disease at the already damaged area of the claw. Whether this is done by creating the right environment for specific pathogenic bacteria or by some other mechanism is unknown. Lobsters treated with vitamin E and those in the control treatment showed a similar effect, but to a lesser degree. PVP-I, malachite green, and formalin had the least amount of wound size increase indicating that these treatments are effective in minimizing the growth of established lesions due to their antiseptic (PVP-I) or antimicrobial (malachite green and formalin) capacities.

The freshwater treatment may cause a stress response that may have caused the lobsters to be more susceptible to the microbial community that can expand shell disease. Speare et al. (1996) showed that lobsters treated in low salinity (i.e., 8) for 1-hr had lower sodium, chloride, and calcium levels in their hemolymph post-treatment compared to lobsters in a control group, and that the sodium and chloride levels did not recover 1-wk post-treatment. These low salinity treated lobsters also had a difference in behavior in comparison to lobsters in other treatment groups, including being less able to right themselves, having less response to visual stimulus, and less body rigidity post-treatment. While the lobsters in our study were not submerged in a bath, we cannot rule out that the treatment application had some negative physiological effects. This is an unlikely scenario given the treatment methodology, but fresh water may have entered the gill system when treating the ventral side of the lobster, which may have led to a physiological response specific to this treatment group. Shell disease is understood to be a multi-factorial disease as well as a polymicrobial disease. Even though the disease erodes externally on the shell with no internal infection, factors that can lower the overall health of lobsters,

such as poor diet, can make lobsters more susceptible to shell disease (Tlustý et al. 2008). The potential negative effects of the freshwater treatment combined with the treatment frequency may have resulted in continuous physiological distress that resulted in a higher susceptibility to shell disease progression.

Hikari® Biobandage did not appear to be beneficial for lobsters. It is important to note that this product is marketed solely as a fish treatment and not for invertebrates. However, given the ingredients in the product, neomycin sulfate and methylene blue, we expected some benefit of these antibiotics and antifungal agents. Biobandage is a blue liquid gel and is applied dropwise to the affected area. Upon re-immersion in water, it is possible that some of the product did not adhere to the abraded area and instead washed off the lobster (as indicated by observed blue coloration in the water), making the product ineffective. Biobandage was applied only to the abraded area of the shell and not the entire lobster, as was done in Study 2. It is not surprising then that the resulting rate of development of nonfacilitated disease lesions would be similar to the control lobsters, as both of these groups were effectively treated the same way in body areas away from the abraded area (i.e., handled frequently but were not treated beyond the abraded area of carapace). It was surprising that most of the lobsters in the late-stage treatment group did not develop lesions in the abraded area, as this method has been used in the past by our laboratory with success (Davies et al. 2014, Whitten et al. 2014). Most of the lobsters (5 out of 6) in this group received no treatments and were handled less frequently: only once a week for abrasion analysis and biweekly for shell disease analysis. Given that the product may not have adhered to the abraded area of the lobster shell, testing methylene blue and neomycin sulfate, together or separate, in a different application, such as a bath, may prove to be more effective, but care should be taken to avoid antibiotic resistance in using neomycin sulfate.

There may be other contributing factors beyond the antimicrobial properties of malachite green and formalin that led to their effectiveness in treating shell disease. These were the only treatments performed as baths, and it is possible that a bath application may be optimal for treating shell disease. If one were to convert the topical treatments into bath treatments, as suggested above for the active ingredients in Biobandage, it may lead to more effective results. However, care should be taken with PVP-I and freshwater (low salinity) treatments, as these are known to be toxic (PVP-I; Browne et al. 2009) or cause stress (Speare et al. 1996) in lobsters. A result of conducting bath treatments is the animals were handled less than those receiving topical treatments. Lobsters in all treatments for each study were handled similarly for shell disease analysis, wound facilitation, and picture taking, but those receiving topical treatments were handled frequently to apply treatments, either daily (Study 1) or three times per week (Study 2) vs the bath treatments, which were performed two times per week (Study 2). While care was taken not to excessively stress the lobsters during any handling procedure, it is possible that frequent handling caused a physiological stress that was not being visually observed in the animals. Handling and emersion time have been documented to cause stress in lobsters (Lavalley et al. 2000a,b). While these studies were performed on adult lobsters on lobster fishing vessels, in our studies, juveniles may be more susceptible to such stressors, even when care is taken to minimize these factors. Since increasing stressors can lead to increased shell disease (Castro et al. 2012), emersion time and handling may be unwittingly adding stress to animals held in captivity and causing an increase in disease

severity. In Study 2, where lobsters in the control treatment exhibited a faster rate of development of nonfacilitated shell disease lesions, the topical treatments may be providing a temporary synthetic barrier on the lobster's shell for a short duration, enough to either inhibit or decelerate disease-initiating bacteria from being able to attack the shell. It has been observed that physical barriers on the shell can prevent the formation of shell disease, as adult lobsters with banded claws generally do not exhibit shell disease on the banded area even if the remaining of the claw is severely diseased (A Kim, pers obs). However, this is speculation and the mechanism for how lobster handling may promote shell disease initiating bacteria is unknown.

In conclusion, the present study aimed to identify a treatment method for shell disease in lobsters that are held in public exhibits. Malachite green and formalin both show promise as a treatment method, but a more practical treatment plan and its effectiveness on not just rate of body areas affected, but also in number and size of lesions, needs to be assessed. Freshwater (distilled water) topical treatment can lead to a faster rate of exacerbation in damaged areas of shell, while frequent handling of lobsters without any treatment may lead to an increased rate in the development of nonfacilitated lesions. Other potential treatments should be tested and care should be taken if considering using formalin or malachite green for other crustacean species, as dosage and frequency may need to be altered accordingly. Use of these treatments with other crustaceans may not succeed as the etiology of shell disease varies by species. While neither of these treatments is applicable for use in fisheries or with wild populations, we encourage future research that focuses on being proactive and empowering people, whether aquarist staff or lobstermen, to working toward solutions to the problem of shell disease.

ACKNOWLEDGMENTS

The authors would like to thank the numerous volunteers and student interns who assisted in caring for the lobsters in the LRRF and performed treatments for these experiments. We thank C Innis and J Cavin for their input in determining effective treatments. We would also like to thank the Ruth D Turner Foundation for funding this work, and the two anonymous reviewers and the editor of this journal for their edits and insight. Experiments were performed in accordance with New England Aquarium Animal Care and Use Committee protocol 2014-05.

LITERATURE CITED

- Aiken D, Waddy S. 1980. Maturity and reproduction in the American lobster. *Can J Fish Aquat Sci.* 37:60–71.
- Alderman DJ. 1985. Malachite green: a review. *J Fish Dis.* 8:289–298. <https://doi.org/10.1111/j.1365-2761.1985.tb00945.x>
- Anderson WC, Turnipseed SC, Roybal JE. 2005. Quantitative and confirmatory analyses of malachite green and leucomalachite green residues in fish and shrimp. *Laboratory Information Bulletin.* No. 4363.
- Athanassopoulou F, Pappas IS, Bitchava K. 2009. An overview of the treatments for parasitic disease in Mediterranean aquaculture. *In: Rogers C, Basurco B, editors. The use of veterinary drugs and vaccines in Mediterranean aquaculture.* Zaragoza: CIHEAM.
- Bell SL, Allam B, McElroy A, Dove A, Taylor GT. 2012. Investigation of epizootic shell disease in American lobster (*Homarus americanus*) from Long Island Sound: I. Characterization

- of associated microbial communities. *J Shellfish Res.* 31(2):473–484. <https://doi.org/10.2983/035.031.0207>
- Bergeron CE. 2011. Research on lobster age-size relationships: developing regionally specified growth models from meta-analysis of existing data [thesis]. [Orono (ME)]: University of Maine.
- Braverman H, Leibovitz L, Lewbart GA. 2012. Green algal infection of American horseshoe crab (*Limulus polyphemus*) exoskeletal structures. *J Invertebr Pathol.* 111(1):90–93. <https://doi.org/10.1016/j.jip.2012.06.002>
- Browne R, Benavente GP, Uglem I, Marino Balsa JC. 2009. An illustrated hatchery guide for the production of clawed lobsters. Using a green water technique. *Aquac Explain.* 23.
- Bullis R, Leibovitz L, Swanson L, Young R. 1988. Bacteriologic investigation of shell disease in the deep-sea red crab, *Geryon quinquedens*. *Biol Bull.* 175:304.
- Caporaso JG, Lauber CL, Walters WA, Berg-Lyons D, Huntley J, Fierer N, Owens SM, Betley J, Fraser L, Bauer M. 2012. Ultra-high-throughput microbial community analysis on the Illumina HiSeq and MiSeq platforms. *ISME J.* 6(8):1621. <https://doi.org/10.1038/ismej.2012.8>
- Castro KM, Cobb JS, Gomez-Chiarri M, Tlusty M. 2012. Epizootic shell disease in American lobsters *Homarus americanus* in southern New England: past, present, and future. *Dis Aquat Organ.* 100:149–158. <https://doi.org/10.3354/dao02507>
- Chistoserdov AY, Quinn RA, Gubbala SL, Smolowitz R. 2012. Bacterial communities associated with lesions of shell disease in American lobster, *Homarus americanus* Milne-Edwards. *J Shellfish Res.* 31(2):449–462. <https://doi.org/10.2983/035.031.0205>
- Chistoserdov AY, Smolowitz R, Mirasol F, Hsu A. 2005. Culture-dependent characterization of the microbial community associated with epizootic shell disease lesions in American lobster, *Homarus americanus*. *J Shellfish Res.* 24(3):741–747. [https://doi.org/10.2983/0730-8000\(2005\)24\[741:CCOTMC\]2.0.CO;2](https://doi.org/10.2983/0730-8000(2005)24[741:CCOTMC]2.0.CO;2)
- Culp SJ. 2004. NTP Technical Report on the toxicity studies of malachite green chloride and leucomalachite green (CAS Nos. 569-64-2 and 129-73-7) administered in feed to F344/N rats and B6C3F1 mice. National Toxicology Program Toxicity Report Series. No. 71.
- Davies CE, Whitten MMA, Kim A, Wootton EC, Maffei TGG, Tlusty M, Vogan CL, Rowley AF. 2014. A comparison of the structure of American (*Homarus americanus*) and European (*Homarus gammarus*) lobster cuticle with particular reference to shell disease susceptibility. *J Invertebr Pathol.* 117:33–41. <https://doi.org/10.1016/j.jip.2014.01.001>
- Defoirdt T, Boon N, Sorgeloos P, Verstraete W, Bossier P. 2007. Alternatives to antibiotics to control bacterial infections: luminescent vibriosis in aquaculture as an example. *Trends Biotechnol.* 25(10):472–479. <https://doi.org/10.1016/j.tibtech.2007.08.001>
- Diggles BK. 1999. Diseases of spiny lobsters in New Zealand. Evans LH, Jones JB, editors. International Symposium on Lobster Health and Management: Proceedings. Adelaide, Australia.
- Duong A, Steinmaus C, McHale CM, Vaughan CP, Zhang L. 2011. Reproductive and developmental toxicity of formaldehyde: a systematic review. *Mutat Res.* 728(3):118–138. <https://doi.org/10.1016/j.mrrev.2011.07.003>
- Feinman SG, Martínez AU, Bowen JL, Tlusty ME. 2017. Fine-scale transition to lower bacterial diversity and altered community composition precedes shell disease in laboratory-reared juvenile American lobster. *Dis Aquat Organ.* 124(1):41–54. <https://doi.org/10.3354/dao03111>
- Fisher WS, Nilson EH, Steenbergen JE, Lightner DV. 1978. Microbial diseases of cultured lobsters: a review. *Aquaculture.* 14:115–140. [https://doi.org/10.1016/0044-8486\(78\)90025-X](https://doi.org/10.1016/0044-8486(78)90025-X)
- Francis-Floyd R. 1996. Use of formalin to control fish parasites. Gainesville, FL: University of Florida Cooperative Extension Service Institute of Food and Agricultural Sciences. VM-77; Accessed January 13, 2016. Available from: <http://fisheries.tamu.edu/files/2013/09/Use-of-Formalin-to-Control-Fish-Parasites.pdf>

- Gardner C, Northam M. 1997. Use of prophylactic treatments for larval rearing of giant crabs, *Pseudocarcinus gigas* (Lamarck). *Aquaculture*. 158:203–214. [https://doi.org/10.1016/S0044-8486\(97\)00182-8](https://doi.org/10.1016/S0044-8486(97)00182-8)
- Gilbert JA, Jansson JK, Knight R. 2014. The Earth Microbiome project: successes and aspirations. *BMC Biol*. 12(1):69. <https://doi.org/10.1186/s12915-014-0069-1>
- Goarant C, Brizard R, Marteau A-L. 2000. A white spot disease-like syndrome in the Pacific blue shrimp (*Litopenaeus stylirostris*) as a form of bacterial shell disease. *Aquaculture*. 183:25–30. [https://doi.org/10.1016/S0044-8486\(99\)00284-7](https://doi.org/10.1016/S0044-8486(99)00284-7)
- Gravetter F, Wallnau L. 2014. *Essentials of statistics for the behavioral sciences*. 8th ed. Belmont, CA: Wadsworth.
- Hadfield CA, Clayton LA. 2011. Fish quarantine: current practices in public zoos and aquaria. *J Zoo Wildl Med*. 42(4):641–650. <https://doi.org/10.1638/2011-0034.1>
- Hamasaki K, Hatai K. 1993. Prevention of fungal infection in the eggs and larvae of the swimming crab *Portunus trituberculatus* and the mud crab *Scylla serrata* by bath treatment with formalin. *Nippon Suisan Gakkaishi*. 59(6):1067–1072. <https://doi.org/10.2331/suisan.59.1067>
- Hashimoto JC, Paschoal JAR, de Querioz JF, Reyes FGR. 2011. Considerations on the use of malachite green in aquaculture and analytical aspects of determining the residues in fish: a review. *J Aquat Food Prod Technol*. 20(3):273–294. <https://doi.org/10.1080/10498850.2011.569643>
- Hess EA. 1937. Shell disease in lobsters (*Homarus americanus*) caused by chitiniferous bacteria. *J Biol Board Can*. 3:358–362. <https://doi.org/10.1139/f37-021>
- Holmström K, Gräslund S, Wahlström A, Pongshompoo S, Bengtsson BE, Kautsky N. 2003. Antibiotic use in shrimp farming and implications for environmental impacts and human health. *Int J Food Sci Technol*. 38:255–266. <https://doi.org/10.1046/j.1365-2621.2003.00671.x>
- Hughes JT, Shleser RA, Tchobanoglous G. 1974. A rearing tank for lobster larvae and other aquatic species. *Prog Fish-Cult*. 36:129–132. [https://doi.org/10.1577/1548-8659\(1974\)36\[129:ARTFLL\]2.0.CO;2](https://doi.org/10.1577/1548-8659(1974)36[129:ARTFLL]2.0.CO;2)
- Laufer H, Demir N, Biggers WJ. 2005. Response of the American lobster to the stress of shell disease. *J Shellfish Res*. 24(3):757–760. [https://doi.org/10.2983/0730-8000\(2005\)24\[757:RO TALT\]2.0.CO;2](https://doi.org/10.2983/0730-8000(2005)24[757:RO TALT]2.0.CO;2)
- Lavallee J, Hammell KL, Spangler ES, Cawthorn RJ, Dohoo IR. 2000a. Descriptive statistics of fishing practices, postharvest health status, and transport conditions in the Prince Edward Island lobster (*Homarus americanus*) industry. *J Shellfish Res*. 19:265–274.
- Lavallee J, Spangler ES, Hammell KL, Dohoo IR, Cawthorn RJ. 2000b. Analytical assessment of handling, fishing practices, and transportation risk factors on lobster (*Homarus americanus*) health in Prince Edward Island, Canada. *J Shellfish Res*. 19(1):275–281.
- Malachite (Malachite green contraindications and toxicity) [Internet]. [date unknown]. Hayward, CA: Kordon LLC. Accessed August 24, 2016. Available from: <http://www.kordon.com/kordon/products/chemical-preventatives-and-treatments-2/malachite-green#contraindications-toxicity!>
- Malloy SC. 1978. Bacteria induced shell disease of lobsters (*Homarus americanus*). *J Wildl Dis*. 14(1):2–10. <https://doi.org/10.7589/0090-3558-14.1.2>
- McVey JP. 1993. *CRC Handbook of mariculture crustacean aquaculture 2nd edition volume 1*. Boca Raton, FL: CRC Press, Inc.
- Meres NJ, Ajuzie CC, Sikaroodi M, Vemulapalli M, Shields JD, Gillevet PM. 2012. Dysbiosis in epizootic shell disease of the American lobster (*Homarus americanus*). *J Shellfish Res*. 31(2):463–472. <https://doi.org/10.2983/035.031.0206>
- Meyer FP, Jorgenson TA. 1983. Teratological and other effects of malachite green on development of rainbow trout and rabbits. *Trans Am Fish Soc*. 112(6):818–824. [https://doi.org/10.1577/1548-8659\(1983\)112<818:TAOEOM>2.0.CO;2](https://doi.org/10.1577/1548-8659(1983)112<818:TAOEOM>2.0.CO;2)

- Noga EJ, Engel DP, Arroll TW, McKenna S, Davidian M. 1994. Low serum antibacterial activity coincides with increased prevalence of shell disease in blue crabs *Callinectes sapidus*. *Dis Aquat Organ.* 19:121–128. <https://doi.org/10.3354/dao019121>
- Noga EJ, Hancock AL, Bullis RA. 2012. Crustaceans. *In: Lewbart GA, editor. Invertebrate medicine.* 2nd ed. West Sussex, UK: Wiley-Blackwell. p. 235–254.
- Porter L, Butler M, Reeves RH. 2001. Normal bacterial flora of the spiny lobster *Panulirus argus* and its possible role in shell disease. *Mar Freshw Res.* 52:1401–1405. <https://doi.org/10.1071/MF01092>
- Quinn RA, Metzler A, Smolowitz RM, Tlusty M, Chistoserdov AY. 2012. Exposures of *Homarus americanus* shell to three bacteria isolated from naturally occurring epizootic shell disease lesions. *J Shellfish Res.* 31(2):485–493. <https://doi.org/10.2983/035.031.0208>
- Shamsuzzaman MM, Biswas TK. 2012. Aqua chemical in shrimp farm: a study from south-west coast of Bangladesh. *Egypt J Aquat Res.* 38:275–285. <https://doi.org/10.1016/j.ejar.2012.12.008>
- Shields JD. 2011. Diseases of spiny lobsters: a review. *J Invertebr Pathol.* 106:79–91. <https://doi.org/10.1016/j.jip.2010.09.015>
- Smolowitz R, Chistoserdov A, Hsu A. 2005. Epizootic shell disease in the American lobster, *Homarus americanus*. *In: Lobster Shell Disease Workshop.* Tlusty M, Halvorson H, Smolowitz R, Sharma U, editors. Aquatic Forum Series 05-1. New England Aquarium, Boston (MA).
- Spangenberg JV. 2013. Investigation of the safety and efficacy of chloramine-T in the treatment of external fluke infestations. *KoiVet.* Accessed August 24, 2016. Available from: http://www.koivet.com/a_chloramine_T_bath_treatment_bacterial_infections_koi.html
- Speare DF, Cawthorn RJ, Horney BS, MacMillan R, MacKenzie AL. 1996. Effects of formalin, chloramine-T, and low salinity dip on the behavior and hemolymph biochemistry of the American lobster. *Can Vet J.* 37:729–734.
- Stevens BG. 2009. Effects of epizootic shell disease in American lobster *Homarus americanus* determined using a quantitative disease index. *Dis Aquat Organ.* 88:25–34. <https://doi.org/10.3354/dao02135>
- Strohmeier C. 2016. Aquarium and pond parasite and chemical treatments. Grants Pass, OR: American Aquarium Products. Updated 2017. Accessed January 13, 2016. Available from: <http://www.americanaquariumproducts.com/AquariumMedication3.html>
- Srivastava S, Sinha R, Roy D. 2004. Toxicological effects of malachite green. *Aquat Toxicol.* 66:319–329. <https://doi.org/10.1016/j.aquatox.2003.09.008>
- Sudova E, Machova J, Svobodova Z, Vesely T. 2007. Negative effects of malachite green and possibilities of its replacement in the treatment of fish eggs and fish: a review. *Vet Med.* 12:527–539.
- Tlusty MF, Metzler A. 2012. Relationship between temperature and shell disease in laboratory populations of juvenile American lobsters (*Homarus americanus*). *J Shellfish Res.* 31(2):533–541. <https://doi.org/10.2983/035.031.0213>
- Tlusty MF, Smolowitz RM, Halvorson HO, DeVito SE. 2007. Host susceptibility hypothesis for shell disease in American lobsters. *J Aquat Anim Health.* 19(4):215–225. <https://doi.org/10.1577/H06-014.1>
- Tlusty MF, Myers A, Metzler A. 2008. Short- and long-term dietary effects on disease and mortality on American lobster *Homarus americanus*. *Dis Aquat Organ.* 78:249–253. <https://doi.org/10.3354/dao01867>
- Tlusty MF, Kim A, Castro KM. 2014. Modeling shell disease in American lobsters (*Homarus americanus*) as individual-based health trajectories. *Can J Fish Aquat Sci.* 71:808–813. <https://doi.org/10.1139/cjfas-2013-0373>
- Vogan CL, Costa-Ramos C, Rowley AF. 2002. Shell disease syndrome in the edible crab, *Cancer pagurus* – isolation, characterization and pathogenicity of chitinolytic bacteria. *Microbiology.* 148:743–754. <https://doi.org/10.1099/00221287-148-3-743>

- Wagner EJ, Arndt RE, Billman EJ, Forest A, Cavender W. 2008. Comparison of the efficacy of iodine, formalin, salt, and hydrogen peroxide for control of external bacteria on rainbow trout eggs. *N Am J Aquaculture*. 70:118–127. <https://doi.org/10.1577/A06-068.1>
- Whitten MMA, Davies CE, Kim A, Tlusty M, Wootton EC, Chistoserdov A, Rowley AF. 2014. Cuticles of European and American lobster harbor diverse bacterial species and differ in disease susceptibility. *MicrobiologyOpen*. 3(3):395–409. <https://doi.org/10.1002/mbo3.174>
- Wickins JF, Lee DO'C. 2002. Techniques: species/groups. *In: Crustacean farming: ranching and culture*. 2nd ed. Oxford: Blackwell Science. p. 136–227.



