

# UCSF

## UC San Francisco Previously Published Works

### Title

A mass that has no (EBUS) echo

### Permalink

<https://escholarship.org/uc/item/6f05p3bn>

### Authors

Rosenblum, Matthew K

Wang, Sue X

Seeley, Eric J

### Publication Date

2018

### DOI

10.1016/j.rmcr.2017.11.001

Peer reviewed



## Case report

## A mass that has no (EBUS) echo

Matthew K. Rosenblum<sup>a,\*</sup>, Sue X. Wang<sup>a</sup>, Eric J. Seeley<sup>b</sup><sup>a</sup> Division of Surgery, University of California San Francisco, San Francisco, CA, USA<sup>b</sup> Division of Pulmonary and Critical Care Medicine, University of California San Francisco, San Francisco, CA, USA

## ARTICLE INFO

## Keywords:

Bronchogenic cysts  
Endobronchial ultrasound  
Hounsfield units

## ABSTRACT

We report findings for a patient that underwent endobronchial ultrasound (EBUS) guided transbronchial needle aspiration (TBNA) for diagnostic purposes after an abnormal chest CT. The patient initially presented with cough and shortness of breath. Chest CT revealed a 6 cm soft tissue mass with mildly enlarged right hilar lymph nodes (LNs) and a small right sided pleural effusion. Based on these radiologic findings, the patient underwent an EBUS guided FNA of the mass. To our surprise, the mass was hypoechoic by EBUS and on aspiration, the syringe filled with yellow fluid. This finding in combination with a re-review of the CT scans with a special focus on the Hounsfield Units of the lesion confirmed the diagnosis of a mediastinal bronchogenic cyst. This case demonstrates the role of Hounsfield units in analyzing mediastinal masses and highlights the effectiveness of EBUS guided TBNA in diagnosis and treatment of bronchogenic cysts.

## 1. Introduction

Bronchogenic cysts are a rare class of thoracic lesions that arise from abnormal budding of the ventral foregut during development [1]. Radiologic diagnosis of bronchogenic cysts can be challenging. The published literature suggests a diagnostic accuracy of 57–69.2% for CT imaging of bronchogenic cysts [2,3]. Diagnosis and treatment of these cysts traditionally involves invasive approaches including mediastinoscopy followed by surgical resection [4–8]. The development of minimally invasive techniques such as endobronchial ultrasound (EBUS) guided bronchoscopic biopsies has opened the door for new diagnostic and therapeutic approaches to these lesions [9]. Recent literature reports successful drainage of cysts via EBUS transbronchial needle aspiration (TBNA), with few reported complications [9–11]. In this article, we report the case of a bronchogenic cyst which upon initial radiologic review was thought to be a soft tissue density suggestive of lymphoma. This case illustrates the importance of the Hounsfield units and ultrasound imaging in correctly diagnosing thin walled paratracheal pathologies.

## 2. Case report

A 40-year-old obese man with a history of hypertension, metham-

phetamine use, and heart failure presented to an outside ED with chest discomfort and shortness of breath. A chest x-ray revealed a right paratracheal mass measuring 6 cm which was confirmed on follow-up CT. CT also showed a small right-sided pleural effusion and moderate hilar, mediastinal, mesenteric and pelvic lymphadenopathy (Fig. 1). The initial outside radiographic read considered these imaging findings concerning for lymphoma vs. metastatic primary lung malignancy. The Hounsfield Units of the initial scan were 17.8.

The patient was initially referred to thoracic surgery, but given the proximity of the lesion to the trachea, thoracic surgery referred the patient for consultation by interventional pulmonary with endobronchial ultrasound (EBUS) guided transbronchial needle aspiration (TBNA). Bronchoscopy with EBUS guided FNA was performed in the operating room under general anesthesia using a laryngeal mask airway (LMA). To our surprise, the mass was hypoechoic, yet Doppler US (Fig. 2a) did not suggest any blood flow through the lesion. A 22 gauge EBUS needle was inserted into the lesion under direct US guidance. On aspiration, the syringe filled with a serous fluid (Fig. 2b). Cytologic analysis of the sample showed a paucicellular proteinaceous fluid with occasional foamy macrophages and no evidence of malignancy.

Further review of the outside pulmonary embolism (PE) protocol CT taken in conjunction with the biopsy results confirmed the clinical picture was most consistent with a bronchogenic cyst. In addition, re-

\* Corresponding author. 2340 Sutter St, Room N26, San Francisco, CA 94143-1724, USA.  
E-mail address: [Rosenblum.matthew1@gmail.com](mailto:Rosenblum.matthew1@gmail.com) (M.K. Rosenblum).

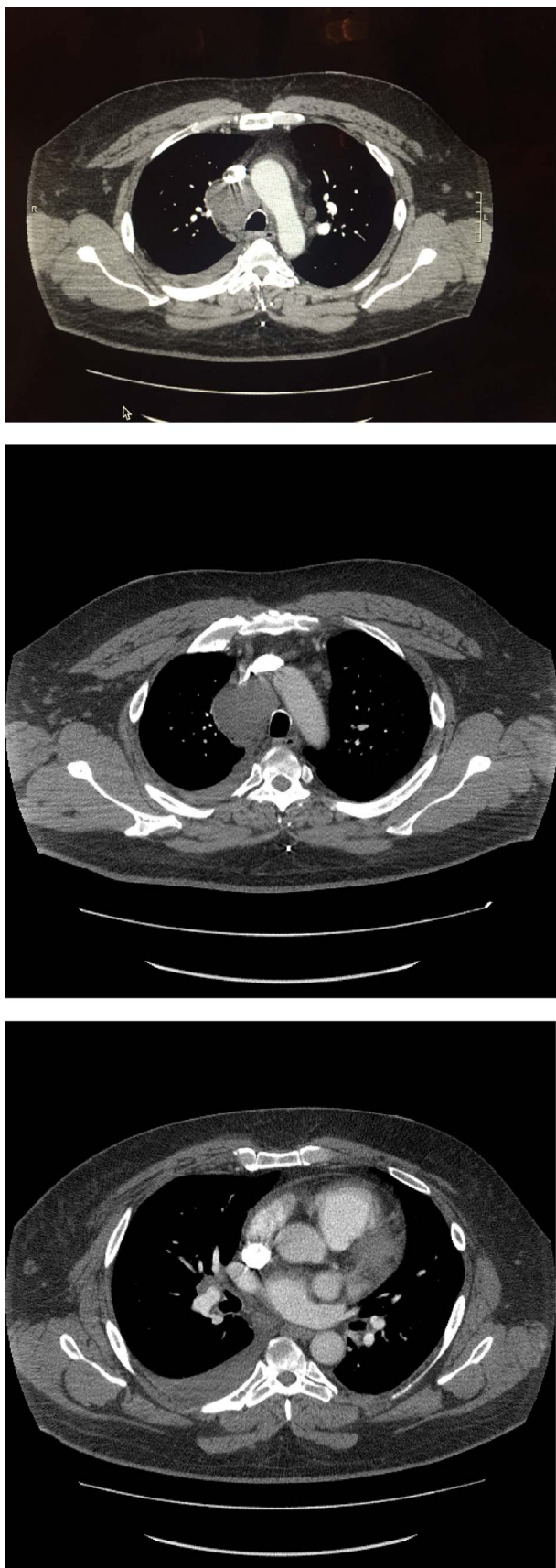

Fig. 1. CT scan showing a paratracheal mass with hilar adenopathy and a pleural effusion.

read of the outside CT suggested the presence of a PE, which helped explain the hilar and mediastinal adenopathy and pleural effusion. Due to concern for PE, a repeat PE protocol CT was performed showing no evidence of a current PE; furthermore, it showed resolution of the ipsilateral pleural effusion and hilar and mediastinal lymphadenopathy. The cyst was reduced to from 6 cm to 3 cm following drainage (Fig. 3). Since undergoing EBUS guided TBNA, our patient has reported a good functional outcome with total resolution of his symptoms and greatly improved exercise tolerance.

### 3. Discussion

Bronchogenic cysts can be difficult to diagnose and the optimal treatment remains unclear. Studies suggest bronchogenic cysts are misclassified as soft tissue masses in 4 out of 10 patients [3]. Several radiographic features may be suggestive of bronchogenic cysts. These include, 1) sharply marginated, thin walled masses with either smooth or lobulated borders 2) low attenuation and 3) homogenous attenuation [3]. Special attention should be paid to these radiologic nuances in order to ensure proper pre-procedural diagnosis. If ambiguity persists, sampling of the lesion may be safely attempted using EBUS guided FNA. Table 1 lists Hounsfield Unit ranges for common mediastinal lesions and surrounding tissues:

Due to the rare nature of this congenital pulmonary abnormality, there is little evidence to guide management. Management options include observation, EBUS guided drainage, and surgical resection [1,2,4]. Long term complications of bronchogenic cysts include infection, hemorrhage, or neoplasia within the cyst [3]. Although these complications are rare, drainage or resection of the cyst is recommended in young, asymptomatic patients [3,13] and in all symptomatic patients unless the surgical risk is unreasonably high [3,11]. This case demonstrates the efficacy of EBUS guided TBNA as a tool for both diagnosis and treatment of bronchogenic cysts.

### 4. Conclusions

This case and current literature show that EBUS guided TBNA can be a useful tool in the diagnosis and treatment of bronchogenic cysts, particularly in patients that are sub-optimal surgical candidates. Special care should be taken by diagnostic radiologists and interventional pulmonologist when interpreting CT scans of mediastinal lesions, with Hounsfield units of less than 20 being a useful cut-off in differentiating bronchogenic cysts from soft tissue lesions.

### Conflicts of interest

No conflicts of interest exist for any of the authors.

### Sources of funding

None.

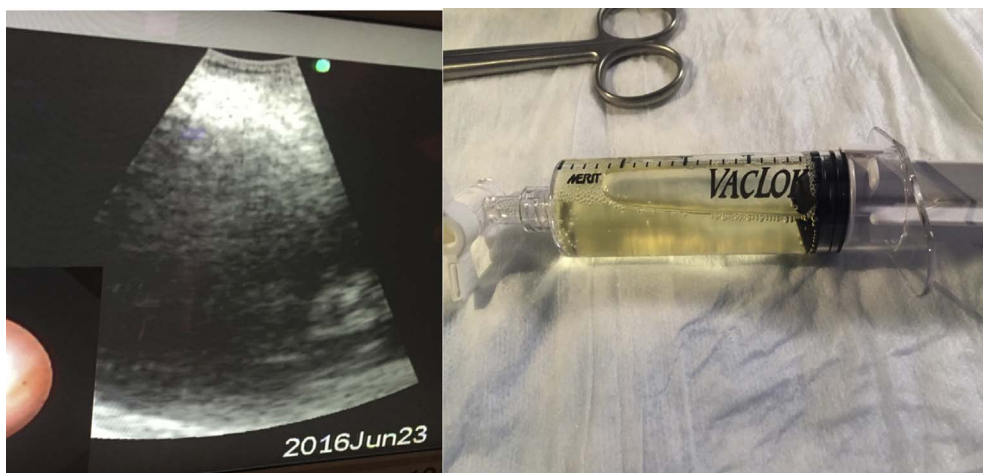

Fig. 2. Doppler US image and syringe with fluid aspirated from the paratracheal mass.

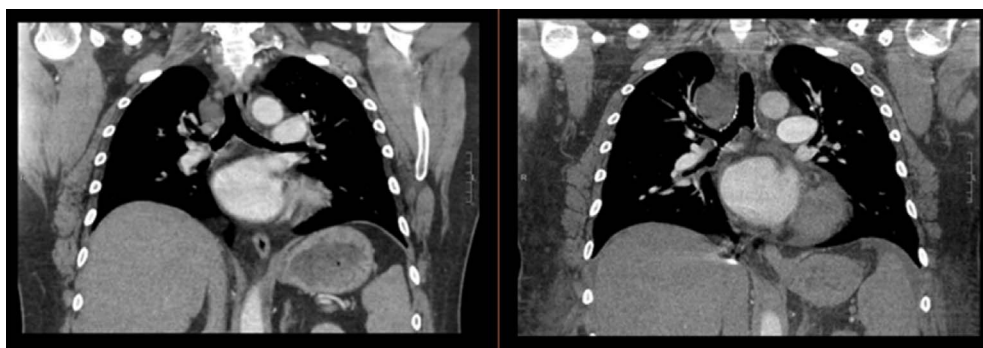


Fig. 3. CT imaging of the paratracheal mass before (right) and after (left) aspiration using the EBUS needle.

**Table 1**  
Hounsfield units for common mediastinal lesions and surrounding tissues [3,12].

Substance	Hounsfield Units (HU)
Fat	– 50
Water	0
Bronchogenic cyst	< 20
Soft-tissue mass	> 20
Muscle	+ 40
Calculus	+ 100 to + 400

**References**

- [1] Andrew Twehues, Shaheen Islam, Cystic lesions of the thorax: role of endobronchial ultrasound-guided transbronchial needle aspiration, *J. Bronchol. Intervent. Pulmonol.* 18 (3) (2011) 265–268 PubMed. Web.
- [2] Y. Kanemitsu, et al., Clinical features and management of bronchogenic cysts: report of 17 cases, *Surg. Today* 29 (11) (1999) 1201–1205 Print.
- [3] H.P. McAdams, et al., Bronchogenic cyst: imaging features with clinical and histopathologic correlation, *Radiology* 217 (2) (2000) 441–446 PubMed. Web.
- [4] J.W. Bolton, D.M. Shahian, Asymptomatic bronchogenic cysts: what is the best management? *Ann. Thorac. Surg.* 53 (6) (1992) 1134–1137 Print.
- [5] Wobbe Bouma, et al., Removal of a giant intrathoracic cyst from the anterior mediastinum, *J. Cardiothorac. Surg.* 9 (2014) 152 PubMed. Web.
- [6] Manouchehr Hekmat, et al., Giant pericardial cyst: a case report and review of literature, *Iran. J. Radiol. A Q. J. Publ. by Iran. Radiol. Soc.* 13 (1) (2016) e21921PubMed. Web.
- [7] Giant pericardial cyst: a case report and review of literature, *Iran. J. Radiol. A Q. J. Publ. by Iran. Radiol. Soc.* 13 (1) (2016) e21921PubMed. Web.
- [8] Aleksandar Kiralj, Nada Vučković, Ivana Mijatov, Congenital cervical bronchogenic cyst: a case report, *Srp. Arh. Za Celok. Lek.* 143 (5–6) (2015) 317–321 Print.
- [9] Venkata N. Maturu, Sahajal Dhooria, Ritesh Agarwal, Efficacy and safety of transbronchial needle aspiration in diagnosis and treatment of mediastinal bronchogenic cysts: systematic review of case reports, *J. Bronchol. Intervent. Pulmonol.* 22 (3) (2015).
- [10] Giovanni Galluccio, Gabriele Lucantoni, Mediastinal bronchogenic Cyst's recurrence treated with EBUS-FNA with a long-term follow-up, *Eur. J. Cardio-Thoracic Surg. Off. J. Eur. Assoc. Cardio-Thoracic Surg.* 29 (4) (2006) 627–629 discussion 629. PubMed. Web.
- [11] Han, Se Eun, et al., “Mediastinal bronchogenic Cysts: demonstration of fluid-fluid level in bronchoscopic US imaging, *J. Bronchol. Intervent. Pulmonol.* (2016) 153–155 PubMed. Web.
- [12] J. Higgins, J. Fitzgerald, Evaluation of incidental renal and adrenal masses, *Am. Fam. Physician* 63 (2) (2001) 288–294.
- [13] U. Cioffi, L. bonavina, M. De Simone, et al., Presentation and surgical management of bronchogenic and esophageal duplication cysts in adults, *Chest* 113 (1998) 1492–1496.