

# UC Davis

## Dermatology Online Journal

### Title

Primary vulvar Paget disease - the importance of clinical suspicion

### Permalink

<https://escholarship.org/uc/item/6ff381x4>

### Journal

Dermatology Online Journal, 23(10)

### Authors

Mota, Fernando  
Horta, Miguel  
Marques, Claudia  
et al.

### Publication Date

2017

### DOI

10.5070/D32310037001

### Copyright Information

Copyright 2017 by the author(s). This work is made available under the terms of a Creative Commons Attribution-NonCommercial-NoDerivatives License, available at <https://creativecommons.org/licenses/by-nc-nd/4.0/>

Peer reviewed

# Primary vulvar Paget disease – the importance of clinical suspicion

Fernando Mota<sup>1</sup>, Miguel Horta<sup>1</sup>, Claudia Marques<sup>2</sup>, Susan Foreid<sup>3</sup>, Manuela Selores<sup>1,4,5</sup>

Affiliations: <sup>1</sup>Dermatology Department, Centro Hospitalar do Porto, Portugal, <sup>2</sup>Gynecology and Obstetrics Department, Centro Hospitalar do Porto, Portugal, <sup>3</sup>Anatomo-pathology, Laboratório Macedo Dias, Porto, Portugal, <sup>4</sup>Dermatology Research Unit, Centro Hospitalar do Porto, Portugal, <sup>5</sup>Instituto de Ciências Biomédicas Abel Salazar, Universidade do Porto, Portugal

Corresponding Author: Fernando Mota, Rua Central, 180, Branzelo, 4515-498 Melres, Portugal, Email: fernandojrmota@gmail.com

## Abstract

Extramammary Paget disease of the vulva is a rare condition that accounts for only 1-2% of vulvar malignancies and represents a frequent cause of misdiagnosis. It is most commonly seen in postmenopausal women. Clinically it is similar to Paget disease of the breast, appearing as red, well-demarcated eczematoid lesions, with slightly raised edges. A high degree of clinical suspicion is very important when evaluating these lesions in order to avoid misdiagnosis and delay of effective treatment. We present a case of vulvar Paget disease treated with vulvectomy.

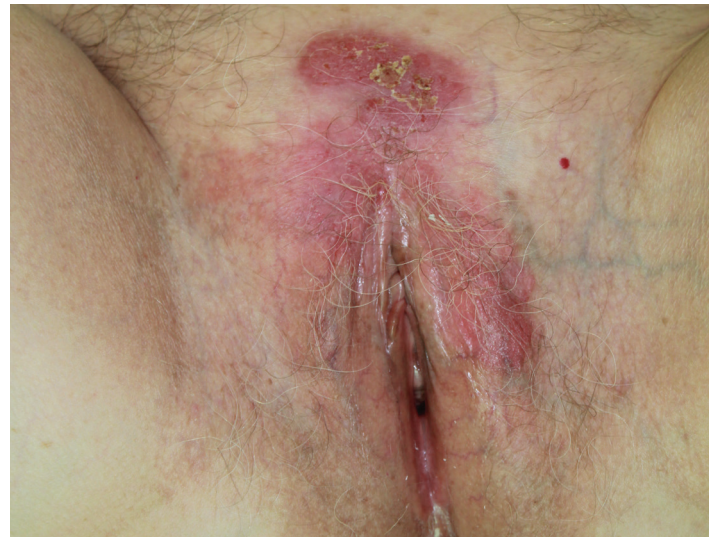**Keywords:** extramammary Paget disease; vulvar Paget disease; vulvar oncology

## Introduction

Vulvar cancer is the fourth most common gynecologic cancer comprising five percent of malignancies involving the female genital tract. Extramammary Paget disease (EMPD) of the vulva is a rare disease that accounts for only 1-2% of vulvar malignancies and represents a frequent cause of misdiagnosis [1,2]. We present a case of primary vulvar EMPD treated with simple vulvectomy.

## Case Synopsis

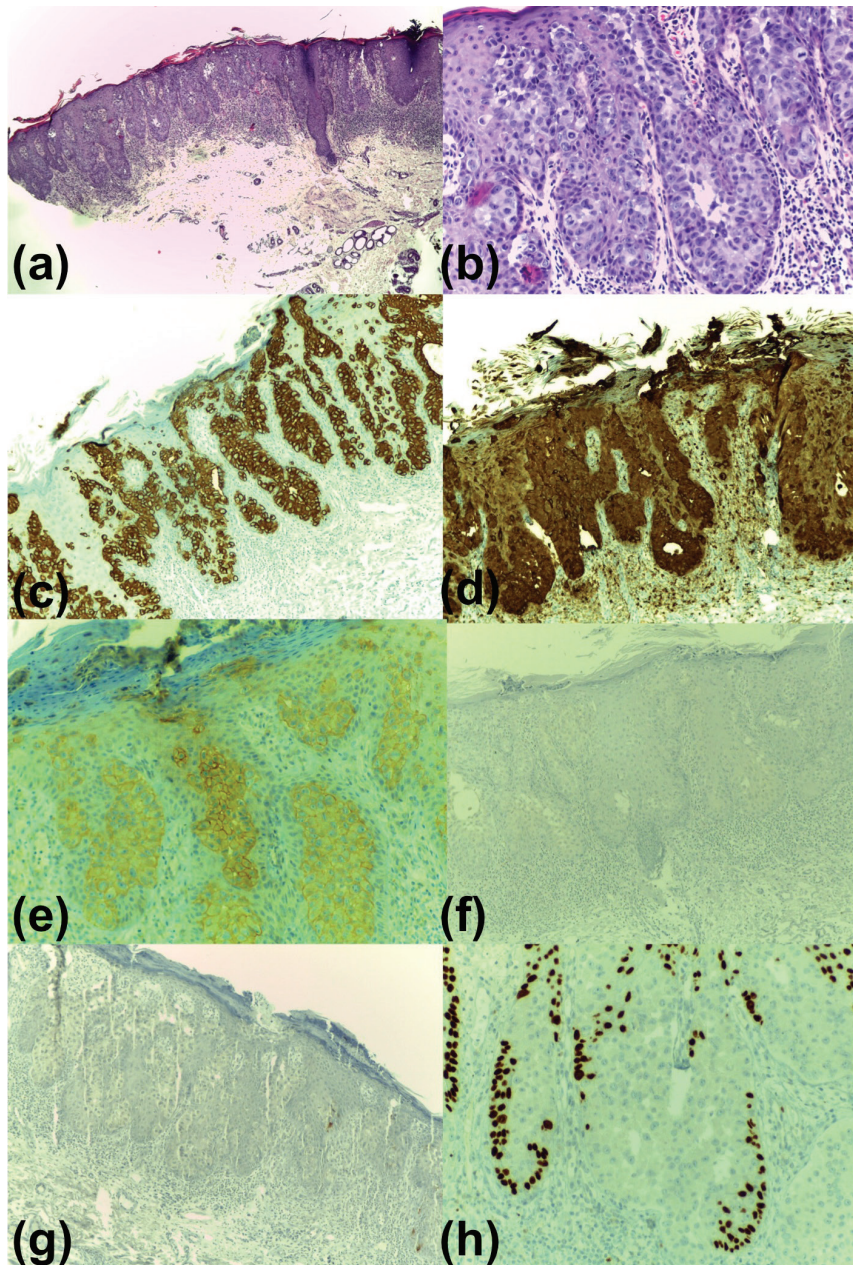
A 78-year-old woman was referred to our department owing to a 3-year history of a pruritic cutaneous plaque with an eczematous appearance located in the suprapubic area and extending to the vulva. She had undergone previous treatments with topical corticosteroids, alone and in association



**Figure 1.** Clinical aspect of the lesion.

with vitamin D derivatives and antifungals, without improvement. Her past medical history was otherwise unremarkable. There was no family history of skin disease. Age appropriate cancer screening was up-to-date and without changes. On physical examination, the patient had an erythematous, well-demarcated plaque with scaling and ulcerated areas occupying the suprapubic area and labia majora (**Figure 1**). No other relevant changes were found, including adenopathies or organomegalies.

Owing to a clinical suspicion of Paget disease, a skin biopsy was performed revealing an epidermal infiltrate composed of aggregates of large atypical cells with vesicular nuclei, prominent nucleoli, and clear cytoplasm; mitoses were also visible (**Figure 2a, b**). Immunostaining was positive for cytokeratin (CK) 7, carcinoembryonic antigen (CEA), and human epidermal growth factor receptor (HER) 2 (**Figure 2c-e**). Stains were negative for cytokeratin (CK) 20,



**Figure 2.** Histology and immunohistochemistry: a) H&E, 4%; b) H&E, 10%; Immunohistochemistry, 10%, positivity for c) CK7, d) CEA and e) HER2. Immunohistochemistry, 10%, negative for f)–h) CK20, MelanA and p63, respectively.

MelanA, and p63 (**Figure 2f-h**), and S100 protein (not shown).

A thoracoabdominopelvic computed tomography and a colonoscopy were performed and did not reveal an underlying neoplasm. A diagnosis of primary vulvar EMPD was made. After discussing treatment options with the patient, she was referred to the gynecology department for treatment and a simple vulvectomy was performed (**Figures 3, 4**). She has remained disease-free after a follow-up of 16 months.

## Case Discussion

Extramammary Paget disease was first described in 1889 by Crocker, whereas Dubreuilh reported the first case of Paget disease of the vulva in 1901 [3,4]. It is a rare intra-epithelial adenocarcinoma, which affects mainly postmenopausal women [5]. Most patients are Caucasian and in their 60s or 70s [6-8].

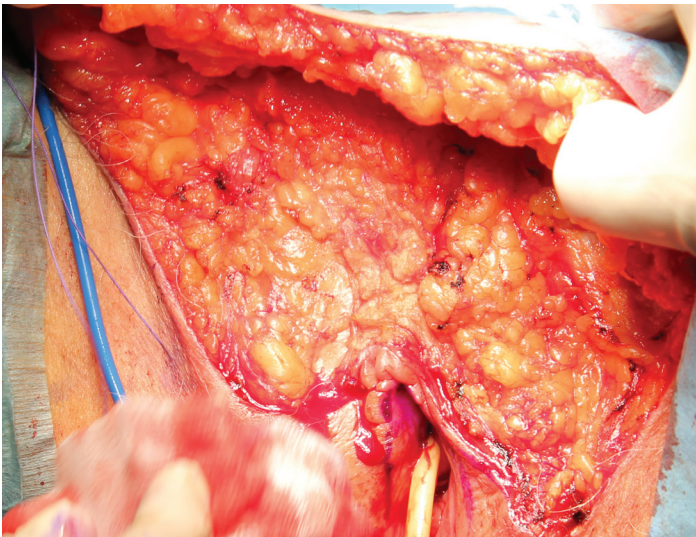
The vulva is the most common site of extra-mammary PD [9]. Other affected body regions include: perianal region, groin, thigh, buttocks, axilla, eyelids, and external ear canal [9]. Scrotum and penis involvement may also be found in men [9].

EMPD may be primary or secondary [9,10]. Primary EMPD accounts for the majority of cases and is believed to arise from cutaneous adnexal glandular epithelium; it is not associated with underlying malignancies. The cell origin of primary PD is uncertain [9]. The Paget cells in secondary EMPD are thought to be epidermotropic metastatic cancer cells from a visceral adenocarcinoma [9,10].

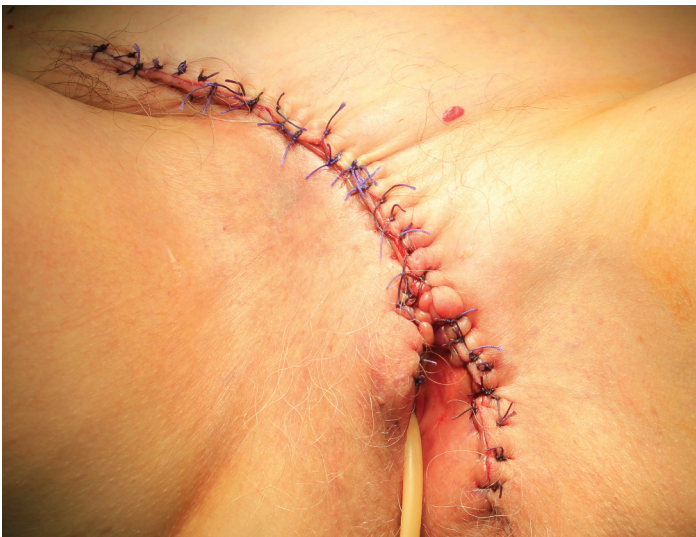Clinically, EMPD typically presents as a well-demarcated red or brown plaque with an eczematoid appearance, with variable areas of induration, crusting, scaling, or ulceration [11]. Pruritus is a common complaint [5].

EMPD is a frequent cause of misdiagnosis and thus delayed effective treatment. It has been reported that the time from onset of symptoms to diagnosis can range up to over 30 years [9]. Clinical differential diagnoses may include cutaneous candidiasis, tinea cruris, seborrheic dermatitis, psoriasis, Bowen disease, or melanoma (pigmented variant of EMPD).

Histology is required to confirm the diagnosis and immunohistopathology helps to distinguish this disease from other entities such as atypical squamous cell carcinoma and melanoma [12,13]. Typical histological findings are large cells (Paget cells) with abundant basophilic, finely granular cytoplasm and



**Figure 3.** Intra-operative aspect of simple vulvectomy.



**Figure 4.** Immediate post-operative aspect after simple vulvectomy with complete clearance of the lesion.

a large central nucleus, sometimes with a prominent nucleolus [12]. Pronounced nuclear atypia and pleomorphism are present. These cells might be found isolated or in clusters. Most cells are found in the lower epidermis, although infiltration of the upper strata may also be seen [12]. The combination of careful observation of morphological features with appropriate histochemical stains (positivity for Cam 5.2, Epithelial Membrane Antigen, CEA) allows confirmation of the diagnosis in most cases in clinical practice [12,13]. In our case, the combination of positive CK 7 and CEA and negative p63 was used to distinguish EMPD from in situ 'pagetoid' squamous cell carcinoma. The negativity for MelanA and S100 protein excluded melanocytic differentiation, namely melanoma. CK 20 is typically positive in pagetoid

spread of underlying regional internal malignancy. The combination of positive CK 7 and negative CK 20 was useful in distinguishing primary EMPD from a pagetoid spread of extracutaneous malignancies.

It has been established that vulvar EMPD has a positive association with other internal malignancies, with a frequency of around 20% [5,8]. Particularly, it has been reported to be associated with an underlying adnexal carcinoma in 4-17% of cases [8]. Furthermore, different sites of EMPD may be associated with different underlying tumors [12]. EMPD of the external male and female genitalia may be associated with neoplasms arising in the bladder and urethra, and in the prostate in men [12]. EMPD of the perianal skin is often associated with colorectal tumors [12]. Some cases have been reported to involve the skin of the extremities and abdomen [12].

Although there is no consensus about which tests should be performed, the diagnosis of EMPD should prompt a comprehensive age-appropriate cancer screening (including colonoscopy, urinalysis, Pap smear and mammography in women, prostate-specific antigen measurement in men), [14]. The authors consider that an abdominal and pelvic ultrasonography or computed tomography can be further performed to exclude urinary tract involvement. Early diagnosis and long-term follow-up are the keys to successful management.

The standard treatment is local excision of the affected area with adequate margins. However, 40~45% of cases recur after surgery within 4 years [15]. Other treatments for localized, inoperable, or recurrent disease include photodynamic therapy, laser therapy, radiotherapy, topical treatments, or even chemotherapy [16-18]. Among topical treatments, imiquimod has shown good response rates (71% of complete response), [19]. With close follow-up, it may be used in women with EMPD of the vulva to avoid surgery. It may also be used in cases with involved surgical resection margins, given that the patient is willing to tolerate local side effects [19].

The prognosis varies according to the degree of invasion and the presence of an underlying carcinoma (excellent in EMPD confined to the epidermis compared to 0% 5-year survival in the

presence of inguinal lymph node metastases), [12]. Lengthy follow up is advocated for all cases of EMPD. In our case only the vulva was involved and complete clearing of the tumor was achieved with surgical excision.

## Conclusion

The authors present a case of a disease in which a high degree of clinical suspicion is very important in order to avoid misdiagnosis and delay in effective treatment.

## References

1. Curtin JP, Rubin SC, Jones WB, Hoskins WJ, Lewis JL. Paget's disease of the vulva. *Gynecol Oncol.* 1990;39:374-377. [PMID: 2175288].
2. Billings SD, Roth LM. Pseudoinvasive, nodular extramammary Paget's disease of the vulva. *Arch Pathol Lab Med.* 1998;122:471-474. [PMID: 9593351].
3. Crocker HR. Paget's disease affecting the scrotum and penis. *Trans Pathol Soc London.* 1889;40:187-191.
4. Dubreuilh W. Paget's disease of the vulva. *Br J Dermatol.* 1901;13:403-13.
5. Baehrendtz H, Einhorn N, Pettersson F, Silfverswärd C. Paget's disease of the vulva: the Radiumhemmet series 1975-1990. *Int J Gynecol Cancer.* 1994;4:1-6. [PMID: 11578378].
6. Gregori CA, Smith CI, Breen JL. Extramammary Paget's disease. *Clin Obstet Gynecol.* 1978;3:1107-15. [PMID: 216512].
7. Bergen S, DiSaia PJ, Liao SY, Berman ML. Conservative management of extramammary Paget's disease of the vulva. *Gynecol Oncol.* 1989;33:151-6. [PMID: 2539315].
8. Fanning J, Lambert H, Hale TM, Morris PC, Schuerch C. Paget's disease of the vulva: prevalence of associated vulvar adenocarcinoma, invasive Paget's disease, and recurrence after surgical excision. *Am J Obstet Gynecol.* 1999;180:24-7. [PMID: 9914572].
9. Jones IS, Crandon A, Sanday K. Paget's disease of the vulva: Diagnosis and follow-up key to management; a retrospective study of 50 cases from Queensland. *Gynecol Oncol.* 2011;122:42-4. [PMID: 21501860].
10. De la Garza Bravo MM, Curry JL, Torres-Cabala CA, Ivan DS, Drucker C, Prieto VG, Tetzlaff MT. Pigmented extramammary Paget disease of the thigh mimicking a melanocytic tumor: report of a case and review of the literature. *J Cutan Pathol.* 2014;41:529-35. [PMID: 24698435].
11. Parker LP, Parker JR, Bodurka-Bevers D, Deavers M, Bevers MW, Shen-Gunther J, Gershenson DM. Paget's disease of the vulva: pathology, pattern of involvement, and prognosis. *Gynecol Oncol.* 2000;77:183-9. [PMID: 10739709].
12. Lloyd J, Flanagan AM. Mammary and extramammary Paget's disease. *J Clin Pathol.* 2000;53:742-9. [PMID: 11064666].
13. Wang EC1, Kwah YC, Tan WP, Lee JS, Tan SH. Extramammary Paget disease: Immunohistochemistry is critical to distinguish potential mimickers. *Dermatol Online J.* 2012;18:4. [PMID: 23031371].
14. van der Linden M, Meeuwis KA, Bulten J, Bosse T, van Poelgeest MI, de Hullu JA. Paget disease of the vulva. *Crit Rev Oncol Hematol.* 2016;101:60-74. [PMID: 26971063].
15. Barmon D, Kataki AC, Imchen L, Sharma JD. Extra mammary Paget's disease of the vulva. *J Midlife Health.* 2012;3:100-102. [PMID: 23372329].
16. Son SH, Lee JS, Kim YS, Ryu MR, Chung SM, Namkoong SE, Han GT, Lee HJ, Yoon SC. The role of radiation therapy for the extramammary Paget's disease of the vulva: experience of 3 cases. *Cancer Res Treat.* 2005;37:365-9. [PMID: 19956374].
17. Shieh S, Dee AS, Cheney RT, Frawley NP, Zeitouni NC, Oseroff AR. Photodynamic therapy for the treatment of extramammary Paget's disease. *Br J Dermatol.* 2002;146:1000-5. [PMID: 12072068].
18. Berman B, Spencer J, Villa A, Poochareon V, Elgart G. Successful treatment of extramammary Paget's disease of the scrotum with imiquimod 5% cream. *Clin Exp Dermatol.* 2003;28:36-8. [PMID: 14616812].
19. Dogan A, Hilal Z, KrenTel:H, Cetin C, Hefler LA, Grimm C, Tempfer CB. Paget's Disease of the Vulva Treated with Imiquimod: Case Report and Systematic Review of the Literature. *Gynecol Obstet Invest.* 2017;82:1-7. [PMID: 27655036].