

# UC Irvine

## UC Irvine Previously Published Works

### Title

Provisional practice recommendation for the management of myopathy in VCP-associated multisystem proteinopathy.

### Permalink

<https://escholarship.org/uc/item/6j77z1f7>

### Journal

Annals of clinical and translational neurology, 10(5)

### ISSN

2328-9503

### Authors

Roy, Bhaskar  
Peck, Allison  
Evangelista, Teresinha  
et al.

### Publication Date

2023-05-01



### DOI

10.1002/acn3.51760

Peer reviewed

## REVIEW ARTICLE

**Provisional practice recommendation for the management of myopathy in VCP-associated multisystem proteinopathy**

Bhaskar Roy<sup>1</sup> , Allison Peck<sup>2</sup>, Teresinha Evangelista<sup>3</sup>, Gerald Pfeffer<sup>4</sup>, Leo Wang<sup>5</sup>, Jordi Diaz-Manera<sup>6</sup>, Manisha Korb<sup>7</sup>, Matthew P. Wicklund<sup>8</sup>, Margherita Milone<sup>9</sup> , Miriam Freimer<sup>10</sup>, Hani Kushlaf<sup>11</sup>, Rocio-Nur Villar-Quiles<sup>12</sup>, Tanya Stojkovic<sup>12</sup>, Merrilee Needham<sup>13</sup>, Johanna Palmio<sup>14</sup>, Thomas E. Lloyd<sup>15,16</sup>, Benison Keung<sup>1</sup>, Tahseen Mozaffar<sup>7</sup>, Conrad Chris Weihl<sup>17</sup> & Virginia Kimonis<sup>7,18</sup>

<sup>1</sup>Department of Neurology, Yale School of Medicine, New Haven, Connecticut, USA

<sup>2</sup>Cure VCP Disease, Americus, Georgia, USA

<sup>3</sup>GH Pitié-Salpêtrière, Sorbonne Université-Inserm UMRS97, Institut de Myologie, Paris, France

<sup>4</sup>Hotchkiss Brain Institute, Department of Clinical Neurosciences, University of Calgary Cumming School of Medicine, Calgary, Alberta, Canada

<sup>5</sup>Department of Neurology, University of Washington, Seattle, Washington, USA

<sup>6</sup>John Walton Muscular Dystrophy Research Centre, Newcastle University, Newcastle upon Tyne, UK

<sup>7</sup>Department of Neurology, University of California—Irvine School of Medicine, Orange, California, USA

<sup>8</sup>Department of Neurology, University of Colorado, Denver, Colorado, USA

<sup>9</sup>Department of Neurology, Mayo Clinic, Rochester, Minnesota, USA

<sup>10</sup>Department of Neurology, Ohio State University, Columbus, Ohio, USA

<sup>11</sup>Department of Neurology and Rehabilitation Medicine, University of Cincinnati College of Medicine, Cincinnati, Ohio, USA

<sup>12</sup>APHP, Reference Center for Neuromuscular Disorders, Center of Research in Myology, Sorbonne Université-Inserm UMRS974, Pitié-Salpêtrière Hospital, Paris, France

<sup>13</sup>University of Notre Dame, Murdoch University and Fiona Stanley Hospital, Perth, Australia

<sup>14</sup>Neuromuscular Research Center, Tampere University Hospital, Tampere, Finland

<sup>15</sup>Department of Neurology, Johns Hopkins University School of Medicine, Baltimore, Massachusetts, USA

<sup>16</sup>Department of Neuroscience and Pathology, Johns Hopkins University School of Medicine, Baltimore, Massachusetts, USA

<sup>17</sup>Department of Neurology, Washington University School of Medicine, St. Louis, Missouri, USA

<sup>18</sup>Department of Pediatrics, University of California—Irvine School of Medicine, Orange, California, USA

**Correspondence**

Bhaskar Roy, Department of Neurology, Yale School of Medicine, P.O. Box 208018, New Haven, CT, USA. Tel: 2037853070; fax: 2037856246; E-mail: [bhaskar.roy@yale.edu](mailto:bhaskar.roy@yale.edu)  
Virginia Kimonis, Department of Pediatrics, University of California—Irvine School of Medicine, Orange, CA, USA. Tel: 7144565791; fax: 7144565330; E-mail: [vkimonis@hs.uci.edu](mailto:vkimonis@hs.uci.edu)

**Funding Information:** No funding information provided.

Received: 19 January 2023; Revised: 1 March 2023; Accepted: 3 March 2023

**Annals of Clinical and Translational Neurology** 2023; 10(5): 686–695

doi: 10.1002/acn3.51760

Three of the authors (Teresinha Evangelista, Rocio-Nur Villar-Quiles, Tanya Stojkovic) of this publication are members of the

**Abstract**

Valosin-containing protein (VCP)-associated multisystem proteinopathy (MSP) is a rare genetic disorder with abnormalities in the autophagy pathway leading to various combinations of myopathy, bone diseases, and neurodegeneration. Ninety percent of patients with VCP-associated MSP have myopathy, but there is no consensus-based guideline. The goal of this working group was to develop a best practice set of provisional recommendations for VCP myopathy which can be easily implemented across the globe. As an initiative by Cure VCP Disease Inc., a patient advocacy organization, an online survey was initially conducted to identify the practice gaps in VCP myopathy. All prior published literature on VCP myopathy was reviewed to better understand the different aspects of management of VCP myopathy, and several working group sessions were conducted involving international experts to develop this provisional recommendation. VCP myopathy has a heterogeneous clinical phenotype and should be considered in patients with limb-girdle muscular dystrophy phenotype, or any myopathy with an autosomal dominant pattern of inheritance. Genetic testing is the only definitive way to diagnose VCP myopathy, and single-variant testing in the case of a known familial VCP variant, or multi-gene panel sequencing in undifferentiated cases can be considered. Muscle biopsy is important in cases of diagnostic uncertainty or lack of a definitive pathogenic genetic variant since rimmed vacuoles (present in ~40% cases) are considered a hallmark of VCP myopathy. Electrodiagnostic studies and

European Reference Network for Rare Neuromuscular Diseases (ERN EURO-NMD)—Project ID No 739543.

magnetic resonance imaging can also help rule out disease mimics. Standardized management of VCP myopathy will optimize patient care and help future research initiatives.

## Introduction

Multisystem proteinopathy (MSP) is a rare genetic disorder with abnormalities in the autophagy pathway leading to various combination of myopathy, bone disease, and neurodegeneration.<sup>1–3</sup>

The classic triad of MSP, inclusion body myopathy, Paget disease of the bone (PDB), and frontotemporal dementia, collectively termed as IBMPFD, was first linked to the valosin-containing protein (VCP) gene in chromosome 9p13.3–12.<sup>4</sup> Since then, several other genes, including heterogeneous nuclear ribonucleoprotein A2B1 and A1 (*hnRNPA2B1*, *hnRNPA1*), sequestosome 1 (*SQSTM1*), matrin 3 (*MATR3*), T-cell restricted intracellular antigen 1 (*TIA1*), and optineurin (*OPTN*) have been implicated in MSP.<sup>3,5–15</sup> However, various missense mutations in VCP remain the most common etiology of MSP.<sup>1,2,8</sup> In this study, we have focused on the myopathy in VCP-associated MSP (termed as VCP myopathy), a multisystem and often disabling neurodegenerative disorder. VCP mutations can lead to a spectrum of other neuromuscular clinical phenotypes, including motor neuron disease and Charcot–Marie–Tooth type 2 (CMT2).<sup>16–21</sup>

VCP is a ubiquitously expressed ATPase, which is a part of the AAA<sup>+</sup> superfamily ATPase and involved in multiple essential cellular processes, including ubiquitin-dependent cellular processes through the ubiquitin–proteasome system (UPS), cell cycle control, and regulation of autophagy.<sup>1,22</sup> Impaired protein degradation and autophagy play a role in VCP-mediated MSP.<sup>1</sup> VCP-associated MSP is a rare disorder with a reported prevalence of 0.66 per million in the United Kingdom.<sup>1,3,23,24</sup> This prevalence, however, is likely to be an underestimate due to the onset in adulthood (which may lead to symptoms being attributed to other conditions), wide clinical variability, and difficulties accessing genetic testing in some populations.<sup>25</sup> There is a lack of awareness among the physicians, there is no standard of care of disease management for VCP myopathy, and no treatment is currently available.<sup>3</sup> This provisional recommendation is a part of the joint effort initiated by Cure VCP Disease Inc. in developing international consensus guidance for the diagnosis and management of VCP-associated MSP.<sup>26</sup>

## Methods

Given the lack of randomized control trials and the rarity of the disease, an evidence-based recommendation for the

management of VCP myopathy is not yet feasible. Cure VCP Disease Inc. initiated an effort to develop consensus summary recommendations for the clinical assessment and management of VCP-associated MSP and summarized standard of care for VCP-associated MSP was published addressing some of the aspects of genetic diagnosis and counseling; the management of myopathy, motor neuron disease, Charcot–Marie–Tooth disease, PDB, and frontotemporal dementia; and the utilization of physical/occupational therapy, exercise, speech/language therapy, supplements, and respiratory care.<sup>27</sup> However, it did not capture the full spectrum of myopathy associated with VCP, which is the most frequently affected system in VCP-associated MSP.

To develop this provisional practice recommendation for VCP myopathy, experts on VCP myopathy, recommended by the Medical Advisory Board of Cure VCP Disease, were invited to participate in this initiative. Twenty-one participants from six countries, including physicians, researchers, geneticist, and disease activists, formed this consensus group focused specifically on the myopathy aspect of VCP-associated MSP. This consensus group's primary aim was to establish provisional recommendations for the diagnosis, management, and monitoring of the VCP myopathy. These participants were surveyed to identify the key topics to include in developing this recommendation. All prior literature on VCP myopathy was reviewed by the corresponding authors; afterward, multiple meetings were arranged to review each topic and generate a specific recommendation, which was agreed upon by all. Furthermore, each participant contributing to the development of this manuscript was included as an author.<sup>27–29</sup>

## Results

### Review of clinical features

Myopathy with limb-girdle distribution of muscle weakness is the most common feature of VCP-associated MSP affecting 90% of the affected individuals. The mean age of onset is 43–46 years.<sup>1,2,30,31</sup> Distribution of muscle weakness almost always involves proximal muscles, and symmetric lower limb weakness is the most common presentation (50% cases).<sup>31</sup> However, initial presentation with distal weakness of the hands and feet is not uncommon.<sup>2,23,31</sup> Affected individuals may experience difficulty raising their arms above the shoulder, foot drop, scapular

winging, and scapulo-peroneal weakness; but facial weakness is unusual (Table 1).<sup>3,23</sup> Muscle involvement can be asymmetric in about 10%–20% cases.<sup>24,31</sup> Patients develop a waddling gait with a lordotic stance, notice difficulty climbing stairs, often lose their balance, and may experience falls.<sup>2</sup> Disease progression is usually slow, but eventually, other limbs and respiratory muscles become affected. Significant muscle atrophy and camptocormia have been reported.<sup>23,24</sup> Many patients become wheelchair dependent with a loss of ambulation in  $13 \pm 7$  years from symptom onset.<sup>2,23</sup>

Early respiratory muscle involvement has not yet been identified in VCP myopathy but dyspnea on exertion, nocturnal hypoventilation, and recurrent respiratory infection have been reported. Furthermore, predicted forced vital capacity (FVC) is usually lower in about 50% of patients.<sup>32</sup>

Cardiac involvement is relatively less common, and only has been reported in less than 10% patients from a large multicenter cohort study.<sup>31</sup> Hypertrophic and dilated cardiomyopathy can be present. Rarely, bundle branch block and atrial fibrillation can also be present. However, autonomic dysfunction has been reported in about 21.4% of patients.<sup>31</sup> [Correction added on 17 April 2023, after first online publication: In the preceding sentence, '67%' was changed to '21.4%'.]

Overall, the phenotype of VCP myopathy is heterogeneous. Severity and rate of progression also can vary. Specific variants in VCP do not correlate well with clinical phenotype, and variations in clinical presentation have been observed even within the same family.<sup>1,31,33</sup> However, patients with the R159C mutation in one family had a later age of onset of myopathy and did not develop PDB.<sup>1,34</sup>

Patients with VCP-associated MSP are commonly misdiagnosed as limb-girdle muscular dystrophy, facioscapulo-humeral muscular dystrophy (FSHD), myofibrillar myopathy, and inherited distal myopathies (tibial muscular dystrophy, and GNE myopathy).<sup>23</sup>

Recommendation: Increased awareness of the varied presentation of VCP myopathy, and the incorporation of VCP in the routinely performed genetic panel for suspected inherited myopathy and muscular dystrophy, are crucial to make a timely and accurate diagnosis. Respiratory problems can be difficult to recognize; therefore, patients would benefit from respiratory specialist care. Similarly, cardiac assessment at baseline and routine follow-up can be beneficial.

## Review of laboratory markers

Creatinine kinase (CK) value can be normal or mildly elevated (usually less than 5 times of upper limit of normal).

**Table 1.** Clinical presentation and diagnostic findings in VCP-associated myopathy.

### Clinical presentation

- Limb-Girdle onset (most common, about 90%) weakness
- Distal onset
- Scapulo-peroneal, axial muscle involvement
- Camptocormia

### Laboratory markers

Creatinine kinase (CK) value normal or mildly elevated (<5 times of upper limit of normal)

### Electromyography (EMG) and nerve conduction studies (NCSs)

- Pure myopathic changes in 33%–47% of cases
- Only neurogenic changes in 12%–21% of cases
- Mixed myopathic and neurogenic changes in about 14%–20% of cases
- Nerve conduction studies normal or show an axonal motor or sensorimotor neuropathy
- Can show a pattern consistent with motor neuron disease in a subset of patients

### Muscle magnetic resonance imaging (MRI)

- Pockets of fatty tissue in the calf muscles, quadriceps and hamstring muscles

### Muscle biopsy

- Variation in fiber size with atrophic and hypertrophic fibers, and type 1 fiber predominance
- Rimmed vacuoles are considered hallmark of disease pathology, but not always present
- TAR DNA-binding protein 43 (TDP-43) positive inclusions can be seen in some fibers

### Evaluation for Paget disease of bone

- Alkaline phosphatase, bone specific alkaline phosphatase, deoxy-pyridinoline, pyridinoline, crosslinked C- (CTX) and N- (NTX) telopeptides of type I collagen for PDB
- Bone scan

### Respiratory involvement

- Dyspnea on exertion, nocturnal hypoventilation, and recurrent respiratory infection can be present
- Predicted forced vital capacity (FVC) is usually lower in about 50% of patients

### Cardiac involvement

- Cardiac involvement has been reported in less than 10% patients. Hypertrophic and dilated cardiomyopathy can be present
- Rarely, bundle branch block and atrial fibrillation can also be present

A large cohort from the United States reported a mean CK level of  $187.4 \pm 161.75$  U/L (range 32–909) (normal range 22–199 IU/L for women, and 22–334 UL/L for men) among all patients with VCP myopathy.<sup>1,35</sup>

Recommendation: The utility of CK as a biomarker of muscle disease appears to be limited; however, a higher CK level maybe an early indicator of muscle pathology.<sup>1</sup>

## Review of electromyography (EMG) and nerve conduction studies (NCSs)

Two studies with large cohorts ( $n = 138$  from the United States, and  $n = 182$  from a multicenter study) reported extensively on the NCSs and EMG pattern in VCP myopathy.<sup>1,30,31</sup> Needle EMG showed pure myopathic changes in 33%–47% of the patients, only neurogenic changes in 12%–21% cases, and mixed myopathic and neurogenic changes in about 14%–20% cases (Table 1).<sup>1,30</sup> Whereas, a study from a small Asian cohort only found neurogenic changes.<sup>23</sup> Fibrillation potentials, which can represent either ongoing denervation or muscle membrane irritation, have been reported in several studies, particularly in the proximal muscles.<sup>36,37</sup> Some studies reported myotonia in the proximal and axial muscles.<sup>36</sup> Motor neurons or their axons can also be involved.<sup>16</sup> Occasionally, needle EMG can also be normal, possibly in the early stage of the disease.<sup>31</sup> NCSs can be normal or show an axonal motor or sensorimotor neuropathy in some cases.<sup>30,36</sup> Demyelinating features are rare, and only has been reported in <2% of cases.<sup>31</sup>

Recommendation: EMG/NCS does not directly help in making the diagnosis or assessing disease severity. However, mixed myopathic and neurogenic changes, albeit nonspecific, in patients with predominant limb-girdle weakness, can be suggestive of VCP myopathy in the appropriate clinical context. Similarly, it can help to rule out other disease mimics, and help in identifying a subgroup of patients with motor neuron disease phenotype (~10%).

## Review of muscle magnetic resonance imaging (MRI)

While muscle MRI is increasingly being used in the neuromuscular world, only limited data on muscle MRI is available in patients with VCP myopathy. Muscle MRI show pockets of fatty tissue most prominently in the calf muscles, and in quadriceps and hamstring muscles (Table 1, Fig. 1B–D).<sup>23,38</sup> In some isolated muscles, short T1 inversion recovery (STIR) can show increased signal possibly suggesting muscle edema.<sup>38</sup>

Recommendation: At present, there is not enough data to comment on the utility of MRI as a disease biomarker of VCP myopathy. Similarly, it is not clear which muscle groups should be imaged. However, most patients with VCP myopathy have limb-girdle myopathy, and bilateral proximal lower extremity imaging is easier to perform. Furthermore, a recent study showed that changes in proximal lower extremity muscles can help differentiate between different myopathies. Imaging of

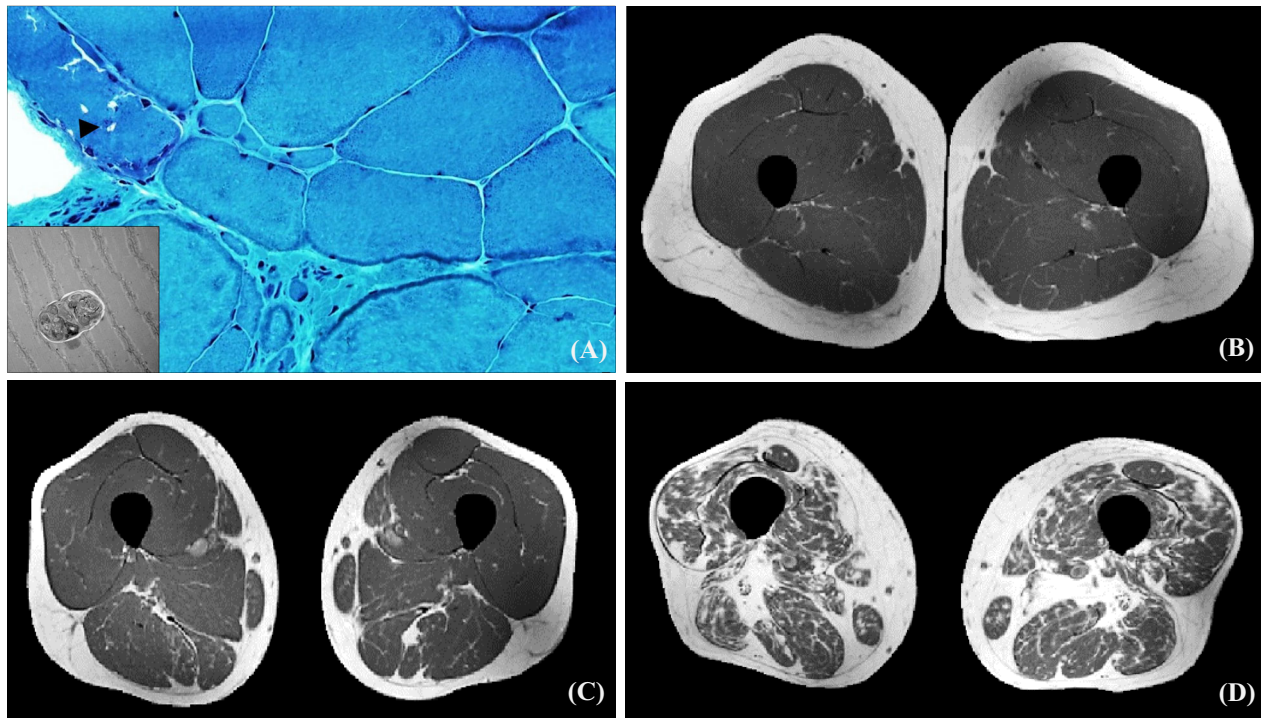
proximal lower extremity muscles can be considered in VCP myopathy.<sup>39</sup> Identification of a pattern of muscle involvement can be helpful in narrowing the differential diagnosis.

## Review of muscle biopsy

Muscle biopsy in VCP myopathy generally shows nonspecific changes with variation in fiber size, atrophic and hypertrophic fibers, and type 1 fiber predominance. Both myopathic and neuropathic changes have been reported.<sup>2,23</sup> Findings in myofibers, including rimmed vacuoles and cytoplasmic ubiquitin and TAR DNA-binding protein 43 (TDP-43) positive inclusions, characteristic of inclusion body myopathy, can be seen in 40% of individuals (Fig. 1A).<sup>2,6</sup> Rimmed vacuoles are considered a hallmark of disease pathology, but it is not always present and can be seen in other inherited muscle diseases.<sup>6,24,40</sup> Inflammation is usually absent; however, MHC1 (myosin heavy chain 1) up-regulation and minor inflammatory infiltrates have been reported from a small cohort.<sup>23</sup> Cytochrome c oxidase staining has shown COX deficient fibers in some cases from an Asian cohort.<sup>23</sup> In advanced cases, degenerative changes and fatty replacement are noted.<sup>2</sup> Under electron microscopy, randomly oriented 15–21 nm diameter tubulofilaments inclusions can be seen in muscle nuclei and cytoplasm.<sup>2</sup>

Recommendation: Muscle biopsy may suggest the diagnosis of VCP-associated MSP, however genetic testing is necessary for confirmation of the diagnosis. Even though genetic testing is readily available in many regions, and VCP is included in several genetic panels of myopathy, amyotrophic lateral sclerosis, dementia, and other neuromuscular and neurodegenerative phenotypes, there are several clinical situations where muscle biopsy is still considered an important investigation. When genetic testing reveals variants of uncertain significance (VUS), muscle biopsy can provide evidence in support of the diagnosis when the characteristic myopathologic findings are present. Due to the late age of onset of VCP myopathy, many patients may initially be suspected of having an acquired myopathy. In this situation, a muscle biopsy may precede genetic testing in order to differentiate cases as being inflammatory, toxic, degenerative, or genetic. Furthermore, muscle biopsy may be a more accessible investigation in some regions if access to genetic testing is limited (due to lack of resources or other factors). Finally, muscle biopsy may even have utility in patients with confirmed diagnoses of VCP myopathy if unexpected clinical change occurs and there is suspicion of a comorbid muscle disease that would affect clinical management (e.g., inflammatory or toxic myopathy).





**Figure 1.** (A) Muscle biopsy of right vastus lateralis showing fiber size variability and rimmed vacuole (black arrowhead, Gomori trichrome stain, inset: electron microscopy showing inclusions inside a rimmed vacuole). (B–D) T1-weighted muscle MRI of a healthy control (B), and patients with VCP myopathy with mild (C) and severe (D) muscle involvement with pockets of fatty infiltration, and muscle atrophy (D).

### Review of follow-up and treatment

There is no approved therapy for myopathy in patients with VCP-associated MSP, and the management is supportive. There is no proven benefit of any supplements.<sup>2,3</sup> Several agents targeting the autophagy and VCP inhibition have shown some promise in preclinical studies.<sup>41–43</sup> One questionnaire-based study has suggested beneficial effect of exercise and higher fat/sugar diet in VCP myopathy; however, these findings need to be confirmed by larger clinical trials.<sup>44</sup> Affected individuals also may need mechanical and mobility aids, or surgical intervention for orthopedic complications.<sup>2</sup>

PDB is the second most common clinical feature and depending on the underlying mutation can be present in 18%–44% of patients. Screening consists of bone scans of areas that are suspicious for lesions. The majority of patients (~77%) with PDB have bone lesions on radiography and bone pain is common (~48%). Serum alkaline phosphatase is elevated in about 55% patients.<sup>27,31</sup> A referral to an endocrinologist should be considered if evidence of PDB is present.<sup>27</sup>

Frontotemporal dementia and mixed cognitive impairment are the common patterns of cognitive impairment. A cognitive screening should be a part of the assessment,

and appropriate cognitive management from a specialist is recommended.<sup>27,31</sup>

Given the multisystem involvement, a multispecialty care approach should be provided, including a neuromuscular neurologist, physical therapist, respiratory therapist, speech pathologist, genetic counselor, and other specialists as indicated such as a pain specialist, cardiologist, and may involve care from other medical/surgical and allied health specialists, such as a palliative care specialist.<sup>26</sup> Multidisciplinary care in VCP myopathy should be considered a standard of care to improve quality of care and survival, as has been demonstrated in other progressive neuromuscular disorders such as amyotrophic lateral sclerosis (ALS).<sup>45</sup>

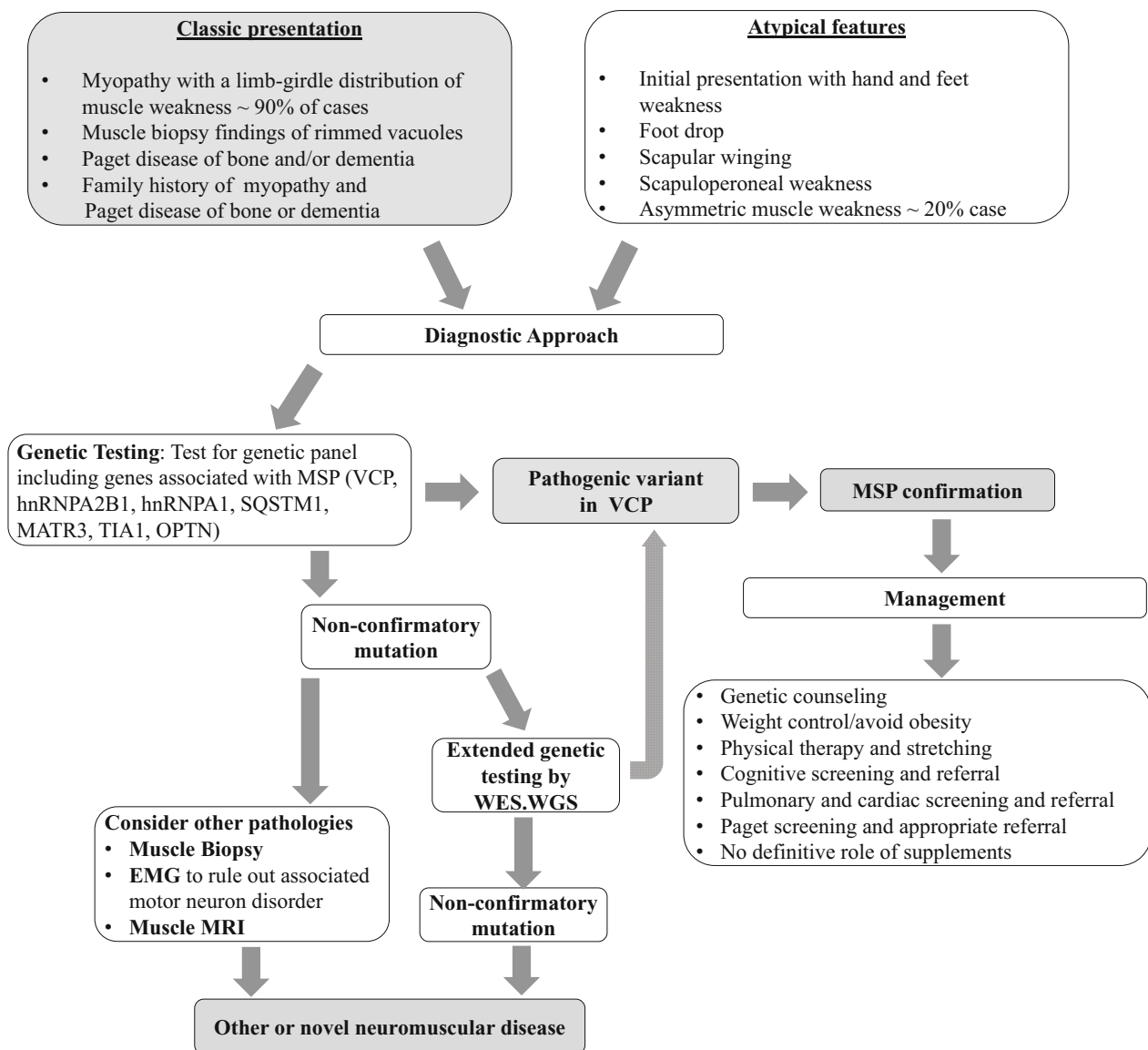
### Discussion

Myopathy, the most common clinical presentation of VCP-associated MSP, has a heterogeneous phenotype, with nonspecific changes in EMG/NCSS, muscle MRI and muscle biopsy findings.<sup>2,3,23</sup> Increased awareness about VCP myopathy is essential to recognize this complex multisystem disease and to avoid misdiagnosis. EMG/NCSS, muscle MRI are helpful in the diagnostic workup, but confirmation through genetic testing is warranted.

Given the wide clinical and genetic spectrum associated with MSPs, we recommend multi-gene panel testing (including *VCP*, *hmRNPA2B1*, *hmRNPA1*, *SQSTM1*, *MATR3*, *TIA1*, *OPTN*) to confirm the diagnosis in undifferentiated cases.<sup>25</sup> In patients with a known pathogenic familial variant, single variant testing is sufficient, unless atypical clinical features are present that could be explained by a dual diagnosis.<sup>2</sup> Genetic counseling is indicated prior to testing in pre-symptomatic individuals.<sup>46</sup>

The present literature has described well the clinical presentation of myopathy in VCP-associated MSP, and the associated clinical syndromes, including ALS and CMT2. However, the heterogeneous presentation and phenotypic variability even within families makes it

particularly challenging for clinicians. Electrodiagnostic studies can show mixed neurogenic and myopathic features, and a sub-population of patients with motor neuron disease phenotype can further add to the diagnostic dilemma. Differences in opinion among physicians regarding the diagnosis based on clinical presentation and electrodiagnostic studies would not be surprising. A detailed family history focused not only on a history of weakness but also on non-motor manifestations such as dementia, Parkinson’s disease, neuropathy, and Paget’s disease of the bone should be assessed in patients with unexplained late onset muscle disease, and the diagnosis should be confirmed by genetic testing as previously explained (Fig. 2).



**Figure 2.** A flowchart for diagnosis and management of VCP-associated myopathy.

Despite expanding literature on the varied clinical phenotypes of VCP, there remains a knowledge gap regarding predictors of disease severity and disease progression. There is an unmet need for long-term follow-up data to better understand the natural history of the disease. At present, there are multiple efforts in utilizing international patient registries and outcome measures for patients with VCP-associated MSP.<sup>26,47</sup> The Cure VCP Disease CoRDS patient registry includes all common data elements published by the Office of Rare Disease Research.<sup>48</sup> A broader use of the patient registry would increase patient identification and expand patient experience data. One limitation is that the web version of the patient registry is only available in English, and a paper version is available in Spanish. Multilingual translations of questionnaires will be essential when they are to be used in an international platform. Additionally, outcome measures for VCP myopathy would need to be validated before being used in clinical trials. One cross-sectional study has examined the utility of inclusion body myositis-functional rating scale (IBM-FRS) score, 6-min walk test (6MWT) distance, fatigue severity scale (FSS), along with detailed motor function assessment.<sup>49</sup> IBM-FRS, 6MWT, and FSS were able to differentiate between affected individuals and controls. Moreover, IBM-FRS and 6MWT showed a strong correlation with muscle strength measured by total MRC scale score (Pearson  $r > 0.7$ ,  $p$ -value  $< 0.001$ ).<sup>49</sup> An ongoing study is evaluating a battery of neuromuscular outcome measures, including the 100-m timed test, Timed Up and Go, Performance of Upper Limb (PUL) 2.0, North Star Assessment for Dysferlinopathy (NSAD), IBM-FRS, and manual muscle testing, to capture disease progression in VCP myopathy over a 12-month period.<sup>50</sup> The results of the outcome measures study and additional natural history studies will be essential to develop robust clinical outcome measurements for patients with VCP-associated MSP.

While both EMG/NCS and MRI help make the diagnosis of VCP myopathy, there are many unanswered questions. Several studies in other myopathies and muscular dystrophies have shown that quantitative muscle imaging with MRI or neuromuscular ultrasound can be a biomarker of muscle health, but such studies are lacking in VCP myopathy.<sup>51–54</sup> Quantitative imaging potentially can be an objective measure of the disease severity and progression of VCP myopathy. Imaging can be more effective in examining the impact of an intervention.<sup>53</sup> No data exists on which muscle groups should be assessed by muscle MRI. Whole-body MRI is a new approach in neuromuscular diseases which is increasingly being used to determine the pattern of muscle involvement and characterize disease progression. However, data is not available on the utility of MRI in VCP myopathy.<sup>55,56</sup>

One of the major limitations of this work is that we only could provide a provisional practice recommendation, and we are unable to provide a concrete consensus practice guidance based on a more explicit structured process including a modified Delphi process.<sup>29</sup> However, VCP myopathy is rare, a relatively recently recognized entity, and available literature is limited. Such rigorous methods of developing a guideline were not practical at this time due to insufficient published clinical data and natural history studies. As research in VCP myopathy is gaining more momentum, and clinical trials are expected in near future, a more methodical approach can be considered in the upcoming future to further update this provisional recommendation.

At present, there is no approved therapy for VCP myopathy, but research is ongoing. Several preclinical studies have shown promise, which are expected to lead to clinical trials in the near future. Effect of diet/supplements and exercise also need to be examined in larger clinical trials.<sup>57</sup> With the increasing awareness of VCP-associated MSP, and easy availability of genetic testing, more patients will likely be diagnosed with VCP-associated MSP. Standardizing the management of VCP-associated MSP, based on international collaboration and expert consensus, will optimize patient care and help future research initiatives for this rare and complex disorder.

## Summary of Recommendations

- VCP myopathy should be considered in patients with limb-girdle muscular dystrophy phenotype, or any myopathy with an autosomal dominant pattern of inheritance.
- VCP myopathy can have a heterogeneous clinical phenotype but should be considered in patients with concomitant Paget disease of bone and/or frontotemporal dementia and/or ALS or with family history of these conditions.
- Initial evaluation with molecular testing for panels of genes including the genes associated with MSPs (*VCP*, *hNRNPA2B1*, *hNRNPA1*, *SQSTM1*, *MATR3*, *TIA1*, *OPTN*) is recommended.
- EMG/NCSs is recommended to rule out other disease mimics and associated motor neuron disorder.
- Muscle biopsy alone cannot be utilized to confirm the diagnosis since only 40% of individuals have characteristic features (rimmed vacuoles), however can be helpful in selected cases when variants of uncertain significance are identified on genetic testing.
- Role of muscle MRI in VCP myopathy is not well studied but may help identify the pattern of muscle involvement.



- Assessment of respiratory, cardiac, and baseline cognitive function is recommended, and these should be repeated if new symptoms develop, or warranted by the initial findings as guided by the respective experts.
- Weight control, physical therapy, respiratory training, and stretching can be beneficial. There is no proven benefit of any supplements.

## Author Contributions

Bhaskar Roy and Virginia Kimonis conceptualized the study, reviewed the literature, and developed the manuscript. All other authors critically contributed to the manuscript writing.

## Acknowledgments

This research received no specific funding from any funding agency in the public, commercial, or not-for profit sectors.

## Conflict of Interest

Bhaskar Roy has served as a consultant for Alexion Pharmaceuticals, now part of AstraZeneca, Takeda Pharmaceuticals and Argenx. No direct conflicts related to this work. Allison Peck, Teresinha Evangelista, Gerald Pfeffer, Leo Wang, Hani Kushlaf, Rocio-Nur Villar-Quiles, Johanna Palmio, Virginia Kimonis does not have any conflicts of interest to disclose. Jordi Diaz-Manera has served on advisory boards for Sanofi-Genzyme, Sarepta, Amicus, Lupin, Astellas and Jansen. He has received payments for presenting in conferences by Sanofi-Genzyme, Amicus and Sarepta. He has received funding for research by Spark, Sanofi-Genzyme and Boehringer-Ingelheim. Manisha Korb has served on advisory boards and the speakers bureau for Biogen. Matthew Wicklund, MD has no conflicts as relates to this manuscript; Unrelated to this manuscript: Research funding from Alexion, Edgewise, Acceleron, Avidity, Orphazyme, Sarepta, ML Bio, Roche, Avidity, Harmony; Served on advisory boards for Amicus, Edgewise, ML Bio, Sanofi-Genzyme, Sarepta, Spark; No employment for or stock in any pharmaceutical company Margherita Milone has received research support from the Neurology Department and Center for Clinical and Translational Science, care center grant award from the Muscular Dystrophy Association (MDA 497263), and compensation to serve as associate editor of Neurology Genetics. Miriam Freimer has served on the advisory boards for UCB, Argenx, Alexion, CSL Behring, Takeda. Dr. Freimer receives research support from Amicus, Orphazyme, Catalyst, Fulcrum, Ionis, Momenta,

Roche, UCB. Merrilee Needham has received honoraria for participation in educational events and Advisory Boards for Biogen, Roche, Sanofi-Aventis and Abucuro. None of these were related to this Manuscript. Thomas E. Lloyd has received consulting fees or research support from Aavogen, Abata Therapeutics, Abucuro, Acceleron, DrenBio, EMD Serano, Kezar Life Sciences, Ono Pharma, Orphazyme, Pharnext, Regenecy, Sarepta, and Takeda. Benison Keung: No direct conflict of interest related to this study. Conrad Chris Wehl has served on advisory boards for Acceleron, Sarepta, Abata, and Orphazyme, and as a consultant for Sarepta. Tahseen Mozaffar has served in an advisory capacity for Abbvie, Alexion, Amicus, Argenx, Audentes, Maze Therapeutics, Modis, Momenta, Ra Pharmaceuticals, Sanofi-Genzyme, Sarepta, Spark Therapeutics, UCB, and Ultragenyx. He serves on the speaker's bureau for Sanofi-Genzyme. Dr. Mozaffar serves on the medical advisory board for the Myositis Association, Neuromuscular Disease Foundation, Myasthenia Gravis Foundation of California and Myasthenia Gravis Foundation of America. Dr. Mozaffar receives research funding from the Myositis Association, the Muscular Dystrophy Association, the National Institutes for Health and from the following sponsors: Alexion, Amicus, Argenx, Audentes, Bristol-Myers-Squibb, Cartesian Therapeutics, Grifols, Momenta, Ra Pharmaceuticals, Sanofi-Genzyme, Spark Therapeutics, UCB, and Valerion. He serves on the data safety monitoring board for Acceleron, Avexis, Sarepta, and the NIH.

## References

1. Al-Obeidi E, Al-Tahan S, Surampalli A, et al. Genotype-phenotype study in patients with valosin-containing protein mutations associated with multisystem proteinopathy. *Clin Genet*. 2018;93(1):119-125.
2. Kimonis V. Inclusion body myopathy with Paget disease of bone and/or frontotemporal dementia. In: Adam MP, Ardinger HH, Pagon RA, et al. eds. *GeneReviews*((R)). University of Washington; 1993-2023.
3. Korb MK, Kimonis VE, Mozaffar T. Multisystem proteinopathy: where myopathy and motor neuron disease converge. *Muscle Nerve*. 2020;63(4):442-454.
4. Watts GDJ, Wymer J, Kovach MJ, et al. Inclusion body myopathy associated with Paget disease of bone and frontotemporal dementia is caused by mutant valosin-containing protein. *Nat Genet*. 2004;36(4):377-381.
5. Salajegheh M, Pinkus JL, Taylor JP, et al. Sarcoplasmic redistribution of nuclear Tdp-43 in inclusion body myositis. *Muscle Nerve*. 2009;40(1):19-31.
6. Wehl CC, Temiz P, Miller SE, et al. TDP-43 accumulation in inclusion body myopathy muscle suggests a common pathogenic mechanism with frontotemporal dementia. *J Neurol Neurosur Psychiatry*. 2008;79(10):1186-1189.

7. Kim HJ, Kim NC, Wang YD, et al. Mutations in prion-like domains in hnRNPA2B1 and hnRNPA1 cause multisystem proteinopathy and ALS. *Nature*. 2013;495(7442):467-473.
8. Le Ber I, Van Bortel I, Nicolas G, et al. hnRNPA2B1 and hnRNPA1 mutations are rare in patients with “multisystem proteinopathy” and frontotemporal lobar degeneration phenotypes. *Neurobiol Aging*. 2014;35(4):934.e5-6.
9. Naruse H, Ishiura H, Mitsui J, et al. Molecular epidemiological study of familial amyotrophic lateral sclerosis in Japanese population by whole-exome sequencing and identification of novel HNRNPA1 mutation. *Neurobiol Aging*. 2018;61:255 e259-255 e216.
10. Qi X, Pang Q, Wang J, et al. Familial early-onset Paget’s disease of bone associated with a novel hnRNPA2B1 mutation. *Calcif Tissue Int*. 2017;101(2):159-169.
11. Bucelli RC, Arhzaouy K, Pestronk A, et al. SQSTM1 splice site mutation in distal myopathy with rimmed vacuoles. *Neurology*. 2015;85(8):665-674.
12. Fecto F, Yan J, Vemula SP, et al. SQSTM1 mutations in familial and sporadic amyotrophic lateral sclerosis. *Arch Neurol*. 2011;68(11):1440-1446.
13. Hocking LJ, Lucas GJ, Daroszewska A, et al. Domain-specific mutations in sequestosome 1 (SQSTM1) cause familial and sporadic Paget’s disease. *Hum Mol Genet*. 2002;11(22):2735-2739.
14. Johnson JO, Pioro EP, Boehringer A, et al. Mutations in the Matrin 3 gene cause familial amyotrophic lateral sclerosis. *Nat Neurosci*. 2014;17(5):664-666.
15. Taylor JP. Multisystem proteinopathy intersecting genetics in muscle, bone, and brain degeneration. *Neurology*. 2015;85(8):658-660.
16. Benatar M, Wu J, Fernandez C, et al. Motor neuron involvement in multisystem proteinopathy: implications for ALS. *Neurology*. 2013;80(20):1874-1880.
17. Gonzalez MA, Feely SM, Speziani F, et al. A novel mutation in VCP causes Charcot-Marie-tooth type 2 disease. *Brain*. 2014;137(Pt 11):2897-2902.
18. Johnson JO, Mandrioli J, Benatar M, et al. Exome sequencing reveals VCP mutations as a cause of familial ALS. *Neuron*. 2010;68(5):857-864.
19. Gite J, Milko E, Brady L, Baker SK. Phenotypic convergence in Charcot-Marie-tooth 2Y with novel VCP mutation. *Neuromuscul Disord*. 2020;30(3):232-235.
20. Kimonis VE, Watts GD. Autosomal dominant inclusion body myopathy, Paget disease of bone, and frontotemporal dementia. *Alzheimer Dis Assoc Disord*. 2005;19(Suppl 1):S44-S47.
21. van de Warrenburg BP, Schouten MI, de Bot ST, et al. Clinical exome sequencing for cerebellar ataxia and spastic paraplegia uncovers novel gene-disease associations and unanticipated rare disorders. *Eur J Hum Genet*. 2016;24(10):1460-1466.
22. Ogura T, Wilkinson AJ. AAA(+) superfamily ATPases: common structure-diverse function. *Genes Cells*. 2001;6(7):575-597.
23. Evangelista T, Wehl CC, Kimonis V, Lochmuller H, VCP related diseases Consortium. 215th ENMC international workshop VCP-related multi-system proteinopathy (IBMPPD) 13-15 November 2015, Heemskerk, The Netherlands. *Neuromuscular Disord*. 2016;26(8):535-547.
24. Figueroa-Bonaparte S, Hudson J, Barresi R, et al. Mutational spectrum and phenotypic variability of VCP-related neurological disease in the UK. *J Neurol Neurosurg Psychiatry*. 2016;87(6):680-681.
25. Pfeffer G, Lee G, Pontifex CS, et al. Multisystem proteinopathy due to VCP mutations: a review of clinical heterogeneity and genetic diagnosis. *Genes (Basel)*. 2022;13(6):963.
26. CUREVCP patient registry. Accessed March 30, 2021. <https://www.curevcp.org/patient-registry>
27. Korb M, Peck A, Alfano LN, et al. Development of a standard of care for patients with valosin-containing protein associated multisystem proteinopathy. *Orphanet J Rare Dis*. 2022;17(1):23.
28. Fitch K, Bernstein SJ, Aguilar MD, et al. The Rand/UCLA Appropriateness Method User’s Manual. RAND; 2001.
29. Guideline Development Process Manual [Press Release]. American Academy of Neurology; 2011.
30. Mehta SG, Khare M, Ramani R, et al. Genotype-phenotype studies of VCP-associated inclusion body myopathy with Paget disease of bone and/or frontotemporal dementia. *Clin Genet*. 2013;83(5):422-431.
31. Schiava M, Ikenaga C, Villar-Quiles RN, et al. Genotype-phenotype correlations in valosin-containing protein disease: a retrospective multicentre study. *J Neurol Neurosurg Psychiatry*. 2022;93:1099-1111.
32. Pfeffer G, Povitz M. Respiratory management of patients with neuromuscular disease: current perspectives. *Degener Neurol Neuromuscul Dis*. 2016;6:111-118.
33. Abrahao A, Neto OA, Kok F, et al. One family, one gene and three phenotypes: a novel VCP (valosin-containing protein) mutation associated with myopathy with rimmed vacuoles, amyotrophic lateral sclerosis and frontotemporal dementia. *J Neurol Sci*. 2016;368:352-358.
34. Chan N, Le C, Shieh P, et al. Valosin-containing protein mutation and Parkinson’s disease. *Parkinsonism Relat Disord*. 2012;18(1):107-109.
35. George MD, McGill NK, Baker JF. Creatine kinase in the U.S. population: impact of demographics, comorbidities, and body composition on the normal range. *Medicine (Baltimore)*. 2016;95(33):e4344.
36. Kazamel M, Sorenson EJ, McEvoy KM, et al. Clinical spectrum of valosin containing protein (VCP)-opathy. *Muscle Nerve*. 2016;54(1):94-99.
37. Kovach MJ, Waggoner B, Leal SM, et al. Clinical delineation and localization to chromosome 9p13.3-p12 of

- a unique dominant disorder in four families: hereditary inclusion body myopathy, Paget disease of bone, and frontotemporal dementia. *Mol Genet Metab.* 2001;74(4):458-475.
38. Diaz-Manera J, Llauger J, Gallardo E, Illa I. Muscle MRI in muscular dystrophies. *Acta Myol.* 2015;34(2-3):95-108.
  39. Verdu-Diaz J, Alonso-Perez J, Nunez-Peralta C, et al. Accuracy of a machine learning muscle MRI-based tool for the diagnosis of muscular dystrophies. *Neurology.* 2020;94(10):e1094-e1102.
  40. Wehl CC. Sporadic inclusion body myositis and other rimmed vacuolar myopathies. *Continuum (Minneapolis Minn).* 2019;25(6):1586-1598.
  41. Llewellyn KJ, Nalbandian A, Weiss LN, et al. Myogenic differentiation of VCP disease-induced pluripotent stem cells: a novel platform for drug discovery. *PLoS One.* 2017;12(6):e0176919.
  42. Wang B, Maxwell BA, Joo JH, et al. ULK1 and ULK2 regulate stress granule disassembly through phosphorylation and activation of VCP/p97. *Mol Cell.* 2019;74(4):742-757 e748.
  43. Zhang T, Mishra P, Hay BA, Chan D, Guo M. Valosin-containing protein (VCP/p97) inhibitors relieve mitofusin-dependent mitochondrial defects due to VCP disease mutants. *eLife.* 2017;6:e17834.
  44. Hamorsky K, Surampalli A, Wencel M, Khare M, Kimonis V. The influence of diet and exercise on the physical health of affected individuals with VCP disease. *Int J Biotechnol Wellness Ind.* 2014;3(2):46-52.
  45. Rooney J, Byrne S, Heverin M, et al. A multidisciplinary clinic approach improves survival in ALS: a comparative study of ALS in Ireland and Northern Ireland. *J Neurol Neurosurg Psychiatry.* 2015;86(5):496-501.
  46. Surampalli A, Khare M, Kubrussi G, et al. Psychological impact of predictive genetic testing in VCP inclusion body myopathy, Paget disease of bone and frontotemporal dementia. *J Genet Couns.* 2015;24(5):842-850.
  47. Ikenaga C, Findlay AR, Seiffert M, et al. Phenotypic diversity in an international cure VCP disease registry. *Orphanet J Rare Dis.* 2020;15(1):267.
  48. Rubinstein YR, McInnes P. NIH/NCATS/GRDR(R) common data elements: a leading force for standardized data collection. *Contemp Clin Trials.* 2015;42:78-80.
  49. Plewa J, Surampalli A, Wencel M, et al. A cross-sectional analysis of clinical evaluation in 35 individuals with mutations of the valosin-containing protein gene. *Neuromuscul Disord.* 2018;28(9):778-786.
  50. Johnson MA, Klickstein JA, Khanna R, Gou Y, Cure VCP Disease Research Consortium, Raman M. The Cure VCP Scientific Conference 2021: molecular and clinical insights into neurodegeneration and myopathy linked to multisystem proteinopathy-1 (MSP-1). *Neurobiol Dis.* 2022;169:105722.
  51. Morrow JM, Sinclair CD, Fischmann A, et al. MRI biomarker assessment of neuromuscular disease progression: a prospective observational cohort study. *Lancet Neurol.* 2016;15(1):65-77.
  52. Wokke BH, van den Bergen JC, Versluis MJ, et al. Quantitative MRI and strength measurements in the assessment of muscle quality in Duchenne muscular dystrophy. *Neuromuscul Disord.* 2014;24(5):409-416.
  53. Zaidman CM, Wu JS, Kapur K, et al. Quantitative muscle ultrasound detects disease progression in Duchenne muscular dystrophy. *Ann Neurol.* 2017;81(5):633-640.
  54. Fischmann A, Hafner P, Gloor M, et al. Quantitative MRI and loss of free ambulation in Duchenne muscular dystrophy. *J Neurol.* 2013;260(4):969-974.
  55. Caetano AP, Alves P. Advanced MRI patterns of muscle disease in inherited and acquired myopathies: what the radiologist should know. *Semin Musculoskelet Radiol.* 2019;23(3):e82-e106.
  56. Warman Chardon J, Diaz-Manera J, Tasca G, et al. MYO-MRI diagnostic protocols in genetic myopathies. *Neuromuscul Disord.* 2019;29(11):827-841.
  57. Gianola S, Castellini G, Pecoraro V, Monticone M, Banfi G, Moja L. Effect of muscular exercise on patients with muscular dystrophy: a systematic review and meta-analysis of the literature. *Front Neurol.* 2020;11:958.