

UCLA

UCLA Previously Published Works

Title

Optical coherent reflectometry: a new technique to guide invasive procedures.

Permalink

<https://escholarship.org/uc/item/6jr935zr>

Journal

Catheterization and cardiovascular interventions : official journal of the Society for Cardiac Angiography & Interventions, 54(2)

ISSN

1522-1946

Authors

Yamashita, T
Kasaoka, S
Son, R
[et al.](#)

Publication Date

2001-10-01

DOI

10.1002/ccd.1278

License

<https://creativecommons.org/licenses/by/4.0/> 4.0

Peer reviewed

Basic Investigation

Optical Coherent Reflectometry: A New Technique to Guide Invasive Procedures

Takehiro Yamashita,¹ MD, PhD, Shunji Kasaoka,¹ MD, PhD, Rirei Son,¹ MD, Ian L. Gordon,² MD, Rahil Khan,³ MD, John Neet,⁴ Allan D. Hedrick,⁴ and Jonathan M. Tobis,^{1*} MD

The success rate of percutaneous transluminal coronary angioplasty for chronic total arterial occlusions is still unsatisfactory. Inability to cross the lesion with a guidewire is a major cause of failure. Optical coherent reflectometry (OCR) is a new method of using laser light to measure the depth of tissue from the end of an optic fiber. This study tests whether an OCR prototype guidewire provides a guidance system that might be useful to assist reopening chronic total arterial occlusions. An OCR fiber optic within a 0.014" hypotube was developed using the interference pattern of two reflected light beams (wave length 1,300 nm). To determine if OCR can distinguish different tissue types, plaques of human lower extremity arterial segments were visually divided into three types (calcified, white, or yellow). The slope of the initial reflectance of the OCR curve was calculated and compared between the three groups. In six other arteries, the OCR wire was advanced longitudinally through occluded human artery segments *in vitro*. Guidewire position was determined by OCR and compared to the position of the guidewire tip observed simultaneously by intravascular ultrasound (IVUS) imaging. In 16 arterial surface segments, calcified plaques had a significantly steeper slope than white or yellow plaques (-227.2 ± 82.2 ; -81.5 ± 12.9 ; -103.6 ± 19.6 dB/mm; $P < 0.01$). For the determination of the guidewire position, IVUS and OCR corresponded correctly in 82% of 28 measurements. Sensitivity and specificity of OCR for detection of plaque versus the media/adventitia boundary were 79% and 89%, respectively ($P < 0.001$). OCR can distinguish calcified from noncalcified plaque and may distinguish plaque from the media/adventitia boundary. This technology may be useful as a means to help navigate a guidewire safely through an occluded artery. *Cathet Cardiovasc Intervent* 2001;54:257–263. © 2001 Wiley-Liss, Inc.

Key words: optical coherent reflectometry; angioplasty; chronic occlusion; tissue characterization

INTRODUCTION

The success rate of percutaneous transluminal coronary angioplasty (PTCA) for chronic total occlusions is still unsatisfactory. Successful recanalization is achieved in less than 65% of attempted procedures. Inability to cross the lesion with a guidewire is the reason for failure in more than 75% of unsuccessful attempts [1]. To facilitate guidewire crossing, new guidewires have been developed, including a ball-tipped wire [2], the laserwire [3], guidewires with hydrophilic coating [4], and stiff wires with high-torque control (Athlete wire, Asahi Intech, Japan). Except for one study [5], these have failed to improve the success rate significantly. The lack of visualization to navigate safely the guidewire through the occlusion site is a major cause of failure.

To overcome this limitation, a new guidance system has been developed that uses optical coherent reflectom-

¹Division of Cardiology, Department of Medicine, University of California, Irvine, California

²Department of Surgery, Long Beach Veterans Administration Medical Center, California

³Department of Pathology, Long Beach Veterans Administration Medical Center, California

⁴Intra Luminal Therapeutics, Inc., Carlsbad, California

Grant sponsor: National Institutes of Health; Grant number: HL-45077; Grant sponsor: Intra Luminal Therapeutics, Inc.

*Correspondence to: Dr. Jonathan M. Tobis, University of California, Los Angeles, CA 90095

Received 29 January 2001; Revision accepted 25 May 2001

etry (OCR) to steer a guidewire through total occlusions. OCR uses the interference pattern of two light beams and measures the intensity of reflected light from the tissue as a function of depth along a straight line. Due to the variability of backscatter, the intensity of reflected light varies depending on the type of tissue. In addition to distinguishing different tissue characteristics, the reflected backscatter is affected by tissue interfaces such as the plaque/media/adventitia boundaries. These distinctions could be used to provide a guiding system to recanalize chronic total occlusions.

A prototype OCR system was studied to correlate the information from the OCR reflectance curves with tissue characteristics *in vitro* and to interpret the position of the guidewire within an occluded artery as determined by OCR compared with the position in cross-section determined by intravascular ultrasound (IVUS) imaging.

MATERIALS AND METHODS

The OCR system consists of a laser interferometer, a demodulation-computer unit, fiber optic cables, and a light source. For this study, the light source used was a 1,300 nm, near-infrared laser. A schematic of the system is shown in Figure 1. Light from the source is split evenly by an optical fiber splitter that functions as an interferometer for the reflected signal. One of the fibers directs light to the tissue and the other to a moving reference mirror. The distal end of the optical fiber can be placed at the guidewire tip (Fig. 2). By comparing the interference pattern of the two reflected light beams, the interferometer can determine the precise distance from the guidewire tip to the sample. The precision of this system is on the order of 10 microns.

An example of an OCR graph is shown in Figure 3. The vertical axis represents the reflectance in decibels and the horizontal axis corresponds to the tissue depth from the distal guidewire tip in fractions of a millimeter. When light is transmitted into tissue, it is absorbed and scattered, which decreases the intensity of the light reflected back into the fiber optic. Although visible light is strongly absorbed by tissue, near-infrared light is able to penetrate more effectively through tissue. Near-infrared light is scattered by the interaction with tissue and the light is redirected based on the angle of incidence to the tissue. In less structured tissue, scattering appears to be random so that the light is spread in many directions. The percentage of reflected light toward the probe depends on the depth of the reflection point. This causes a fairly uniform decay of the reflected intensity with depth of penetration. There are several variables that change this response, including incident light power, beam divergence from the end of the fiber (numerical aperture), and detector sensitivity. These variables were kept constant

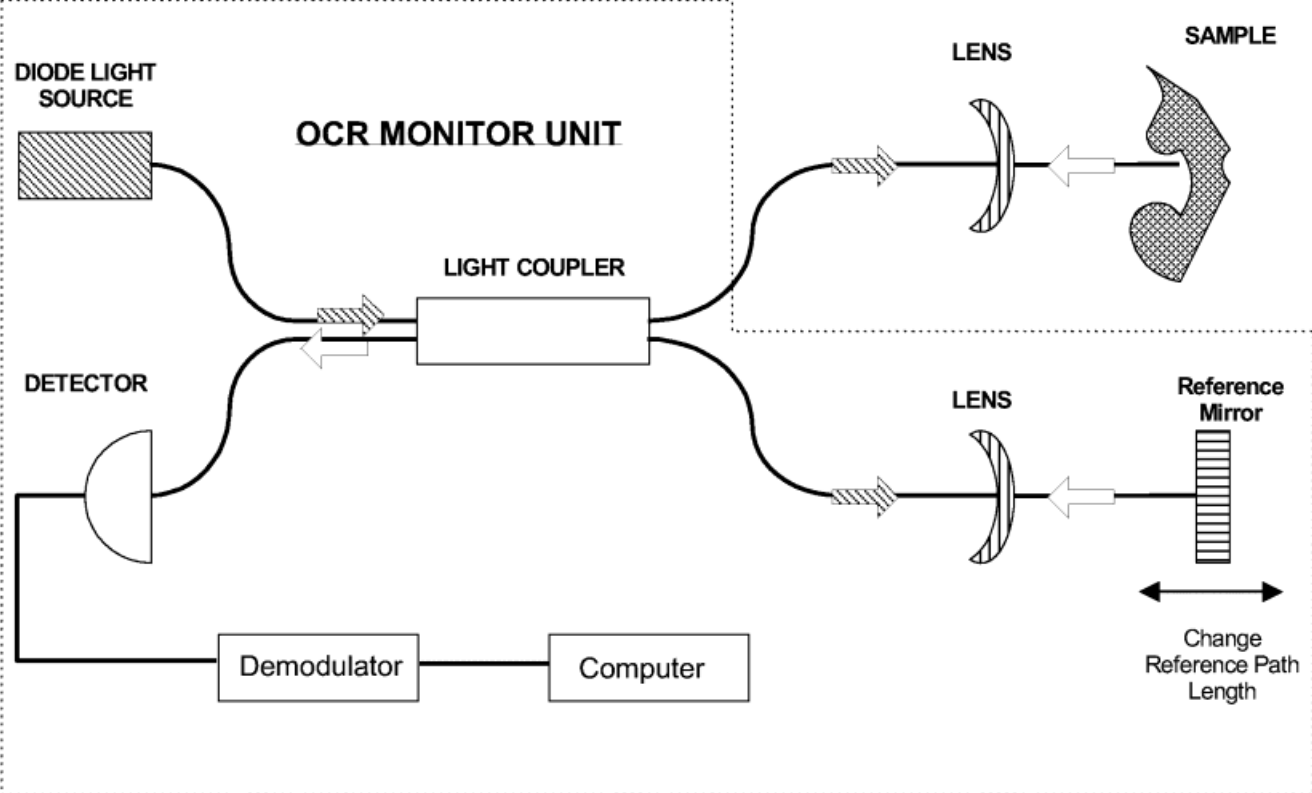
during these experiments. Plaque and arterial wall boundaries (media and adventitia) scatter light differently. Because the wall boundaries are more orderly structures, they scatter light in an anisotropic manner (i.e., not in all directions). This difference in light scattering between plaque and the arterial wall produces a distinct OCR curve: an initial fairly uniform slope of decreased intensity of the reflected light followed by an inflection point corresponding to the boundary of the arterial wall.

Amputated human popliteal or tibial artery segments were used *in vitro* for two sets of experiments. In the first, OCR reflectance graphs were recorded from 16 plaques from two artery segments. The arteries were opened longitudinally and the orientation was established by placing o-silk sutures along the cut edge and at one end of the specimen. Plaques seen on the endoluminal surface of the sample were visually divided into three types: calcified, white, or yellow plaques. The plaque type was later confirmed with histology. The slope of the initial reflectance (between the peak and the first inflection point) was measured and compared between the three groups. The OCR graphs were recorded at intervals of 2–4 mm along a straight line from the sutured points perpendicular to the edge and the distance from the edge was measured. Each specimen was fixed in a standard manner and stained with hematoxylin-eosin and Masson's trichrome. Plaques were histologically divided into three types: calcified, fibrous, or fibrofatty plaques.

In the second set of studies, the OCR wire was advanced longitudinally through occluded human peripheral artery segments *in vitro*. The position of the OCR guidewire tip was interpreted independently from the OCR graphs. If the OCR graph had an inflection point, it was interpreted that the tip was in the plaque next to the plaque/media interface. If the graph had a slope but no inflection point, it was interpreted that the tip had extended beyond the plaque and was in media or adventitia. This OCR interpretation was performed independently and then was compared to the real-time position of the guidewire tip as determined by IVUS cross-sectional imaging (console; Hewlett Packard Sonos; catheter: Sonicath CV 3.5 Fr 30 MHz, Boston Scientific). An IVUS catheter was placed longitudinally within the artery segment from the opposite end of the artery, from which the OCR wire was introduced (Fig. 4). The IVUS catheter was manipulated along the length of the vessel until the tip of the guidewire was visualized. The OCR and IVUS imaging was performed in a saline bath at room temperature. Blood-filled medium was not used because the artery segments were occluded and it was not expected that blood would interfere with the signal due to the direct contact of the wire within the chronic total occlusion.

A

OPTICAL GUIDE WIRE



B



Fig. 1. A: Schematic diagram of the optical coherent reflectometry (OCR) system. The area enclosed with the dotted line represents the components within a console unit. There is only a single fiber that extends from the console that is integrated in the OCR guidewire. B: The console and guidewire control system.

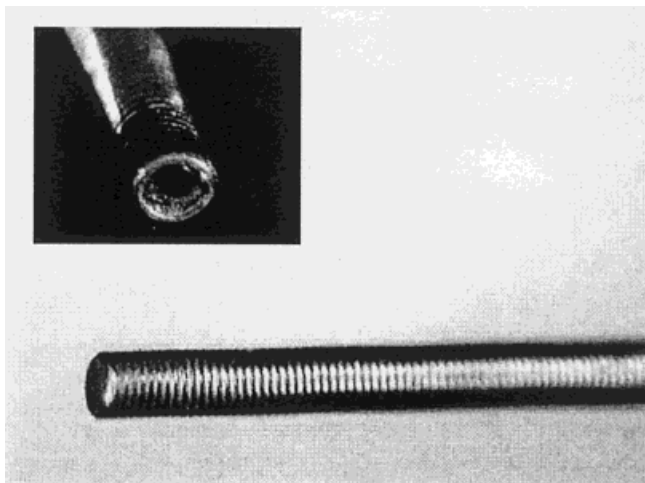


Fig. 2. A magnified photograph of the optical coherent reflectometry wire. The insert shows the wire tip with the fiber optic recessed in the guidewire.

Statistics

Values were expressed as mean \pm standard deviation. Analysis of variance with the Bonferroni posthoc test was used to compare the mean values between groups. Chi-square analysis was used to compare sensitivity and specificity between OCR and IVUS. In these analyses, $P < 0.05$ was considered to be significant.

RESULTS

Comparison of OCR Curve With Plaque Type

Of the 16 plaques, 4 were visually estimated as calcified, 5 as white, and 7 as yellow plaques (Fig. 5). The mean slope was -227.2 ± 82.2 dB/mm for calcified plaque, -81.5 ± 12.9 dB/mm for white plaque, and -103.6 ± 19.6 dB/mm for yellow plaque. Calcified plaques had a significantly steeper slope of the OCR curve than white or yellow plaques ($P < 0.01$). There was no difference in the slope of the OCR curve for white and yellow plaques ($P = 0.39$).

Comparison of OCR Curve With IVUS Position

Twenty-eight positions of the guidewire tip were determined in six arteries (Table I). A 2×2 comparison table was then derived to compare the correspondence between OCR and IVUS. Of the 28 measurements of guidewire position, 19 were diagnosed by IVUS as within plaque; the guidewire was observed in the media or adventitia in 9. OCR diagnosed 16 guidewire positions as within plaque, and 12 were interpreted as being in the media or adventitia. IVUS and OCR correlated in 23 of 28 measurements, for 82% correspondence. The sensi-

tivity of OCR for plaque detection was 79% and the specificity was 89% ($P < 0.001$).

DISCUSSION

A new navigation system could be useful to facilitate guidewire penetration through chronic total occlusions. At the present time, guidance is limited to fluoroscopic imaging. When collaterals are present, simultaneous ipsilateral and contralateral injections may identify the extent of occlusion and clarify if a guidewire has passed successfully into the distal lumen. Intracoronary angioscopy and conventional (side-looking) intravascular ultrasound can delineate the structure of stenotic, nonoccluded lesions; however, these techniques require crossing the lesion with a guidewire prior to imaging. A prototype version of a real-time, forward-looking intravascular ultrasound device was developed [6,7] and reported to be suitable for intracoronary use [8]. The forward-looking ultrasound device produces images of the artery in longitudinal cross-section; however, it is currently too bulky (5 Fr diameter) for use as a guiding device for chronic coronary occlusions. A forward-looking intravascular ultrasound guidewire is being developed; however, signal penetration may be limited and shadowing from calcification impair any ultrasound imaging device. Unlike sound waves, infrared light is less strongly reflected from calcified tissues and thus OCR can obtain valid information even behind calcified tissues. Furthermore, OCR can achieve about 10 times higher resolution than conventional ultrasound imaging [9].

OCR was derived from optical coherent tomography (OCT) technology. OCR provides a reflectance curve, while OCT produces a cross-sectional tomographic image by scanning the light across the subject. The relation between OCR and OCT is similar to that between ultrasound A-mode and two-dimensional imaging. OCT can provide low-power microscopic, cross-sectional tomographic imaging in tissues [10]. OCT was initially introduced to image the transparent tissue of the eye at a level of resolution significantly greater than conventional ultrasound, angiography, or magnetic resonance imaging [10,11]. Recently, OCT has been used to image nontransparent tissue like the aorta [12] or coronary arteries in vitro, but light scattering from blood may make OCT difficult to perform in vivo [13]. Although OCR does not provide an image like OCT, differences in tissue reflectance and miniaturization of the imaging probe to 0.014" diameter enables its use in the field of vascular intervention, especially in occluded arteries where there is no blood flow.

In the past, smart laser concepts have been used to differentiate between plaque and the normal arterial wall. These systems used the principles of laser-induced fluo-

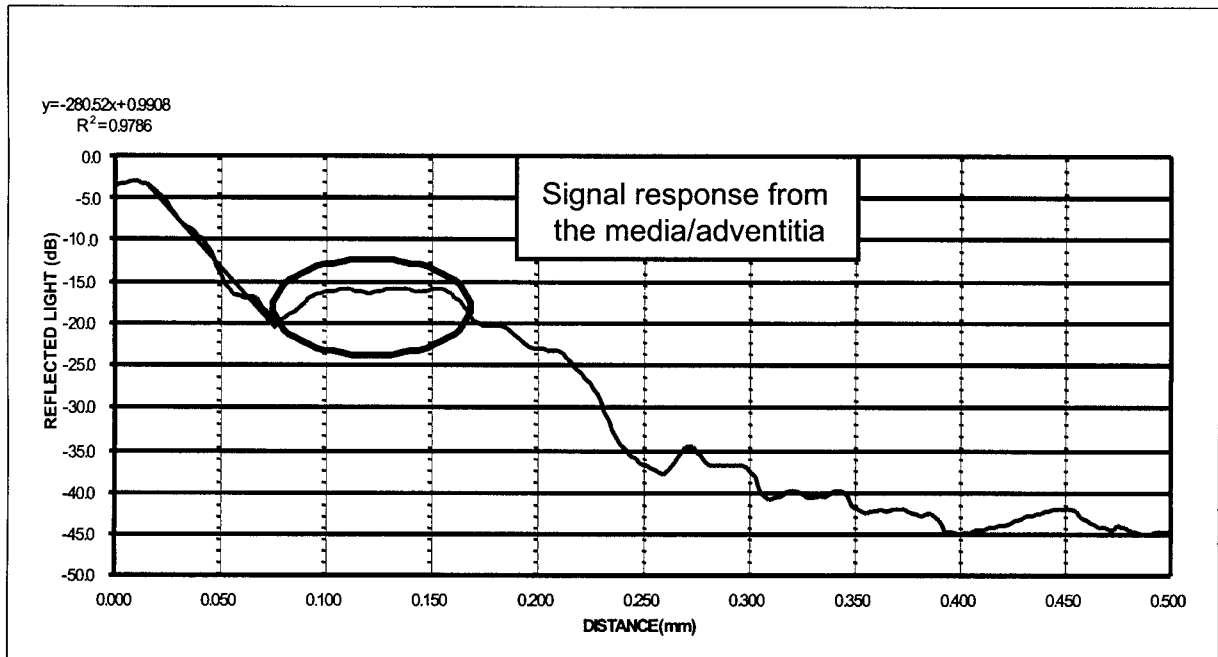


Fig. 3. Example of an optical coherent reflectometry graph. The vertical axis represents the reflectance in decibels and the horizontal axis corresponds to the depth from the distal guidewire tip in fractions of a millimeter. The slope of the initial reflectance was calculated. The circled area represents the inflection point zone or hump.

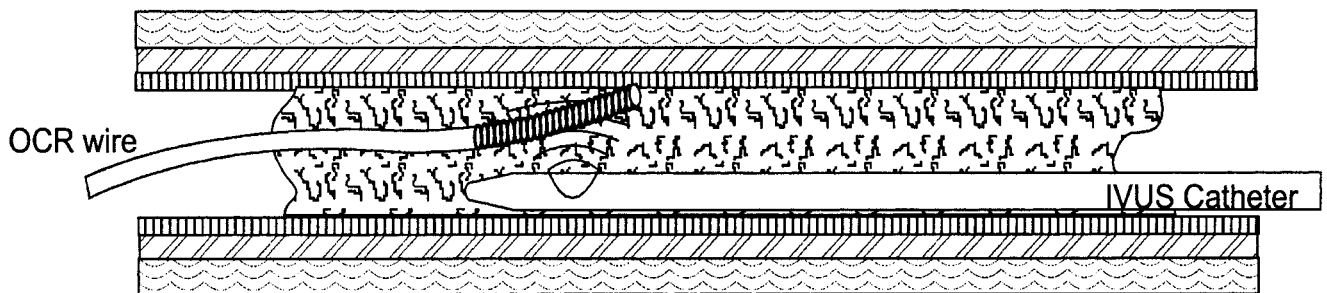


Fig. 4. A schematic representation of the optical coherent reflectometry wire manually passed into an occluded segment of a human peripheral artery. The position of the guidewire tip was imaged in cross-section by an intravascular ultrasound catheter that was placed in the artery from the opposite direction.

rescence, whereby the emitted light from the laser excited material was collected and analyzed by spectroscopy. The emitted light spectra is characteristic of the molecular structure and provides information about chemical composition. Such methods were limited by the ability to collect sufficient quantity of emitted light in vivo to analyze the light spectrum. The chemical nature of atherosclerotic diseased tissues is also complex and the analysis can require interpretation by a skilled spectroscopist to interpret overlaps of spectra and eliminate background effects.

Optical coherence reflectometry is based on imaging concepts rather than molecular composition. It is similar

to ultrasound imaging, but instead of acoustic waves, near-infrared light is used, which penetrates into tissue and is scattered by the composition of tissue and tissue plane interfaces. Interferometry is used to measure the echo time of the backscattered light. An image can be created by plotting the backscatter intensity versus the echo time just like ultrasound imaging. These OCR backscatter data are used to distinguish between plaque and normal arterial wall in a similar manner to the production of an ultrasound image. By using light, however, the imaging modality can be delivered through fiber optics and packaged into an 0.014" guidewire. The much shorter wavelength of near-infrared light (1.3 microns)

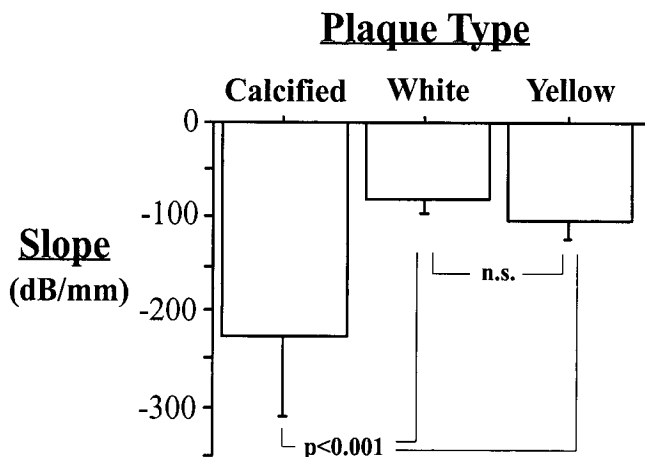


Fig. 5. Comparison of optical coherent reflectometry (OCR) curve with plaque type. The average slopes of calcified, white, and yellow plaques are -227.2 ± 82.2 dB/mm, -81.5 ± 12.9 dB/mm, and -103.6 ± 19.6 dB/mm, respectively.

TABLE I. Correspondence Between Optical Coherent Reflectometry and Intravascular Ultrasound Interpretation*

(n = 28)	OCR		Total
	Plaque	Media or adventitia	
IVUS			
Plaque	15 (79%)	4 (21%)	19
Media or adventitia	1 (11%)	8 (89%)	9
Total	16	12	

*Of the 28 observed positions of the OCR wire tip, 19 were diagnosed in plaque and 9 were in media or adventitia by IVUS. The interpretation of the OCR curve diagnosed 16 wire tip positions as in plaque, and 12 were in media or adventitia.

versus ultrasound (100 microns) improves the resolution of the image.

The results of this in vitro study indicate that OCR can be used to identify calcified tissue from fibrous or fatty plaque. The steeper slope seen with calcified plaque is thought to be due to greater random scattering of the light and therefore less reflection back into the detector.

Our data also suggest that OCR has an ability to delineate the position of the guidewire tip during its manipulation within an occluded artery. In 82% of the observations, OCR distinguished whether the position of the guidewire tip was in plaque or out of plaque compared with the interpretation by IVUS. This analysis assumed that IVUS provided the gold standard for determining the precise position of the guidewire tip. IVUS appears to be the best method to determine the guidewire cross-sectional position in real time; however, this was not confirmed by an independent third method.

Several problems need to be solved before OCR becomes clinically applicable. First, the depth of the mea-

surement is still limited. At the present time, the penetration of OCR is only about 0.5 mm. This may be improved by putting a lens on the guidewire tip. This could increase the depth at least up to 1.0 mm. The optimization of the incident light source wavelength may further improve performance because depth of penetration and distinction between tissues are functions of optical wavelength. Second, blood interferes with reflection of the near-infrared light beam. Although blood strongly absorbs visible light, it has very low absorption in infrared wavelengths. However, optical scattering is high when infrared light passes through blood, which reduces the amount of optical signal that is reflected [12]. Scattering of the signal by blood should not be a significant impediment if the OCR system is used primarily to guide the wire through a chronic total occlusion where the blood field is absent. These hypotheses need to be confirmed with clinical trials. Third, arteries with significant atherosclerotic plaque burden have destruction or thinning of the media underlying the plaque [14,15]. It is unknown whether OCR may distinguish a plaque/adventitia border in a similar manner as the plaque/media boundary. This needs to be clarified with more in vitro histologic comparison studies.

OCR technology is adaptable to place at the end of a 0.014" guidewire. It can distinguish calcified from non-calcified plaque. In addition, the OCR curve inflection may distinguish plaque from the media/adventitia boundary. This technology may be useful as a means to help navigate a guidewire safely through an artery with a chronic total occlusion.

REFERENCES

1. Puma JA, Sketch MHJ, Tchong JE, Harrington RA, Phillips HR, Stack RS, Califf RM. Percutaneous revascularization of chronic coronary occlusions: an overview. *J Am Coll Cardiol* 1995;26:1-11.
2. Meier B, Carlier M, Finci L, Nukta E, Urban P, Niederhauser W, Favre J. Magnum wire for balloon recanalization of chronic total coronary occlusions. *Am J Cardiol* 1989;64:148-154.
3. Sanborn TA, Spokojny AM, Bergman GW, Cohen E, Power J. A 0.018" Excimer Laser guidewire to recanalize chronic total occlusions and guide conventional angioplasty catheters. *Circulation* 1993;88:1504.
4. Freed M, Boatman JE, Siegel N, Safian RD, Grines CL, O'Neill WW. Glidewire treatment of resistant coronary occlusions. *Cathet Cardiovasc Diagn* 1993;30:201-204.
5. Kinoshita I, Katoh O, Nariyama J, Otsuji S, Tateyama H, Kobayashi T, Shibata N, Ishihara T, Ohsawa N. Coronary angioplasty of chronic total occlusions with bridging collateral vessels: immediate and follow-up outcome from a large single-center experience. *J Am Coll Cardiol* 1995;26:409-415.
6. Evans JL, Ng KH, Vonesh MJ, Kramer BL, Meyers SN, Mills TA, Kane BJ, Aldrich WN, Jang YT, Yock PG, Rold MD, Roth SI, McPherson DD. Arterial imaging with a new forward-viewing intravascular ultrasound catheter. I. initial studies. *Circulation* 1994;89:712-717.

7. Ng KH, Evans JL, Vonesh MJ, Meyers SN, Mills TA, Kane BJ, Aldrich WN, Jang YT, Yock PG, Rold MD, Roth SI, McPherson DD. Arterial imaging with a new forward-viewing intravascular ultrasound catheter. II. three-dimensional reconstruction and display of data. *Circulation* 1994;89:718–723.
8. Liang DH, Hu BS. A forward-viewing intravascular ultrasound catheter suitable for intracoronary use. *Biochem Instrument Tech* 1997;31:45–53.
9. Brezinski ME, Tearney GJ, Weissman NJ, Boppart SA, Bouma BE, Hee MR, Weyman AR, Swanson EA, Southern JF, Fujimoto JG. Assessing atherosclerotic plaque morphology: comparison of optical coherence tomography and high frequency intravascular ultrasound. *Heart* 1997;77:397–403.
10. Huan D, Swanson EA, Lin CP, Schuman JS, Stinson WG, Chang W, Hee MR, Flotte T, Gregory K, Puliafito CA, Fujimoto JG. Optical Coherence Tomography. *Science* 1991;254:1178–1181.
11. Hee MR, Izatt JA, Swanson EA, Huang D, Schuman JS, Lin CP, Puliafito CA, Fujimoto JG. Optical coherence tomography of the human retina. *Arch Ophthalmol* 1995;113:325–332.
12. Brezinski ME, Tearney GJ, Bouma BE, Izatt JA, Hee MR, Swanson EA, Southern JF, Fujimoto JG. Optical coherence tomography for optical biopsy: properties and demonstration of vascular pathology. *Circulation* 1996;93:1206–1213.
13. Brezinski ME, Tearney GJ, Bouma BE, Boppart SA, Hee MR, Swanson EA, Southern JF, Fujimoto JG. Imaging of coronary artery microstructure (in vitro) with optical coherence tomography. *Am J Cardiol* 1996;77:92–93.
14. Isner JM, Donaldson RF, Fortin AH, Tischler A, Clarke RH. Attenuation of the media of coronary arteries in advanced atherosclerosis. *Am J Cardiol* 1986;58:937–939.
15. Maheswaran B, Leung CY, Gutfinger DE, Nakamura S, Russo RJ, Hiro T, Tobis JM. Intravascular ultrasound appearance of normal and mildly diseased coronary arteries: correlation with histologic specimens. *Am Heart J* 1995;130:976–986.