Title
Analysis of conventional swept-source OCT of subglottic stenosis in a rabbit model

ISBN
9780819493347

Authors
Hamamoto, Ashley
Su, Erica
Peaks, Ya-Sin
et al.

Publication Date
2013-03-08

DOI
10.1117/12.2014252

Analysis of conventional swept-source OCT of subglottic stenosis in a rabbit model

Ashley Hamamoto, BS*[a], Erica Su, BS[a], Ya-Sin Peaks, MD[a], Zhongping Chen, PhD[a,b]
Brian JF Wong, MD PhD[a,b,c]
[a]Beckman Laser Institute and the Center for Biomedical Imaging,
University of California, Irvine, CA 92612; [b]University of California, Irvine, Department of Biomedical Engineering, Irvine, California 92697; [c]University of California Irvine, Department of Otolaryngology, Irvine, California 92868

ABSTRACT

Acquired subglottic stenosis is a narrowing of the airway caused by prolonged endotracheal intubation. Currently, there are no non-invasive means to diagnose the disease. A previous study by this same group introduced optical coherence tomography (OCT) as a means of monitoring the progression of stenosis. The aim of the current study was to qualitatively and quantitatively analyze OCT images obtained from a subglottic stenosis model of the rabbit airway. 15 rabbits were used throughout the study, and a MEMs based OCT probe was utilized. The OCT images obtained were analyzed using a free software program, 3D Slicer. The region of scarred tissue was grown out and measured quantitatively. This study demonstrated the feasibility of using a program to quantify the progression of scarring in OCT images, in addition to qualitatively correlating between histology, endoscopic, and OCT images. Future works may include utilization of a long-range probe and use of a pressure necrosis model to better emulate the actual onset of neonatal subglottic stenosis.

Keywords: Subglottic Stenosis, Optical Coherence Tomography, Rabbit, 3D Slicer, endoscopic images, histological images

1. INTRODUCTION

1.1 Acquired subglottic stenosis

Acquired subglottic stenosis is the narrowing of the airway caused by prolonged endotracheal intubation. Narrowing of the airway most commonly occurs in pre-mature infants, but has been known to affect children as well as adults [1]. Subglottic stenosis is diagnosed during operative endoscopy after the injury has occurred. Normally the stenosis occurs due to constant movement and pressure of the endotracheal tube [2]. The tube can expose the perichondrium of the cricoid cartilage, leading to an infection. Scar may then form from the infection narrowing the airway. Surgical measures are taken to correct the stenosis such as balloon dilation or tracheotomies. However, such interventions increase the morbidity rate and are highly invasive. Thus, this study aimed to show a new technique using Optical Coherence Tomography (OCT) to monitor the stenosis without invasive procedures.

1.2 Aim of study

OCT is a non-invasive imaging modality that uses a non-ionizing light source to obtain real-time cross-sectional images of tissue [3,4]. OCT is capable of differentiating between tissue layers of the eye, skin, and mucosa. In this study, OCT was able to detect the progression of scar in the airway. In previous studies using a subglottic stenosis model of the rabbit airway, we were able to correlate OCT and histological images qualitatively. The goal of this study was to analyze the data not only qualitatively, but quantitatively using an open source software package called 3D slicer (Cambridge, MA).

*ashley.hamamoto@gmail.com; phone: 951-529-1050

Photonic Therapeutics and Diagnostics IX, edited by Nikiforos Kollias, et al., Proc. of SPIE Vol. 8565, 856521 · © 2013 SPIE · CCC code: 1605-7422/13/$18 · doi: 10.1117/12.2014252

2. MATERIALS AND METHODS

2.1 Rabbit subglottic stenosis model

Fifteen New Zealand White rabbits were used for this study. This study was performed under the guidance of the University of California, Institutional Animal Care and Use Committee (IACUC). Rabbits were housed in the animal facility building (vivarium) at UCI. Male rabbits weighing approximately 4 kg were used in all experiments. Rabbit subglottis dimensions (5.81mm x 5.41mm) at this weight range have been shown to correlate closely to those of a neonate (4.5-5.5mm) [5]. The rabbits were randomly assigned to five different parameters. For each parameter, 3 rabbits were used, for a total of 15 rabbits used for this study. On day 0 the rabbits were anesthetized with subcutaneous injections of 2ml of ketamine hydrochloride (35mg/kg) and 1ml of xylazine hydrochloride (5mg/kg). Once anesthetized, each rabbit was monitored using a pulse oximeter, recording the heart rate and oxygen levels. The rabbit was then placed supine. A laryngoscope was used to visualize the vocal folds. The vocal folds were sprayed with 0.1cc of 1% lidocaine to numb the area. The laryngoscope was suspended to maintain visualization of the airway (**Figure 1**). A zero degree Hopkins endoscope (Karl Storz GmbH & Co®) was then placed through a 26cm, size 3 bronchoscope (Karl Storz GmbH & Co®) for photo and video documentation of the native airway. In order to standardize the area of interest, the bronchoscope was positioned below the vocal chords and secured by taping it to the laryngoscope. The OCT probe was inserted into the bronchoscope exactly 2.5 cm from the distal end of the scope to image the subglottic region. Each pull back of the probe produced around 400 images and a 3-D image stack. Epithelial injury in the subglottis was induced by a nylon brush (16" twisted wire, Nylon brush 5mm diameter, Sharn #MED 100.24, Tampa, FL) through the bronchoscope, rotating and pulsating on an average of 70 times along the surface. The working end of the brush was trimmed to 1cm so that the epithelial damage was restricted to only the subglottic region. The rabbit was then taken out of suspension, allowed to recover from anesthesia and returned to the vivarium. On post-brushed days after initial injuries, the rabbits were anesthetized and resuspended for endoscopic and OCT imaging. Rabbits were euthanized on days 3, 7, 14, 21, or 42 using an injection of 2ml of euthasol ® (pentobarbital sodium and phenytoin sodium). The laryngotracheal sections were then dissected and fixed in formaldehyde for histological analysis. After 24 hours in formaldehyde, samples were transferred into a phosphate buffer solution at a physiological pH of 7.4. After another 24 hours in buffer solution, samples were processed and embedded in paraffin. The samples were serially sectioned at 6 µm thick slices and stained with conventional hematoxylin and eosin. Photomicrographs (PictureFrame®) were then taken for documentation.



Figure 1. Images showing the rabbit in suspension and insertion of OCT probe for data collection.

2.2 OCT device and instrumentation

The Optical Coherence Tomography (OCT) technology designed for this study consists of a distal helical scanning probe, Michelson Interferometer, and high-speed acquisition card [6]. The system utilizes a non-ionizing coherent light source with a 1310 nanometer wavelength and 50 kHz scanning rate. The axial resolution of the system is 8 microns. It has a penetration depth in tissue of 1-2 mm. OCT provides images that are similar to histological cross sections. The

MEMs based OCT probe consists of a rotational motor, shaft, light beam, grin lens, and fiber as shown in **Figure 2.** The probe has a 2.2mm outer diameter. Each acquisition represents a full 360-degree rotation of the probe providing axial penetration data.

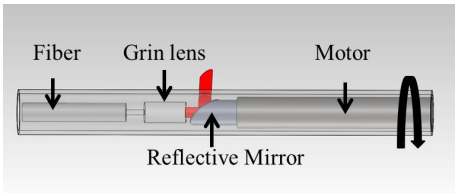

Figure 2. Components of the MEMs based OCT probe.

2.3 Data analysis software

3-D Slicer is a free, open source software package for visualization and image analysis. It is capable of both qualitative and quantitative analysis. In order to obtain quantitative measurements, the region of interest (the scar) must be manually selected and grown out in a stack of consecutive images. For our analysis, we analyzed 100 images in stacks of 15 images. The scar is drawn out in green and outlined in orange as shown in **Figure 3**. After applying the "grow cut" function, the green area (scar) is grown out in consecutive images. The orange tissue is then "thresholded" to select how much of the tissue is to be included in the volumetric rendering. "Grow cut" is a marching algorithm that is used between sequential images that are inputted in the program.



Figure 3. Step by step demonstration of "grow cut" function in 3D Slicer.

After thresholding, the "island effect" function may be used to clean up the noise and artifact in the images (**Figure 4)**.

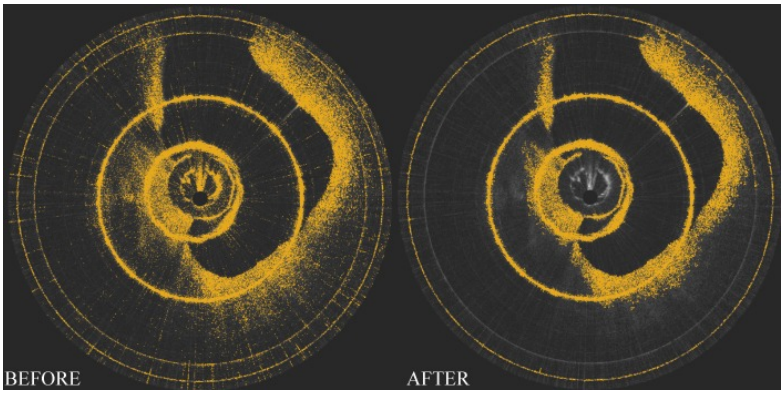

Figure 4. Before and after images of the "island effect" function in 3D Slicer.

Only pixels that are connected to each other will appear in the final 3D segmentation model. Lastly, the merge and build process finalizes the segmentation sequence such that a visual representation of the target area of interest is produced (**Figure 5)**. The volume of scar tissue was then calculated automatically by using an inherent function in 3D slicer.

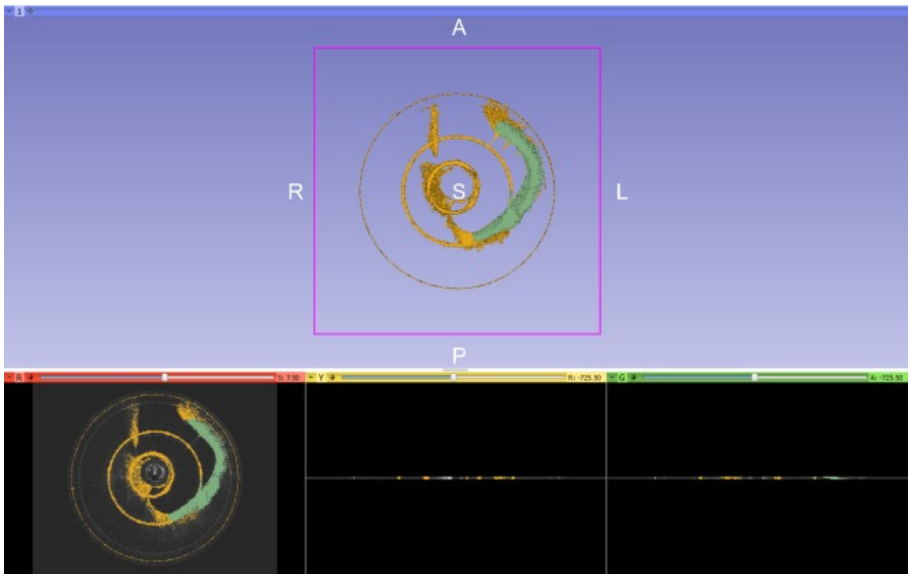

Figure 5. Final 3D rendering of scarred airway with axial, coronal, and sagittal views.

3. RESULTS

Our method of inducing subglottic stenosis in the rabbit produced consistent results. Airway scarring was measure using the software packaging system called 3D slicer. On each post-brushed day, images were obtained via endoscopy and OCT, as shown in **Figure 6**. **Figure 7** shows the results of the scarred airway of a rabbit euthanized on day 42. The graph is consistent with the steps of scar progression. The first week yields the highest volume of scar indicating extreme swelling, angiogenesis and recruitment of lymphocytes. After the second week the injury has decreased due to epithelialization and abundance of fibroblasts. The third week and on, new collagen begins to develop, increasing the volume of scar once again. This trend of the volume of scar was consistent for all rabbits in this study.

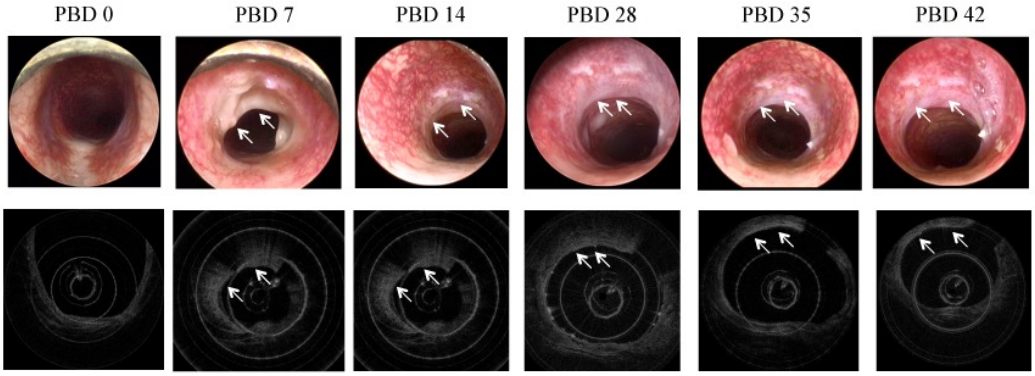

Figure 6. Montage of post-brushed days capturing endoscopic and OCT images, arrows indicating scar tissue.

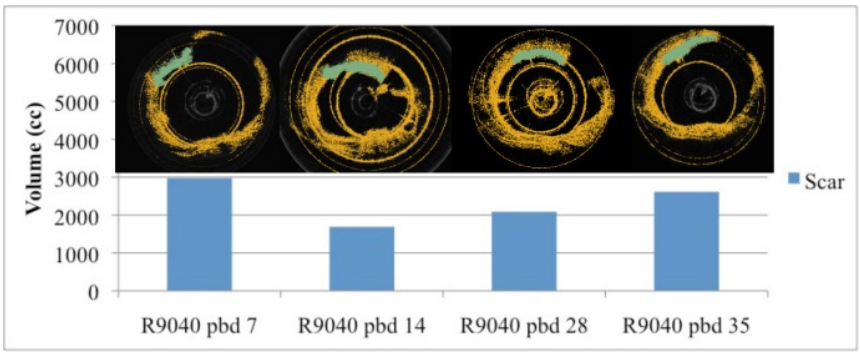

Figure 7. Graph of a post-brushed day 42 rabbit.

4. DISCUSSION

4.1 Long term objective

The long term goal of this study is to use OCT in the NICU to image the neonatal subglottic airway with the intent to identify early airway edema or trauma before surgical procedures are necessary. This study showed the capabilities of the OCT imaging technology for use in the neonatal, intubated airway. We have shown the correlation between endoscopic, OCT, and histologic images and demonstrated the feasibility of using the 3D Slicer for quantitative analysis.

4.2 Limitations of the study

The main limitations of this study originate with the OCT probe design and 3D Slicer program characteristics. The OCT MEMs based probe was designed with the motor at the distal end allowing for distal rotation. However, given the low profile design, the portion containing the motor was not very stable and would stall if the tip was manipulated too much. Additionally, the optics on the first probe were not rigidly fixed and therefore would come out of alignment, varying the image size of the lumen in the airway. The probe design also failed to reliably generate a full 360 degree tissue image due to the limitations of the OCT swept source laser imaging range. Only a limited number of uploaded pictures could be rendered in 3D Slicer due to insufficient computer processing power. The "island effect" was unable to completely eliminate all unnecessary noise. Lastly, the program was not completely automated, which made choosing the scarred area subjective to the researcher.

4.3 Future work

In future studies we would like to design and build a long-range OCT system with a proximal rotational probe. The system would ideally be capable of a larger imaging range of 2cm or more. The distance of the optics will be fixed in order to standardize the image size of the lumen. We would also like to create an endotracheal balloon pressure model which does not involve damages to the surface epithelium. This model would better emulate trauma that causes the beginning stages of neonatal acquired subglottic stenosis.

REFERENCES

1. Santos, D. and R. Mitchell, *The history of pediatric airway reconstruction.* Laryngoscope. **120**(4): p. 815-20.
2. Choi, S.S. and G.H. Zalzal, *Changing trends in neonatal subglottic stenosis.* Otolaryngol Head Neck Surg, 2000. **122**(1): p. 61-3.
3. Ridgway, J.M., et al., *Imaging of the pediatric airway using optical coherence tomography.* Laryngoscope, 2007. **117**(12): p. 2206-12.

4. Ridgway, J.M., et al., *Optical coherence tomography of the newborn airway.* Ann Otol Rhinol Laryngol, 2008. **117**(5): p. 327-34.
5. Loewen, M.S. and D.L. Walner, *Dimensions of rabbit subglottis and trachea.* Lab Anim, 2001. **35**(3): p. 253-6.
6. Fujimoto, J.G., *Optical Coherence Tomography.* Science, 1991. **254**(5035): p. 1178-1181