Title
Styloglossus muscle: a critical landmark in head and neck oncology

Journal
European Annals of Otorhinolaryngology Head and Neck Diseases, 135(6)

ISSN
1879-7296

Authors
Laccourreye, O
Orosco, RK
Rubin, F
et al.

Publication Date
2018-12-01

DOI
10.1016/j.anorl.2017.11.012

Peer reviewed

European Annals of Otorhinolaryngology, Head and Neck diseases 135 (2018) 421–425

Available online at
ScienceDirect
www.sciencedirect.com

Elsevier Masson France
EM|consulte
www.em-consulte.com/en

Review

Styloglossus muscle: a critical landmark in head and neck oncology

O. Laccourreye[a,*], R.K. Orosco[b], F. Rubin[a], F.C. Holsinger[c]

[a] Service d'otorhinolaryngologie et de chirurgie cervicofaciale, HEGP, université Paris Descartes Sorbonne Paris Cité, AP–HP, 20–40, rue Leblanc, 75015 Paris, France
[b] Departments of otorhinolaryngology, Head and Neck Surgery, university of California San Diego, San Diego, CA, USA
[c] Department of otolaryngology, school of medicine, Stanford University, 875 Blake Wilbur Drive, 94305-5820 Palo Alto, CA, USA

ARTICLE INFO

Keywords:
Oropharynx
Oropharyngectomy
Squamous cell carcinoma
Cancer
Styloglossus muscle

ABSTRACT

Goal: To document the role of the styloglossus muscle (SG) in head and neck oncology and at the time of surgical treatment and mandibular preservation surgery for squamous cell carcinoma of the lateral oropharynx (SCCLO).
Method: Based on a search conducted within the Pubmed, Embase, and Cochrane databases, using the key words SG muscle, parapharyngeal space and oropharynx, the authors discuss the embryology, physiology, anatomy and radiology of this muscle as well as its role in the oncologic staging surgery of SCCLO.
Results: The most specific radiologic exam to evaluate the involvement of SG muscle in SCCLO is magnetic resonance imaging (MRI). According to the eigth international staging classification systems, radiologic invasion of the SG muscle, at the time of MRI, leads to reclassify as T4a many tumors considered as T1-3 at the time of clinical and/or on computerized tomography evaluation. This must lead to extreme care when comparing oncologic results from series published prior and after the MRI era. When transoral resection of the SG muscle is advocated for SCCLO, one must know that this maneuver brings numerous arterial and venous structures within the operative field. If difficulties to achieve safe margins of resection and/or to control bleeding are encountered, a simple trans cervical maneuver described herein is most useful.
Conclusion: The importance of the SG muscle should be emphasized as a touchstone for staging and surgeon's guide to mandibular preservation surgery of SCCLO. The various approaches allowing the control of this muscle and its vascular environment must be taught at the time of initial training.

1. Introduction

While the demonstration of the role of the human papilloma virus in the genesis of oropharyngeal squamous cell carcinoma led some to predict an "epidemic" of such cancer in the future [1], the Western world has experienced a revival of mandibular preservation surgery for squamous cell carcinoma of the lateral oropharynx (SCCLO) [2–7]. Simultaneously, magnetic imaging resonance (MRI) has become more widely-used in the pre-treatment work-up of SCCLO and integrated the staging classification systems though radiological criteria [8,9]. As a result, anatomic intricacies of the lateral oropharynx and adjacent parapharyngeal space have been brought to light. An overlooked structure, the styloglossus muscle (SG) plays a critical role in the staging and surgical management of SCCLO. In this report, based on an electronic search conducted within the Pubmed, Embase and Cochrane databases using the keywords styloglossus muscle, parapharyngeal space and oropharynx, the authors delve into the embryology, physiology, anatomy, radiology of the SG muscle together with considerations regarding its impact on staging and key surgical points allowing for its resection without mandibular resection in the face of SCCLO.

2. Discussion

2.1. Embryology, physiology and "conventional" anatomy

Embryologically the SG muscle originates from Reichert's cartilage and starts investing with muscle fibers of the genioglossus and transverse muscle of the tongue in utero as early as day 42 [10,11]. Katori et al. [12] noted that the SG muscle is covered by a fascia adjoined to the carotid sheath. According to the same group, the ascending palatine artery is the major arterial supply of the pre styloid space anterior to this muscle [13].

In addition to the stylopharyngeus and stylohyoid muscles, the SG belong to the group of muscles that originate from the styloid

* Corresponding author. Service d'otorhinolaryngolgie et de chirurgie cervicofaciale HEGP, 20–40, rue Leblanc, 75015 Paris, France.
E-mail address: ollivier.laccourreye@aphp.fr (O. Laccourreye).

https://doi.org/10.1016/j.anorl.2017.11.012
1879-7296/

process [14–17]. As depicted in Figs. 1 and 2, the SG muscle is medial and anterior to the stylohyoid muscle, and runs lateral to the superior constrictor muscle [14–17]. The stylohyoid muscle is also superior and medial to a well-recognized anatomical landmark used by radiologists, radiation therapists, and head and neck surgeons routinely used to delineate, stage, radiate and resect the nodes within the neck of patients with SCCLO: the posterior belly of the digastric muscle.

Rouvière [15], Gray's [16] and Pernkopft's [17] anatomy text books teach that the styloglossus muscle, whose action is to elevate and retract the tongue base backwards, attaches inferiorly along the lateral surface of the tongue and the upper border of the mylohyoid muscle (Fig. 2). At this level, Saito and Itoh [18] noted that more than ten SG muscle fibers bundles formed an arched, multi-layered structure involved with the genioglossus muscle and the intrinsic transverse muscle of the tongue, all the way to the lingual septum. Laterally, they noted that it is also intimated with the fibers of the superior pharyngeal constrictor muscle.

Prades et al. [14], in a cadaver dissection of ten adult heads (20 sides) noted that the glossopharyngeal nerve (IXth cranial nerve) did not appear to be in close relationship with the SG muscle. The nerve turned around the stylopharyngeus muscle – superiorly with a vertical segment posterior to the stylopharyngeus, and inferiorly with a horizontal segment lateral to the same muscle. The meeting point of these two segments of the IXth cranial nerve is about 10 mm anterior from the transverse process of the atlas [14].

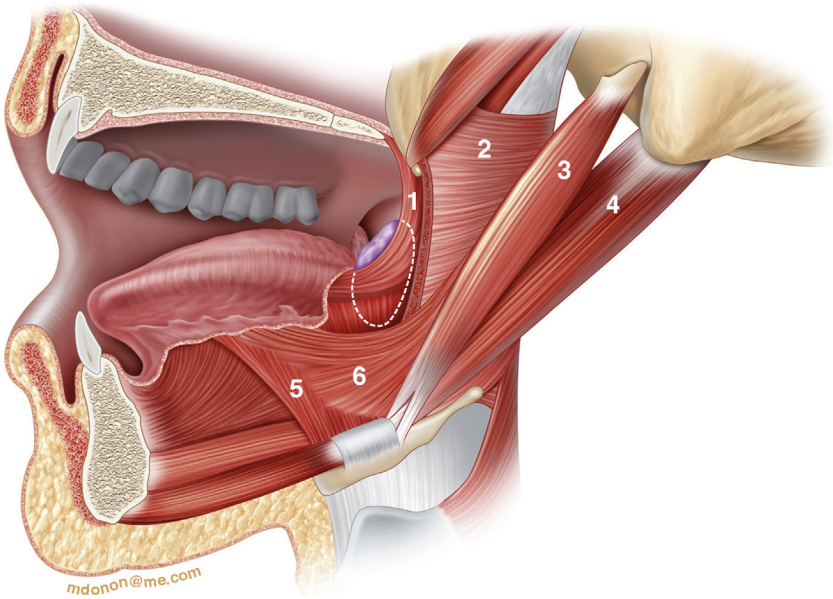

Fig. 1. Schematic representation from outside (mandible and cheek resected) of the relationship between the posterior belly of the digastric muscle (4), stylohyhoid muscle and ligament (3), palatoglossus muscle (1), superior constrictor muscle (2), mylohyoid muscle (5), and styloglossus muscle (6).

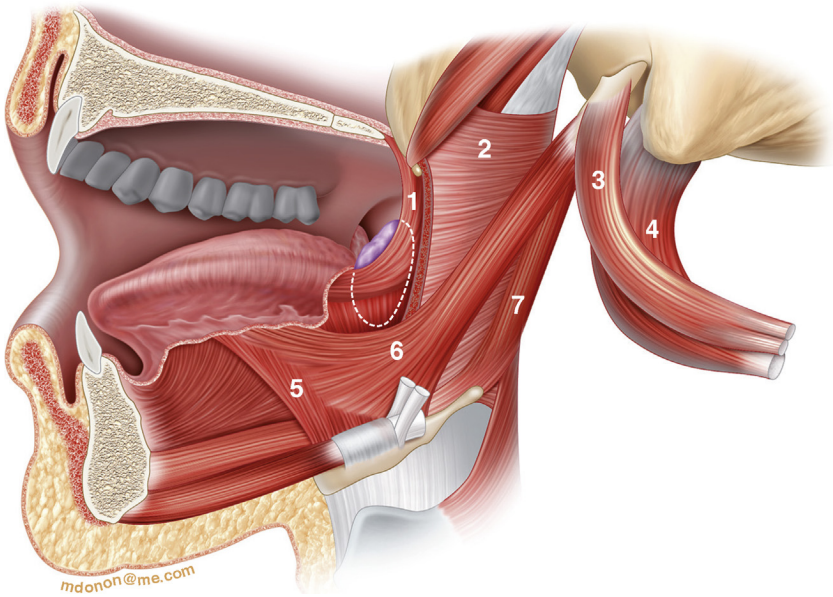

Fig. 2. Schematic representation from outside following transection and deflection of the posterior belly of the digastric muscle (4) and stylohyoid muscle and ligament (3). Note the relationship between the palatoglossus (1), superior constrictor (2), mylohyoid (5), styloglossus (6), and stylopharyngeus (7) muscles. Dotted white line indicates projection of the palatine tonsil.

2.2. Radiology of the styloglossus muscle

The eighth European and American TNM staging classification systems integrated the radiological work up in the pre-treatment staging of SCCLO [8,9]. Within the pharynx, these staging systems classified a T4a cancer as one that invaded the deep extrinsic lingual muscles; namely, at the level of the lateral oropharynx: the palatoglossus, and SG muscles [8,9].

It is widely held that MRI is superior to computed tomography (CT) in the delineation of mucosal and muscular involvement of cancers of the oropharynx [19]. On MRI, the course of the SG muscle within the lateral oropharynx till its insertion in the tongue base musculature is generally well-visualized. It is in extremely close anatomical relationship with the oropharynx mucosa with when it reaches the tongue: 1.3 mm (0.33–1.48) on the right muscle and 2.91 mm (0.66–7.68) for the left [20]. Due to the radiographic staging criteria mentioned above, this extreme proximity with the mucosa of the lateral oropharynx leads to a frequent radiographic up-staging. Based on the radiographic evidence of SG muscle involvement, Boland et al. [21] noted that up to 52% of cases clinically considered as T1-3 have been shown to be reclassified as T4a. However, the validity and relevance of radiographic up-staging is this scenario is controversial.

The first "negative" point of this radiological up staging is the fact that it prevents any comparison with the oncologic data reported prior to the introduction of MRI while the real value of this exam to evaluate mucosal and muscular invasion in SCCLO is still under debate. In a retrospective analysis of 37 patients with SCCs originating from the tonsil who underwent primary resection, Park et al. [22] noted that there was no significant statistical correlation between the invasion depth measured on MRI and the invasion depth measured histologically on the pathology specimens. The second problem relies to the therapeutic indications; when "early" (T1-2) SCC that would be amenable to a surgical conservative approach with an excellent prognosis are up-staged to "advanced" stage (T4a), a non-surgical treatment plan is more likely. This prevents true surgical and pathologic staging assessments, may expose patients to otherwise-avoidable risks related to postoperative radiation or chemoradiation and limit the use of radiation therapy when a metachronous second primary SCC occurs at the level of the upper aero digestive tract. Finally, when not representative of the true disease state, radiographic up-staging invalidates the conventional head and neck oncologic concept that rely T stage to local failure in patients managed with conservative approaches with an increase in the local failure rate as the T stage progresses from 1 to 4. Thereby, Laccourreye et al. [23], when using the lateral pharyngotomy approach for SCCLOs noted that, in terms of local control, the "T4a" group will tend to parallel the results achieved in T2 tumors. Likewise, inappropriate radiographic up-staging artificially mixes the T4 stage grouping by introducing low-volume tumors with apparent styloglossus involvement, contradicting the well-documented finding that the tumor volume is a predictor of outcome after surgical or radiation treatment for SCCLO [24,25]. And recently, Murthy et al. [26] following a prospective analysis of 87 patients with oral tongue squamous cell carcinoma which had MRI prior to surgery advocated the removal of extrinsic muscle involvement in defining stage T4 of the oral cavity considering the modification made in the staging classification system as a "fallacy".

2.3. Surgical anatomy of the styloglossus muscle

From a surgical anatomical perspective, the SG muscle may be encountered when performing a resection either via a transoral approach, or a trans cervical route for SCCLO.

Through a transoral approach, the SG muscle is often encountered crossing from outside to inside by the level of the lower pole of the tonsil (Figs. 1–3). At this level, the SG muscle crosses the internal carotid artery in the parapharyngeal space before it invests with the fibers of the tongue base musculature [27]. Various reports suggested that the other main vessels encountered per-orally are the ascending palatine artery (arising from the facial artery), and the ascending pharyngeal artery (arising from the medial surface of the external carotid artery) [28–30]. Wang et al. [30] noted that both the ascending pharyngeal and ascending palatine arteries crossed the SG muscle. The ascending pharyngeal artery crossed the SG muscle 12.6 ± 3.9 mm from the insertion into the tongue, and in 58% of cases it ascends vertically to the skull base between the internal carotid artery and the constrictor muscles along the capitus muscle (as depicted in Pernkopft's text book [17]). A noteworthy finding in 8% of cases in Wang's series, was that the external carotid artery bulged into the parapharyngeal fat between the SG and stylopharyngeus muscles [30]. There are also numerous vessels from the venous plexus that lie in close relationship with the external surface of the SG muscle and the external carotid artery [28–31].

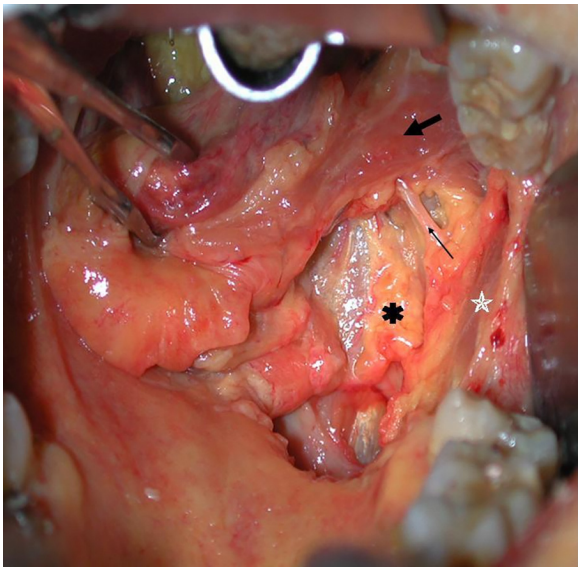

Fig. 3. Intra-operative view of the styloglossus muscle at the lower pole of a right transoral lateral oropharyngectomy [white star: internal (medial) pterygoid muscle, black bold arrow: styloglossus muscle, thin black arrow: IXth cranial nerve, asterisk: fascia overlying internal carotid artery, adjacent to parapharyngeal fat]. With permission from Holsinger et al., Transoral lateral oropharyngectomy for squamous carcinoma of the tonsillar region: I. Technique, complications, and functional results. Arch Otolaryngol Head Neck Surg 2005; 131:583–91 [26].

When performing a trans cutaneous approach, the SG muscle located just above level II is hidden by the posterior belly of the digastric muscle and the stylohyoid muscle and ligament (Figs. 1, 2, 4, 5). As depicted in Figs. 2 and 5, the SG muscle is easily exposed by transecting the posterior belly of the digastric muscle, the stylohyoid muscle and ligament from the lesser horn of the hyoid bone and rotating them outside [28,31]. This opens the external plane of the SG muscle and the adjacent arterial vessels (Figs. 2 and 5). The space and the view achieved may be enlarged anteriorly by ligating and transecting the facial artery when it enters the submandibular space and, eventually, posteriorly by ligating and dividing the terminal extent of the external carotid artery when it enters the parotid space [28,31]. This technique, which permits direct visualization and control of the above-mentioned arteries and venous plexus as well as wide resection of the SG muscle under palpation and direct vision, may be most useful if bleeding occurs when performing a transoral approach [28,31–35].

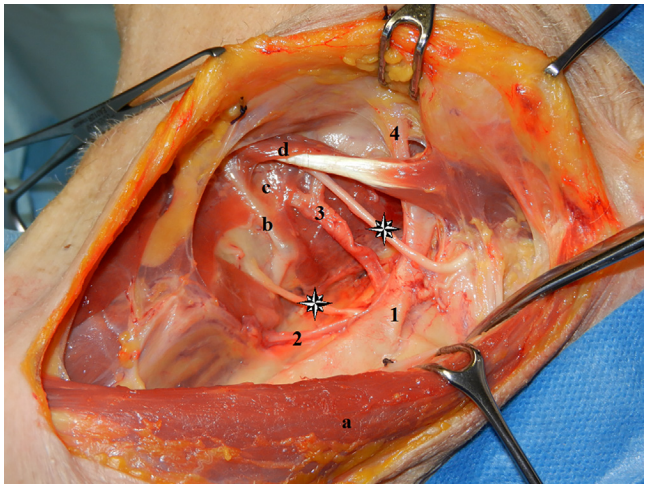

Fig. 4. Cadaveric dissection of the left neck demonstrating the various neural and vascular elements in the operative field before section of the posterior belly of the digastric muscle, stylohyoid muscle and stylohyoid ligament from the hyoid bone (1: external carotid artery, 2: superior thyroid artery, 3: lingual artery with the origin of its first branch, 4: facial artery; a: sternocleidomastoid muscle, b: lateral horn of the hyoid bone, c: mylohyoid muscle, d: tendon of the digastric muscle with stylohyoid muscle fibers; stars indicate trunks of the superior laryngeal and hypoglossal nerves).

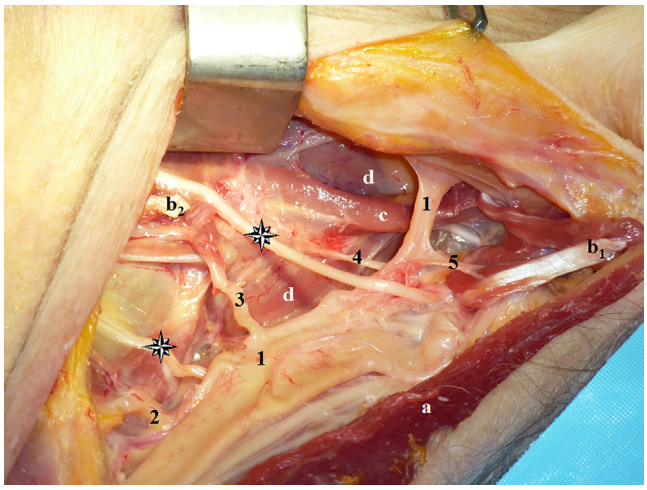

Fig. 5. Cadaveric dissection of the left neck demonstrating the various neural and vascular elements in the operative field once the posterior belly of the digastric muscle and the stylohyoid muscle and ligament have been transected and deflected from the lateral horn of the hyoid bone [1: external carotid artery, 2: superior thyroid artery, 3: lingual artery, 4: pharyngeal ascending artery, 5: occipital artery; a: sternocleidomastoid muscle, b_1 and b_2: extremities of the transected tendon of the digastric muscle and stylohyoid muscles; c: styloglossus muscle; d: superior constrictor muscle; stars indicate trunks of the superior laryngeal and hypoglossal nerves]. The ipsilateral facial artery has been transected at its origin from the external carotid artery and removed to ease the view of the styloglossus and superior constrictor muscles. Faraboeuf retractor pulls away the submandibular gland.

3. Conclusion

This review article suggest hat the transoral and the trans cervical approaches to the lateral oropharynx should be seen as a continuum of head and neck surgery and closely linked, rather than in opposition. Understanding this key relationship between the SG muscle, the neck and increasing complexity of surrounding vasculature may increase the safety and accuracy of surgery and thus spare patients from mandibulotomy unless absolutely necessary.

Disclosure of interest

The authors declare that they have no competing interest.

Acknowledgments

This study was supported in part by the Progrès 2000 Association and Stanford H&N Research Fund.

References

[1] Sturgis EM, Ang KK. The epidemic of HPV-associated oropharyngeal cancer is here: is it time to change our treatment paradigms? J Natl Compr Canc Netw 2011;9:665–73.
[2] Canis M, Martin A, Kron M, et al. Results of transoral laser microsurgery in 102 patients with squamous cell carcinoma of the tonsil. Eur Arch Otorhinolaryngol 2013;270:2299–306.
[3] Chaturvedi AK, Engels EA, Pfeiffer RM, et al. Human papillomavirus and rising oropharyngeal cancer incidence in the United States. J Clin Oncol 2011;29:4294–301.
[4] Haughey BH, Hinni ML, Salassa JR, et al. Transoral laser microsurgery as primary treatment for advanced-stage oropharyngeal cancer: a United States multicenter study. Head Neck 2011;33:1683–94.
[5] Laccourreye O, Hans S, Menard M, Garcia D, Brasnu D, Holsinger FC. Transoral lateral oropharyngectomy for squamous cell carcinoma of the tonsillar region.II. An analysis of the incidence, related variables, and consequences of local recurrence. Arch Otolaryngol Head Neck Surg 2005;131:592–9.
[6] Laccourreye O, Malinvaud D, Holostenco V, Menard M, Garcia D, Bonfils P. Value and limits of non-robotic transoral oropharyngectomy for local control of T1-2 invasive squamous cell carcinoma of the tonsillar fossa. Eur Ann Otorhinolaryngol Head Neck Dis 2015;132:141–6.
[7] Liederbach E, Lewis CM, Yao K, et al. A Contemporary analysis of surgical trends in the treatment of squamous cell carcinoma of the oropharynx from 1998 to 2012: A report from the National Cancer database. Ann Surg Oncol 2015;22:4422–31.
[8] Brierley J, Gosporadowicz M, Wittekin C. TNM Classigfciation System of Malignant Tumours. UK: Eigth Edition Oxford, Wiley-Blackwell; 2016.
[9] Amin MB, Edge S, Greene F, et al. AJCC Cancer Staging Manual Eigth Edition. Springer; 2017.
[10] Benoit R, Lemire M, Saban R. Embryogenesis of the styloglossus muscle in the human embryo. Its relationship with neighboring structures. J Biol Buccale 1985;13:113–31.
[11] Merida-Velasco JR, Rodriguez-Vazquez JF, de la Cuadra Blanco C, Sanchez-Montesinos I, Merida-Velasco JA. Origin of the styloglossus muscle in the human fetus. J Anat 2006;208:649–53.
[12] Katori Y, Kawase T, Ho Cho K, et al. Suprahyoid neck fascial configuration, especially in the posterior compartment of the parapharyngeal space: a histological study using late-stage human fetuses. Clin Anat 2013;26:204–12.
[13] Katori Y, Kawase T, Cho KH, et al. Prestyloid compartment of the parapharyngeal space: a histological study using late-stage human fetuses. Surg Radiol Anat 2012;34:909–20.
[14] Prades JM, Gavid M, Asanau A, Timoshenko AP, Richard C, Martin CH. Surgical anatomy of the styloid muscles and the extracranial glossopharyngeal nerve. Surg Radiol Anat 2014;36:141–6.
[15] Rouvière H. Anatomie humaine descriptive et topographique et fonctionnelle. Tome I Tête et Cou. 10 ed Paris: Masson; 1967. p. 535–53.
[16] Drake RL, Vogl W, Mitchell AWM, Gray H. Gray's anatomy for students. 2nd ed. Philadelphia, PA: Churchill Livingstone/Elsevier; 2010.
[17] Pernkopft WP, Anatomy. Alas of topographic and applied human anatomy. Vol I Head & Neck, 62, 3rd ed. Baltimore: Urban & Schwarzenberg; 1989. p. 340–3.
[18] Saito H, Itoh I. The three-dimensional architecture of the human styloglossus especially its posterior muscle bundles. Ann Anat 2007;189:261–7.
[19] Antoniou AJ, Marcus C, Subramaniam RM. Value of imaging in head and neck tumors. Surg Oncol Clin N Am 2014;23:685–707.
[20] Boland PW, Pataridis K, Eley KA, Golding SJ, Watt-Smith SR. A detailed anatomical assessment of the lateral tongue extrinsic musculature, and proximity to the tongue mucosal surface. Does this confirm the current TNM T4a muscular subclassification? Surg Radiol Anat 2013;35:559–64.
[21] Boland PW, Pataridis K, Eley KA, Golding SJ, Watt-Smith SR. Automatic upstaging of tongue squamous cell carcinoma with lateral extrinsic muscle involvement is not justified. Int J Oral Maxillofac Surg 2013;42:1397–402.
[22] Park JO, Jung SL, Joo YH, Jung CK, Cho KJ, Kim MS. Diagnostic accuracy of magnetic resonance imaging (MRI) in the assessment of tumor invasion depth in oral/oropharyngeal cancer. Oral Oncol 2011;47:381–6.
[23] Laccourreye O, Benito J, Garcia D, Menard M, Bonfils P, Holsinger C. Lateral pharyngotomy for selected invasive squamous cell carcinoma of the lateral oropharynx. Part II: when and why. Laryngoscope 2013;123:2718–22.
[24] Nixon IJ, Palmer FL, Lakin P, Kattan MM, Lee NY, Ganly I. Pathologically determined tumor volume vs pathologic T stage in the prediction of outcome after surgical treatment of oropharyngeal squamous cell carcinoma. JAMA Otolaryngol Head Neck Surg 2013;139:1151–5.

[25] Strongin A, Yovino S, Taylor R, et al. Primary tumor volume is an important predictor of clinical outcomes among patients with locally advanced squamous cell cancer of the head and neck treated with definitive chemoradiotherapy. Int J Radiat Oncol Biol Phys 2012;82:1823–30.
[26] Murthy SP, Thankappan K, Jayasankaran SC, et al. Deep extrinsic muscle involvement is a fallacy in the American Joint Committee on Cancer's seventh edition of tumor staging of oral cavity cancers. J Oral Maxillofac Surg 2018;76:206–12.
[27] Holsinger FC, McWhorter AJ, Menard M, Garcia D, Laccourreye O. Transoral lateral oropharyngectomy for squamous cell carcinoma of the tonsillar region: I. Technique, complications, and functional results. Arch Otolaryngol Head Neck Surg 2005;131:583–91.
[28] Gun R, Durmus K, Kucur C, Carrau RL, Ozer E. Transoral surgical anatomy and clinical considerations of lateral oropharyngeal wall, parapharyngeal space, and tongue base. Otolaryngol Head Neck Surg 2016;154:480–5.
[29] Lim CM, Mehta V, Chai R, et al. Transoral anatomy of the tonsillar fossa and lateral pharyngeal wall: anatomic dissection with radiographic and clinical correlation. Laryngoscope 2013;123:3021–5.
[30] Wang C, Kundaria S, Fernandez-Miranda J, Duvvuri U. A description of arterial variants in the transoral approach to the parapharyngeal space. Clin Anat 2014;27:1016–22.
[31] Masuda M, Fukushima J, Kadota H, Kamizono K, Ejima M, Taura M. Mandible preserving pull-through oropharyngectomy for advanced oropharyngeal cancer: a pilot study. Auris Nasus Larynx 2011;38:392–7.
[32] Bozec A, Poissonnet G, Chamorey E, et al. Transoral and cervical approach without mandibulotomy for oropharynx cancer with fasciocutaneous radial forearm free flap rconstruction. Ann Otolaryngol Chir Cervicofac 2009;126:182–9.
[33] Laccourreye O, Seccia V, Menard M, Garcia D, Vacher C, Holsinger FC. Extended lateral pharyngotomy for selected squamous cell carcinomas of the lateral tongue base. Ann Otol Rhinol Laryngol 2009;118:428–34.
[34] Laccourreye O, Benito J, Menard M, Garcia D, Malinvaud D, Holsinger C. Lateral pharyngotomy for selected invasive squamous cell carcinoma of the lateral oropharynx – Part I: How. Laryngoscope 2013;123:2712–7.
[35] Mandal R, Duvvuri U, Ferris RL, Kaffenberger TM, Choby GW, Kim S. Analysis of post-transoral robotic-assisted surgery hemorrhage: Frequency, outcomes, and prevention. Head Neck 2016;38(Suppl 1):E776–82.