

# UCLA

## UCLA Previously Published Works

### Title

Intracoronary stenting without anticoagulation accomplished with intravascular ultrasound guidance.

### Permalink

<https://escholarship.org/uc/item/6m13k659>

### Journal

Circulation, 91(6)

### ISSN

0009-7322

### Authors

Colombo, A  
Hall, P  
Nakamura, S  
[et al.](#)

### Publication Date

1995-03-01

### DOI

10.1161/01.cir.91.6.1676

### Copyright Information

This work is made available under the terms of a Creative Commons Attribution License, available at <https://creativecommons.org/licenses/by/4.0/>

Peer reviewed

**Circulation**

circ.ahajournals.org

Circulation. 1995;91:1676-1688  
doi: 10.1161/01.CIR.91.6.1676

**Articles****Intracoronary Stenting Without Anticoagulation Accomplished With Intravascular Ultrasound Guidance**

Antonio Colombo, MD; Patrick Hall, MD; Shigeru Nakamura, MD; Yaron Almagor, MD; Luigi Maiello, MD; Giovanni Martini, CCP;  
Antonio Gaglione, MD; Steven L. Goldberg, MD; Jonathan M. Tobis, MD

Author Affiliations

Correspondence to Antonio Colombo, MD, Centro Coure Columbus, Via M. Buonarotti 48, 20145 Milan, Italy.

**Abstract**

**Background** The placement of stents in coronary arteries has been shown to reduce restenosis in comparison to balloon angioplasty. However, clinical use of intracoronary stents is impeded by the risk of subacute stent thrombosis and complications associated with the anticoagulant regimen. To reduce these complications, the hypothesis that systemic anticoagulation is not necessary when adequate stent expansion is achieved was prospectively evaluated on a consecutive series of patients who received intracoronary stents.

**Methods and Results** From March 1993 to January 1994, 359 patients underwent Palmaz-Schatz coronary stent insertion. After an initial successful angiographic result with <20% stenosis by visual estimation had been achieved, intravascular ultrasound imaging was performed. Further balloon dilatation of the stent was guided by observation of the intravascular ultrasound images. All patients with adequate stent expansion confirmed by ultrasound were treated only with antiplatelet therapy (either ticlopidine for 1 month with short-term aspirin for 5 days or only aspirin) after the procedure. Clinical success (procedure success without early postprocedural events) at 2 months was achieved in 338 patients (94%). With an inflation pressure of  $14.9 \pm 3.0$  atm and a balloon-to-vessel ratio of  $1.17 \pm 0.19$ , optimal stent expansion was achieved in 321 of the 334 patients (96%) who underwent intravascular ultrasound evaluation, with these patients receiving only antiplatelet therapy after the procedure. Despite the absence of anticoagulation, there were only two acute stent thromboses (0.6%) and one subacute stent thrombosis (0.3%) at 2-month clinical follow-up. Follow-up angiography at 3 to 6 months documented two additional occlusions (0.6%) at the stent site. At 6-month clinical follow-up, angiographically documented stent occlusion had occurred in 5 patients (1.6%). At 6-month clinical follow-up, there was a 5.7% incidence of myocardial infarction, a 6.4% rate of coronary bypass surgery, and a 1.9% incidence of death. Emergency intervention (emergency angioplasty or bailout stent) for a stent thrombosis event was performed in 3 patients (0.8%). The overall event rate was relatively high because of intraprocedural complications that occurred in 16 patients (4.5%). Intraprocedural complications, however, decreased to 1% when angiographically appropriately sized balloons were used for final stent dilations. There was one ischemic vascular complication that occurred at the time of the procedure and one ischemic vascular complication that occurred at the time of angiographic follow-up. By 6 months, repeat angioplasty for symptomatic restenosis was performed in 47 patients (13.1%).

**Conclusions** The Palmaz-Schatz stent can be safely inserted in coronary arteries without subsequent anticoagulation provided that stent expansion is adequate and there are no other flow-limiting lesions present. The use of high-pressure final balloon dilations and confirmation of adequate stent expansion by intravascular ultrasound provide assurance that anticoagulation therapy can be safely omitted. This technique significantly reduces hospital time and vascular complications and has a low stent thrombosis rate.

**Key Words:**

stents  
ultrasonics  
balloon  
platelets

The placement of intracoronary stents decreases the morbidity of acute closure<sup>1 2</sup> and reduces the restenosis rate in de novo lesions<sup>3 4 5 6</sup> and vein grafts<sup>3 5</sup> compared with historical angioplasty results.<sup>7 8 9 10 11 12 13 14</sup> More recently, the Benestent and STRESS randomized trials compared stents and angioplasty in treating de novo native coronary artery lesions.<sup>15 16</sup> Both studies demonstrated a significant reduction in the restenosis rate in the group treated with stents. In addition, in the Benestent trial, the reduction in restenosis rate was associated with a significant reduction in major clinical events in the group randomized to stents.<sup>16</sup> Increased clinical use of stents may be justified on the basis of these investigations but is impeded by two major limitations: the risk of stent thrombosis and the complications associated with an aggressive anticoagulation regimen. A stringent anticoagulation regimen has been advocated to inhibit the incidence of subacute stent thrombosis but is associated with bleeding and vascular complications without eliminating subacute stent thrombosis.<sup>1 2 5 6 15 16 17 18 19 20</sup>

Prior studies with intravascular ultrasound imaging of deployed stents reveal that >80% of stents may be insufficiently dilated despite an apparently angiographically successful deployment.<sup>21 22</sup> These observations suggest that stent thrombosis may be caused in part by incomplete stent dilation rather than the inherent thrombogenicity of the metallic stent.

The hypothesis of this study is that systemic anticoagulation is not necessary after stent insertion when adequate stent expansion is achieved. This hypothesis was prospectively evaluated in a consecutive series of 359 patients who received Palmaz-Schatz intracoronary stents. All patients with adequate stent expansion as confirmed by intravascular ultrasound were treated only with antiplatelet therapy and did not receive anticoagulation after the procedure.

## Methods

Between March 30, 1993, and January 1, 1994, 359 consecutive patients with 452 lesions were treated with insertion of a Palmaz-Schatz intracoronary stent. During the first 3 months of this investigation, patients were informed of the potential risks and benefits of intracoronary stents and of the novelty of the approach used in this investigation and consented to participate in the study. After the first 3 months, consent was obtained after patients were informed of the risk and benefit of intracoronary stents and of the interim results of this protocol compared with the outcome of stenting with standard anticoagulation regimens. The first 10 patients enrolled in the study were selected on the basis of having lesions that were at low risk of causing major ischemic complications in the event of a stent occlusion (eg, total occlusion lesions, non-left anterior descending lesions, or lesions supplying a small or modest amount of myocardium). Subsequent to this selection, there was no attempt to limit enrollment in patients who consented and met inclusion criteria. The entry criteria included (1) coronary artery disease manifested by clinical symptoms or objective evidence of myocardial ischemia either on exercise test or by nuclear scintigraphy and (2) angiographic evidence of single- or multiple-vessel coronary disease with target lesion stenosis >70% by visual estimate. The exclusion criteria included (1) small vessels <2.5 mm by visual estimate and (2) angiographically diffuse distal disease that might compromise outflow after stent insertion. There were no specific age or ejection fraction limitations for study entry. Patients were not excluded on the basis of indication for stent implantation, lesion location, or complex lesion morphology. Thus, patients with ostial lesions, tortuous vessels, diffuse disease, long lesions, tandem lesions, and lesions with thrombus or severe calcification were eligible for study entry.

### Stent Implantation Procedure

Patients received aspirin 325 mg and calcium channel antagonists before stent deployment. A bolus of 10 000 U heparin was given after sheath insertion, with a repeat bolus of 5000 U given as needed to maintain the activated clotting time >250 seconds. Patients were not given dextran or dipyridamole before, during, or after the stent procedure. Ticlopidine was not administered before or during the stent procedure. Five different types of Johnson and Johnson tubular slotted stents were used during the course of this study: the Palmaz-Schatz stent, a short stent composed of one 7-mm tubular slotted segment, a 10-mm-long biliary stent, a 20-mm renal stent composed of two 10-mm segments with a central articulation, and a short (disarticulated) renal stent. A premounted stent delivery system was used sparingly during the study (n=7). After predilation, stents were hand crimped on balloons and implanted under fluoroscopic guidance. Further dilatations (angiographic optimization) were performed to achieve an acceptable angiographic result with <20% residual stenosis by visual estimates. After the angiographic result was considered acceptable and the procedure would ordinarily be terminated, intravascular ultrasound was performed. All subsequent treatment decisions were based on the ultrasound results in conjunction with angiographic assessment. The initial intravascular ultrasound was the first ultrasound examination performed when initial angiographic success (<20% residual stenosis by visual estimate) was achieved. The final intravascular ultrasound was the last intravascular ultrasound evaluation, which documented that the criteria for stent expansion were achieved. Further balloon dilatation or stent implantation that was performed after the initial intravascular ultrasound imaging was called intravascular ultrasound-guided stent optimization.

The indications for placement of stents were defined as follows: Acute occlusion stenting was undertaken to relieve ischemia associated with complete vessel closure (100%) after angioplasty with no or markedly delayed grade 0 or 1 Thrombolysis in Acute Myocardial Infarction (TIMI) flow; threatened closure stenting was performed when the angioplasty was complicated by a longitudinal or spiral dissection associated with >50% luminal encroachment (with or without compromised flow) and evidence of ischemia; suboptimal result stenting was defined as insertion of a stent for a focal dissection or significant vascular recoil after angioplasty that resulted in >50% luminal narrowing but was not associated with ischemia; restenosis stenting was performed for lesions with a history of restenosis after one or more previous angioplasty procedures; chronic occlusion stenting was performed after a vessel that had been occluded for more than 2 months was reopened; and elective stenting was performed when the operator believed a better result would be obtained with a stent instead of balloon angioplasty. Multiple stenting was defined as the use of more than one Palmaz-Schatz (15-mm) stent. Short stents were counted as a half stent. Biliary, disarticulated renal, and renal stents were counted as one stent each.

### Intravascular Ultrasound Equipment and Measurements

The majority of coronary arteries were imaged with a 3.9F monorail system with a 25-MHz transducer-tipped catheter (Interpret Catheter, InterTherapy/CVIS). A Cardiovascular Imaging System (CVIS) with a 2.9F catheter was used during the last 3 months of the study. Validation of quantitative measurements and pathological correlation with ultrasound measurements has been reported.<sup>23 24</sup> All images were obtained with a manual pullback system. The position of the catheter on fluoroscopy was used to correlate the ultrasound image with the angiogram. Data were stored on 0.5-in super VHS videotape. On-line quantitative measurements were performed during the procedure. The ultrasound catheter was advanced distal to the stent, and images were recorded while the imaging catheter was slowly pulled through the stented segment. The following measurements were made at the proximal or distal reference sites, generally within 5 to 10 mm of the stented segment: vessel cross-sectional area (CSA), vessel minimal and maximal diameters, lumen CSA, and lumen minimal and maximal diameters. The reference site measurements were made at sites that did not appear severely diseased on intravascular ultrasound image and that had a minimum of balloon trauma from prior balloon dilatation. Thus, these measurements were thought to be a reasonable and practical reflection of the true lumen or vessel size by intravascular ultrasound. The border of the vessel (as distinguished from the lumen) was defined on the ultrasound image as the outer boundary of the echolucent medium surrounding the plaque. Lumen measurements were made at the inner border of the echo-dense plaque. Intrastent lumen CSA and diameter measurements were made at the tightest position within the stent. The average of the proximal and distal vessel CSAs was used to estimate the vessel dimensions of the stented segment because intense echo reverberations from the metallic struts frequently prevented measurements of the vessel boundary beyond the stent. Intravascular ultrasound imaging was performed in the reference sites and in the stented segment at the initial intravascular ultrasound evaluation and after each series of balloon dilations. Measurements were made at the tightest point within the stented segment after each series of balloon dilations. The measurements at the reference site were done on the initial intravascular ultrasound evaluation to minimize the potential balloon dilation effect that might increase the dimensions of the reference site.

Interobserver and intraobserver reproducibility of minimum lumen diameter and lumen CSA measurements was retrospectively evaluated by linear regression analysis. Interobserver reproducibility was assessed by two ultrasound reviewers (S.N. and P.H.) performing blinded measurements of randomly selected stent sites (n=30) and reference segments (n=30). Intraobserver reproducibility was based on blinded measurements performed at a different time. The reproducibility of the measurements was reported as correlation coefficients $\pm$ SEE. Interobserver correlation coefficients for the minimum lumen diameter and lumen CSA measurements at the stent site were  $0.94\pm 0.14$  mm and  $0.97\pm 0.50$  mm<sup>2</sup>, and intraobserver correlation coefficients were  $0.96\pm 0.13$  mm and  $0.98\pm 0.43$  mm<sup>2</sup>. In reference segments, interobserver correlation coefficients of the minimum lumen diameter and lumen CSA measurements were  $0.93\pm 0.23$  mm and  $0.98\pm 0.64$  mm<sup>2</sup>, and intraobserver correlation coefficients were  $0.93\pm 0.23$  mm and  $0.99\pm 0.38$  mm<sup>2</sup>. Interobserver correlation coefficients for the reference minimum vessel diameter and vessel CSA were  $0.98\pm 0.16$  mm and  $0.99\pm 0.46$  mm<sup>2</sup>, and intraobserver correlation coefficients were  $0.98\pm 0.15$  mm and  $0.99\pm 0.38$  mm<sup>2</sup>. All probability values were significant to  $<.0001$ .

### Intravascular Ultrasound Criteria for Optimal Stent Expansion

The criteria for optimal stent expansion were governed by the principles of optimizing stent expansion and covering the full extent of the lesion so as to minimize any potential impairment to flow that could contribute to stent thrombosis. The first criterion was a qualitative evaluation of the stent site involving the achievement of good stent apposition to the vessel wall with good plaque compression. The second criterion was the achievement of a quantitative assessment of optimal stent expansion. During the course of the investigation, two quantitative criteria for stent expansion were used. For the majority of the lesions (n=339), 60% of the average of the proximal and distal CSAs was the target for defining intravascular ultrasound success.<sup>25</sup> This target criterion was initially chosen to accommodate the compensatory dilation that occurs with early atheroma deposition, an observation that has been made in both morphology and intravascular ultrasound investigations even in the angiographically normal reference site.<sup>23 26 27</sup> The quantitative criterion for optimal stent expansion was altered in the last 113 lesions so that the goal was to achieve an intrastent lumen CSA equal to or greater than the distal reference lumen CSA. The quantitative criterion for assessing optimal stent expansion was adjusted during the course of the investigation to simplify the criterion and because of the perceived overriding importance of not leaving the stent with a stenosis relative to the distal lumen rather than achieving a specified percent dilation relative to the reference vessel. A third (and equally important) ultrasound criterion was that the nonstented segments immediately adjacent to the stent (proximal or distal) did not reveal evidence of a significant lesion defined as a CSA stenosis  $>60\%$  relative to the adjacent reference lumen. This criterion was established in an attempt to apply a simple and consistent quantitative measurement that could be used to judge and treat lesions that were occasionally seen at the stent margin or in adjacent unstented segments. When a significant lesion was observed in these segments, angioplasty or, more commonly, stent implantation was performed. These lesions were categorized as residual plaque or fractured plaque. A final criterion involving the achievement of symmetrical stent expansion was also one of the initial criteria as previously reported but was never used independently of CSA measurements and was shown in previous intravascular ultrasound studies to not change significantly during stent optimization.<sup>22 25</sup> Thus, the use of this criterion was abandoned.

### Balloon Dilatation and Stent Implantation Strategy

The approach to stent expansion evolved during the study. In the initial 339 lesions, the balloon for final dilatations was sized close to the intravascular ultrasound vessel major diameter. The final stent balloon dilatations were performed with minimally compliant short balloons (generally the 9-mm Chubby, Schneider). This strategy translated into performing final balloon dilatations with balloons oversized by visual estimate of the angiogram. Moderate maximal inflation pressures (8 to 14 atm) were used in the first 40 lesions, and subsequently, high maximal inflation pressures ( $>14$  atm) were used for the final balloon dilatation. In the final 113 lesions, final stent dilatations were performed with a balloon more appropriately sized to the angiographic vessel diameter by visual estimate when inflated to high maximal pressures. In this phase, final balloon dilatations were performed with noncompliant balloons (NC Shadow, SCIMED Life Systems) inflated to pressures up to 20 atm.

### Angiographic Analysis

Coronary angiograms were analyzed without knowledge of the intravascular ultrasound data by experienced angiographers not involved in the stenting procedure. Patients received intracoronary nitroglycerin before baseline and final angiograms to achieve maximal vasodilation. To optimize reproducibility, the position of the x-ray gantry was recorded in all views at the time of the baseline angiograms, and final angiograms were done in matching views. Angiographic measurements were made during diastole. The lesions were measured with digital calipers (Brown and Sharp) from an optically magnified image in a single, matched "worst" view. The guiding catheter was used as the reference object for magnification calibration. Previous studies have shown that digital calipers correlate closely with computer-assisted methods, with a low interobserver and intraobserver variability.<sup>28 29</sup> Minimal lumen diameter and percent diameter stenosis were obtained on the baseline and final angiograms. The diameters of the proximal and distal lumen reference sites were averaged to obtain a mean reference diameter. The average reference diameter was used to calculate the percent diameter stenosis at baseline and final angiogram. The average reference diameter was used for these calculations to have a correlation with the proximal and distal measurements performed on intravascular ultrasound and also because the average reference vessel was thought to be a better reflection of the vessel size when multiple stents were placed in long segments that were of varying diameter. Lesion length was measured on baseline angiography from the point at which the lumen was compromised by 50% at the proximal or distal reference vessel site. Lesions were characterized according to the modified American College of Cardiology-American Heart Association (ACC/AHA) score.<sup>30</sup> The distance between lesions in the same vessel was measured. Tandem lesions were defined as lesions in the same vessel that were separated by  $<15$  mm. Long lesions were defined as a single continuous narrowing  $>15$  mm. The presence of large filling defects was noted at baseline or during the procedure. Thrombus was defined as a filling defect seen in multiple projections surrounded by contrast in the absence of calcification. TIMI grade flow was recorded at the time of the initial procedure to characterize the indication for stenting as previously described.<sup>31</sup> Angiographic findings such as the occurrence of dissection, vessel rupture, or side branch compromise were recorded and analyzed.

### Events

Major clinical events were considered death, emergency bypass surgery, elective bypass surgery, myocardial infarction (Q-wave or non-Q-wave), emergency repeat intervention (bail-out stenting or repeat angioplasty), and vascular complications. Specific major event definitions were as follows: Death was defined as any death irrespective of cause. A diagnosis of Q-wave myocardial infarction was made when there was documentation of new pathological Q waves ( $\geq 0.14$  seconds) on an ECG in conjunction with elevation of creatine kinase to greater than twice the upper limit of normal. A diagnosis of non-Q-wave myocardial infarction was defined as elevation of the cardiac enzymes to greater than twice the upper limit of normal

without the development of new pathological Q waves. Emergency coronary bypass surgery was defined as bypass surgery involving immediate transfer of the patient from the catheterization laboratory to the operating room. Elective coronary bypass surgery was defined as nonemergent bypass surgery performed more than 24 hours after a stent procedure for procedural failure in the absence of ischemia or evolving myocardial infarction. Acute thrombosis events were defined as angiographically documented occlusion with TIMI grade 0 flow at the stent site occurring within 24 hours of the stent procedure. Subacute thrombosis events were angiographically documented occlusions with TIMI grade 0 flow at the stent site occurring beyond 24 hours of the stent procedure. Emergency intervention was bail-out stenting or emergency angioplasty performed for ongoing acute ischemia or evolving myocardial infarction in the setting of an angiographically documented stent thrombosis event. Repeat angioplasty was nonemergency angioplasty performed for symptomatic restenosis. Vascular complications were defined as the occurrence of bleeding or hematoma formation at the access site requiring transfusion, vascular repair, or external compression.

Events were categorized as intraprocedural complications, postprocedure events that occurred during hospitalization (hospital events), events that occurred after hospital discharge up to 2 months (short-term posthospitalization events), and late events that occurred between 2 and 6 months of clinical follow-up. Cumulative events were reported at 6-month clinical follow-up. Intraprocedural and early postprocedural events were separated to evaluate the safety of the intravascular ultrasound-guided stent implantation procedure and to assess the efficacy of antiplatelet therapy without anticoagulation after a successful stent procedure.

### Postprocedure Medication Protocol

If the intravascular ultrasound criteria for optimal stent expansion were met and the angiographic result was also acceptable, no further heparin was administered and sheaths were removed in 4 to 6 hours. When procedures were performed in the evening, heparin was infused overnight and the sheaths were removed the following morning. The first 252 patients to complete a successful Palmaz-Schatz stent procedure received ticlopidine 250 mg PO BID for 2 months (the first 150 patients) or 1 month (subsequent 102 patients). Patients who had not received ticlopidine before the stent procedure also received aspirin 325 mg/d for 3 to 5 days. The last 69 consecutive patients in this cohort were treated only with aspirin 325 mg BID.

Patients who did not have intravascular ultrasound performed, patients who had an attempted but unsuccessful intravascular ultrasound evaluation, and patients who had a final suboptimal intravascular ultrasound performed were treated with a standard postprocedure anticoagulation and antiplatelet regimen. In these patients, at the completion of the stent procedure, the heparin was discontinued briefly to allow for sheath removal, then reinstated within 4 to 6 hours. Warfarin was initiated on the day of the procedure, and both heparin and warfarin were continued until the prothrombin time was  $>16$  (international normalized ratio, 2.0 to 3.5), after which the heparin was stopped. Starting on the day of the procedure, these patients received aspirin 325 mg/d indefinitely but did not receive dextran or dipyridamole.

### Follow-up

In the first 2 months of this protocol (first 60 patients), patients were observed in the hospital for 7 to 10 days. Subsequently, patients were discharged from the hospital within 2 days. This was done so that an evaluation of the safety and efficacy of short hospitalizations after stent implantation could also be performed. The short-term complications (stent thrombosis) continued to be carefully assessed with regular and uniform contact of all patients within 4 weeks of hospital discharge and at 2 months. Late clinical follow-up was performed at 6 months.

### Statistics

Normally distributed data are expressed as mean $\pm$ SD. Data that are not normally distributed are expressed as a median with a range of values. Comparisons between equivalent groups were performed by paired Student's *t* test. Subgroup comparisons of discrete variables were made by  $\chi^2$  analysis. Differences were considered statistically significant at  $P<.05$ . Intraobserver and interobserver reproducibility of minimum lumen diameter and lumen CSA measurements were evaluated by linear regression analysis.

## Results

### Patient, Angiographic, and Procedural Characteristics

The clinical characteristics and indications for use of a stent in the 359 patients undergoing Palmaz-Schatz stent implantation are shown in Table 1<sup>↵</sup>. The majority of stent procedures were performed electively (67%). Angiographic and procedural characteristics are presented in Table 2<sup>↵</sup>. A total of 452 lesions were treated in 398 vessels. A total of 864 stents were implanted. Multiple stents were implanted in 180 of 452 lesions (40%), in 196 of 398 vessels (49%), and in 199 of 359 patients (55%). The mean number of stents per lesion was  $1.51\pm 0.98$  (range, 0.5 to 9 stents per lesion), per vessel  $1.72\pm 1.14$ , and per patient  $1.8\pm 1.17$ . A single short stent was placed in 36 lesions (8%). A single Palmaz-Schatz stent (one Palmaz-Schatz or two short stents) was placed in 234 lesions (52%). One Palmaz-Schatz stent and one short stent were deployed in 50 lesions (11%). Two or more Palmaz-Schatz stents were implanted in 132 lesions (29%).

**Table 1.**

Baseline Clinical Characteristics and Indications for Stenting

View this table:  
In this window In a new window

**Table 2.**

Angiographic and Procedural Characteristics

View this table:  
In this window In a new window

### Procedural Success

Between March 30, 1993, and January 1, 1994, a total of 359 consecutive patients with 452 lesions underwent intracoronary stent implantation. After stent deployment and angiographic optimization, initial stent implantation was successful in 347 patients (96.6%) and in 438 lesions (96.9%), as shown in Fig 1. Before intravascular ultrasound imaging, stent implantation was unsuccessful in 12 patients (3.3%) with 14 lesions (3.1%). After initial stent implantation success, there were 9 patients (2.6%) with 13 lesions (2.9%) that did not have intravascular ultrasound performed for technical reasons, and intravascular ultrasound was unsuccessful in 3 patients (0.8%) with 5 lesions (1.1%). Of the 420 lesions in 335 patients that were imaged by intravascular ultrasound, optimal stent expansion was observed in 127 lesions (30%) on the initial ultrasound evaluation. After intravascular ultrasound-guided stent site optimization, a final optimal ultrasound result was achieved at the stent site on 402 lesions (96%) in 321 patients (96%). With increased experience and the change in the criteria for success, the percent of lesions in which there was adequate stent expansion at the initial intravascular ultrasound increased from 12% in the first 100 lesions to 60% in the last 113 lesions. During the process of intravascular ultrasound-guided optimization, stent failure with major complications occurred in an additional 6 patients (1.7%) with 8 lesions (1.7%). There were 8 patients (2.2%) with 10 lesions (2.2%) who had a suboptimal stent result at the final intravascular ultrasound evaluation. The 321 patients who had adequate stent expansion by intravascular ultrasound criteria were treated with antiplatelet medications and did not receive additional anticoagulation (heparin or warfarin). During the 2-month short-term clinical follow-up, there were three stent thrombosis events in the 321 patients (0.9%) with 399 lesions (0.7%) treated only with antiplatelet therapy and no anticoagulation. The short-term clinical follow-up was done in all patients at 2 months. An additional two stent occlusions (0.6%) were documented at angiographic follow-up at 3 and 4 months. These occlusions were associated with angina recurrence but not clinical events.

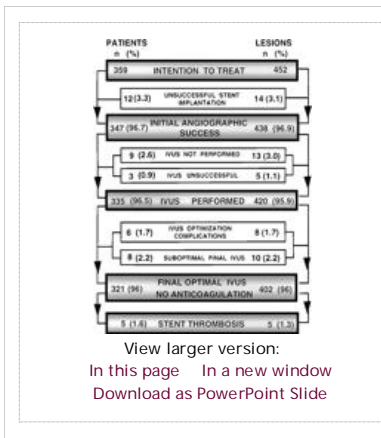


Figure 1.

Flow diagram depicting patient and lesion primary stent success, patients and lesions undergoing intravascular ultrasound (IVUS)-guided stenting, and patients who did not have anticoagulation after the stent procedure.

A total of 20 patients (5.6%) were treated with a standard anticoagulation regimen consisting of short-term heparin, warfarin for 2 months, and aspirin indefinitely. This group included the 9 patients who did not have intravascular ultrasound guidance, the 3 patients who had an attempted but unsuccessful intravascular ultrasound procedure, and the 8 patients who had a final intravascular ultrasound that revealed suboptimal stent expansion. These patients did not have any clinical or angiographically documented stent thrombosis events.

**Unsuccessful Stent Implantation and Intraprocedural Events**

The stent implantation procedure was unsuccessful in 18 patients (5.0%). Two of the procedures were unsuccessful without clinical events. Unsuccessful stent implantation associated with a major event occurred in 16 patients (4.5%), as shown in Table 3. In these 16 patients, myocardial infarction occurred in 11 patients (3.1%), only 5 of whom had Q-wave myocardial infarctions (1.4%). Emergency bypass was necessary in 11 patients (3.1%) and elective bypass in 2 patients (0.6%). Three patients (0.8%) died during the procedure. The timing of the 18 unsuccessful stent implantation procedures relative to the intravascular ultrasound imaging is illustrated in Fig 1. Unsuccessful stent implantations associated with major clinical events were due to unsuccessful stent delivery in 5 patients (1.4%) and occurred after successful stent delivery to the lesion site in 11 patients (3.1%), as shown in Fig 2. Unsuccessful stent delivery was due to incomplete lesion coverage in 3 patients, left main dissection before stent delivery in 1 patient, and left anterior descending artery dissection that occurred during stent delivery into an angulated circumflex in 1 patient. Causes of complications after successful stent delivery included distal embolization in a degenerated vein graft in 1 patient and dissection from the intravascular ultrasound catheter in one patient. After successful stent delivery, stent site optimization complications were nonocclusive dissections in 4 patients (1.1%), coronary vessel rupture in 4 patients, and side branch compromise during stent optimization in 1 patient.

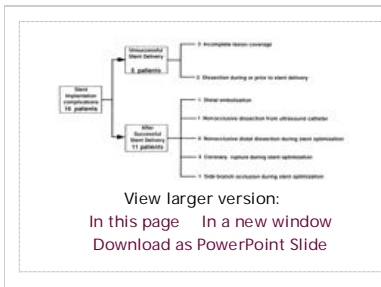


Figure 2.

Flow diagram depicting angiographic findings in unsuccessful stent implantation procedures associated with major events.

Table 3.

Intraprocedural, Hospital, Early Posthospitalization (≤2 Months), Late (2 to 6 Months), and Cumulative Events at 6-Month Follow-up

View this table:  
[In this window](#)   [In a new window](#)

### Early Postprocedural Events

Early postprocedural hospital events occurred in 4 patients (Table 3<sup>↑</sup>). Two patients had acute thrombosis events at the stent site 3 hours and 12 hours after the stent procedure. Both of these events were associated with Q-wave myocardial infarctions. One of the acute occlusions occurred in the vessel with slow flow related to a prestent coronary Rotablator procedure. The second acute thrombosis event was the result of a vessel closure distal to a patent stent that had preserved flow into a large side branch. While not strictly a stent thrombosis, the occlusion was counted as an acute thrombosis event because the distal dissection was a result of the stent implantation procedure. This patient underwent bailout stent implantation, which restored vessel patency and hemodynamic stability before emergency coronary bypass surgery. One other non-Q-wave myocardial infarction occurred in the postprocedure hospitalization period that was not due to stent thrombosis. This patient had undergone a combined Rotablator and stent procedure and returned to the catheterization laboratory for angiographic evaluation of an asymptomatic cardiac enzyme elevation. Angiographic and intravascular ultrasound evaluations revealed a patent stent site and no evidence of thrombus. This non-Q-wave myocardial infarction event was considered an embolic event related to a prestent Rotablator procedure.

After the procedure, there were one vascular complication and one death, in the same patient. This patient underwent multiple percutaneous interventions and vascular surgical repairs for lower-extremity ischemia, developed rhabdomyolysis and renal failure, and died 17 days after the stent procedure of multiorgan failure and sepsis.

Short-term clinical follow-up was obtained in all patients at 2 months. During the 2-month short-term clinical follow-up period after hospital discharge, there was one subacute stent thrombosis event (Table 3<sup>↑</sup>). The event occurred 8 days after the stent procedure and was associated with a non-Q-wave myocardial infarction. The occlusion was reopened, an additional bailout stent was placed at the site of a distal dissection, and the patient continued on antiplatelet therapy.

### Late Events

Long-term follow-up was obtained in 351 patients (98%). Late events between 2 and 6 months occurred in 57 patients (16%), as shown in Table 3<sup>↑</sup>. The majority of these events were repeat angioplasty, performed in 47 patients (13.1%) for symptomatic restenosis. A total of 8 patients (2.2%) underwent nonemergency coronary bypass during the late follow-up period. Myocardial infarction during the late follow-up was observed in 5 patients (1.4%). There were 3 deaths during the late follow-up period, and all were cardiac related. One death occurred after a large inferior myocardial infarction in a patient 5.5 months after stent implantation in the left anterior descending artery. An angiogram performed 3 weeks before the death revealed a patent left anterior descending artery stent and moderate diffuse disease in the right coronary artery but no evidence of a critical lesion. A second late death was a witnessed in-hospital ventricular fibrillation event 4 months after the procedure. The patient had a history of ischemic cardiomyopathy and refractory ventricular arrhythmias. The third late death also occurred in a patient with ischemic cardiomyopathy due to refractory congestive heart failure without evidence of ischemia.

### Angiographic Analysis

As shown in Table 4<sup>↓</sup>, the baseline proximal reference vessel diameter was  $3.3\pm 0.53$  mm. The baseline distal reference vessel was  $3.06\pm 0.56$  mm. The baseline average (of proximal and distal) reference vessel diameter was  $3.18\pm 0.53$  mm. The reference vessel diameter after the stent procedure was not significantly different. Baseline minimum lumen diameter was  $0.94\pm 0.57$  mm, with a baseline percent diameter stenosis of  $71\pm 16\%$ . The final stent diameter was  $3.39\pm 0.53$  mm, with a mean final percent stenosis of  $-7\pm 16\%$ . Mean lesion length was  $9.5\pm 6.7$  mm. The median length of the lesions was 7.6 mm (range, 1.2 to 39 mm). The results were achieved with a mean pressure of  $14.9\pm 3.0$  atm and a balloon-to-vessel ratio of  $1.17\pm 0.19$ .

**Table 4.**

Quantitative Angiographic Measurements

View this table:  
[In this window](#) [In a new window](#)

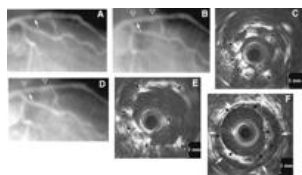
Qualitative angiographic assessment revealed other information on the effect of high-pressure balloon dilatation. Transient side branch occlusion during the stent procedure occurred in 15 lesions (3.3%). These transient occlusions usually resolved with the administration of intracoronary nitroglycerin but sometimes required balloon dilatation. All had resolved at the end of the stent procedure and were not associated with major events. Vasospasm was noted more prominently during the procedure when high pressures, >15 atm, were used for final balloon dilation. This phenomenon was self-limiting, always resolved with time or after high doses of intracoronary nitroglycerin, and was not associated with any unfavorable clinical events.

### Intravascular Ultrasound Analysis

Table 5<sup>↓</sup> shows the intravascular ultrasound measurements. The mean lumen CSA at the tightest point within the stent increased 26%, from  $6.5\pm 2.0$  mm<sup>2</sup> at the initial intravascular ultrasound to  $8.8\pm 2.5$  mm<sup>2</sup> at the final intravascular ultrasound ( $P<.0001$ ). The tightest intrastent lumen area relative to the reference area expanded from  $49\pm 13\%$  at the initial intravascular ultrasound to  $66\pm 13\%$  at the final intravascular ultrasound ( $P<.0001$ ). The minor stent lumen diameter increased from  $2.7\pm 0.5$  to  $3.1\pm 0.5$  mm ( $P<.0001$ ), and the major stent diameter increased from  $3.1\pm 0.5$  to  $3.5\pm 0.5$  mm between the initial and final intravascular ultrasound ( $P<.0001$ ). A mean of  $2.4\pm 1.2$  ultrasound evaluations were performed per lesion. Examples of suboptimal stent expansion with subsequent intravascular ultrasound-guided stent optimization are shown in Figs 3<sup>↓</sup> and 4<sup>↓</sup>.

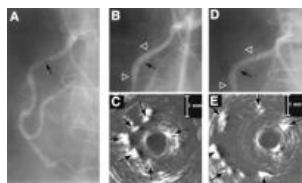
**Figure 3.**

Example of intravascular ultrasound-guided coronary stent implantation. A, Baseline angiogram of a left anterior descending artery with a proximal stenosis (arrow). B, Angiogram after stent deployment (between open white triangles) and initial dilatation with 3.5-mm balloon



View larger version:  
[In this page](#) [In a new window](#)  
[Download as PowerPoint Slide](#)

at 11 atm shows a slight residual stenosis proximal to the original lesion (white arrow). C, Initial intravascular ultrasound image at this site (white arrow in B) after dilatation with 3.5-mm balloon at 11 atm reveals an underdilated stent. Stent struts are marked with black-and-white arrows, and guide wire artifact is noted by an asterisk. The central black circle corresponds to the ultrasound catheter, which is surrounded by a white echogenic circle from the plastic sheath. The lumen is echolucent. D, Final angiogram after further balloon dilatation with 3.5-mm balloon inflated to 15 atm. E, Final intravascular ultrasound image at same site (white arrow in D) after dilatation with a 3.5-mm balloon at 15 atm. The stent cross-sectional area (CSA) increased from 4.6 to 11.7 mm<sup>2</sup>, with corresponding improvements in the minor lumen diameter (from 2.2 to 4.2 mm) and the major lumen diameter (from 2.5 to 4.5 mm). F, The distal reference vessel site shows a well-delineated lumen (black arrows) and media (white arrows). The initial stent CSA of 4.6 mm<sup>2</sup> was smaller than the distal lumen CSA of 8.5 mm<sup>2</sup>. After further high-pressure dilatation, the stent CSA increased to 11.7 mm<sup>2</sup>, and the stenosis relative to the distal lumen was obliterated.



View larger version:  
[In this page](#) [In a new window](#)  
[Download as PowerPoint Slide](#)

**Figure 4.**

A, Baseline angiogram demonstrates a proximal right coronary artery stenosis (arrow). B, Angiogram after dilation of a Palmaz-Schatz stent (white triangles) with a 3.5-mm noncompliant balloon inflated to 10 atm. Black arrow denotes a slight indentation in the stent. C, Intravascular ultrasound image obtained at the site of the black arrow in B shows an underexpanded stent with a cross-sectional area of 3.1 mm<sup>2</sup>. Stent struts are demarcated by black-and-white arrows and the guide wire with an asterisk. D, Angiogram after final dilatation of the stent (between the white triangles) with a 3.5-mm noncompliant balloon inflated to 15 atm reveals minimal angiographic improvement. E, Subsequent intravascular ultrasound image recorded from the same site (black arrow in D). The Palmaz-Schatz stent struts are well visualized (black-and-white arrows), and the stent is now well expanded, with an intrastent cross-sectional area of 9.3 mm<sup>2</sup>, a 66% increase from the initial intravascular ultrasound image.

**Table 5.**

Quantitative Intravascular Ultrasound Measurements

View this table:  
[In this window](#) [In a new window](#)

Intravascular ultrasound evaluation of the artery segments adjacent to the stent revealed that 73 of the 419 lesions (17%) had significant luminal encroachment of >60% relative to the reference lumen. The lumen CSA of these lesions was 3.8±1.9 mm<sup>2</sup>. Additional stents were inserted at these stenoses to reduce potential flow limitations in the stented artery. These lesions at the stent margins were identified as residual plaque (57 lesions) or, less commonly, fractured plaque (16 lesions).

#### Effect of Balloon Dilatation Strategy

The oversize and appropriate-size final balloon dilatation strategies that were used sequentially during the study are summarized in Table 6↓. The reference artery diameters were similar with the two balloon dilatation strategies. The use of larger balloons in the oversize dilatation strategy is reflected by the balloon-to-vessel ratio of 1.20±0.19, in contrast to the balloon-to-vessel ratio of 1.05±0.14 when appropriate-size balloons were used for final dilatation ( $P<.0001$ ). The maximal balloon inflation pressure (in atmospheres) when final dilatations were performed with oversize balloons was 14.7±2.9, compared with a maximal pressure of 15.7±3.1 when appropriate-size balloons were used for final dilatations ( $P<.0001$ ). The effect that the different balloon dilatation strategies had on stent expansion is demonstrated by both the final stent minimum lumen diameter and the final percent diameter stenosis. The final stent minimum lumen diameter decreased from 3.44±0.54 mm when the oversize balloon dilatation strategy was used to 3.2±0.47 mm in the final phase ( $P<.0001$ ). The mean final percent stenosis of -9±15% when oversize balloons were used for final dilatations is a clear reflection of the overdilatation effect with the oversize balloon dilatation strategy and was in contrast to the final percent stent stenosis of 1±10% when appropriate-size balloon were used for final stent dilatations. With the change in dilatation strategy, there was a reduction of intraprocedural complications from 5.7% to 1% ( $P=.04$ ). There were four coronary vessel ruptures (1.2%) when oversize balloons were used for final dilatations, and this decreased to 0% when appropriate-size balloons were used for final dilatation ( $P=NS$ ). There was no significant change in the stent thrombosis events when oversize balloons were used (0.8%) and when appropriate-size balloons were used (1.0%).

**Table 6.**

Angiographic Results and Complications With Different Dilatation Strategies

View this table:  
[In this window](#) [In a new window](#)

#### Effect of Antiplatelet Therapy

In the 252 patients treated with ticlopidine, there were two acute stent thromboses (0.8%). In the 69 patients treated with aspirin alone after the stent procedure, there was one subacute stent thrombosis (1.4%). There was no significant difference between the stent thrombosis rates between the ticlopidine and the aspirin treatment groups. Side effects that precipitated medication discontinuation were more frequent with ticlopidine than with aspirin. Ticlopidine was stopped for minor complications of skin rash or gastrointestinal disturbances within 2 weeks of the stent insertion in 5



patients. Neutropenia was documented in 2 patients and was reversible after the medication was stopped. These 7 patients were continued on aspirin after the ticlopidine was discontinued. There were no adverse medication effects in the 69 patients treated with aspirin.

## Discussion

The results of this nonrandomized study on patients undergoing intravascular ultrasound-guided intracoronary stent implantation indicate that anticoagulation can be safely withheld when adequate stent expansion is achieved and flow optimized in the stented and adjacent inflow and outflow segments. These findings represent a departure from previous doctrine regarding coronary stents and suggest an alternative approach that may eliminate the need for anticoagulation, with reduction in hospital stay and vascular complications.

### Comparison With Other Studies

Large multicenter studies on patients undergoing elective stenting have reported an incidence of stent thrombosis of 3% to 4%.<sup>6 15 16 17</sup> Hospital or early complications included a 3% incidence of Q-wave myocardial infarction, a 2% to 3% rate of non-Q-wave myocardial infarction, and a 2% to 3% need for bypass surgery.<sup>15 16</sup> When stenting is performed for bailout or emergency indications, stent thrombosis and major complication rates are higher.<sup>1 2 19 20</sup> The incidence of stent thrombosis is 8% to 16%, with a 6% to 21% rate of myocardial infarction, a 4% to 13% need for emergency bypass surgery, and a 2% to 4% incidence of death.<sup>1 2 19</sup> Although stents decrease morbidity of acute closure,<sup>1 2</sup> lower the incidence of major hospital or early events, and reduce restenosis rates compared with angioplasty-treated groups,<sup>15 16</sup> the potential benefit of stent implantation is, unquestionably, lost in patients with stent thrombosis.

Vascular access complications and bleeding associated with a stringent anticoagulation regimen further increase the morbidity of the stenting procedure. The reported incidence of access site complications requiring vascular repair is 4% to 10%.<sup>2 5 6 16 19</sup> The combined rate of vascular complications and bleeding complications at the access site or other sites that require transfusions varies considerably, from 7% to 20%.<sup>1 2 5 15 19</sup>

In the present study, stent insertion was performed for a variety of indications but was frequently performed electively. Lesion anatomy was complex in this cohort, as reflected by the 16% of lesions >15 mm, the 14% of tandem lesions, the 26% of lesions that were stented in angiographically small vessels (<3 mm), the high percentage of complex lesion morphology (modified AHA/ACC lesion types B<sub>2</sub> or C), and the 3% of lesions with large filling defects consistent with thrombus. Despite the high complexity in this nonselected cohort of patients, the overall clinical success and complication rates compare favorably with those reported for elective or single stent deployment and those reported for the indications of acute or threatened closure.

As with prior studies, intravascular ultrasound was important in assessing adequate stent expansion, which was frequently underestimated by angiography.<sup>21 22</sup> The most frequent site of potential flow limitation was within the stented segment. After intravascular ultrasound-guided repeat dilatations, the intrastent lumen CSA was significantly enlarged, from 6.5 to 8.8 mm<sup>2</sup>, *P*<.0001. With this approach, stent thrombosis was rare despite the absence of anticoagulation.

The primary focus of the present study was a short-term assessment of the safety of stent implantation without subsequent anticoagulation after intravascular ultrasound confirmation. The novelty of the approach that combines both improved stent expansion and the use of multiple stents for full lesion coverage also warranted a long-term assessment of outcome. Despite the complexity of the patients in this cohort, the 6-month event rate is only slightly higher than the event rates reported in multicenter trials on single stent implantation.<sup>15 16</sup> The procedural complications in the early experience and the inclusions of patients with low ejection fraction contribute to the cumulative high death rate reported at 6 months.

### Intravascular Ultrasound-Guided Stenting

By study design, intravascular ultrasound imaging was first performed after an initially successful angiographic result with <20% residual stenosis by visual analysis was obtained. Despite the angiographic appearance, measurements at the initial intravascular ultrasound study suggested that further dilatation was necessary in the majority of cases. The diameter and CSA of the stent lumen were enlarged significantly after repeat dilatation. Analysis of the intravascular ultrasound data provided other important information in evaluating the effect of various balloon dilatation strategies. The intravascular ultrasound data illustrated the overdilatation effect from the oversize balloon strategy. Balloons that were sized to the intravascular ultrasound vessel diameter (angiographically oversized) were used for final balloon dilatations in the majority of the stent implantation procedures. This strategy was initially used to maximize protection against stent thrombosis in a large, unselected, and consecutive series of patients who were undergoing stent implantation without subsequent anticoagulation for the first time. Although protective against stent thrombosis, this strategy came with the price of a high procedural complication rate and an unacceptable incidence of intracoronary vessel rupture. The experience gained from intravascular ultrasound imaging together with an evaluation of clinical results affected the choice of balloon size and inflation pressures. As the study progressed, balloons selected on the basis of angiographic vessel size and higher pressures were used to provide adequate expansion within the stented segment. With the adjustment in the balloon dilatation strategy, the final stent expansion was more appropriate relative to the reference vessel measurements. This resulted in a lower intraprocedural complication rate but did not increase the incidence of stent thrombosis.

### Full Lesion Coverage and Use of Multiple Stents

Intravascular ultrasound identified lesions in the adjacent unstented segments that were poorly visualized on angiogram. Typically, the angiogram at the corresponding site would reveal an area of ill-defined haziness without stenosis, a discrete stenosis <20%, and less commonly, no evidence of a lesion. The decision to treat the lesions at the stent margins based on a quantitative assessment of their severity by intravascular ultrasound was in keeping with a practice of covering the full extent of the lesion. Both intravascular ultrasound and pathology reports have shown that angiography underestimates the severity of coronary disease.<sup>22 23 26 27 32</sup> In some instances, intravascular ultrasound imaging was also valuable in assisting in the decision not to deploy stents to lesions at the stent margins. The lesions that were stented tended to be in angiographically small vessels in which the lesions were more likely to encroach on the intravascular ultrasound catheter and in which the risk for stent thrombosis was perceived to be higher. In the majority of these lesions, the lumen CSA was <5 mm<sup>2</sup>.

Previous stent investigations have identified residual lesions and dissections after stent implantation as a major cause of subsequent early

thrombotic events.<sup>2 33 34 35 36 37 38</sup> Residual lesions (or dissections) after stent implantation are due either to a failure to cover the distal extent of a lesion or to the balloon dilatation process after successful stent deployment to the appropriate lesion site. In the present study, the use of more than one stent, when necessary, to achieve full lesion coverage may also be an important reason for the low incidence of stent thrombosis. The low incidence of stent thrombosis also demonstrates that the use of multiple stents for full lesion coverage is a safe strategy to use despite the lack of anticoagulation after the stent procedure.

### Angiographic Versus Ultrasound Assessment

Well-defined angiographic criteria for successful stent expansion that alleviates the risk of stent thrombosis and the need for anticoagulation have not been developed. There is a limit to visual interpretation of small percent stenosis differences on the angiogram. It is arguable that careful on-line quantitative angiographic measurements could better determine angiographic success similar to the results achieved with intravascular ultrasound. The experience of this study showed that indentations in the balloon profile or angiographic mismatch between the measured and chosen balloon diameters correspond to inadequate stent expansion as documented by intravascular ultrasound. Empirical high-pressure balloon inflations with an appropriate-size noncompliant balloon may increase the number of patients who will have acceptable stent expansion. In the present study, high-pressure balloon inflations have increased the percentage of patients who achieved adequate stent expansion at the initial intravascular ultrasound evaluation from 12% to 60%. Despite this aggressive inflation approach, 40% of the stents with an acceptable angiographic result still required additional dilatation with higher pressures or, less commonly, a dilatation with a larger balloon. The angiographic method of determining stent expansion has inherent limitations of a one-dimensional assessment of percent diameter stenosis. In contrast, intravascular ultrasound cross-sectional imaging from within the lumen of the stent is a reliable method of confirming adequate stent expansion with a degree of security that allows anticoagulation to be eliminated from the poststent medical regimen.

### Antiplatelet Therapy

In this study, the majority of patients were treated with ticlopidine after stent insertion. In this group, there were two stent thrombosis events (0.8%). In the group treated with aspirin, there was one stent thrombosis event (1.4%) ( $P=NS$ ). The two late stent occlusions occurred with the patients on aspirin (started after 1 to 2 months of ticlopidine therapy). The lack of difference in the stent thrombosis rates suggests that the achievement of adequate stent expansion and good flow in adjacent segments is a more important variable in the prevention of stent thrombosis than the specific antiplatelet agent. A randomized comparison may better determine whether small differences in efficacy exist between the two antiplatelet agents.

### Study Limitations

One limitation was the absence of computerized quantitative coronary angiographic analysis. Another important methodological weakness was the lack of a consistent intravascular ultrasound criterion and balloon dilatation strategy. The change in the quantitative intravascular ultrasound criterion was based on knowledge gained during the course of the investigation and reflects an adjustment to a simplified criterion that is easier to achieve and may have more physiological meaning in terms of the prevention of stent thrombosis. After the initial experience showed a low stent thrombosis rate, balloon dilatation strategies were also adapted in an attempt to reduce intraprocedural complications, which were unacceptably high. The evolving balloon dilatation strategy, however, significantly decreases the sample size for each phase and creates difficulties in discerning differences for low event rate complications such as stent thrombosis and coronary vessel rupture. Postprocedure complications associated with prestent rotational atherectomy contributed to two of the early postprocedural events. Although the Rotablator has utility in the treatment of lesions that resist dilatation, cautious use of this device may be warranted in the patient in whom stent implantation is anticipated. Short-term heparin for 24 hours may also be appropriate in this select situation.

One drawback to the technique of using intravascular ultrasound to assess the adequacy of stent expansion and lesion coverage is the increased number of stents and balloons and a longer procedure time. A more accurate analysis of the overall cost of the technique, however, should weigh the expense of increased procedural resources together with an evaluation of the savings from a decrease in postprocedural complications, a reduction in hospital stay, and the elimination of laboratory costs associated with monitoring anticoagulation regimens. The use of balloon delivery systems that incorporate a high-pressure balloon for the initial stent deployment would further reduce procedural costs and might also decrease dissections at stent margins that are due to balloon misplacement when stents are not visible.

The results of the study apply primarily to patients undergoing elective stent implantation, since the majority of patients underwent stent insertion for nonemergent indications. It is encouraging, however, that there were no stent thromboses in 21 consecutive patients who underwent emergency Palmaz-Schatz stent implantation despite not having postprocedural anticoagulation. Whether there is an absolute requirement of intravascular ultrasound to confirm stent expansion before treatment only with antiplatelet therapy was not addressed in the present investigation. A randomized, multicenter trial would perhaps best answer this issue in view of the important clinical and economic ramifications.

### Conclusions and Future Directions

On the basis of these observations, it is reasonable to conclude that the Palmaz-Schatz stent can be deployed in coronary arteries with a low rate of thrombosis provided that stent expansion is adequate and there are no other flow-limiting lesions present. If high-pressure stent dilatation, treatment of the entire lesion, and intravascular ultrasound documentation of optimal stent expansion and lesion coverage are used, anticoagulation can be safely omitted after the procedure. This strategy should facilitate the expanded use of stents to provide the benefit of decreased restenosis while simultaneously reducing the cost and complications associated with stent insertion.

### Acknowledgments

This study was supported in part by National Institutes of Health grant 5-RO1-HL-45077-03.

### Footnotes

Presented in part at the 66th Scientific Sessions of the American Heart Association, Atlanta, Ga, November 8-11, 1993, and the American College of Cardiology Meeting, March 1994.

Received August 2, 1994.  
Revision received October 3, 1994.  
Accepted October 24, 1994.

Copyright © 1995 by American Heart Association

## References

1. George BS, Voorhees WD, Roubin GS, Fearnot NE, Pinkerton CA, Raizner AE, King SR, Holmes DR, Topol EJ, Kereiakes DJ, Hartzler GO. Multicenter investigation of coronary stenting to treat acute or threatened closure after percutaneous transluminal coronary angioplasty: clinical and angiographic outcomes. *J Am Coll Cardiol*. 1993;22:135-143. [Medline](#)
2. Roubin GS, Cannon AD, Agrawal SK, Macander PL, Dean LS, Raylev WA, Breland J. Intracoronary stenting for acute or threatened closure complicating percutaneous transluminal coronary angioplasty. *Circulation*. 1992;85:916-927. [Abstract/FREE Full Text](#)
3. Serruys PW, Strauss RH, Reatt KI, Bertrand ME, Puel J, Rickards AE, Meier B, Guy L-L, Vont P, Kannerberger JK, Sigwart U. Angiographic follow-up after placement of a self-expanding coronary-artery stent. *N Engl J Med*. 1991;324:13-17. [CrossRef](#) [Medline](#)
4. Strauss RH, Serruys PW, de Scheerder IK, Tiessen IGP, Bertrand ME, Puel J, Meier B, Kaufmann H, Stauffer LC, Rickards AF, Sigwart U. Relative risk analysis of angiographic predictors of restenosis within the coronary wall stent. *Circulation*. 1991;84:1636-1643.
5. Carrozza JP, Kuntz RF, Levine MI, Pomerantz RM, Fishman RF, Mansour M, Gibson CM, Senerchia CC, Diver DJ, Safian RD, Baim DS. Angiographic and clinical outcome of intracoronary stenting: immediate and long-term results from a large single center experience. *J Am Coll Cardiol*. 1992;20:328-337. [Medline](#)
6. Schatz RA, Goldberg S, Leon M, Baim D, Hirshfeld J, Cleman M, Ellis S, Topol E. Clinical experience with the Palmaz-Schatz coronary stent. *J Am Coll Cardiol*. 1991;17:155B-1559B.
7. Detre KM, Holmes DR, Holubkov P, Cowley MJ, Bourassa MG, Faxon DP, Dorros GO, Bentivoglio LG, Kent KM, Myler RK. Incidence and consequences of periprocedural occlusion: the 1985-1986 National Heart, Lung, and Blood Institute percutaneous transluminal coronary angioplasty registry. *Circulation*. 1990;82:739-750. [Abstract/FREE Full Text](#)
8. Simpfendorfer C, Belardi J, Bellamy G, Galan K, Franco I, Hollman J. Frequency management and follow-up of patients with acute occlusion after percutaneous transluminal coronary angioplasty. *Am J Cardiol*. 1987;59:267-269. [CrossRef](#) [Medline](#)
9. Sinclair IM, Melaha CH, Sinnerly ME, Baim DS. Predictors, therapeutic options and long-term outcome of abrupt reclosure. *Am J Cardiol*. 1988;61:61G-66G. [CrossRef](#) [Medline](#)
10. Popma JJ, Topol EJ. Factors influencing restenosis after coronary angioplasty. *Am J Med*. 1990;88:16N-24N. [Medline](#)
11. Serruys PW, Luitjen HF, Reatt KI, Geuskens R, de Feuter PL, van den Brand M, Reiber IH, ten Katen HJ, van Es GA, Hugenholtz PG. Incidence of restenosis after successful coronary angioplasty: a time related phenomenon: a quantitative angiographic study in 342 consecutive patients at 1, 2, 3 and 4 months. *Circulation*. 1988;77:361-371. [Abstract/FREE Full Text](#)
12. Califf RM, Fortin DE, Frid DJ, Haarlan WP, Ohman EM, Bengtson JR, Nelson CL, Tchong JE, Mark DB, Stack RS. Restenosis after coronary angioplasty: an overview. *J Am Coll Cardiol*. 1991;17:2B-13B.
13. Nobuyoshi M, Kimura T, Nosaka H, Minka S, Hano K, Yokoi H, Hamaoka N, Horiuchi H, Ohishi H. Restenosis after successful percutaneous transluminal coronary angioplasty: serial angiographic follow-up of 229 patients. *J Am Coll Cardiol*. 1988;12:616-623.
14. Platko WP, Hollman J, Whitlow PL, Franco I. Percutaneous transluminal angioplasty of saphenous vein graft stenosis: long term follow up. *J Am Coll Cardiol*. 1989;14:1645-1650. [Medline](#)
15. Serruys PW, de Jaegere P, Kiemeneij F, Macaya C, Rutsch W, Heyndrickx G, Emanuelsson H, Marco J, LeGrand V, Materne P, Belardi J, Sigwart U, Colombo A, Guy L-L, van den Huevel P, Delcan I, Moral MA, for the Benestent Study Group. A comparison of balloon expandable stent implantation with balloon angioplasty in patients with coronary artery disease. *N Engl J Med*. 1994;331:489-495. [CrossRef](#) [Medline](#)
16. Fisch D, Colombo A, Leon MR, Baim D, Schatz RA, Penn I, Detre K, Savage MP, Veltri L, Ricci D, Nobuyoshi M, Cleman M, Heuser P, Almond D, Teirstein P, Fish D, Colombo A, Brinker H, Moses J, Hirshfeld J, Raylev S, Ellis S, Pake R, Goldberg S. A randomized comparison of coronary stent placement and balloon angioplasty in the treatment of coronary artery disease. *N Engl J Med*. 1994;331:496-501.
17. Schatz RA, Baim DS, Leon M, Ellis SG, Goldberg S, Hirshfeld JW, Cleman MW, Cabin HS, Walker C, Stagg J, Buchbinder M, Teirstein PS, Topol E, Savage M, Paraz JA, Curry RC, Whitworth H, Sousa IE, Tin E, Almagor Y, Ponder R, Penn IM, Leonard B, Levine SJ, Fish RD, Palmaz JC. Clinical experience with the Palmaz-Schatz coronary stent: initial results of a multicenter study. *Circulation*. 1991;83:148-161. [Abstract/FREE Full Text](#)
18. Kimura T, Nosaka H, Yokoi H, Iwabuchi M, Nobuyoshi M. Serial angiographic follow-up after Palmaz-Schatz stent implantation: comparison with conventional balloon angioplasty. *J Am Coll Cardiol*. 1993;21:1557-1563. [Medline](#)
19. Herrman NC, Buchbinder M, Cleman MW, Fischman D, Goldberg S, Leon M, Schatz RA, Teirstein P, Walker CM, Hirshfeld JW. Emergent use of balloon expandable coronary artery stenting for failed percutaneous transluminal coronary angioplasty. *Circulation*. 1992;86:812-819. [Abstract/FREE Full Text](#)
20. Nath FC, Muller DMM, Ellis SG, Rosenschein U, Chanakis A, Quain J, Zimmerman C, Topol EJ. Thrombosis of a flexible coil coronary stent: frequency, predictors, and clinical outcomes. *J Am Coll Cardiol*. 1993;21:622-627. [Medline](#)
21. Goldberg S, Colombo A, Nakamura S, Almagor M, Maiello L, Tobis JM. The benefit of intracoronary ultrasound in the deployment of Palmaz-Schatz stents. *J Am Coll Cardiol*. In press.
22. Nakamura S, Colombo A, Gardlione S, Almagor Y, Goldberg S, Maiello L, Finzi L, Tobis JM. Intracoronary ultrasound observations during stent implantation. *Circulation*. 1994;89:2026-2034. [FREE Full Text](#)
23. Tobis JM, Mallory J, Mahon D, Lehman K, Zalesky P, Griffith J, Gessert J, Moriuchi M, McPae M, Dwyer MI, Green N, Henry WL. Intravascular ultrasound imaging of human coronary arteries in vivo: analysis of tissue characteristics with comparison to in vitro histological specimens. *Circulation*. 1991;83:913-926. [Abstract/FREE Full Text](#)
24. Nishimura RA, Edwards WD, Warnes CA, Reeder GS, Holmes DR Jr, Tajik AJ, Yock PG. Intravascular ultrasound imaging: in vitro validation and

- pathologic correlation. *J Am Coll Cardiol*. 1990;16:145-154. [Medline](#)
25. Hall P, Colombo A, Almagor Y, Maiello I, Nakamura S, Martini G, Tobis JM. Preliminary experience with intravascular ultrasound guided Palmaz-Schatz coronary stenting: the acute and short term results on a consecutive series of patients. *J Intervent Cardiol*. 1994;7:141-159. [Medline](#)
  26. Glavin S, Weisenberg F, Zarins CK, Stankunavicius K, Koletts GJ. Compensatory enlargement of human atherosclerotic coronary arteries. *N Engl J Med*. 1987;316:1371-1375. [CrossRef](#) [Medline](#)
  27. Stiel GM, Stiel JG, Schofer J, Donath K, Mathey DG. Impact of compensatory enlargement of atherosclerotic coronary arteries on angiographic assessment of coronary disease. *Circulation*. 1989;80:1603-1609. [Abstract/FREE Full Text](#)
  28. Soblienko DP, Brown C, Mitten S. A new digital electronic caliper for measurement of coronary arterial stenosis: a comparison with visual and computer assisted measurements. *Am J Cardiol*. 1984;53:689-693. [CrossRef](#) [Medline](#)
  29. Theron HT, Lambert CR, Pepine CJ. Video densitometry versus digital calipers for quantitative coronary angiography. *Am J Cardiol*. 1990;66:1886-1890.
  30. Ryan TJ, Faxon DP, Gunnar RM, Kennedy JW, King SB III, Leon ED, Peterson KI, Reeves TJ, Williams DO, Winters WJ, Jr. Guidelines for percutaneous transluminal coronary angioplasty: a report of the American College of Cardiology/American Heart Association Task Force on assessment of diagnostic and therapeutic cardiovascular procedures. *Circulation*. 1988;78:486-502. [FREE Full Text](#)
  31. The TIMI Study Group. The Thrombolysis in Acute Myocardial Infarction Trial. *N Engl J Med*. 1985;312:932-936. [Medline](#)
  32. Waller RF, Pinkerton CA, Slack JD. Intravascular ultrasound: a histological study of vessels during life: a new 'gold standard' for vascular imaging. *Circulation*. 1992;85:2305-2310. [FREE Full Text](#)
  33. Fischman DL, Savage MP, Leon MR, Hirschfield JW Jr, Cleman MW, Tierstein P, Goldberg S. Angiographic predictors of subacute thrombosis following coronary artery stenting. *Circulation*. 1991;84(suppl II):II-588. Abstract.
  34. Penn IM, Brown PIC, Macdonald R, Ricci D, Almond D, Burton I, O'Neill R, Galligan J, Foley IR, Murray-Parsons N, White I, Slivocka I. Stent complications are dependent on the "stent environment": multicenter Canadian experience. *J Am Coll Cardiol*. 1992;19(suppl A):47A. Abstract.
  35. Schemin A, Dietz P, Kuehler W, Hsu E, Krazhoefer R. Outcome after emergency stent insertion of coronary stents. *J Am Coll Cardiol*. 1992;19(suppl A):198A. Abstract.
  36. Haude M, Erbel R, Issa H, Hafner G, Swars H, Fischer T, Prallwhite W, Meyer J. How to handle patients after intracoronary insertion of Palmaz-Schatz stent presenting risk factors for the occurrence of subacute thrombotic event? *Eur Heart J*. 1992;13(suppl):5. Abstract.
  37. Agrawal SK, Hearn JA, Liu MM, Cannon AD, Bilodeau J, Iyer SS, Bayliss WA, Dean LS, Roubin GS. Stent thrombosis and ischemic complications following coronary artery stenting. *Circulation*. 1992;86(suppl I):I-113. Abstract.
  38. Shaknovich A, Moses JW, Bailly S, Ricci D, Klez S, Tierstein P, Schatz RA, for the STRESS Investigators. Subacute stent thrombosis in the STent Restenosis Study (STRESS): clinical impact and predictive factors. *Circulation*. In press. Abstract.

## Articles citing this article

### Stent thrombosis and restenosis: what have we learned and where are we going? The Andreas Gruntzig Lecture ESC 2014

*Eur Heart J*. 2015;0:ehv511v1-ehv511,

[Abstract](#) [Full Text](#) [PDF](#)

### Hydroxybutyl Chitosan Polymer-Mediated CD133 Antibody Coating of Metallic Stents to Reduce Restenosis in a Porcine Model of Atherosclerosis

*J CARDIOVASC PHARMACOL THER*. 2015;20:322-329,

[Abstract](#) [Full Text](#) [PDF](#)

### ANMCO/SICI-GISE paper on antiplatelet therapy in acute coronary syndrome

*Eur Heart J Suppl*. 2014;16:C2-C28,

[Abstract](#) [Full Text](#) [PDF](#)

### Endeavour zotarolimus-eluting stent reduces stent thrombosis and improves clinical outcomes compared with cypher sirolimus-eluting stent: 4-year results of the PROTECT randomized trial

*Eur Heart J*. 2014;35:2812-2820,

[Abstract](#) [Full Text](#) [PDF](#)

### Revascularisation for patients with stable coronary artery disease

*BMJ*. 2014;348:g4099,

[Full Text](#) [PDF](#)

### Standing on Solid Ground?: Reassessing the Role of Incomplete Strut Apposition in Drug-Eluting Stents

*Circ Cardiovasc Interv*. 2014;7:6-8,

[Full Text](#) [PDF](#)

### Putting the microscope on stent thrombosis

*Heart*. 2012;98:1187-1188,

[Full Text](#) [PDF](#)

**Grabbing the Horns of a Dilemma: The Duration of Dual Antiplatelet Therapy After Stent Implantation**

*Circulation*. 2012;125:1967-1970,

[Full Text](#) | [PDF](#)

**Ultrasonic image analysis and image-guided interventions**

*Interface Focus*. 2011;1:673-685,

[Abstract](#) | [Full Text](#) | [PDF](#)

**Coronary intravascular ultrasound: a closer view**

*Heart*. 2010;96:1318-1324,

[Full Text](#) | [PDF](#)

**Drug-eluting stents: a reappraisal**

*Heart*. 2010;96:489-493,

[Full Text](#) | [PDF](#)

**Effects of Stent Design and Atherosclerotic Plaque Composition on Arterial Wall Biomechanics**

*J Endovasc Ther*. 2008;15:643-654,

[Abstract](#) | [PDF](#)

**Aortic Wall Injury as a Complication of Neonatal Aortic Valvuloplasty: Incidence and Risk Factors**

*Circ Cardiovasc Interv*. 2008;1:53-59,

[Abstract](#) | [Full Text](#) | [PDF](#)

**Clark DJ, Lessio S, O'Donoghue M, Tsalamandris C, Schainfeld R, Rosenfield R. Mechanisms and predictors of carotid artery restenosis: a serial intravascular ultrasound study. *J Am Coll Cardiol*. 2006;47:2390-2396**

*PERSPECT VASC SURG ENDOVASC THER*. 2007;19:199-201,

[Abstract](#) | [PDF](#)

**A Cause for Concern**

*Circulation*. 2007;115:1440-1455,

[Full Text](#) | [PDF](#)

**Incidence, predictors, and outcomes of coronary dissections left untreated after drug-eluting stent implantation**

*Eur Heart J*. 2006;27:540-546,

[Abstract](#) | [Full Text](#) | [PDF](#)

**Coronary stenting and abciximab in primary angioplasty for ST-segment-elevation myocardial infarction**

*QJM*. 2005;98:633-641,

[Abstract](#) | [Full Text](#) | [PDF](#)

**Drug-eluting stents for chronic total occlusions make sense, but it is too early to close the discussion**

*Eur Heart J*. 2005;26:1049-1051,

[Full Text](#) | [PDF](#)

**Ten Years of Advancements in Interventional Cardiology**

*J Endovasc Ther*. 2004;11:II-10-II-18,

[PDF](#)

**Intraprocedural Stent Thrombosis During Implantation of Sirolimus-Eluting Stents**

*Circulation*. 2004;109:2732-2736,

[Abstract](#) | [Full Text](#) | [PDF](#)

**Catheter based intracoronary brachytherapy leads to increased platelet activation**

*Heart*. 2004;90:160-164,

[Abstract](#) | [Full Text](#) | [PDF](#)

**Continued improvement of clinical outcome and cost effectiveness following intravascular ultrasound guided PCI: insights from a prospective, randomised study**

*Heart*. 2003;89:1043-1049,

[Abstract](#) | [Full Text](#) | [PDF](#)

**Stent Thrombosis: An Issue Revisited in a Changing World**

[Circulation](#). 2003;108:2-5,

[Full Text](#) | [PDF](#)

**Predictors of Subacute Stent Thrombosis: Results of a Systematic Intravascular Ultrasound Study**

[Circulation](#). 2003;108:43-47,

[Abstract](#) | [Full Text](#) | [PDF](#)

**Evaluation of intracoronary stenting by intravascular optical coherence tomography**

[Heart](#). 2003;89:317-320,

[Abstract](#) | [Full Text](#) | [PDF](#)

**Outcome after treatment of coronary in-stent restenosis: Results from a systematic review using meta-analysis techniques**

[Eur Heart J](#). 2003;24:266-273,

[Abstract](#) | [Full Text](#) | [PDF](#)

**Atorvastatin Reduces the Ability of Clopidogrel to Inhibit Platelet Aggregation: A New Drug-Drug Interaction**

[Circulation](#). 2003;107:32-37,

[Abstract](#) | [Full Text](#) | [PDF](#)

**The challenge of in-stent restenosis: insights from intravascular ultrasound**

[Eur Heart J](#). 2003;24:138-150,

[Full Text](#) | [PDF](#)

**Heparin dose during percutaneous coronary intervention: how low dare we go?**

[Heart](#). 2002;88:331-334,

[Abstract](#) | [Full Text](#) | [PDF](#)

**Results and Long-Term Predictors of Adverse Clinical Events After Elective Percutaneous Interventions on Unprotected Left Main Coronary Artery**

[Circulation](#). 2002;106:698-702,

[Abstract](#) | [Full Text](#) | [PDF](#)

**Understanding coronary artery disease: tomographic imaging with intravascular ultrasound**

[Heart](#). 2002;88:91-96,

[Full Text](#) | [PDF](#)

**What Is "The Matter" With Restenosis in 2002?**

[Circulation](#). 2002;105:2932-2933,

[Full Text](#) | [PDF](#)

**The stent is here to stay: a note on stenting, ultrasound imaging, and the prevention of restenosis**

[Eur Heart J](#). 2002;23:595-597,

[Full Text](#) | [PDF](#)

**Discrepancy between angiography and intravascular ultrasound when analysing small coronary arteries**

[Eur Heart J](#). 2002;23:247-254,

[Abstract](#) | [Full Text](#) | [PDF](#)

**Angiography-Guided Routine Coronary Stent Implantation Results in Suboptimal Dilatation**

[ANGIOLOGY](#). 2002;53:69-75,

[Abstract](#) | [PDF](#)

**The impact of high pressure vs low pressure stent implantation on intimal hyperplasia and follow-up lumen dimensions; results of a randomized trial**

[Eur Heart J](#). 2001;22:2015-2024,

[Abstract](#) | [PDF](#)

**Fractional Flow Reserve Compared With Intravascular Ultrasound Guidance for Optimizing Stent Deployment**

[Circulation](#). 2001;104:1917-1922,

[Abstract](#) | [Full Text](#) | [PDF](#)

**Randomized Comparison of Coronary Stent Implantation Under Ultrasound or Angiographic Guidance to Reduce Stent Restenosis (OPTICUS Study)**

[Circulation](#). 2001;104:1343-1349,

[Abstract](#) | [Full Text](#) | [PDF](#)

**Intravascular Ultrasound Guidance for Stent Implantation**

[Circulation](#). 2001;103:e110,

[Full Text](#) | [PDF](#)

**Relation of a Common Methylenetetrahydrofolate Reductase Mutation and Plasma Homocysteine With Intimal Hyperplasia After Coronary Stenting**

[Circulation](#). 2001;103:2048-2054,

[Abstract](#) | [Full Text](#) | [PDF](#)

**Stent Thrombosis in the Modern Era : A Pooled Analysis of Multicenter Coronary Stent Clinical Trials**

[Circulation](#). 2001;103:1967-1971,

[Abstract](#) | [Full Text](#) | [PDF](#)

**Hyperhomocysteinemia and Restenosis**

[European Journal of Preventive Cardiology](#). 2001;8:9-13,

[Abstract](#) | [PDF](#)

**Intravascular Ultrasound : Novel Pathophysiological Insights and Current Clinical Applications**

[Circulation](#). 2001;103:604-616,

[Abstract](#) | [Full Text](#) | [PDF](#)

**Ultrasound-Guided Strategy for Provisional Stenting With Focal Balloon Combination Catheter : Results From the Randomized Strategy for Intracoronary Ultrasound-Guided PTCA and Stenting (SIPS) Trial**

[Circulation](#). 2000;102:2497-2502,

[Abstract](#) | [Full Text](#) | [PDF](#)

**Is provisional stenting the effective option? The WIDEST study (Wiktor stent in de novo stenosis)**

[Heart](#). 2000;84:522-528,

[Abstract](#) | [Full Text](#)

**Long term angiographic and clinical follow up in patients with stent implantation for symptomatic myocardial bridging**

[Heart](#). 2000;84:403-408,

[Abstract](#) | [Full Text](#)

**Antithrombotic Therapy during and after Intracoronary Stenting**

[Journal of Pharmacy Technology](#). 2000;16:185-196,

[Abstract](#) | [PDF](#)

**Final Results of the Can Routine Ultrasound Influence Stent Expansion (CRUISE) Study**

[Circulation](#). 2000;102:523-530,

[Abstract](#) | [Full Text](#) | [PDF](#)

**Biodegradable Stents : "Fulfilling the Mission and Stepping Away"**

[Circulation](#). 2000;102:371-373,

[Full Text](#) | [PDF](#)

**In vitro evaluation of c7E3-Fab (ReoPro™) eluting polymer-coated coronary stents**

[Cardiovasc Res](#). 2000;46:585-594,

[Abstract](#) | [Full Text](#) | [PDF](#)

**CORONARY ARTERY STENTS: REVIEW AND PATIENT-MANAGEMENT RECOMMENDATIONS**

[Journal of the American Dental Association](#). 2000;131:797-801,

[Abstract](#) | [Full Text](#) | [PDF](#)

**Edge Restenosis After Implantation of High Activity 32P Radioactive (beta)-Emitting Stents**

[Circulation](#). 2000;101:2454-2457,

[Abstract](#) | [Full Text](#) | [PDF](#)**Antiplatelet Is Superior to Anticoagulant Treatment After Coronary Stenting: Fewer Coronary and Other Events Within 30 Days After Stenting**[ANGIOLOGY](#). 2000;51:289-294,[Abstract](#) | [PDF](#)**Safety and Efficacy of Ticlopidine After Stent Placement Response**[Circulation](#). 2000;101:e46-e47,[Full Text](#) | [PDF](#)**Short- and Intermediate-Term Results of 32P Radioactive (beta)-Emitting Stent Implantation in Patients With Coronary Artery Disease : The Milan Dose-Response Study**[Circulation](#). 2000;101:18-26,[Abstract](#) | [Full Text](#) | [PDF](#)**Intravascular ultrasound guided PTCA: a way to escape stent mania?**[Eur Heart J](#). 2000;21:92-94,[PDF](#)**Reference Chart Derived From Post-Stent-Implantation Intravascular Ultrasound Predictors of 6-Month Expected Restenosis on Quantitative Coronary Angiography**[Circulation](#). 1999;100:1777-1783,[Abstract](#) | [Full Text](#) | [PDF](#)**Influence of Balloon Pressure During Stent Placement in Native Coronary Arteries on Early and Late Angiographic and Clinical Outcome : A Randomized Evaluation of High-Pressure Inflation**[Circulation](#). 1999;100:918-923,[Abstract](#) | [Full Text](#) | [PDF](#)**Late Coronary Occlusion After Intracoronary Brachytherapy**[Circulation](#). 1999;100:789-792,[Abstract](#) | [Full Text](#) | [PDF](#)**Late Thrombosis After Radiation : Sitting on a Time Bomb**[Circulation](#). 1999;100:780-782,[Full Text](#) | [PDF](#)**In Vivo Assessment of Stent Expansion and Recoil in Normal Porcine Coronary Arteries : Differential Outcome by Stent Design**[Circulation](#). 1999;100:756-760,[Abstract](#) | [Full Text](#) | [PDF](#)**Effectiveness of Clopidogrel and Aspirin Versus Ticlopidine and Aspirin in Preventing Stent Thrombosis After Coronary Stent Implantation**[Circulation](#). 1999;99:2364-2366,[Abstract](#) | [Full Text](#) | [PDF](#)**Elective Intracoronary Micro-Stent IITM Implantation Without Quantitative Coronary Angiography or Intravascular Ultrasound Guidance and Without Subsequent Anticoagulation: Short- and Long-Term Results**[ANGIOLOGY](#). 1999;50:381-391,[Abstract](#) | [PDF](#)**Balloon-Artery Interactions During Stent Placement : A Finite Element Analysis Approach to Pressure, Compliance, and Stent Design as Contributors to Vascular Injury**[Circ. Res.](#). 1999;84:378-383,[Abstract](#) | [Full Text](#) | [PDF](#)**Comparison of Quantitative Coronary Angiography, Intravascular Ultrasound, and Coronary Pressure Measurement to Assess Optimum Stent Deployment**[Circulation](#). 1999;99:1015-1021,[Abstract](#) | [Full Text](#) | [PDF](#)



**Safety and Efficacy of Ticlopidine for Only 2 Weeks After Successful Intracoronary Stent Placement**

[Circulation](#). 1999;99:248-253,

[Abstract](#) | [Full Text](#) | [PDF](#)

**Randomized Evaluation of Anticoagulation Versus Antiplatelet Therapy After Coronary Stent Implantation in High-Risk Patients : The Multicenter Aspirin and Ticlopidine Trial after Intracoronary Stenting (MATTIS)**

[Circulation](#). 1998;98:2126-2132,

[Abstract](#) | [Full Text](#) | [PDF](#)

**New developments in intravascular ultrasound**

[Vasc Med](#). 1998;3:281-290,

[Abstract](#) | [PDF](#)

**Randomized Multicenter Comparison of Conventional Anticoagulation Versus Antiplatelet Therapy in Unplanned and Elective Coronary Stenting : The Full Anticoagulation Versus Aspirin and Ticlopidine (FANTASTIC) Study**

[Circulation](#). 1998;98:1597-1603,

[Abstract](#) | [Full Text](#) | [PDF](#)

**Stenting After Optimal Lesion Debulking (SOLD) Registry : Angiographic and Clinical Outcome**

[Circulation](#). 1998;98:1604-1609,

[Abstract](#) | [Full Text](#) | [PDF](#)

**Antiplatelet treatment with cilostazol after stent implantation**

[Heart](#). 1998;80:393-396,

[Abstract](#) | [Full Text](#)

**Feasibility of Combined Percutaneous Transluminal Angioplasty and Minimally Invasive Direct Coronary Artery Bypass in Patients With Multivessel Coronary Artery Disease**

[Circulation](#). 1998;98:1048-1050,

[Abstract](#) | [Full Text](#) | [PDF](#)

**Intracoronary Stenting and Risk for Major Adverse Cardiac Events During the First Month**

[Circulation](#). 1998;98:104-111,

[Abstract](#) | [Full Text](#) | [PDF](#)

**Mechanisms of Residual Lumen Stenosis After High-Pressure Stent Implantation : A Quantitative Coronary Angiography and Intravascular Ultrasound Study**

[Circulation](#). 1998;98:112-118,

[Abstract](#) | [Full Text](#) | [PDF](#)

**Procedural Results and Late Clinical Outcomes After Placement of Three or More Stents in Single Coronary Lesions**

[Circulation](#). 1998;97:1355-1361,

[Abstract](#) | [Full Text](#) | [PDF](#)

**A Call for Provisional Stenting : The Balloon Is Back!**

[Circulation](#). 1998;97:1298-1305,

[Full Text](#) | [PDF](#)

**Comparison of Antiplatelet Effects of Aspirin, Ticlopidine, or Their Combination After Stent Implantation**

[Circulation](#). 1998;97:1046-1052,

[Abstract](#) | [Full Text](#) | [PDF](#)

**Procedural and follow up results with a new balloon expandable stent in unselected lesions**

[Heart](#). 1998;79:234-241,

[Abstract](#) | [Full Text](#)

**Prevention of Restenosis After Angioplasty in Small Coronary Arteries With Probucol**

[Circulation](#). 1998;97:429-436,

[Abstract](#) | [Full Text](#) | [PDF](#)

**Silicon Carbide-Coated Stents: Clinical Experience in Coronary Lesions with Increased Thrombotic Risk**

[J Endovasc Ther](#). 1998;5:32-36,

[Abstract](#) | [PDF](#)**Thrombosis and Hemostasis in Cardiology: Review of Pathophysiology and Clinical Practice (Part I)**[CLIN APPL THROMB HEMOST.](#) 1998;4:51-75,[Abstract](#) | [PDF](#)**Early and intermediate term clinical outcome after multiple coronary stenting**[Heart.](#) 1998;79:29-33,[Abstract](#) | [Full Text](#) | [PDF](#)**Long-term Angiographic and Clinical Outcome of Patients Undergoing Multivessel Coronary Stenting**[Circulation.](#) 1997;96:3873-3879,[Abstract](#) | [Full Text](#)**Introduction to Coronary Artery Stents and Their Pharmacotherapeutic Management**[Ann Pharmacother.](#) 1997;31:1490-1498,[Abstract](#) | [PDF](#)**Comparison of Immediate and Intermediate-Term Results of Intravascular Ultrasound Versus Angiography-Guided Palmaz-Schatz Stent Implantation in Matched Lesions**[Circulation.](#) 1997;96:2997-3005,[Abstract](#) | [Full Text](#)**Disturbed Intracoronary Hemodynamics in Myocardial Bridging : Early Normalization by Intracoronary Stent Placement**[Circulation.](#) 1997;96:2905-2913,[Abstract](#) | [Full Text](#)**Intravascular Ultrasound Image System for Experimental Implantation of Various Stents: Part 1**[Interv Neuroradiol.](#) 1997;3:82-85,[Abstract](#) | [PDF](#)**Antithrombotic Therapy in Patients Undergoing Coronary Angioplasty or Coronary Stent Placement**[CLIN APPL THROMB HEMOST.](#) 1997;3:S24-S31,[PDF](#)**Gene therapy for arterial thrombosis**[Cardiovasc Res.](#) 1997;35:459-469,[Abstract](#) | [Full Text](#) | [PDF](#)**Sustained Platelet Glycoprotein IIb/IIIa Blockade With Oral Xemilofiban in 170 Patients After Coronary Stent Deployment**[Circulation.](#) 1997;96:1117-1121,[Abstract](#) | [Full Text](#)**Comparison of Coronary Luminal Quantification Obtained From Intracoronary Ultrasound and Both Geometric and Videodensitometric Quantitative Angiography Before and After Balloon Angioplasty and Directional Atherectomy**[Circulation.](#) 1997;96:491-499,[Abstract](#) | [Full Text](#)**Coronary Stenting After Rotational Atherectomy in Calcified and Complex Lesions : Angiographic and Clinical Follow-Up Results**[Circulation.](#) 1997;96:128-136,[Abstract](#) | [Full Text](#)**Drug Information Rounds**[Ann Pharmacother.](#) 1997;31:770-778,[PDF](#)

**Major Benefit From Antiplatelet Therapy for Patients at High Risk for Adverse Cardiac Events After Coronary Palmaz-Schatz Stent Placement : Analysis of a Prospective Risk Stratification Protocol in the Intracoronary Stenting and Antithrombotic Regimen (ISAR) Trial**

[Circulation](#). 1997;95:2015-2021,

[Abstract](#) | [Full Text](#)

**State-of-the-Art Review: Antiplatelet Agents and Thrombin Inhibitors: Combined Modality Therapy**

[CLIN APPL THROMB HEMOST](#). 1997;3:82-85,

[PDF](#)

**Experimental Study of Thrombogenicity and Foreign Body Reaction Induced by Heparin-Coated Coronary Stents**

[Circulation](#). 1997;95:1549-1553,

[Abstract](#) | [Full Text](#)