

# UCSF

## UC San Francisco Previously Published Works

### Title

Surgical Planning for Adult Spinal Deformity: Anticipated Sagittal Alignment Corrections According to the Surgical Level

### Permalink

<https://escholarship.org/uc/item/6m18q987>

### Journal

Global Spine Journal, 12(8)

### ISSN

2192-5682

### Authors

Lafage, Renaud  
Schwab, Frank  
Elysee, Jonathan  
[et al.](#)

### Publication Date

2022-10-01

### DOI

10.1177/2192568220988504

Peer reviewed

# Surgical Planning for Adult Spinal Deformity: Anticipated Sagittal Alignment Corrections According to the Surgical Level

Global Spine Journal  
2022, Vol. 12(8) 1761–1769  
© The Author(s) 2021  
Article reuse guidelines:  
sagepub.com/journals-permissions  
DOI: 10.1177/2192568220988504  
journals.sagepub.com/home/gsj



Renaud Lafage, MS<sup>1</sup> , Frank Schwab, MD<sup>1</sup>, Jonathan Elysee, MS<sup>1</sup>, Justin S. Smith, MD, PhD<sup>2</sup> , Basel Sheikh Alshabab, MD<sup>1</sup>, Peter Passias, MD<sup>3</sup>, Eric Klineberg, MD<sup>4</sup>, Han Jo Kim, MD<sup>1</sup> , Christopher Shaffrey, MD<sup>5</sup>, Douglas Burton, MD<sup>6</sup>, Munish Gupta, MD<sup>7</sup>, Gregory M. Mundis Jr, MD<sup>8</sup>, Christopher Ames, MD<sup>9</sup>, Shay Bess, MD<sup>10</sup>, and Virginie Lafage, PhD<sup>1</sup>; on behalf of International Spine Study Group (ISSG)

## Abstract

**Study Design:** Retrospective cohort study.

**Objectives:** Establish simultaneous focal and regional corrective guidelines accounting for reciprocal global and pelvic compensation.

**Methods:** 433 ASD patients (mean age 62.9 yrs, 81.3% F) who underwent corrective realignment (minimum L1-pelvis) were included. Sagittal parameters, and segmental and regional Cobb angles were assessed pre and post-op. Virtual postoperative alignment was generated by combining post-op alignment of the fused spine with the pre-op alignment on the unfused thoracic kyphosis and the pre-op pelvic retroversion. Regression models were then generated to predict the relative impact of segmental (L4-L5) and regional (L1-L4) corrections on PT, SVA (virtual), and TPA.

**Results:** Baseline analysis revealed distal (L4-S1) lordosis of  $33 \pm 15^\circ$ , flat proximal (L1-L4) lordosis ( $1.7 \pm 17^\circ$ ), and segmental kyphosis from L2-L3 to T10-T11. Post-op, there was no mean change in distal lordosis (L5-S1 decreased by  $2^\circ$ , and L4-L5 increased by  $2^\circ$ ), while the more proximal lordosis increased by  $18 \pm 16^\circ$ . Regression formulas revealed that  $\Delta 10^\circ$  in distal lordosis resulted in  $\Delta 10^\circ$  in TPA, associated with  $\Delta 100$  mm in SVA or  $\Delta 3^\circ$  in PT;  $\Delta 10^\circ$  in proximal lordosis yielded  $\Delta 5^\circ$  in TPA associated with  $\Delta 50$  mm in SVA; and finally  $\Delta 10^\circ$  in thoraco-lumbar junction yielded  $\Delta 2.5^\circ$  in TPA associated with  $\Delta 25$  mm in SVA and no impact on PT correction.

**Conclusions:** Overall impact of lumbar lordosis restoration is critically determined by location of correction. Distal correction leads to a greater impact on global alignment and pelvic retroversion. More specifically, it can be assumed that  $1^\circ$  L4-S1 lordosis correction produces  $1^\circ$  change in TPA / 10 mm change in SVA and  $0.5^\circ$  in PT.

## Keywords

adult spinal deformity, sagittal alignment, surgical planning, simulation, segmental correction, regional correction, predictive model

<sup>1</sup> Spine Service, Hospital for Special Surgery, New York, NY, USA

<sup>2</sup> Department of Neurosurgery, University of Virginia Medical Center, Charlottesville, VA, USA

<sup>3</sup> Department of Orthopaedics, NYU Langone Orthopedic Hospital, New York, NY, USA

<sup>4</sup> Department of Orthopaedic Surgery, University of California, Davis, Sacramento, CA, USA

<sup>5</sup> Department of Neurosurgery, Duke University Medical Center, Durham, NC, USA

<sup>6</sup> Department of Orthopaedics, University of Kansas Medical Center, Kansas City, KS, USA

<sup>7</sup> Department of Orthopaedics, Washington University, St Louis, MO, USA

<sup>8</sup> Scripps Clinic, San Diego, CA, USA

<sup>9</sup> Department of Neurological Surgery, University of California, San Francisco, School of Medicine, San Francisco, CA, USA

<sup>10</sup> Denver International Spine Center, Presbyterian St. Luke's/Rocky Mountain Hospital for Children, Denver, CO, USA

## Corresponding Author:

Renaud Lafage, Spine Service, Hospital for Special Surgery, 525 E 71st St., Belaire 4E, New York, NY 10021, USA.  
Email: renaud.lafage@gmail.com



## Introduction

Adult spinal deformity is a highly common pathology in the older population, often associated with significant pain and disability. Growing evidence supports the clinical role of the sagittal component of the deformity, with progressive loss of lumbar lordosis (LL) and increased truncal inclination associated with poor patient-reported health-related quality of life (HRQoL).<sup>1-3</sup> Restoring sagittal alignment during surgical treatment of spinal deformity is critical to improving outcomes. Despite the proven relevance of achieving proper alignment, advanced but yet simple guidelines are still missing, and a large proportion of patients remain malaligned postoperatively.<sup>4</sup>

Global alignment is often characterized by the sagittal vertical axis (SVA), defined as the offset between the C7 plumbline to the posterosuperior corner of the sacrum.<sup>5</sup> Adult spinal deformity often starts with regional loss of lordosis followed by compensatory mechanisms to maintain an upright posture. SVA is useful in assessing globally truncal inclination and is one of the most correlated parameters with patient-reported outcomes.<sup>6</sup> However, defining alignment is more than a simple plumbline offset, and studying the position of the pelvis is essential to understand the body's reaction to a deformity. Pelvic tilt (PT), first described by Duval-Beaupere, is defined as the angle between the vertical and a line from the center of the femoral heads to the midpoint of the sacral endplate.<sup>7</sup> PT quantifies the pelvic rotation around the femoral heads, an established compensatory mechanism for anterior sagittal malalignment. Both SVA and PT are key components of the current ASD classification.<sup>8</sup> Suboptimal values represent reliable predictors of adverse clinical symptoms. Both parameters are not independent and have a dynamic relationship defining the overall spinal alignment. For a given alignment without changing any curvature, an increase in PT will decrease SVA, and vice versa.

Corrective surgery to restore ASD alignment relies on focal techniques that mostly have a direct impact on regional curvatures, which ultimately leads to a change in global alignment. Many studies have examined the quantitative effects of the degree and location of local correction on global parameters. Lafage et al described the relationship between the level and degree of pedicle subtraction osteotomy (PSO) on PT and SVA.<sup>9</sup> They found that a lower level of PSO has a larger impact on PT correction. This can be explained by a larger SVA correction achieved by a lower PSO level and a subsequent PT change in response to altered mass distribution above the pelvis, highlighting the dynamic interplay between PT and SVA.

Surgical planning for ASD in light of the complex interdependent spinopelvic parameters is challenging; having reliable predictive formulas could help in achieving better postoperative outcomes. While a published report has investigated the impact of regional correction on global alignment (SVA) and pelvic compensation (PT),<sup>10</sup> little is known about the impact of segmental correction in obtaining the desired global alignment. The goal of this study was to develop new predictive formulas to fine-tune truncal inclination and pelvic retroversion goals based on segmental and regional correction of the lumbar spine.

## Method

### Patient Population

This study was a retrospective review of a prospectively collected multicenter database of adult spinal deformity patients. Patients were enrolled into the ongoing database through an institutional review board approved protocol across all centers. The ethical approval was obtained from the Institutional Review Board of Hospital for Special Surgery prior to conducting the study (IRB No. 2014-357). Informed consent was obtained from all participating patients. Patients were enrolled if they met the following criteria: age > 18 years and spinal deformity confirmed by at least one of the following measures: scoliosis Cobb angle > 20°, SVA > 5 cm, pelvic tilt (PT) > 25°, and TK > 60°. For the current analysis, only patients with a minimum of 2-year follow-up data who underwent a complete fusion of the lumbar spine (L1 to S1 minimum) were retained.

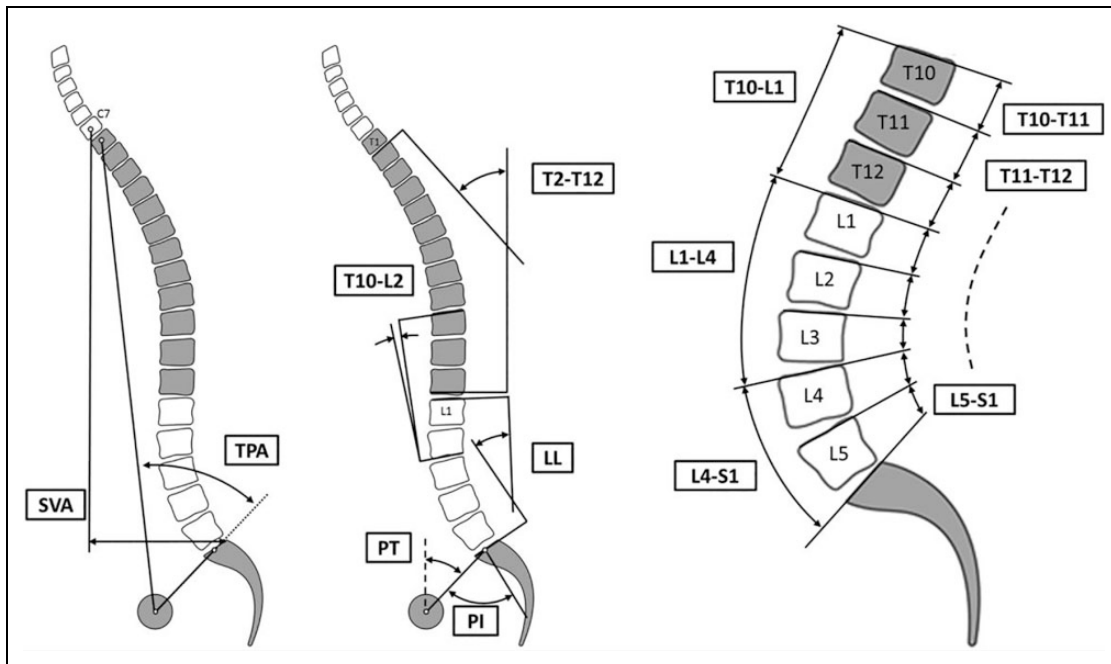
### Data Collection and Radiographic Parameters

Demographic information (age, sex, and BMI) were collected. Full-length, freestanding lateral, and anteroposterior spine radiographs were collected preoperatively and postoperatively. Identification and mapping of various anatomical landmarks were performed using validated software<sup>11</sup> (SpineView, ENSAM Laboratory of Biomechanics) to calculate the following parameters (Figure 1): PI, PT, mismatch between PI and LL (PI-LL), T1-pelvic angle (TPA), sagittal vertical axis (SVA), distal and proximal lumbar lordosis (i.e. L4-S1 and L1-L4), and thoraco-lumbar alignment (T10-L1). In addition, segmental angles for each vertebral level were calculated as the Cobb angle between the superior endplate of the vertebral level of interest and the superior endplate of the subjacent vertebral level.

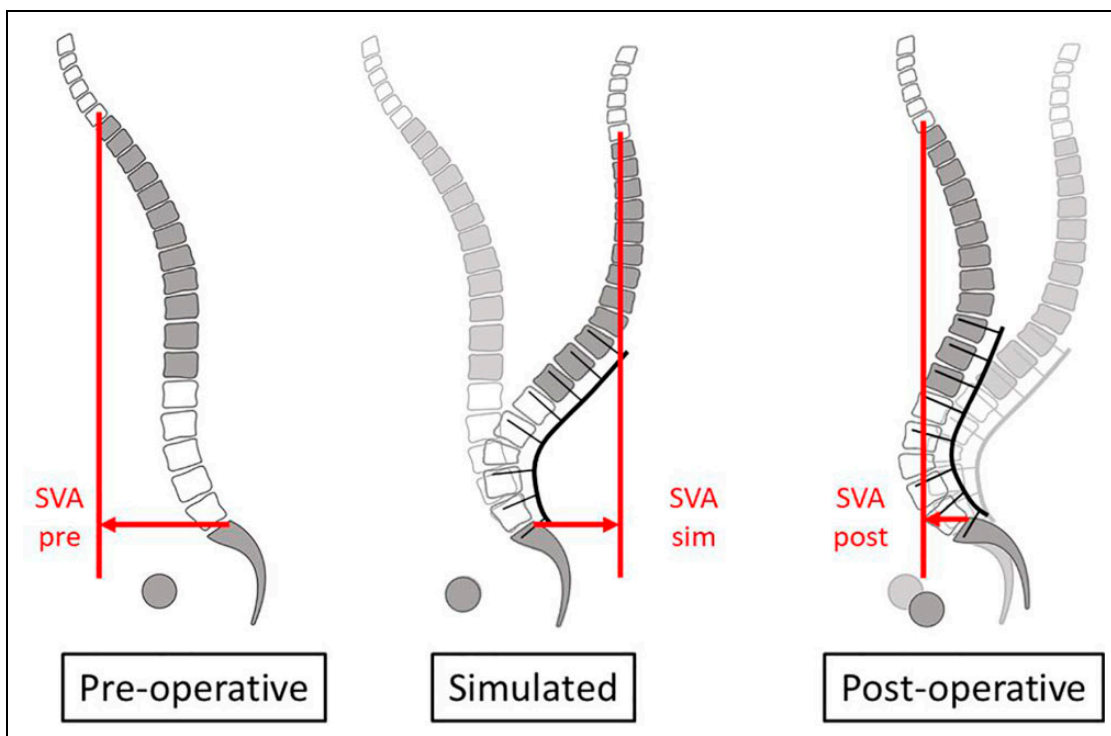
In an effort to analyze the truncal correction independently of pelvic correction or thoracic reciprocal changes occurring after the realignment procedure, a simulated intermediary position was modeled (Figure 2) by applying the surgically induced lordosis while maintaining the preoperative PT and thoracic alignment. This intermediate simulated position allowed quantification of the SVA ( $\Delta$ SVAsim) and TPA ( $\Delta$ TPAsim) correction free of any reciprocal change.

### Statistical Analysis

Demographic and radiographic data were described and analyzed at each time point. Multilinear regressions were generated to predict the simulated global alignment and the postoperative PT based on the segmental and regional corrections. The overall objective of these simulations was to investigate the impact of the location of correction on spino-pelvic alignment. Data were analyzed using SPSS software (SPSS, Inc.). Statistical analyses were 2-sided, and the level of significance was set to 0.05.



**Figure 1.** Radiographic parameters collected for this study including global parameters, regional parameters, and segmental parameters.



**Figure 2.** Pre-operative alignment (left), simulated (middle) and post-operative alignment (right). The simulated position is the result of the surgical correction before the relaxation of the thoracic compensation and pelvic retroversion.

## Results

### Cohort Description

A total of 433 out of 667 patients met inclusion criteria, the mean age of the cohort was  $62.9 \pm 9.7$  years, the mean BMI

was  $28.1 \pm 5.5$  kg/m<sup>2</sup>, and 81.3% were female. The mean follow-up period was  $26.6 \pm 6.4$  months. At baseline, the cohort exhibited a moderate to severe malalignment (Table 1), as demonstrated by the SRS-Schwab classification modifiers with, respectively, 32.6%, 47.1%, 36.3% of the patients having

**Table 1.** Preoperative, Postoperative and Change in Sagittal Alignment as Well as Pre-to-Post Test (Pair t-Test).

	Pre-op		2-year		Change		P
	Mean	StD	Mean	StD	Mean	StD	
PI	55.3	12.3	55.4	12.4	0.0	2.8	0.741
PT	26.4	10.2	22.7	10.0	-3.7	8.3	<0.001
PI-LL	20.6	19.0	3.8	14.9	16.9	16.7	<0.001
L1-S1	34.7	19.9	51.6	13.7	16.9	16.7	<0.001
T10-L2	-15.1	18.6	-9.0	13.4	6.1	17.8	<0.001
T2-T12	-34.8	18.5	-53.3	18.3	18.4	14.7	<0.001
TPA	25.9	12.4	18.6	10.7	-7.3	10.7	<0.001
SVA	79	71	33	53	-46	66	<0.001

**Table 2.** Preoperative and Postoperative Regional and Segmental Alignment of the Thoracolumbar Spine.<sup>a</sup>

		Pre-op		2-year change		P
		Mean	StD	Mean	StD	
Segmental angles	L5-S1	19.5	9.6	-2.3	8.5	<0.001
	L4-L5	13.5	8.8	1.5	9.1	0.001
	L3-L4	6.5	8.5	6.0	10.9	<0.001
	L2-L3	-0.8	8	6.7	8.5	<0.001
	L1-L2	-4	7.4	4.9	6.7	<0.001
	T12-L1	-4.1	6.7	2.5	6.7	<0.001
	T11-T12	-3.3	5.4	-1.0	6.1	0.001
Regional angles	T10-T11	-2	5.1	-3.1	7.2	<0.001
	L4-S1	33	14.7	-0.7	12.8	0.231
	L1-L4	1.7	17.5	17.7	15.9	<0.001
	T10-L1	-9.3	13.3	-1.7	13.8	0.011

<sup>a</sup>Positive values denote a lordotic alignment/change, while negative values denote a kyphotic alignment/change.

a sagittal modifier grade of ++ in PT, PI-LL, and SVA. As illustrated in (Table 1), at 2-year follow-up, there was a significant improvement in all the sagittal spino-pelvic parameters ( $P < 0.001$ ).

Preoperative segmental alignment demonstrated a flattening of the superior portion of the lumbar spine (L1-L4) associated with a kyphotic segmental alignment from L1-L2 to T10-T11 (Table 2). At 2-year follow-up, there was a significant difference in all the segmental angles, except L4-S1. This can be explained by the observed increase in L4-L5 lordosis associated with a decrease in L5-S1 lordosis. The largest segmental correction occurred at L3-L4 ( $+6.0 \pm 10.9$ ) and L2-L3 ( $+6.7 \pm 8.5$ ), while small kyphotic changes were observed from T10 to T12.

**Prediction of Postoperative Alignment**

Prediction of the expected changes in alignment was carried out in 2 steps: prediction of the global alignment changes (i.e.  $\Delta$ SVAsim and  $\Delta$ TPAsim) on the simulated position, followed by a prediction of the pre-to-post change in pelvic rotation (i.e.  $\Delta$ PPT)

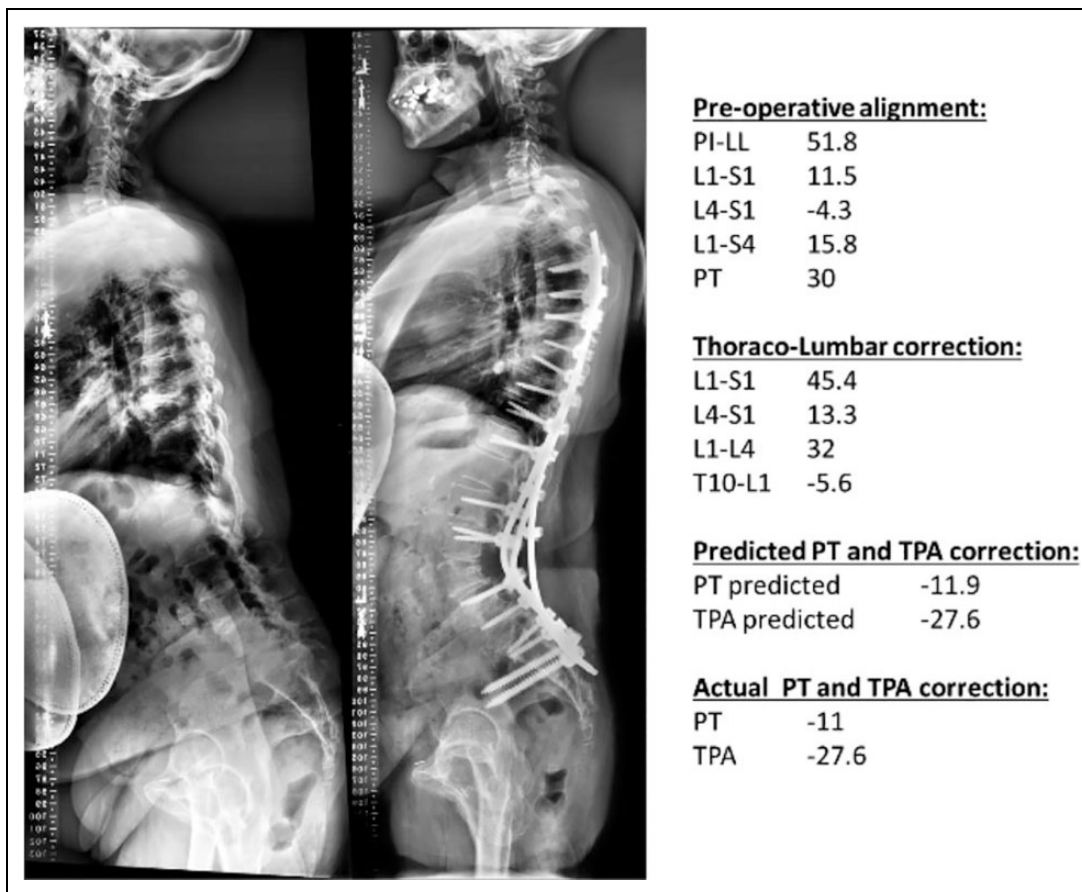
*Global alignment correction from pre-op to the simulated position.* Linear regressions to predict  $\Delta$ SVAsim and  $\Delta$ TPAsim based on focal and regional correction all demonstrated excellent results, with r-square values above 0.94. Analysis of the standardized coefficients (Table 3) revealed that on average:

- 1° of distal lordosis correction results in a correction of **1° in TPAsim**, and **10 mm in SVAsim**
- 1° of proximal lordosis correction results in a correction of **0.5° in TPAsim**, and **5 mm in SVAsim**

**Table 3.** Multilinear Regression Predicting  $\Delta$ tpasim,  $\Delta$ SVAsim,  $\Delta$ PPT Using Segmental or Regional Correction Thoraco-Lumbar Corrections.

		TPA correction <u>before</u> thoracic reciprocal changes		SVA correction <u>before</u> thoracic reciprocal changes		PT correction <u>after</u> thoracic reciprocal changes	
		Real pred.	Rounded	Real pred.	Rounded	Real pred.	Rounded
Segmental angles	constant	-	-	-	-	2.178	2.00
	L5-S1	-0.797	-1	-8.527	-10	-0.526	-0.5
	L4-L5	-0.702	-1	-7.536	-10	-0.408	-0.5
	L3-L4	-0.586	-0.5	-6.441	-5	-0.36	-0.5
	L2-L3	-0.575	-0.5	-6.281	-5	-0.361	-0.25
	L1-L2	-0.473	-0.5	-5.491	-5	-0.319	-0.25
	T12-L1	-0.441	-0.5	-4.607	-5	-0.209	-0.25
	T11-T12	-0.304	-0.25	-3.689	-2.5	-0.218	-0.25
	T10-T11	-0.368	-0.25	-3.755	-2.5	-0.278	-0.25
	Mean error	0.07	0.72	1.85	18.90	0.00	-0.25
	Mean abs Error	2.32	3.75	27.80	42.44	3.82	4.14
RMSE	3.19	4.90	37.68	55.18	5.08	5.54	
Regional angles	constant	-	-	-	-	2.42	2.50
	L4-S1	-0.747	-1	-7.997	-10	-0.456	-0.5
	L1-L4	-0.555	-0.5	-6.142	-5	-0.346	-0.25
	T10-L1	-0.364	-0.25	-3.999	-2.5	-0.227	-0.25
	Mean error	-0.33	1.12	-2.56	22.81	-0.22	1.50
	Mean abs Error	3.18	4.50	36.53	50.19	4.15	4.33
	RMSE	4.30	5.91	49.30	65.76	5.50	5.85





**Figure 3.** Case example 1 (Large correction).

- 1° of TL correction results in a correction of **0.25° in TPAsim**, and **2.5 mm in SVAsim**

**PT correction after reciprocal change:** Predictions of PT correction yielded moderate to good results depending on the type of independent predictors considered with r-square of 0.642 with segmental angles, 0.615 with regional angles, and 0.652 with  $\Delta$ TPAsim. Coefficients of regression suggested that 1° of distal lumbar lordosis correction led to 0.5° in PT correction, 1° of proximal lumbar lordosis correction led to 0.25° in PT correction, and 1° of TL junction correction induced 0.25° in PT correction (Table 3).

### Case Examples

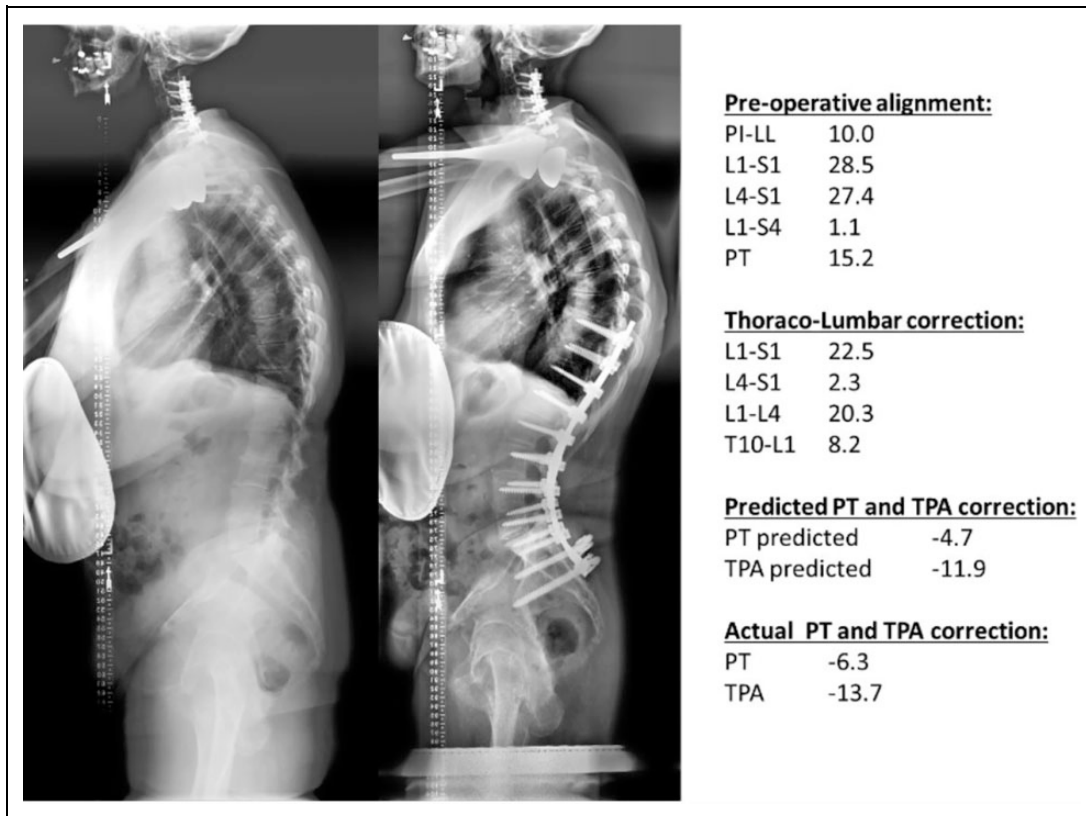
**Large correction.** This patient (Figure 3) presented with a sizable spino-pelvic mismatch (PI-LL = 52°). The surgical correction consisted of a 45° restoration of L1-S1 lordosis with 2/3 located between L1-L4 (L3 PSO) and a small correction of the thoracolumbar kyphosis. Based on the developed formulas, the anticipated outcomes of this strategy would be a 27.6° and 12° correction of TPA and PT. At the 2-year postoperative evaluation, the actual decreases in TPA and PT were 27.6° and 11°, respectively.

**Overcorrection of lumbar lordosis.** This patient (Figure 4) presented with degenerative scoliosis and a maintained lumbar alignment (PI-LL = 10°). The patient underwent a T10-Pelvis posterior fusion, with an increase in lumbar lordosis of 20°. Despite this overcorrection, the model predicted a 5° correction in PT, along with a 12° correction of TPA. Postoperative 2-year follow-up showed a change in PT of 6.3° and a correction of TPA of 13.7°.

**Proximal correction of the lumbar spine.** For this revision case (Figure 5) with a previous L4-L5 fusion, the surgical strategy called for a 10° increase in proximal lordosis, without any change in the distal lordosis (due to the existing fusion). The predictive model showed no change in pelvic retroversion and a minimum change in global alignment despite a lumbar realignment of 10°. At 2-year post-op, change in PT was 0° associated with a change in TPA of 3°.

### Discussion

In this cohort of ASD patients, preoperative sagittal alignment was characterized by an overall loss of lumbar sagittal curvature proximally and a kyphotic alignment between the L1 and L2 vertebrae. Description of the segmental correction showed that most of the lordotic change occurred between L4 and L1,



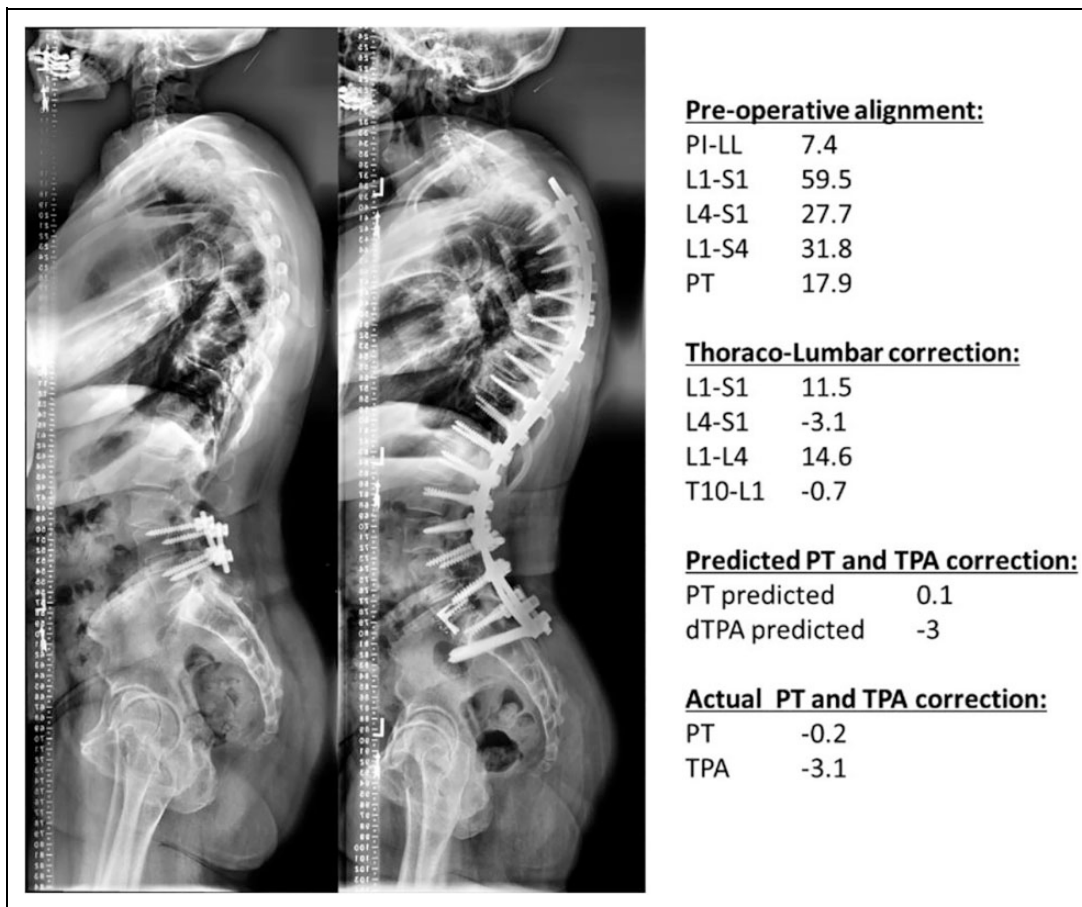
**Figure 4.** Case example 2 (Overcorrection of lumbar lordosis).

while L4-S1 distal lordosis did not significantly increase between pre- and post-op. The predictive formula for global alignment free of reciprocal change demonstrated excellent results. The error of prediction using segmental alignment was relatively low and close to the measurement error, making it usable in a clinical setting. Finally, the prediction of postoperative pelvic retroversion using only segmental alignment demonstrated acceptable results.

The importance of restoring global sagittal alignment is widely recognized in the spine community. However, describing and understanding the numerous factors affecting postoperative sagittal alignment is challenging, and more than 50% of patients remain with a suboptimal alignment after deformity correction.<sup>4</sup> Recently, optimizing preoperative surgical planning by analyzing the immediate impact of surgical correction on overall alignment outcomes has been the focus of many studies. When ASD surgery is performed, correction of the deformity driver will lead to a global relaxation of the spinopelvic axis and induce spontaneous correction of compensatory mechanisms. An ideal planning method would incorporate how operative techniques influence truncal global inclination (TPA and SVA) and the PT, 2 of the alignment parameters most correlated with HRQoL measures. This study provides a new model that includes more detailed vertebral segmental alignment in the planning process.

In our cohort, the preoperative segmental alignment demonstrated an overall loss of proximal lordosis with a kyphotic

alignment starting at L1-L2. Surgical correction of the loss of lumbar lordosis occurred mainly at the L1-L4 segments. On average, there was no alignment change/correction at the L4-S1 segment. Interestingly, a deeper look at this segment revealed a kyphotic change at L5-S1 combined with a lordotic change at L4-L5, in line with another published report.<sup>12</sup> This pattern of correction here does not achieve a normal distribution of lumbar lordosis. Pesenti et al.<sup>13</sup> demonstrated that in asymptomatic adults the distal lumbar lordosis was about 35° and accounted for 62% of the total lordosis, with (L5-S1) specifically responsible for 35%. In the present study, preoperative deformity demonstrated a larger deformity proximally, therefore the correction needed to occur more proximally. However, distal alignment should not deteriorate while achieving a normal lumbar shape. To support our findings, we also see that patients with greater global correction had most of the correction located at the L3-L4 and L2-L3 levels. These levels represent the most common location of major osteotomy, as demonstrated by Diebo et al.<sup>14</sup> With the current trend of decreased use of major osteotomies and increased correction at the distal levels through the disc spaces, these results may be different in a more recent cohort. Examining PT change in our study shows patients with significant global correction had an improved PT, while patients with a maintenance/deterioration of their global alignment tend to worsen their pelvic compensation. Previous reports state that up to 66% of patients had increases in PT postoperatively (25% had >5 degrees of



**Figure 5.** Case example 3 (Proximal correction of the lumbar spine).

deterioration).<sup>15</sup> Insufficient correction and/or unanticipated reciprocal changes can explain this sub-optimal postoperative outcome.

Predicting postoperative alignment is not easy and requires more than just experience. A survey study reported difficulties for experienced spine surgeons to predict postoperative alignment,<sup>16</sup> highlighting the need for predictive formulas and advanced computer planning.<sup>17</sup> Published predictive methods include a variety of formulas ranging from simple (Lumbar Lordosis > Thoracic Kyphosis +20°), to more complex ones that include compensatory mechanisms. Not surprisingly, the more complex ones tend to be more accurate but at the same time are less practical in daily practice. As demonstrated by Langella and colleagues, computer-assisted methods could address this challenging question and permit the use of machine learning algorithms that continue to improve with time and data.<sup>18</sup>

The formulas developed in the current investigation include different layers of parameters that reflect regional (distal lordosis, proximal lordosis) and segmental (individual levels) change for more detailed prediction. They are adapted for clinical use and can be integrated into digital planning tools. Prediction of pelvic retroversion compared to a previously published formula had a slightly lower r-square (0.6 vs 0.8).<sup>19</sup> The

current prediction is based only on fused segments, while previous formulas require the ability to anticipate reciprocal changes in the thoracic spine. Decomposition of SVA correction and PT correction allows anticipation of the maximum correction of SVA without any deterioration of pelvic retroversion. Classic prediction does not differentiate SVA correction from PT correction and requires knowing or assuming the ratio of closure between the truncal and pelvic correction.<sup>9,20</sup> Furthermore, the developed method in the present study enables understanding of a result that seems counter-intuitive: the lower the correction is performed in the lumbar spine, the larger the pelvic correction compared to the SVA correction.<sup>9</sup> From a geometric point of view, a lower correction should induce a larger global correction due to the lever arm effect. As the truncal inclination and pelvic retroversion are not independent from each other, a portion of the global correction is consumed in correcting the pelvic retroversion.

This study is limited by its retrospective nature. Also, it does not include the actual preoperative planning. Therefore, the postoperative alignment was defined as preoperative planning with perfect surgical execution. In addition, the widespread use of predictive formulas is contingent on their ability to be generalized to a large population. This cohort has a large variability of surgical techniques used across several years. Finally,



this is a radiographic study only, and outcomes do not account for the effect of neural element decompression, muscle quality, or other dynamic effects between balance and alignment.

## Conclusion

In conclusion, the overall effect of lumbar lordosis restoration depends on the vertebral levels at which correction is achieved. A more distal correction will lead to more global change and more PT correction. As a rule of thumb: 1° of correction between L4 and S1 will at best correct the SVA by 10 mm and will induce a 1° change in TPA and a 0.5° change in PT. Based on regional (PI-LL) and segmental alignment objectives in the context of global alignment (TPA/SVA) and PT, preoperative planning can be customized to be patient-specific, rather than relying on the overly generalized assumption that all patients warrant the same correction at the same vertebral levels.

## Authors' Note

The International Spine Study Group (ISSG) is funded through research grants from DePuy Synthes (current), Nuvasive (current), K2M (current), Innovaxis (past), Biomet (past), and individual donations. Funding sources did not play a role in investigation.


## Declaration of Conflicting Interests


The author(s) declared no potential conflicts of interest with respect to the research, authorship, and/or publication of this article.


## Funding

The author(s) received no financial support for the research, authorship, and/or publication of this article.

## ORCID iD

Renaud Lafage, MS  <https://orcid.org/0000-0002-4820-1835>

Justin S. Smith, MD, PhD  <https://orcid.org/0000-0003-0467-5534>

Han Jo Kim, MD  <https://orcid.org/0000-0003-2170-3592>

## References

- Glassman SD, Bridwell K, Dimar JR, Horton W, Berven S, Schwab F. The impact of positive sagittal balance in adult spinal deformity. *Spine (Phila Pa 1976)*. 2005;30(18):2024-2029. doi: 10.1097/01.brs.0000179086.30449.96
- Glassman SD, Berven S, Bridwell K, Horton W, Dimar JR. Correlation of radiographic parameters and clinical symptoms in adult scoliosis. *Spine (Phila Pa 1976)*. 2005;30(6):682-688. doi: 10.1097/01.brs.0000155425.04536.f7
- Schwab FJ, Patel A, Ungar B, Farcy J-PP, Lafage V. Adult spinal deformity-postoperative standing imbalance: how much can you tolerate? An overview of key parameters in assessing alignment and planning corrective surgery. *Spine (Phila Pa 1976)*. 2010; 35(25):2224-2231. doi:10.1097/BRS.0b013e3181ee6bd4
- Moal B, Schwab FJ, Ames CP, et al. Radiographic outcomes of adult spinal deformity correction: a critical analysis of variability and failures across deformity patterns. *Spine Deform*. 2014;2(3): 219-225. doi:10.1016/j.jspd.2014.01.003
- Jackson RP, McManus AC. Radiographic analysis of sagittal plane alignment and balance in standing volunteers and patients with low back pain matched for age, sex, and size. A prospective controlled clinical study. *Spine (Phila Pa 1976)*. 1994;19(14): 1611-1618. Accessed January 29, 2021. <http://onlinelibrary.wiley.com/o/cochrane/clcentral/articles/484/CN-00105484/frame.html>
- Lafage V, Schwab F, Patel A, Hawkinson N, Farcy J-P. Pelvic tilt and truncal inclination: two key radiographic parameters in the setting of adults with spinal deformity. *Spine (Phila Pa 1976)*. 2009;34(17): E599-606. doi:10.1097/BRS.0b013e3181aad219
- Duval-Beaupère G, Schmidt C, Cosson P. A barycentremetric study of the sagittal shape of spine and pelvis: the conditions required for an economic standing position. *Ann Biomed Eng*. 1992;20(4):451-462. doi:10.1007/BF02368136
- Schwab F, Ungar B, Blondel B, et al. SRS-Schwab adult spinal deformity classification: a validation study. *Spine (Phila Pa 1976)*. 2011;37:1077-1082. doi:10.1097/BRS.0b013e31823e15e2
- Lafage V, Schwab FJ, Vira S, et al. Does vertebral level of pedicle subtraction osteotomy correlate with degree of spinopelvic parameter correction? *J Neurosurg Spine*. 2011;14(2):184-191. doi: 10.3171/2010.9.SPINE10129
- Lafage V, Bharucha NJ, Schwab FJ, et al. Multicenter validation of a formula predicting postoperative spinopelvic alignment. *J Neurosurg Spine*. 2012;16(1):15-21. doi:10.3171/2011.8.SPINE 11272
- Champain S, Benchikh K, Nogier A, Mazel C, Guise JD, Skalli W. Validation of new clinical quantitative analysis software applicable in spine orthopaedic studies. *Eur Spine J*. 2006; 15(6):982-991. doi:10.1007/s00586-005-0927-1
- Lafage R, Obeid I, Liabaud B, et al. Location of correction within the lumbar spine impacts acute adjacent-segment kyphosis. *J Neurosurg Spine*. 2019;30(1):69-77. doi:10.3171/2018.6.SPINE161468
- Pesenti S, Lafage R, Stein D, et al. The amount of proximal lumbar lordosis is related to pelvic incidence. *Clin Orthop Relat Res*. 2018;476(8):1603-1611. doi:10.1097/CORR.0000000000000380
- Diebo BG, Lafage V, Varghese JJ, et al. After 9 years of 3-column osteotomies, are we doing better? Performance curve analysis of 573 surgeries with 2-year follow-up. *Neurosurgery*. July 2017; 83(1):69-75. [epub ahead of print July 21,2017 doi: 10.1093/neu. doi:10.1093/neuros/nyx338
- Theologis AA, Safaee M, Scheer JK, et al. Magnitude, location, and factors related to regional and global sagittal alignment change in long adult deformity constructs: report of 183 patients with 2-year follow-up. *Clin Spine Surg*. 2017;30(7):948-953. doi: 10.1097/BSD.0000000000000503
- Ailon T, Scheer JK, Lafage V, et al. Adult spinal deformity surgeons are unable to accurately predict postoperative spinal alignment using clinical judgment alone. *Spine Deform*. 2016;4(4): 323-329. doi:10.1016/j.jspd.2016.02.003
- Lafage R, Pesenti S, Lafage V, Schwab FJ. Self-learning computers for surgical planning and prediction of postoperative alignment. *Eur Spine J*. 2018;27(S1):123-128. doi:10.1007/s00586-018-5497-0

18. Langella F, Villafaña JH, Damilano M, et al. Predictive accuracy of Surgimap™ surgical planning for sagittal imbalance: a cohort study. *Spine (Phila Pa 1976)*. 2017;42(22):E1297-E1304. doi:10.1097/BRS.0000000000002230
19. Lafage V, Schwab FJ, Vira S, Patel A, Ungar B, Farcy J-PP. Spino-pelvic parameters after surgery can be predicted: a preliminary formula and validation of standing alignment. *Spine (Phila Pa 1976)*. 2011;36(13):1037-1045. doi:10.1097/BRS.0b013e3181eb9469
20. Diebo BG, Lafage R, Ames CP, et al. Ratio of lumbar 3-column osteotomy closure: patient-specific deformity characteristics and level of resection impact correction of truncal versus pelvic compensation. *Eur Spine J*. 2016;25(8):2480-2487. doi:10.1007/s00586-016-4533-1