

**UCLA**  
**Behavioral Neuroscience**

**Title**

Resources for Teaching Mammalian Neuroanatomy Using Sheep Brains: A Review

**Permalink**

<https://escholarship.org/uc/item/6mj9917w>

**Author**

Grisham, William

**Publication Date**

2006

Peer reviewed

## MEDIA REVIEW

# Resources for Teaching Mammalian Neuroanatomy Using Sheep Brains: A Review

**William Grisham**

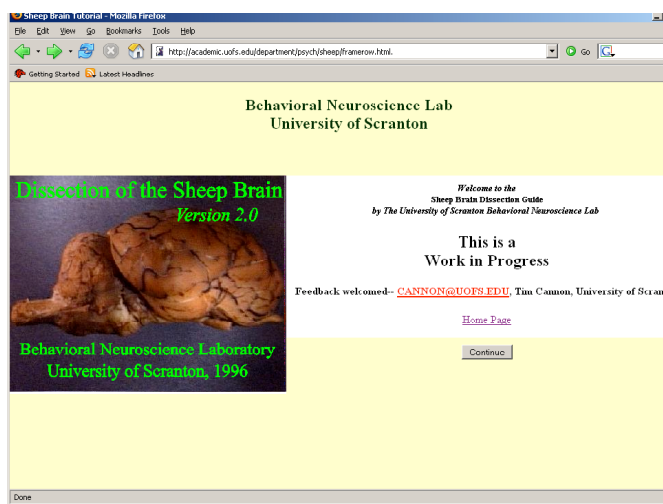
*Department of Psychology, University of California, Los Angeles, 90095-1563.*

Sheep brain dissection is a mainstay of many neuroscience and biological psychology lab courses. Sheep brain dissection is relatively easy and requires only the brains, surgical gloves, and a large, sharp knife without serrations to provide a valuable learning experience. Preserved sheep brains are readily available from a variety of vendors at a reasonable cost. (Getting brains with the dura already removed is highly recommended because students tend to tear up the brain when removing the dura.) Most structures in the sheep brain are highly homologous to structures in the brains of other placental mammals, including humans. Only cortical structures, particularly sulci and gyri, which are not always homologous across mammalian orders, differ markedly between humans and sheep. Thus, specific facts learned from dissecting sheep brains can be readily generalized to other species.

A published hard-copy photographic atlas of the sheep brain is available (Vanderwolf and Cooley, 2002), but searching the internet also reveals many resources made freely available by instructors at a variety of institutions. Most of the websites are designed to be supplements for specific courses, but some are clearly designed for broader use. Many websites could serve as excellent supplements to in-lab dissections, and some could even replace in-lab dissections if resources are tight or if students have ethical objections to using animals.

### Sheep Brain Websites Intended for Broad Use

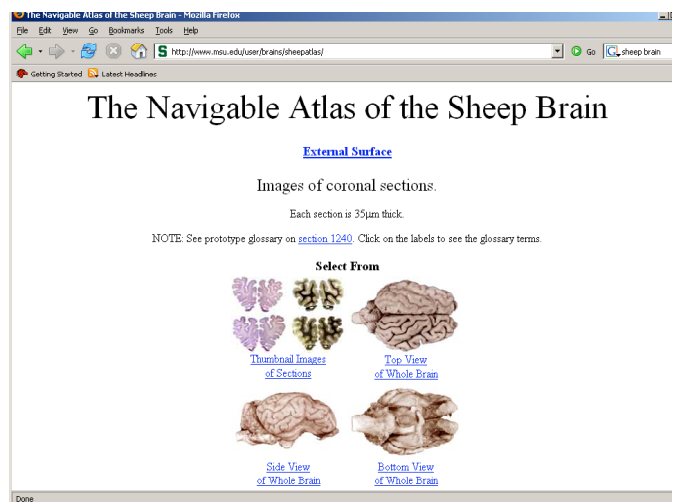
One of the most complete websites comes from the University of Scranton (Figure 1; Wheeler et al., 1996).



**Figure 1.** Screenshot of the U. of Scranton Website maintained by Dr. Tim Cannon. Reproduced by permission.

Students who perform well on neuroanatomy exams rave about how helpful this website is. Like almost all of the websites, this one uses photographs. The pictures are wonderful: they show details well, and even the close-ups have high resolution. The sharpness and color of the pictures make them better than the Vanderwolf and Cooley (2002) atlas, which is only in black-and-white. Unfortunately, the pictures are hard to copy to a computer for offline study. Beginning students sometimes find the close-ups difficult to apprehend; they sometimes lose orientation and find them confusing. The University of Scranton website does allow a user to remove the labels but does not have an explicit quiz function where the pointers stay but the labels disappear. In addition to external views of the brain, the University of Scranton website provides midsagittal views and coronal sections in roughly the same planes as does the Vanderwolf and Cooley atlas. One of the greatest virtues of the University of Scranton website is that it provides extensive explanatory text along with the images. This text is based on text composed at Dartmouth by Robert N. Leaton and revised at Amherst by Charles A. Sorenson and later at UCLA by Darrel Dearnmore, Gaylord Ellison, and Alan Keys where it is still in use in hard copy.

The Michigan State University (MSU) website (Figure 2; Johnson et al., no date) presents no explanatory text but has more labeled structures and presents a more extensive set of coronal images than the University of Scranton website. The coronal sections presented are either cell stains or fiber stains.



**Figure 2.** Screenshot of the Michigan State University website, which is supported by the National Science Foundation. Reproduced by permission of Dr. John Irwin Johnson.

Although these stains help to differentiate the structures, they do not completely resemble what students might see doing dissections with unstained material. The MSU site does not provide any midsagittal sections. Like the University of Scranton website, labels can be hidden but no explicit quiz function is provided. The photographs and histology presented on the MSU website are excellent, except for the external views of the brain, which are in black-and-white and not as crisp and beautiful as the University of Scranton website. The MSU website presents the best and probably most accurate labels on cortical features. All of the images provided can be easily copied for offline study. The MSU website is easily navigated and links to atlases of human brains can also be accessed from this website.

Very few print or web resources on neuroanatomy address neural function. One of the few that does is provided by San Francisco's Exploratorium (Cave and Schwartzenberg, 1998), and it only addresses learning and memory. Although exhibits provided by the Exploratorium are usually excellent, this website was disappointing. When they illustrate the hippocampus, they switch from a sheep brain to a diagram of a human brain. This site is aimed at the general public and provides very little for those wishing to study neuroanatomy in depth.

The Brain Museum collection (Welker et al., no date) was also disappointing. Although it has the potential for being a treasure trove for web-bound neuroscientists, it only offers external views of the sheep brain with neither coronal nor sagittal sections (although coronals are provided for other species). This site has links addressing circuits and function but both just give very general information and neither are terribly edifying. No brain of any species has labels. Accordingly, this site has only limited utility for teaching neuroanatomy.

### Websites Designed as Supplements for Specific Courses

University of Pennsylvania's Veterinary School website (2001) provides some unusually oblique but informative dissections that allow students to get a better grasp on the three-dimensional configuration of structures such as the hippocampus and its spatial relationship to the amygdala. Unfortunately, they use some of these same oblique views to show the pyriform cortex, which is suboptimal because they do not give a full view of the pyriform cortex. Again, students are probably better off using the Michigan State website for cortical features. Images on the Penn website are very good quality, the dissections are masterful, and the pictures are easy to copy for offline study. It provides a midsagittal section of a sheep brain and coronal sections that highlight given structures when clicked, which is useful, but it is unclear which species were used for these (dogs and sheep may be intermixed but admittedly, they are not that different in subcortical structures). Structures are extensively labeled in all views presented.

A Penn State University website (Strauss, no date) focuses on special senses and brain, so it is a somewhat superficial treatment of sheep brain anatomy and not nearly as extensive as those discussed above. This

website does provide a quiz function. It also offers good views of unstained coronals that students would see in their dissections. Coronal sections match well with Vanderwolf and Cooley sections, and a nice midsagittal is presented. No descriptive text is provided, but the photos are high quality and can be easily copied for offline viewing.

Another website giving students an opportunity to quiz themselves comes from California State University, Sacramento (Carter, no date). Unfortunately, the images on the quiz are minimized and difficult to see. This site is one of the few providing horizontal sections. Unfortunately, because the structures are not explicitly labeled and the photos are washed out, clearly discerning structures and differences between gray and white matter is difficult on the horizontal views. Coronal sections are promised but I was unable to access them, and no sagittal sections are provided. Images are easy to copy for offline viewing, but there is no descriptive text.

A site providing breathtaking views of cranial nerves comes from Kent State University (York, no date), and is meant as an aid for a comparative anatomy course. This site provides good quality external and midsagittal photos that can be easily copied for offline viewing but only includes one coronal section and no text.

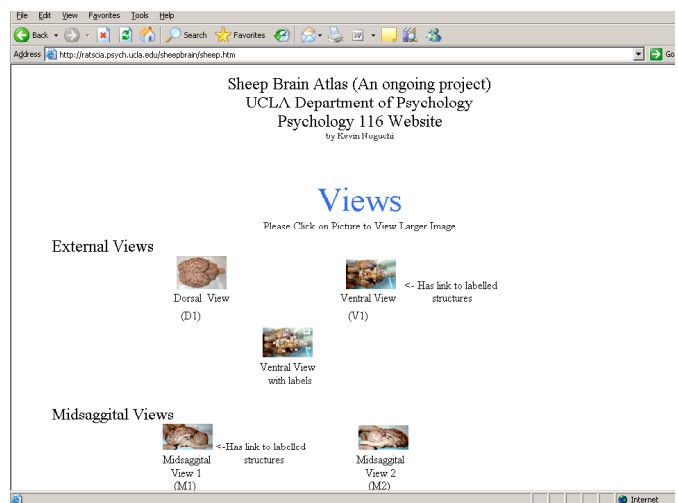

Figure 3. Screenshot of the splash page for the UCLA sheep brain website. Reproduced by permission of website's creator, Dr. Kevin Noguchi.

UCLA's offering comes from a website constructed by a former teaching assistant (Noguchi, no date) as a supplementary resource for our mammalian neuroanatomy module. The pictures are very good quality and easy to copy for online study. Unfortunately, the dorsal view and coronal and horizontal sections are not labeled. This website provides students with excellent views of what they will see during their dissection as well as views of human brains, but no descriptive text is provided.

The University of California, Davis offers a brief overview of gross brain anatomy as a part of a class in comparative anatomy (Guinan, no date). Unfortunately, some of the pictures are of poor quality and so do not

convey much. To its credit, some descriptive text accompanies the images. Cranial nerves are pointed out but not explicitly labeled. Only one coronal section is provided.

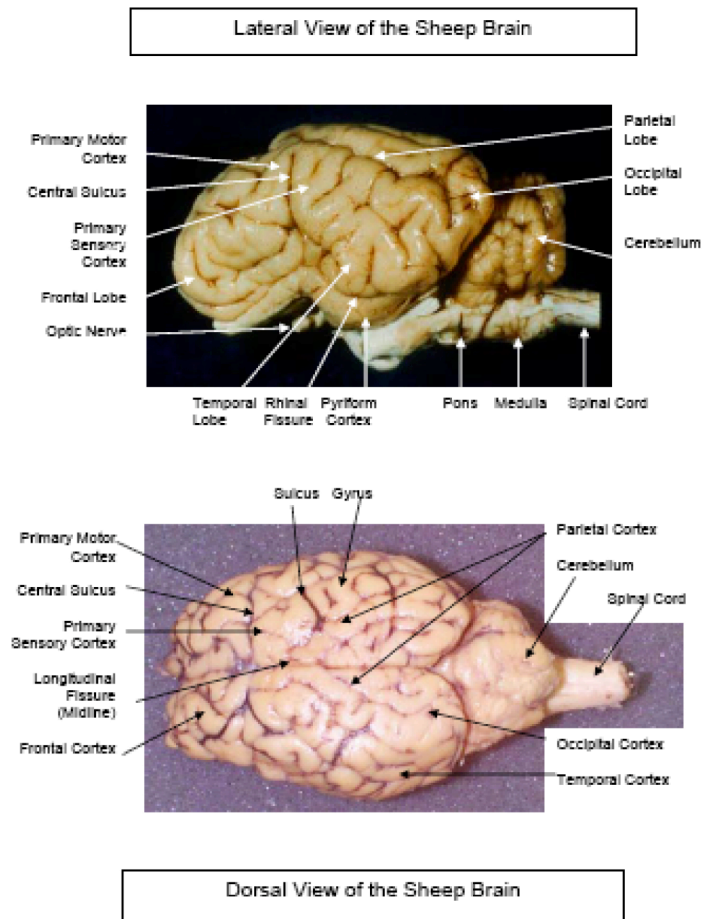


Figure 4. Page from Barnard College sheep brain PDF. Reproduced by permission of Dr. K. Taylor.

A site that provides good descriptive text along with good quality images is the Barnard College website (Taylor, no date). Information provided is accurate, although one cortical feature is given a non-standard label—see below on differences of opinion. The Barnard College website provides sagittal views and some coronal sections but far fewer than either the University of Scranton or the MSU websites and only a limited number of labels. Because it comes as a PDF, it is easily downloadable for offline study.

The St. Louis University website (Stark, no date) also provides good text for guiding dissection. Further, this site actually addresses neural systems and directs some dissections accordingly. It is one of the few websites to address function to any degree although it only addresses cranial nerve function. Very nice views of the cranial nerves are provided including the trochlear, which isn't shown in the Vanderwolf and Cooley (2002) atlas. Excellent quality views of the diagonal band and lateral olfactory tract and the rest of the rhinencephalon that can be visualized from an external view are also provided.

Superb dissection allows views of tracts such as the fornix, mammillothalamic tract, and habenulo-peduncular tract. Other nice dissections provide good views of the cerebellar peduncles. This website does not do much with either cerebral or cerebellar cortical features, but otherwise, the external views are really good and have good labels. No coronal sections are presented. Unfortunately, not all views have labels, and one clearly shows ungloved hands holding a brain, which is a safety violation. This website is one of the few to provide a horizontal section—one view without labels.

Grand Valley State University's website (Paschke and Xu, 1998) is one of the most unusual because it does not present photographs but rather line drawings based on the Vanderwolf and Cooley (2002) atlas. It includes external views and some of Vanderwolf and Cooley's more ambitious dissections revealing the hippocampus and the dissected brainstem. A brief descriptive text is present, and labels are included on the drawings. Drawings of coronal and horizontal sections are not presented.

A surprising number of the websites available come from community and two-year colleges. Among them is Community College of Baltimore County (Lathrop-Davis and Gorski, 2002). This site provides limited descriptive text and only external and sagittal sections with few labels but no horizontal or coronal sections. The images are not as crisp and clean as University of Scranton website and don't have as much detail, but they can be copied for offline study. Another offering comes from Victoria College in Texas (Hamilton, no date). This website has fairly ugly pictures of a sheep brain, but the photos could be copied for offline study. The Victoria College site provides external and sagittal photos that are exactly what a student might encounter in their own less-than-perfect dissections and are displayed as in a lab practical replete with pins. This site is not an in-depth treatment of neuroanatomy, and no text is provided. Another site comes from Bay Path College in Longmeadow, MA (Semprebon, no date). The quality of the pictures is passable, but the brain that they selected is not terribly pretty. This site is also not an in-depth treatment, providing only external and midsagittal features. Furthermore, there are a couple of errors in labeling.

One of the most interactive websites comes from GateWay Community College in Arizona (Crimando, 2005). Although it only presents sagittal sections and is the only one to present parasagittal sections, it has a lot of features and is an innovative website. The names of structures pop up and one drags the cursor over them, and a thumbnail sketch of the midsagittal highlights a drawing of the entire structure as the cursor moves over it. Students can quiz themselves with this feature since the name isn't revealed until the user clicks. Also, the user can request multiple-choice items on some of the structures that even address function.

Only one movie of sheep brains is presently available on the web, displaying the actual dissection of a sheep brain (Yu, 2004). Freeze frames at the end of the video label the structures, which are mentioned in the narration. Unfortunately, the movie is so fast-paced that it would be



difficult for the novice to ascertain what name went with which structure, especially since the narration is a little out of synchrony with the gestures of the person doing the dissection. Not many structures are illustrated, but it does offer a nice view of the dorsal brainstem along with the hippocampus.

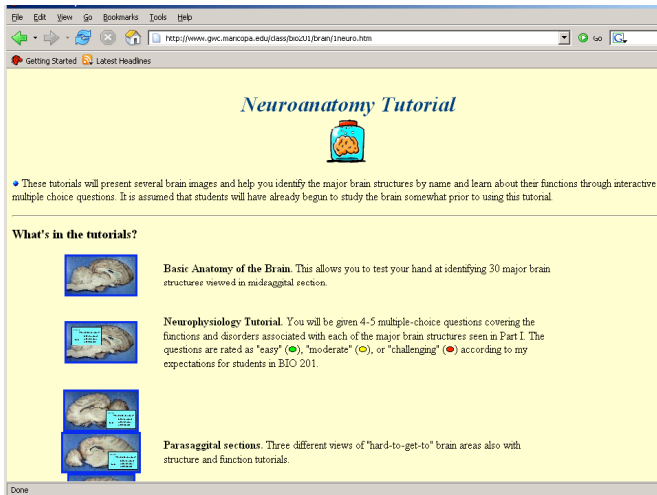


Figure 5. Screenshot of the splash page for the GateWay Community College. Reproduced by permission of Dr. J. Crimando.

### Points of Disagreement, Quibbles, and Errors

Although a vast number of sheep brains are studied in undergraduate neuroscience laboratory classes each year, very little modern research on the neuroanatomy of sheep or ungulates has been undertaken. Accordingly, some websites and text sources differ on the naming of structures. A case in point is the cruciate sulcus. The cruciate sulcus (cross-shaped because it makes a cross with the longitudinal fissure) is proclaimed to be homologous to the central sulcus or fissure of Rolando in humans by the Dartmouth/Amherst/UCLA text. Nonetheless, the most complete source on sheep brain cortex (Ariens Kappers et al., 1967) proclaims that, although carnivores do have a cruciate sulcus, no homologous sulcus has been identified with certainty in ungulates, including sheep. In carnivores, the cruciate is a deep sulcus that extends from the rostral midline running fairly far lateral on the dorsal surface across both hemispheres. The cruciate sulcus can be seen clearly in dog (Figure 6). Sheep have a similar deep sulcus in about the right position, except theirs does not extend very far laterally. The MSU website labels this particular sulcus as the "crucial," and the University of Pennsylvania Veterinary School website as well as a text on ruminant neuroanatomy (Dellmann and McClure, 1975) call this the cruciate sulcus. Other texts label this same sulcus as the splenial in sheep (Ariens Kappers et al., 1967; Lauer, 1982). The University of Scranton website does not label this sulcus but instead labels a more caudal and shallow sulcus as the cruciate. This latter sulcus is labeled as the ansate or ansatus both by the MSU website and other texts (Ariens Kappers et al., 1967; Skinner, 1971; Dellmann and McClure, 1975; Vanderwolf and Cooley, 2002). The

Barnard College website labels this ansatus as the central sulcus, and Ariens Kappers et al. concur that the ansatus is the forerunner of the central sulcus. Skinner (1971) claims that the region on either side of the ansate is sensorimotor cortex, but this claim is based on extrapolation from Krieg (1954), who only worked on rats and rhesus monkeys. Thus, we probably do not know for sure which sulcus of sheep is homologous to the central sulcus in humans and where the boundary between the frontal and parietal lobes is.

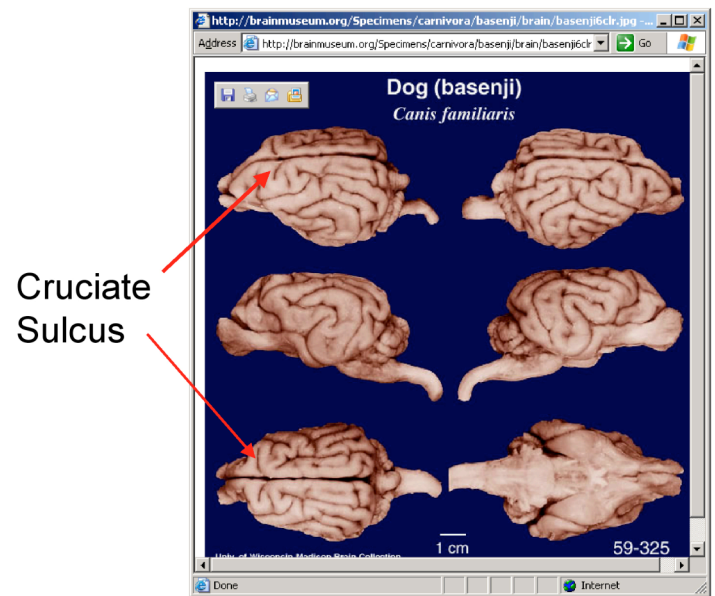


Figure 6. View of the cruciate sulcus in the dog. Label provided by the reviewer. Photos from the Brain Museum, which is funded by the National Science Foundation (See Welker et al.) Reproduced by permission.

Differences also exist in naming regions of the pyriform area. The MSU website labels part of the pyriform area as parahippocampal gyrus, whereas the University of Scranton website labels the same area as hippocampal gyrus. The MSU website further differentiates the pyriform area by separately labeling the periamygdaloid cortex. The Grand Valley State University website similarly labels the anterior portion of the pyriform as periamygdaloid cortex and designates the posterior portion as entorhinal cortex. The Vanderwolf and Cooley (2002) atlas labels the periamygdaloid area as the uncus, which is what it is called in humans. The St. Louis University website labels this same area as the amygdaloid nucleus, which cannot be accurate because the amygdala is not a surface structure. This latter confusion ultimately may stem from the Dartmouth/Amherst/UCLA text, which muddles this point somewhat.

Some errors can be found on some websites, but even these can be used creatively toward instructional ends. Instructors can put the mislabeled image on an exam and ask students to identify what is wrong with the picture. Such items definitely will discriminate between those students who have a good command of the material and those that do not. Good examples come from the Penn

Vet School: in cross-sections of the caudal brainstem, they seem to have confused the medial lemniscus and the pyramidal tract in a couple of instances: the medial lemniscus is mislabeled as the decussation of the pyramids

Author(s) Institution URL	Text	Quiz	Coronal Views	Sagittal Views
<b>Carter</b> Cal. State Sacramento <a href="http://www.csus.edu/org/nrg/carter/carter.htm">http://www.csus.edu/org/nrg/carter/carter.htm</a>		•		
<b>Cave &amp; Schwartzberg</b> Exploratorium <a href="http://www.exploratorium.edu/memory/braindissection/">http://www.exploratorium.edu/memory/braindissection/</a>	•			•
<b>Crimando</b> GateWay Comm. College <a href="http://www.gwc.maricopa.edu/class/bio201/brain/1neuro.htm">http://www.gwc.maricopa.edu/class/bio201/brain/1neuro.htm</a>		•		•
<b>Guinan</b> UC, Davis <a href="http://trc.ucdavis.edu/mjguinan/apc100/modules/Nervous/_topics.html">http://trc.ucdavis.edu/mjguinan/apc100/modules/Nervous/_topics.html</a>			•	•
<b>Hamilton</b> Victoria College <a href="http://www.victoriacollege.edu/dept/bio/Brain/Index.htm">http://www.victoriacollege.edu/dept/bio/Brain/Index.htm</a>				•
<b>Johnson et al.</b> MSU <a href="http://www.msu.edu/user/brains/sheepatlas/">http://www.msu.edu/user/brains/sheepatlas/</a>			•	•
<b>Lathrop-Davis &amp; Gorski</b> Comm. Coll. Baltimore Co. <a href="http://student.cbcemd.edu/c_anatomy/sheep_brain/">http://student.cbcemd.edu/c_anatomy/sheep_brain/</a>				•
<b>Noguchi</b> UCLA <a href="http://ratscia.psych.ucla.edu/sheepbrain/sheep.htm">http://ratscia.psych.ucla.edu/sheepbrain/sheep.htm</a>			•	•
<b>Paschke &amp; Xu</b> Grand Valley State Univ. <a href="http://www.gvsu.edu/psych/index.cfm?id=24F7B8A5-C397-C30A-FFC2AD8B0CA4CAB0">http://www.gvsu.edu/psych/index.cfm?id=24F7B8A5-C397-C30A-FFC2AD8B0CA4CAB0</a>	•			•
<b>Semprebon</b> Bay Path College <a href="http://web.baypath.edu/biology/sheep%20brain/brain-sheep.html">http://web.baypath.edu/biology/sheep%20brain/brain-sheep.html</a>				•
<b>Stark</b> St. Louis Univ. <a href="http://starklab.slu.edu/neuro/Dissection.htm">http://starklab.slu.edu/neuro/Dissection.htm</a>	•		•	•
<b>Strauss</b> Penn State Univ. <a href="http://www.bio.psu.edu/people/faculty/strauss/anatomy/nerv/nervous.htm">http://www.bio.psu.edu/people/faculty/strauss/anatomy/nerv/nervous.htm</a>		•	•	•
<b>Taylor</b> Barnard College <a href="http://bc.barnard.edu/~ktaylor/Neuroanatomy.pdf">http://bc.barnard.edu/~ktaylor/Neuroanatomy.pdf</a>	•		•	•
<b>Univ. Pennsylvania Veterinary School</b> <a href="http://cal.vet.upenn.edu/neuro/server/lab4frameset.html">http://cal.vet.upenn.edu/neuro/server/lab4frameset.html</a>				•
<b>Welker et al.</b> Brain Museum <a href="http://brainmuseum.org/Specimens/index.html">http://brainmuseum.org/Specimens/index.html</a>	•			
<b>Wheeler et al.</b> Univ. of Scranton <a href="http://academic.uofs.edu/department/psych/sheep/framerow.html">http://academic.uofs.edu/department/psych/sheep/framerow.html</a>	•		•	•
<b>York</b> Kent State Univ. <a href="http://fp.dl.kent.edu/hyork/catshb1.htm">http://fp.dl.kent.edu/hyork/catshb1.htm</a>			•	•
<b>Yu</b> Wellesley College <a href="http://www.wellesley.edu/Biology/Concepts/Html/sheepbrain.html">http://www.wellesley.edu/Biology/Concepts/Html/sheepbrain.html</a>				

Table 1. Summary Table of Websites Reviewed

in one view and the pyramidal tract is labeled medial lemniscus in another. Also their view of the septal nuclei is rather shabby since what they call septal nuclei is mostly fornix at the level in which they sectioned. On UCLA's sheep brain site, the olfactory bulb is shown to be more extensive than it really is. Similarly, on the UC Davis website, the cross section displaying the thalamus actually labels a lot of structures as thalamus that are not. The Kent State University labels the olfactory bulb as the olfactory nerve, which is not present because it inevitably gets destroyed in dissection. The Kent State site also labels the hypothalamic protrusion, which is the tuber cinerium/median eminence, as the infundibulum, which has actually been removed in their image. Some labels on the Baypath College site are definitely wrong: "cerebral aqueduct" is on the fourth ventricle, the label for trigeminal nerve is actually on the cerebral peduncle next to the oculomotor nerve, and the label for the spinal cord is actually on the caudal medulla. Finally, the University of Pennsylvania website shows the third ventricle off the midline, which is not correct.

### Summary

Teaching neuroanatomy gives students not only the nomenclature of nervous system structures, but also a framework for understanding the function of the brain. Using sheep brains is an effective way to present the material in a very concrete way. The internet offers a storehouse of free resources for teaching mammalian neuroanatomy based on sheep brain dissection.

Unfortunately, both textbook and web resources tend to focus on teaching structure and rarely address either circuits or function. Nonetheless, teaching neuroanatomy exclusively focused on structure does not necessarily impart a deeper understanding of the brain. A more reasoned approach to the material involves thinking of neuroanatomy in terms of neural pathways and their functional characteristics both in health and disease. The photographic atlas of Vanderwolf and Cooley (2002) offers schematic diagrams of both sensory and motor neural circuits, which none of the websites do. Unfortunately, the Vanderwolf and Cooley (2002) atlas makes no reference to function nor do most of the neuroanatomy texts and websites reviewed. Thus, instructors are left to fill-in these essential parts of the lesson with other resources.

### REFERENCES

- Ariens Kappers CU, Huber CG, Crosby EC (1967) The comparative anatomy of the nervous system of vertebrates including man (Volume 3). New York: Hafner, p 1532.
- Carter R. (no date) *Sheep brain external anatomy and internal anatomy*. (California State University, Sacramento) Retrieved February 27, 2006 from <http://www.csus.edu/org/nrg/carter/carter.htm>
- <http://www.csus.edu/org/nrg/carter/NeurosyActive/sheepbrain/index.htm>.
- Cave S, Schwartzberg S (1998) *Sheep brain dissection: The anatomy of memory*. (San Francisco's Exploratorium). Retrieved March 6, 2006 from <http://www.exploratorium.edu/memory/braindissection/>.

- Crimando J (2005) *Neuroanatomy tutorial*. (GateWay Community College) Retrieved March 17, 2006 from <http://www.gwc.maricopa.edu/class/bio201/brain/1neuro.htm>.
- Delmann H-D, McClure RC (1975) Ruminant central nervous system. In: *The anatomy of the domestic animals*. (Getty R, ed.). Philadelphia, PA: W. B. Saunders.
- Guinan M. (no date) *Topics*. (University of California, Davis). Retrieved March 6, 2006 from [http://trc.ucdavis.edu/mjguinan/apc100/modules/Nervous/\\_topics.html](http://trc.ucdavis.edu/mjguinan/apc100/modules/Nervous/_topics.html).
- Hamilton J (no date) *Sheep brain*. (Victoria College, Victoria Texas). Retrieved March 8, 2006 from <http://www.victoriacollege.edu/dept/bio/Brain/Index.htm>.
- Johnson JI, Sudheimer KD, Davis KK, Winn BM (no date) *The navigable atlas of the sheep brain*. (Michigan State University) retrieved February 27, 2006 from <http://www.msu.edu/user/brains/sheepatlas/>.
- Krieg WJS (1954) *Collected papers relating to the cerebrum*. Springfield, Ill.: Charles C. Thomas.
- Lathrop-Davis E, Gorski E (2002) *Central nervous system*. (Community College of Baltimore County). Retrieved March 7, 2006 from [http://student.ccbcmd.edu/c\\_anatomy/sheep\\_brain/](http://student.ccbcmd.edu/c_anatomy/sheep_brain/).
- Lauer EW (1982) Telencephalon of ungulates. In: *Comparative correlative neuroanatomy of the vertebrate telencephalon* (Crosby EC and Schnitzlein HN, eds). New York, NY: Macmillan.
- Noguchi K (no date) *Sheep brain atlas (An ongoing project)*. (University of California, Los Angeles). Retrieved May 30, 2006 from <http://ratscia.psych.ucla.edu/sheepbrain/sheep.htm>.
- Paschke RE, Xu X (1998). *Sheep Brain*. (Grand Valley State University) Retrieved February 23, 2006 from <http://www.gvsu.edu/psych/index.cfm?id=24F7B8A5-C397-C30A-FFC2AD8B0CA4CAB0>.
- Semprebon GM (no date) *Sheep brain*. (Bay Path College, Longmeadow, MA). Retrieved March 5, 2006 from <http://web.baypath.edu/biology/sheep%20brain/brain-sheep.html>.
- Skinner JE (1971) *Neuroscience: A laboratory manual*. Philadelphia, PA: W. B. Saunders.
- Stark WS (no date) *Dissection of the sheep brain*. (St. Louis University) Retrieved February 27, 2006 from <http://starklab.slu.edu/neuro/Dissection.htm>.
- Strauss J (no date) *Nervous system and special senses*. (Pennsylvania State University) Retrieved February 27, 2006 from <http://www.bio.psu.edu/people/faculty/strauss/anatomy/nervous.htm>.
- Taylor KM (no date) *Neuroanatomy: Dissection of the sheep brain*. (Barnard College) Retrieved March 6, 2006 from <http://bc.barnard.edu/~ktaylor/Neuroanatomy.pdf>.
- University of Pennsylvania Veterinary School website (2001) *Neuroscience lab 4 - Gross brain sheep brain - dorsal view*. Retrieved February 27, 2006 from <http://cal.vet.upenn.edu/neuro/server/lab4frameset.html>.
- Vanderwolf CH, Cooley RK (2002) *The sheep brain: A photographic series*. London, Ontario: A.J. Kirby Co.
- Welker W, Johnson JI, Noe A (no date) *Comparative mammalian brain collections*. (University of Wisconsin, Michigan State University, and the National Museum of Health and Medicine) Retrieved March 10, 2006 from <http://brainmuseum.org/Specimens/index.html>.
- Wheeler RA, Baldwin AE, Reid RS, Quinn JJ, Cannon JT (1996) *Dissection of the sheep brain*. (University of Scranton) Retrieved February 23, 2006 from <http://academic.uofs.edu/departments/psych/sheep/framerow.html>.
- York H (no date) *Sheep brain*. (Kent State University). Retrieved March 6, 2006 from <http://fp.dl.kent.edu/hyork/catshb1.htm>.
- Yu C (2004) *Digital videos: sheep dissection*. (Wellesley College maintained by: Carol Ann Paul) Retrieved March 6, 2006 from <http://www.wellesley.edu/Biology/Concepts/Html/sheepbrain.html>

Address correspondence to: William Grisham, Ph.D., Department of Psychology, UCLA, 1285 Franz Hall, P.O. Box 951563, Los Angeles, CA 90095-1563 [grisham@lifesci.ucla.edu](mailto:grisham@lifesci.ucla.edu)