

UC Irvine

UC Irvine Previously Published Works

Title

Biomechanical investigation of arm position on deforming muscular forces in proximal humerus fractures

Permalink

<https://escholarship.org/uc/item/6n188037>

Journal

Clinics in Shoulder and Elbow, 25(4)

ISSN

2383-8337

Authors

Chalmers, Christen E
Wright, David J
Patel, Nilay A
[et al.](#)

Publication Date

2022-12-01

DOI

10.5397/cise.2022.00885

Peer reviewed



Biomechanical investigation of arm position on deforming muscular forces in proximal humerus fractures

Christen E. Chalmers¹, David J. Wright¹, Nilay A. Patel¹, Hunter Hitchens², Michelle McGarry³,
Thay Q. Lee³, John A. Scolaro¹

¹Department of Orthopedic Surgery, University of California Irvine, Irvine, CA, USA

²Cornell University, Ithaca, NY, USA

³Orthopaedic Biomechanics Laboratory, Congress Medical Foundation, Pasadena, CA, USA

Background: Muscular forces drive proximal humeral fracture deformity, yet it is unknown if arm position can help mitigate such forces. Our hypothesis was that glenohumeral abduction and humeral internal rotation decrease the pull of the supraspinatus and subscapularis muscles, minimizing varus fracture deformity.

Methods: A medial wedge osteotomy was performed in eight cadaveric shoulders to simulate a two-part fracture. The specimens were tested on a custom shoulder testing system. Humeral head varus was measured following physiologic muscle loading at neutral and 20° humeral internal rotation at both 0° and 20° glenohumeral abduction.

Results: There was a significant decrease in varus deformity caused by the subscapularis ($p < 0.05$) at 20° abduction. Significantly increasing humeral internal rotation decreased varus deformity caused by the subscapularis ($p < 0.05$) at both abduction angles and that caused by the supraspinatus ($p < 0.05$) and infraspinatus ($p < 0.05$) at 0° abduction only.

Conclusions: Postoperative shoulder abduction and internal rotation can be protective against varus failure following proximal humeral fracture fixation as these positions decrease tension on the supraspinatus and subscapularis muscles. Use of a resting sling that places the shoulder in this position should be considered.

Keywords: Proximal humeral fracture; Biomechanics; Rotator cuff; Shoulder joint

INTRODUCTION

Surgical fixation of proximal humeral fractures remains a clinical challenge and an area of ongoing investigation [1,2]. Alternative treatment options, including nonoperative management and arthroplasty, have been proposed for some fracture patterns and patient populations given the challenges experienced with surgi-

cal fracture fixation. Intra-operative techniques to augment fixation have been extensively explored and implemented to improve fracture fixation [3,4]. A paucity of research exists on post-surgical interventions and rehabilitation protocols that could potentially decrease the rates of fixation failure and malalignment.

Muscular forces acting on the shoulder have been shown to drive fracture deformity [5]. Muscle tension drives initial fracture

Received: February 22, 2022 Revised: April 12, 2022 Accepted: April 28, 2022

Correspondence to: John A. Scolaro

Department of Orthopedic Surgery, University of California Irvine, 101 The City Drive S Pavilion III, Building 29A Orange, CA 92868, USA

Tel: +1-714-456-7012, Fax: +1-714-456-7547, E-mail: jscolaro@hs.uci.edu, ORCID: <https://orcid.org/0000-0001-7926-5017>

Financial support: This study was funded by a grant from the Foundation for Orthopedic Trauma.

Conflict of interest: None.

Copyright© 2022 Korean Shoulder and Elbow Society.

This is an Open Access article distributed under the terms of the Creative Commons Attribution Non-Commercial License (<http://creativecommons.org/licenses/by-nc/4.0/>) which permits unrestricted non-commercial use, distribution, and reproduction in any medium, provided the original work is properly cited.

displacement, counteracts fracture reduction efforts, is present at all points following surgery, and has a role in reduction failure. Initial work with a two-part proximal humeral fracture model demonstrated that the supraspinatus and subscapularis muscles are the primary and secondary drivers of varus fracture deformity with the arm in a neutral position. However, patients are typically placed in a sling or brace with the arm in variable abduction and/or internal rotation during the postoperative period.

The purpose of this study was to determine if arm position affected the deforming muscular forces of the shoulder. We specifically sought to identify if humeral abduction or internal rotation affected varus deformity. Our hypothesis was that glenohumeral abduction would mitigate deformity caused by the superior cuff muscles, while internal rotation would decrease varus fracture deformity caused by the anterior cuff muscles.

METHODS

No Institutional Review Board approval was required for this biomechanical laboratory study which did not require patient consent or involve patient protected health information.

Eight fresh-frozen cadaveric shoulder specimens from four female and four male donors (mean age, 64 years; range 48–72 years) were used. All subcutaneous tissue and muscle bellies were removed from specimens, while the coracoacromial ligament and tendinous insertions of the subscapularis, supraspinatus, infraspinatus, teres minor, and deltoid remained intact. A standard Krackow locking suture was placed through each tendon using No. 2 FiberWire (Arthrex, Naples, FL, USA). The humerus was transected 2 cm distal to the deltoid tuberosity, and the proximal humerus was disarticulated from the glenoid through the shoulder capsule. Rotator cuff repairs had been previously performed in some specimens and were evaluated and reinforced, if necessary. In two specimens, a full thickness single rotator cuff muscle tear was discovered during dissection. Therefore, an allograft tendon was attached via suture anchors to the anatomic footprint.

Next, a two-part fracture (AO/OTA 11A2.2) consisting of a head fragment and shaft fragment was created by first making a 1-cm medial wedge osteotomy in each specimen. The wedge extended two thirds of the medial-to-lateral diameter of the proximal humerus just distal to the humeral head articular surface. After creation of the medial wedge, the final one third of the osteotomy was completed through the lateral cortex in a linear fashion to complete the two-part fracture. By preserving cortical contact at the lateral aspect of the medial wedge osteotomy, the fracture model was able to be anatomically aligned after each

testing trial. This created a consistent, reproducible starting position prior to muscle loading. To digitize the position of the humerus in each loading condition, a MicroScribe (Model G; Revware Inc., Raleigh, NC, USA) was used. Digitization reference points included six unicortical screws placed 1.5 cm apart on either side of the osteotomy along the lateral cortex of the proximal humerus (Fig. 1). One screw was placed in the coracoid and two screws were placed in the acromion for use as constant reference points. Finally, two elastic bands were placed parallel to each other, around the lateral reference screws adjacent to the osteotomy site. The purpose of these bands was to maintain stable cortical contact between the proximal and distal fragments at the lateral one-third of the osteotomy, while still allowing for motion in all planes between the humeral head and shaft.

Each specimen was mounted with the scapula fixed to a metal plate and positioned at 0° abduction and 20° anterior tilt in the sagittal plane on a custom, validated shoulder testing system (Fig. 2) [6]. The humeral shaft was fixed to an intramedullary rod connected to a 360° goniometer sensor (Novotechnik U.S. Inc., Southborough, MA, USA) and secured to a hemi-

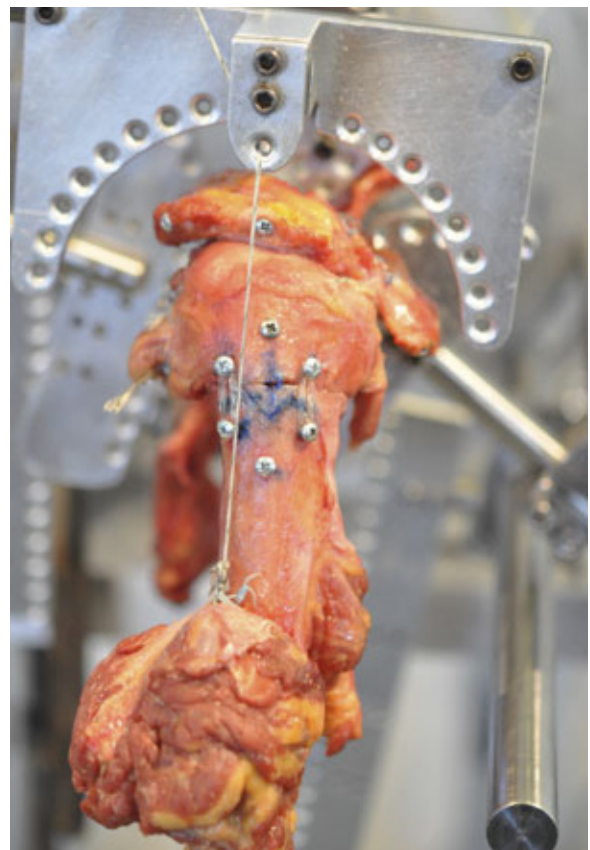


Fig. 1. Lateral view of the proximal humerus and digitization reference screws surrounding osteotomy along the lateral cortex.




Fig. 2. Lateral view of the proximal humerus and scapula mounted on the custom shoulder testing jig.

spheric arc that allowed for varying angles of abduction and rotation. Glenoid inclination was measured, and 0° glenohumeral abduction was set to match glenoid inclination. Neutral humeral axial rotation was set with the humeral head concentrically aligned within the glenoid cavity.

Physiologic muscle loading during testing was simulated using braided low-stretch fishing line (Izorline, Paramount, CA, USA) tied to the Krakow sutures at the musculotendinous junctions. The lines were fed through adjustable pulleys on the shoulder testing system, which reproduced the native force vector generated by each muscle *in vivo*. To maintain concentric positioning of the humeral head, a balanced muscle loading consisting of the following loads was applied: subscapularis, 5 N; infraspinatus, 2.5 N; teres minor, 2.5 N; deltoid, 5 N. Due to the presence of the medial wedge, any load applied to the supraspinatus caused the humeral head to fall into varus deformity, so the supraspinatus

was not included in the balanced muscle load. For unbalanced individual loading, each muscle was tested by applying an additional 2.5 N, 5 N, and 7.5 N to the balanced load condition. To evaluate the role of glenohumeral abduction and humeral internal rotation on varus fracture deformity based on shoulder musculature, measurements were performed following muscle loading at neutral and 20° internal rotation and at 0° and 20° glenohumeral abduction.

All measurements were performed twice in all testing conditions, and the average of these values was used in data analysis. The primary outcome of this study was impact of glenohumeral abduction on the deforming muscular forces contributing to varus collapse (Fig. 3). The secondary outcome was impact of humeral internal rotation on varus collapse. A Shapiro-Wilk Normality test was performed, and the data were deemed not normal. Thus, a non-parametric Wilcoxon signed-rank test was used to compare varus collapse between testing conditions. Data are presented as mean \pm standard error of the mean. The threshold for statistical significance was defined as $p < 0.05$.

RESULTS

Primary Outcome

At a load of 2.5 N or 5 N, there were no significant differences in varus fracture deformity caused by the rotator cuff musculature or deltoid when comparing glenohumeral abduction. At a load of 7.5 N, with the shoulder internally rotated, there was a significant decrease in varus fracture deformity caused by the subscapularis ($13.8^\circ \pm 3.1^\circ$ vs. $12.0^\circ \pm 2.2^\circ$, $p = 0.018$). There were no significant differences in varus deformity with changing abduction angle caused by the infraspinatus, teres minor, supraspinatus, or deltoid (Figs. 4-6).

Secondary Outcomes

At a load of 2.5 N, humeral internal rotation significantly decreased varus fracture deformity caused by the supraspinatus ($13.6^\circ \pm 3.5^\circ$ vs. $6.9^\circ \pm 2.8^\circ$ varus deformity, $p = 0.021$) and infraspinatus ($9.5^\circ \pm 3.3^\circ$ vs. $5.1^\circ \pm 2.6^\circ$ varus deformity, $p = 0.036$) at 0° glenohumeral abduction but not at 20° glenohumeral abduction. Alternatively, at 20° glenohumeral abduction, humeral head internal rotation significantly decreased varus deformity caused by the subscapularis ($6.3^\circ \pm 3.2^\circ$ vs. $3.4^\circ \pm 2.0^\circ$ varus deformity, $p = 0.028$); this did not occur at 0° glenohumeral abduction. There were no significant differences in varus deformity with humeral internal rotation caused by the teres minor or deltoid at a load of 2.5N (Figs. 4-6).

At a load of 5N, humeral internal rotation significantly de-

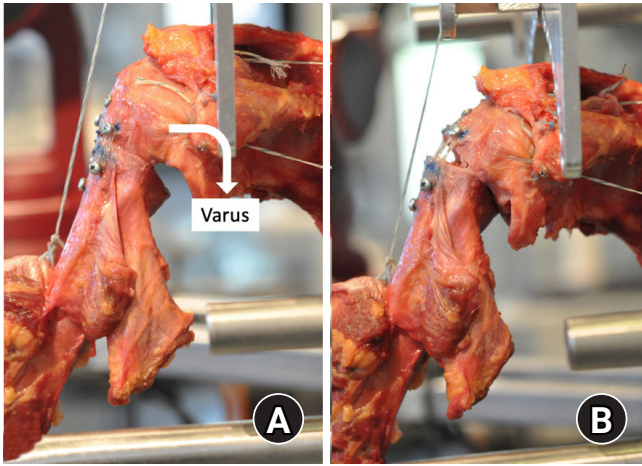


Fig. 3. Anterior to posterior view of the two-part proximal humerus fracture with defining direction of varus fracture deformity (A). Varus fracture deformity produced by loading the supraspinatus (B).

creased varus deformity caused by the subscapularis at both 0° ($15.5^\circ \pm 1.6^\circ$ vs. $6.1^\circ \pm 2.2^\circ$ varus deformity, $p=0.017$) and 20° ($12.9 \pm 2.6^\circ$ vs. $8.4 \pm 2.0^\circ$ varus deformity, $p=0.018$) glenohumeral abduction. Humeral head internal rotation also significantly decreased varus deformity caused by the supraspinatus ($28.1^\circ \pm 1.1^\circ$ vs. $20.2^\circ \pm 3.8^\circ$ varus deformity, $p=0.036$) at 0° but not 20° glenohumeral abduction. There were no significant differences in varus deformity caused by the infraspinatus, teres minor, or deltoid with humeral internal rotation at a load of 5 N (Figs. 4-6).

At a load of 7.5 N, humeral internal rotation significantly decreased varus deformity caused by the subscapularis at both 0° ($21.7^\circ \pm 3.1^\circ$ vs. $13.8^\circ \pm 3.1^\circ$ varus deformity, $p=0.028$) and 20° ($14.5^\circ \pm 2.7^\circ$ vs. $12.0^\circ \pm 2.2^\circ$ varus deformity, $p=0.028$) glenohumeral abduction. There were no significant differences in varus deformity with humeral internal rotation caused by the supraspi-

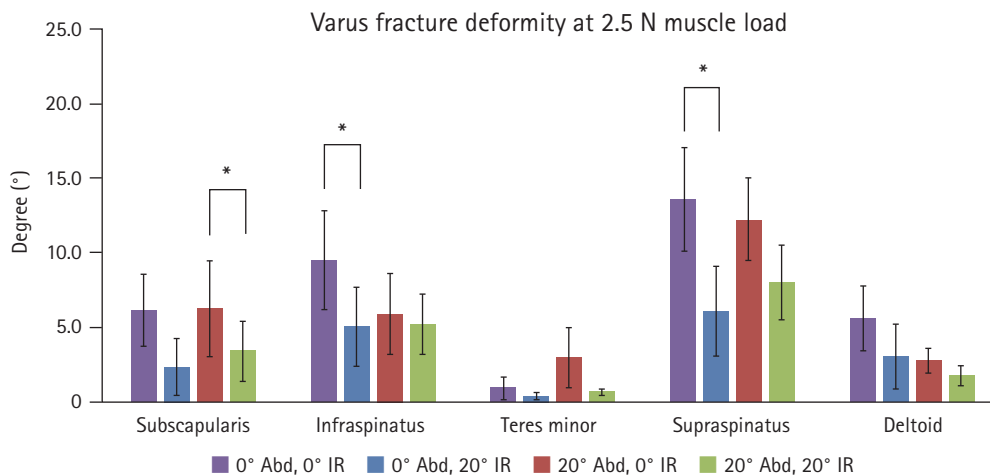


Fig. 4. Relative varus fracture deformity produced by the rotator cuff musculature and deltoid with a load of 2.5 N at 0° and 20° glenohumeral abduction and at neutral and 20° internal rotation. Abd: abduction, IR: internal rotation. * $p<0.05$.

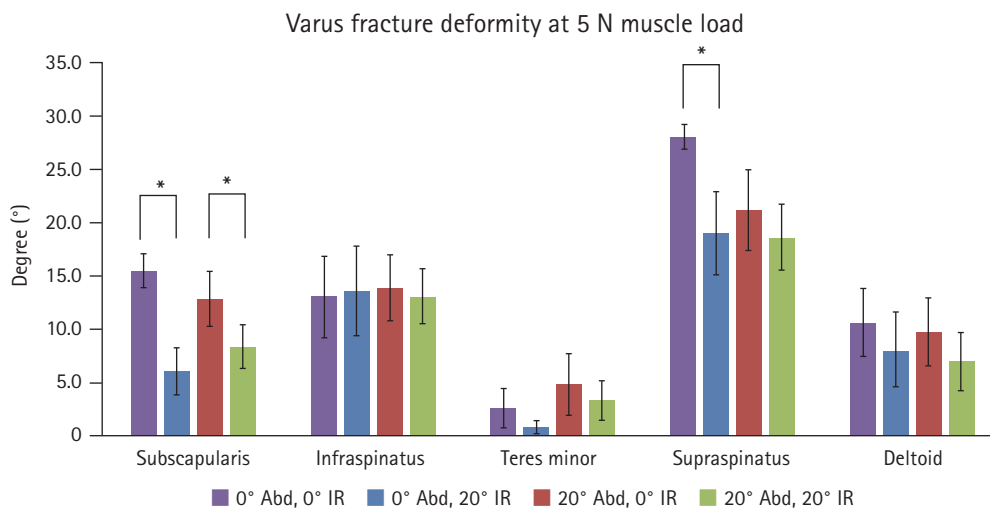


Fig. 5. Relative varus fracture deformity produced by the rotator cuff musculature and deltoid with a load of 5 N at 0° and 20° glenohumeral abduction and at neutral and 20° internal rotation. Abd: abduction, IR: internal rotation. * $p<0.05$.

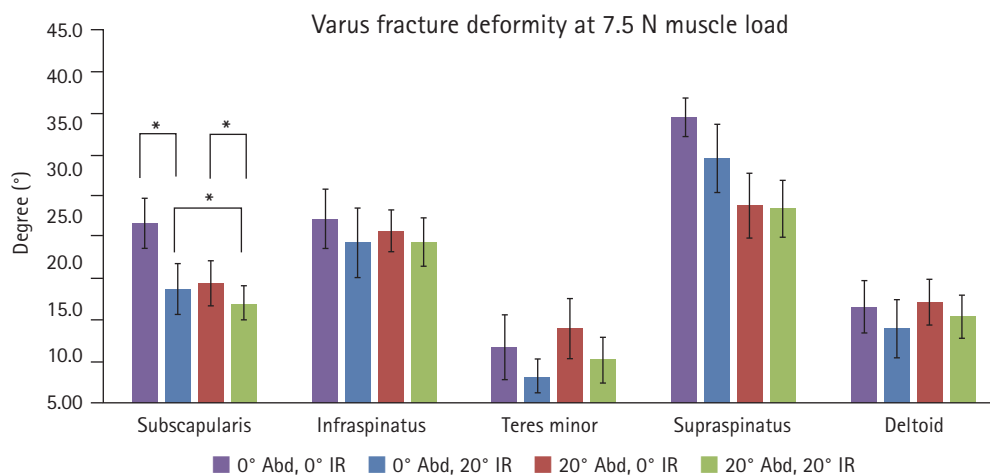


Fig. 6. Relative varus fracture deformity produced by the rotator cuff musculature and deltoid with a load of 7.5 N at 0° and 20° glenohumeral abduction and at neutral and 20° internal rotation. Abd: abduction, IR: internal rotation. *p<0.05.

natus, infraspinatus, teres minor, or deltoid at a load of 7.5 N (Figs. 4-6).

DISCUSSION

Arm position following proximal humerus fracture fixation is an uncommon consideration to decrease the rate of fixation failure. The shoulder musculature has been shown to induce humeral head deformity after fracture, specifically in the varus due to the pull of the supraspinatus and subscapularis [5]. Internal rotation was protective of varus deformity driven by the subscapularis at all loads in 20° of abduction and the supraspinatus at 2.5 N and 5 N in 0° of abduction. While we hypothesized that glenohumeral abduction would mitigate deformity caused by the superior cuff muscles, internal rotation appeared to have stronger impact on decreasing varus fracture deformity caused by both the anterior and superior cuff muscles. Ultimately, our results demonstrate that the arm positioned in abduction and internal rotation decreases tension on the supraspinatus and subscapularis, resulting in decreased varus deformity induced by these muscles.

Little attention has been given to factors within the postoperative period that might improve results of fracture repair. Some studies have researched mobilization protocols following non-operative management of proximal humerus fractures [7-9]. Fewer studies have looked at the effect of postoperative arm position following fracture fixation in the shoulder. Chen et al. [10] recently described their results using a custom neutral position shoulder and elbow sling following proximal humeral fracture fixation. They reported no increase in adverse events or loss of fixation but did report improved functional scores with their custom postoperative sling.

Biomechanical studies have commonly induced varus failure in proximal humerus models by placing a load on the cranial aspect of the humeral head [11-13]. This force can produce varus in the laboratory setting but is dissimilar to any load experienced by the humeral head *in vivo*. Many prior investigations have utilized a medial wedge, gap osteotomy, or gap to replicate comminution at the medial calcar, a factor that has been shown to predict failure [14]. Following surgery, apart from a new trauma, activation of the rotator cuff muscles and glenohumeral motion/contact contribute to early varus collapse and fixation failure. Our study set out to determine if arm position affected the deforming forces of the shoulder musculature in our two-part proximal humeral fracture model. Information could then potentially be used to guide postoperative protocols to minimize fixation failure.

The results of this biomechanical study provide information to support the position of the shoulder in internal rotation and abduction as a protective factor against varus failure following proximal humeral fracture fixation, especially for fractures at risk of fixation failure. In the clinical setting, consideration should be given to use of a resting sling that holds the shoulder in this position. Similarly, passive and active motion protocols can potentially utilize this information to mobilize the shoulder in a position that decreases the deforming pull of rotator cuff muscles.

Limitations of this study include the biomechanical investigation design that did not include concurrent proximal humeral fixation. Additionally, in some specimens, rotator cuff repairs had been previously performed, and two specimens had a full-thickness single rotator cuff muscle tear. However, these tendon repairs were re-enforced or reconstructed with an allograft tendon anchored to the anatomic footprint as defined by prior

studies [15]. In addition, the fracture model was not stabilized with plates/screws, and arm position was not tested dynamically. We have recently established this physiologically relevant biomechanical fracture model, and future work will include evaluation of proximal humerus fracture characteristics as well as fixation constructs in order to improve the care of these injuries.

In this biomechanical study of a two-part proximal humerus fracture with an incompetent medial calcar, humeral abduction resulted in significantly less varus fracture deformity caused by the subscapularis. Increasing humeral internal rotation significantly decreased varus fracture deformity caused by primarily the subscapularis and supraspinatus. While early motion protocols are important following fracture surgery, postoperative positioning of the shoulder in abduction and internal rotation can be protective against varus failure for fractures at risk for loss of fixation. This position decreases the tension generated by rotator cuff muscles that drive varus deformity.

ORCID

Christen E. Chalmers <https://orcid.org/0000-0002-5049-610X>
 David J. Wright <https://orcid.org/0000-0001-5952-2602>
 John A. Scolaro <https://orcid.org/0000-0001-7926-5017>

REFERENCES

- Rangan A, Handoll H, Brealey S, et al. Surgical vs nonsurgical treatment of adults with displaced fractures of the proximal humerus: the PROFHER randomized clinical trial. *JAMA* 2015; 313:1037-47.
- Pizzo RA, Gianakos AL, Haring RS, et al. Are arthroplasty procedures really better in the treatment of complex proximal humerus fractures?: a comprehensive meta-analysis and systematic review. *J Orthop Trauma* 2021;35:111-9.
- Biermann N, Prall WC, Böcker W, Mayr HO, Haasters F. Augmentation of plate osteosynthesis for proximal humeral fractures: a systematic review of current biomechanical and clinical studies. *Arch Orthop Trauma Surg* 2019;139:1075-99.
- Davids S, Allen D, Desarno M, Endres NK, Bartlett C, Shafritz A. Comparison of locked plating of varus displaced proximal humeral fractures with and without fibula allograft augmentation. *J Orthop Trauma* 2020;34:186-92.
- Chalmers CE, Wright DJ, Patel N, et al. Muscular forces responsible for proximal humeral deformity after fracture. *J Orthop Trauma* 2022;36:e18-23.
- Lee YS, Lee TQ. Specimen-specific method for quantifying glenohumeral joint kinematics. *Ann Biomed Eng* 2010;38:3226-36.
- Aguado HJ, Ariño B, Moreno-Mateo F, et al. Does an early mobilization and immediate home-based self-therapy exercise program displace proximal humeral fractures in conservative treatment?: observational study. *J Shoulder Elbow Surg* 2018;27: 2021-9.
- Carbone S, Razzano C, Albino P, Mezzoprete R. Immediate intensive mobilization compared with immediate conventional mobilization for the impacted osteoporotic conservatively treated proximal humeral fracture: a randomized controlled trial. *Musculoskelet Surg* 2017;101(Suppl 2):137-43.
- Lefevre-Colau MM, Babinet A, Fayad F, et al. Immediate mobilization compared with conventional immobilization for the impacted nonoperatively treated proximal humeral fracture: a randomized controlled trial. *J Bone Joint Surg Am* 2007;89: 2582-90.
- Chen X, Yu ZX, Wang HY, et al. Proximal humeral internal locking plate combined with a custom neutral-position shoulder and elbow sling for proximal humerus fractures: a randomized study. *Medicine (Baltimore)* 2019;98:e15271.
- Bai L, Fu Z, An S, Zhang P, Zhang D, Jiang B. Effect of calcar screw use in surgical neck fractures of the proximal humerus with unstable medial support: a biomechanical study. *J Orthop Trauma* 2014;28:452-7.
- Rusimov L, Zderic I, Ciric D, et al. Does supplemental intramedullary grafting increase stability of plated proximal humerus fractures. *J Orthop Trauma* 2019;33:196-202.
- Hast MW, Chin M, Schmidt EC, Sanville J, Van Osten GK, Mehta S. Mechanical effects of bone substitute and far-cortical locking techniques in 2-part proximal humerus fracture reconstruction: a cadaveric study. *J Orthop Trauma* 2020;34:199-205.
- Osterhoff G, Hoch A, Wanner GA, Simmen HP, Werner CM. Calcar comminution as prognostic factor of clinical outcome after locking plate fixation of proximal humeral fractures. *Injury* 2012;43:1651-6.
- Park MC, ElAttrache NS, Tibone JE, Ahmad CS, Jun BJ, Lee TQ. Part I: footprint contact characteristics for a transosseous-equivalent rotator cuff repair technique compared with a double-row repair technique. *J Shoulder Elbow Surg* 2007;16: 461-8.