

UCLA

UCLA Previously Published Works

Title

AT1R Activating Autoantibodies in Hematopoietic Stem Cell Transplantation

Permalink

<https://escholarship.org/uc/item/6nz9w9z8>

Journal

Transplantation and Cellular Therapy, 26(11)

ISSN

2666-6367

Authors

Bradford, Kathryn L

Pearl, Meghan

Kohn, Donald B

et al.

Publication Date

2020-11-01

DOI

10.1016/j.bbmt.2020.07.029

Copyright Information

This work is made available under the terms of a Creative Commons Attribution-NonCommercial-NoDerivatives License, available at

<https://creativecommons.org/licenses/by-nc-nd/4.0/>

Peer reviewed



HHS Public Access

Author manuscript

Biol Blood Marrow Transplant. Author manuscript; available in PMC 2021 November 01.

Published in final edited form as:

Biol Blood Marrow Transplant. 2020 November ; 26(11): 2061–2067. doi:10.1016/j.bbmt.2020.07.029.

AT1R Activating Autoantibodies in Hematopoietic Stem Cell Transplantation

Kathryn L. Bradford¹, Meghan Pearl², Donald B. Kohn^{1,3,4,5}, Patricia Weng², Ora Yadin², La Vette Bowles^{1,5}, Satiro N. De Oliveira^{1,4,5}, Theodore B. Moore^{1,5,*}

¹ Department of Pediatrics, Division of Pediatric Hematology-Oncology, University of California, Los Angeles, Los Angeles, California

² Department of Pediatrics, Division of Pediatric Nephrology, University of California, Los Angeles, Los Angeles, California

³ Department of Molecular & Medical Pharmacology, University of California, Los Angeles, Los Angeles, California

⁴ The Eli & Edythe Broad Stem Cell Research Center, University of California, Los Angeles, Los Angeles, California

⁵ Pediatric Blood and Marrow Transplant Program, University of California, Los Angeles, Los Angeles, California

Abstract

Angiotensin II type 1 receptor activating autoantibodies (AT1R-AA) have gained attention in solid organ transplant as non-human leukocyte antigen antibodies associated with rejection, vasculopathy, and graft dysfunction. These antibodies have also been reported in the context of pre-eclampsia, scleroderma, and isolated hypertension. Here, we present three post-hematopoietic stem cell transplant (HSCT) cases with patients demonstrating elevated levels of AT1R-AA detected within the first year post-HSCT. All patients had hypertension, and two patients exhibited profound diarrhea and hypokalemia. The hypertension, in all cases, was refractory to multiple classes of antihypertensives. Upon autoantibody identification, an angiotensin receptor blocker, losartan, was promptly initiated, and all patients showed blood pressure improvement. The two patients with electrolyte disturbances had rapid normalization of these levels and resolution of the diarrhea. These cases demonstrate a previously unreported association of elevated AT1R-AA levels in post-HSCT patients with a rapid response to angiotensin receptor blockade initiation.

Keywords

AT1R activating autoantibodies; hematopoietic stem cell transplantation; autoimmunity; immune dysregulation; hypertension; intestinal graft versus host disease

*Correspondence and reprint requests: Theodore B. Moore, MD, UCLA Marion, Davies Children's Center, 10833 Le Conte Avenue, A2-410 MDCC, Los, Angeles, CA 90095-1752. tbmoore@mednet.ucla.edu (T.B. Moore).

Introduction

Autoimmune conditions have been well-described drivers of various diseases and are known to cause significant complications following hematopoietic stem cell transplant (HSCT) with thyroid disease and autoimmune cytopenias being the most common pathologies.^{1,2} Some instances involve adoptive transfer of autoimmunity from the donor to the recipient, as in the case of vitiligo, psoriasis, and Crohn Disease,² while *de novo* conditions, such as autoimmune hepatitis and various autoimmune cytopenias are also described. Furthermore, autoantibody formation has been well-recognized in the post-HSCT population.^{1,3} While autoantibodies often result in impaired function of the involved tissue, several examples of disease due to agonistic autoantibodies have been described including Graves disease driving hyperthyroidism, β_1 -adrenergic receptor agonism driving dilated cardiomyopathy, and α_1 -adrenergic receptor agonism driving refractory hypertension (HTN).⁴

The angiotensin II type 1 receptor is a G-protein coupled receptor that mediates the effects of angiotensin II and drives pro-inflammatory, vasoconstrictive, and growth pathways with downstream generation of reactive oxygen species through nicotinamide adenine dinucleotide phosphate (NADPH) oxidase activity.⁵⁻⁷ Renin-angiotensin system (RAS) activity, while best described in the context of blood pressure and electrolyte homeostasis, has also been shown to cause perturbations in the gastrointestinal (GI) tract, cardiac system, adipose tissue, brain, and a variety of other tissues and organs.⁸ Angiotensin II type 1 receptor activating autoantibodies (AT1R-AA) have been implicated in the development of HTN and vascular pathology in multiple disease states including primary hypertension,^{4,9} pre-eclampsia,^{10,11} primary hyperaldosteronism,^{12,13} and scleroderma.¹⁴⁻¹⁶ These autoantibodies have also been well described in the solid organ transplant population, and have been associated with increased risk of rejection, HTN, allograft loss, and vascular inflammation.¹⁷⁻²⁶

Though the associations between AT1R-AA and various outcomes have been reported in solid organ transplantation, there is very limited data on the impact of AT1R-AA on post-hematopoietic stem cell (HSCT) patients. The post-HSCT physiology involves dramatic changes in the hematopoietic system as new cell lines from the incoming graft engraft at various rates. The process of engraftment, immunosuppression medication exposure, and depletion of T-regulatory cells by lymphodepleting chemotherapy regimens fosters an environment in which autoimmunity can develop relatively unchecked. Here, we describe three pediatric post-HSCT cases in which clinically significant elevated titers of an AT1R-AA were found and responsive to treatment with angiotensin receptor blockade (ARB). Further, we discuss the broader implications of these cases for post-HSCT patients.

Patients and Methods

All patients or their guardians consented to clinical data compilation and reporting under an IRB-approved protocol for all HSCT recipients at UCLA. Data collection occurred after informed consent was obtained from the subjects.

AT1R-AA quantitation was determined by enzyme-linked immunosorbent based assay (ELISA) (One Lambda, Canoga Park, CA). Sera were diluted 1:100, tested in duplicate by the UCLA Immunogenetics Center, and AT1R-AA concentrations were determined by a standard curve. The laboratory cutoff is 10 units/ml at 1:100 dilution.

Cases

Case 1

A 3.5-year-old male with X-linked Chronic Granulomatous Disease (CGD), diagnosed at 9 months of age by absent neutrophil oxidase activity by dihydrorhodamine testing and confirmed pathogenic mutation within the *CYBB* gene, was admitted for lentiviral gene therapy (GT) with an autologous transplant (Table 1). By the time of GT, he had developed multiple infections and severe inflammatory urethritis, for which he was treated with multiple pulses of corticosteroid therapy with limited response. He had a history of intermittent elevations in stool calprotectin, for which he was managed with mesalamine with the pathology being most suggestive of Crohn disease. He was not on immune suppressive medications or mesalamine at the time of his hospital admission. In the six months leading up to the GT, his blood pressures were mostly normal for age, with episodes of asymptomatic Stage I diastolic HTN during intermittent steroid use. He had no history of cardiac or renal comorbidities and no history of urinary tract infections.

On days -4 through -2, he underwent cytoablative conditioning with six doses of IV busulfan and had a total area-under-the-curve of 73.1 mg/L × hour. On day 0, he received his lentiviral vector gene-modified filgrastim/plerixafor-mobilized peripheral blood stem cells (PBSC) CD34+ cells. The post-transplant course was complicated by neutropenia, thrombocytopenia, and mucositis. On day +23, which corresponded with early neutrophil engraftment with an absolute neutrophil count >500/mm³ sustained for 3 days, he developed sustained Stage II HTN (Figure 1). Prior to this time, his systolic blood pressures (BPs) were in the normotensive range and diastolic BPs ranged from normotensive to Stage I HTN range. In addition, the period of neutrophil engraftment coincided with a period of platelet refractoriness, for which he received IVIG, rituximab, and romiplostim.

Over the ensuing days, he was treated with various antihypertensive agents, including calcium channel blockers (CCBs), an angiotensin converting enzyme inhibitor (ACE-I), an α_2 -agonist patch, and a number of rescue medications. Corticosteroid therapy for the inflammatory urethritis was discontinued on day +26. Renal artery stenosis was ruled out by imaging studies, and thyroid function tests, renal function tests, urine output, and urinalysis were normal, and there was no evidence of infection. Echocardiogram showed a left ventricular wall thickness at the upper limit of normal.

On day +37, AT1R-AA level measured by ELISA was >40 units/ml at a 1:100 dilution. Losartan therapy was started, the ACE-I was discontinued, and the CCB and α_2 -agonist patch were continued. The BP normalized within the following days, and he was able to be weaned off the CCB and α_2 -agonist patch after discharge from the hospital. He remained normotensive on losartan continued through four months post-GT. Of note, AT1R-AA titer remained >40 units/ml at a 1:100 dilution throughout this time. Of note, a pre-GT blood

sample was retrospectively tested for the presence of AT1R-AA, and remarkably, this sample also demonstrated a AT1R-AA titer at >40 units/ml at a 1:100 dilution. During that period, the patient had only normotensive systolic BPs, though his diastolic BPs ranged from normotensive to stage I HTN.

Case 2

A 20-year-old female with a history of severe aplastic anemia, a persistent Paroxysmal Nocturnal Hemoglobinuria clone, and diffuse large B cell lymphoma underwent a 10/10 matched unrelated donor hematopoietic stem cell transplantation (HSCT) following conditioning with 1,200 cGy total body irradiation and 2 doses of 60 mg/kg cyclophosphamide (Table 1). Post-transplant graft versus host disease (GVHD) prophylaxis involved steroids, tacrolimus, and scheduled methotrexate. She also received replacement doses of IVIG every other week.

The post-HSCT course was complicated by severe intestinal GVHD starting day +81, and immune-suppression therapies, including oral, intravenous, and topical steroids, tacrolimus, sirolimus, basiliximab, and ruxolitinib, were administered (Figure 2). During this period, she developed new Stage I-II HTN, and was placed on antihypertensive therapy with a CCB and an ACE-I with an inadequate response. The patient was admitted several more times for episodes of pancytopenia, high output and bloody stools, community acquired pneumonia and pulmonary edema. During all these admissions, despite increasing doses and adding several more antihypertensive medications, she remained hypertensive and hypokalemic. The trans-tubular potassium gradient was 3, which was consistent with some degree of urinary potassium losses and in addition to her GI losses. In addition, she did not achieve normal platelet levels until post-HSCT day +81; however, she became chronically thrombocytopenic starting day +100 (platelets ~50–100), and became transfusion dependent starting day +249, which was 2 weeks after her hypokalemia became a chronic issue.

To further investigate the refractory HTN, on day +292, the AT1R-AA level was measured by ELISA and was found to be elevated at 16 units/ml at a 1:100 dilution. The ACE-I was discontinued, and losartan treatment was started. Within days of the switch to the losartan, the diarrhea resolved, in the setting of prolonged diarrhea on high dose budesonide, and her serum potassium completely normalized; however, her BP remained in the Stage I HTN range, despite adjustments in the losartan dosing. A week later, her creatinine had increased to 1.32 mg/dL from 1.0 mg/dL. Her tacrolimus was transitioned to sirolimus, but her acute kidney injury worsened, with a peak creatinine of 3.2 mg/dL. She developed pulmonary hemorrhage, and she was diagnosed with transplant associated thrombotic microangiopathy (TA-TMA) which responded well to eculizumab with improvement of her creatinine. During the admission, the losartan was held and a β -blocker was initiated with a slight improvement in the BP to the pre-HTN range. However, following hospital discharge, despite up-titration of her β -blocker dose, her BP increased to Stage II HTN with a concurrent increase in the AT1R-AA level to 23 units/ml at a 1:100 dilution. The losartan was restarted with a rapid improvement in the BPs into the normal to pre-hypertensive range, and her creatinine remained stable. She continues at this time without diarrhea, and, apart from a few mildly

low potassium levels, her electrolytes have remained in the normal range without supplementation.

Case 3

A 6-year-old male was diagnosed with standard risk B-cell acute lymphoblastic leukemia (B-ALL) that was complicated by high risk cytogenetics, post-induction minimal residual disease, and PEG-asparaginase pancreatitis (Table 1). In the setting of the pancreatitis, he developed new onset Stage I-II HTN, which was well-controlled on an ACE-I. A work-up for the possible etiologies of the HTN included imaging which demonstrated wedge-shaped hypoperfused areas in the left kidney, compatible with renal infarcts. After achieving first complete remission following consolidation, he underwent a 10/10 matched unrelated HSCT with PBSC following conditioning with 1,200 cGy total body irradiation, 4 doses of 500 mg/m² cytarabine, and 2 doses of 60 mg/kg cyclophosphamide. GVHD prophylaxis included post-transplant methotrexate, tacrolimus, and IV methylprednisolone.

The post-HSCT course was complicated by severe mucositis, requiring total parenteral nutrition and patient controlled analgesia use as well as intermittent blood product transfusions. Neutrophil engraftment, defined as absolute neutrophil count >500/mm³ for three days was achieved by day +17. He was discharged from the hospital on day +22 on oral tacrolimus, prednisone, and standard prophylactic medications. At this time, he had grade I skin GVHD characterized by a mild erythematous rash on his upper extremities, which was not associated with elevations in elafin and was managed with emollient therapy.

He was readmitted on day +39 with abdominal pain and large volume diarrhea and persistence of his skin findings. GVHD studies were notable for newly elevated regenerating islet-derived 3-alpha levels, which were within normal limits at the time of hospital discharge. He was also found to have adenovirus in the stool without adenoviremia. He was treated with high dose IV methylprednisolone and transitioned to an entirely parenteral diet. Upper endoscopy and colonoscopy were performed, and biopsies demonstrated colonic grade 1 GVHD with no small intestine pathology and no evidence of intestinal adenovirus infection. Skin findings had resolved. He was transitioned to oral steroids and discharged again on day +59. During this admission, he frequently had BPs in the Stage I HTN range, which at the time, were attributed to the high dose steroids (Figure 3). This HTN occurred in the setting of previously well-controlled HTN on a stable ACE-I dose.

Following the hospital discharge (days +59 to +69), he developed severe hypokalemia with incomplete response to increasing doses of oral supplementation. In addition, he demonstrated concomitant increased levels of serum sodium. He continued to have fluctuations of his BP, with most readings in the Stage I HTN range. He again developed large volume diarrhea which resolved with transition to total parenteral nutrition and resumption of IV methylprednisolone. A work up revealed an appropriate kidney response to the hypokalemia with a trans-tubular potassium gradient of 1.3, suggesting that the major etiology underlying the hypokalemia was the increased losses in the stool. Having previously observed the combination of HTN, severe diarrhea, and hypokalemia in the setting of AT1R-AA in Case 2, the medical team sent AT1R-AA testing on this patient, and on day +72, the level was measured at >40 units/ml at a 1:100 dilution by ELISA. Losartan

therapy was initiated, with weaning of his ACE-I, with rapid improvement in his BPs and hypokalemia, and he had resolution of the diarrhea over the ensuing days and tolerated gradual advancements to his diet. The ACE-I was discontinued. Due to a brief recurrence of the diarrhea with re-introduction of solids, he underwent repeat endoscopy and sigmoidoscopy on day +86, which revealed a full resolution of the previously noted GVHD findings. He remained normotensive and had no diarrhea or hypokalemia for the following month. For undetermined reasons, after day +100, he developed recurrence of his HTN, which improved over the following months without intervention or adjustment to his losartan dose, and the etiology for the HTN recurrence was never determined. The primary speculations for this finding were (1) inadequate losartan dosing as the patient began to have improved intestinal function and weight gain and (2) a transition to outpatient BP monitoring following day +100 without home BP assessments.

Discussion

Taken collectively, these cases highlight the propensity of patients that have undergone stem cell transplantation, including gene therapy, to develop clinically significant complications due to the presence of AT1R-AA. We propose that new or worsened HTN with incomplete response to standard antihypertensive therapy with CCB or ACE-I should prompt further evaluation for AT1R-AA. We also present the novel observation of ARB-responsive diarrhea and diarrhea-associated electrolyte disturbances that were incompletely responsive to steroid therapy. The clinical overlap of the intestinal manifestations of TA-TMA and intestinal-GVHD make the etiology of the losartan-responsive diarrhea unclear, and additional investigation will be needed to determine whether one or both of these post-HSCT complications will respond well to ARB therapy in the setting of elevated AT1R-AA. Early identification of this autoantibody allows for prompt ARB initiation and may mitigate the endothelial damage that can develop in the case of longstanding, untreated AT1R constitutive activation. Clinical sequelae of AT1R-AA have not previously been reported in the pediatric post-HSCT population, and further work is needed to determine the incidence, timing, and implications of this complication in the pediatric and adult post-HSCT populations.

While transplant physicians have been trained to be vigilant for autoimmune manifestations in the post-HSCT period, development of AT1R-AA has not been a typical consideration within this population. We present a constellation of symptoms in the post-HSCT population for practitioners to consider the risk of AT1R-AA-related pathology in post-HSCT patients to enable effective screening and targeted therapy as indicated: HTN that is incompletely responsive to non-ARB antihypertensives and severe diarrhea with intestinal-driven marked hypokalemia. Further work will be needed to refine patient-specific risk factors, such as age, gender, and type of HSCT, that may further modify the risk of this complication. Regarding the timing of complications due to AT1R-AA, all of the cases we described had clinically significant AT1R-AA-related symptoms that began after neutrophil engraftment and occurred within the first year following transplantation, though the timing of antibody formation is unknown at this time.

The primary symptom that unified all three presented cases was marked HTN that was relatively refractory to conventional non-ARB therapies. There are various reasons for children and adults to develop HTN following HSCT. Most patients will require some duration of steroid therapy, either for GVHD prophylaxis or for GVHD therapy, which can result in long-term, high-dose immune suppression. In addition, these patients often receive multiple forms of other HTN-inducing medications, which can include tacrolimus, sirolimus, and cyclosporin A. These medications can also be associated with other renal complications leading to HTN, such as TA-TMA as demonstrated in Case 2. Of note, all three of the patients were on significant doses of systemic steroids at the time of their HTN, and the two recipients of allogeneic HSCT were additionally were on immune suppressants known to drive HTN (Figures 2 and 3).

Case 1 highlighted AT1R-AA development in a patient with CGD. Immune dysregulation with autoimmune features has been well-described in this condition, and reported autoimmune manifestations have included increased rates above the general population of systemic lupus erythematosus, rheumatoid arthritis, immunoglobulin A nephropathy, inflammatory bowel disease, autoimmune hepatitis, and others.²⁷ This patient, with the reported history of prior inflammatory bowel disease and early post-GT presumed immune-mediated thrombocytopenia had previously demonstrated autoimmune features. His conditioning with myeloablative doses of busulfan was not immunoablative. Indeed, further review of a pre-GT sample during a time when he was normotensive with the exception of intermittent diastolic BPs in the Stage I hypertensive range revealed the same high titer AT1R-AA. Functional NADPH oxidase has been implicated in the signaling pathway of the RAS,^{5,7,28} and for this reason, we hypothesize that this patient did not demonstrate significant pre-GT HTN, despite the presence of circulating AT1R-AA pre-GT, since he did not have intact neutrophil NADPH oxidase activity prior to GT. Since his GT only resulted in modified cells derived from the transduced hematopoietic stem cells, any non-hematopoietic lineage derived cells would not have intact NADPH oxidase signaling. Notably, both colonic and renal tissue have been reported to highly express NADPH oxidase,²⁹ and this tissue expression would not be restored through GT or HSCT. Thus, we posit that AT1R-AA effects would be limited in this patient to the gene-modified neutrophil-driven pressor effects, since substantial evidence exists that neutrophils play a major role in vascular tone through generation of reactive oxygen species.^{30,31} Though this is our leading hypothesis particularly given the timing of HTN with engraftment, we cannot rule out the potential role of varying AT1R expression or other unknown antibody characteristics that could account for the differences in his hypertensive response.

Another aspect of the HTN noted for this patient was that his HTN, while still Stage II at the time of losartan administration had actually been slowly down trending over the several days preceding the initiation of losartan. There exist several possible contributors that could account for the apparently paradoxical finding: (1) downregulation of AT1R expression through downstream negative feedback caused by the newly intact NADPH oxidase signaling, (2) cessation of all steroids day +27 through day +31, and (3) response to the IVIG and rituximab treatments, which could have decreased the autoantibody titer and production, respectively. In addition, the initiation of a CCB on day +24, clonidine on day +25, and an ACE-I day +29 with dose escalation could have contributed to the slight

improvement in BP, despite not blocking the AT1R activity. Further analysis of post-HSCT patients with elevated AT1R-AA levels will be needed to clarify the compensatory response to increased AT1R signaling as well as the impact of non-ARB based anti-hypertensives.

Importantly, there has been some recognition in the literature between an increased AT1R-AA titer and chronic GVHD. Chiron et al. conducted an observational study that demonstrated elevated AT1R-AA levels in 24% of the adult post-HSCT patients with chronic GVHD (n=42) compared with 7% of those without chronic GVHD (n=45, age and sex matched controls).³² In addition, the patients with elevated AT1R-AA levels in the chronic GVHD group exhibited higher scores for organ severity. Notably, the chronic GVHD group included skin, intestinal, liver, and lung as sites of GVHD, and the study did not show a significant relationship between an elevated AT1R-AA level and the site of GVHD, and there was no significant difference in the rates of HTN in the population with GVHD with or without an elevated AT1R-AA level.³² Elevated AT1R-AA levels were associated with the presence of antinuclear antibodies.³² Yaguchi et al. evaluated the role of tissue RAS in a murine model of chronic GVHD characterized by lacrimal gland fibrosis, and they reported suppression of fibrosis through ARB therapy.^{33,34} Lastly, Saardi et al. recently reported GVHD-associated calcinosis cutis development in seven post-HSCT patients, and calcinosis cutis has been most commonly associated with systemic sclerosis, a condition that shares many phenotypic features with skin GVHD.³⁵ Further work will be needed to clarify if elevated AT1R-AA levels contribute to this pathology.

With regard to GVHD, the two allogeneic HSCT recipients (Cases 2 and 3) demonstrated large volume diarrhea accompanied by severe, supplementation-refractory hypokalemia. From a renal standpoint, activation of AT1R directly induces sodium and water retention through the epithelial sodium channel within the distal convoluted tubule, connecting tubule, and collecting duct.³⁶ Importantly, these patients demonstrated primarily intact renal response to hypokalemia, suggesting that GI losses drove the hypokalemia. While prior work substantiates a role of RAS signaling in the GI tract, there are no prior reports of diarrhea-associated with an AT1R-AA, which is an immunoglobulin (Ig) G type antibody. Traditionally, gastrointestinal immunity has been associated with IgA activity, though IgG has been identified within the GI tract.³⁷ Animal studies of GI tract RAS signaling have demonstrated rat jejunal AT1R stimulation inhibiting water absorption,³⁸ and a murine colitis models have suggested excessive AT1R activity as a driver of disease, with AT1R-deficient mice demonstrating significantly decreased colonic inflammation relative to that of mice with intact AT1R expression.³⁹

Prior work has demonstrated a major role for intestinal neutrophil infiltration in the pathogenesis of acute GVHD, with neutrophil depletion reducing GVHD severity.⁴⁰ Neutrophils have been shown to express AT1R,⁴¹ and as previously mentioned, AT1R signaling directly drives ROS generation and downstream inflammatory responses.⁵ In a model of intestinal ischemia-reperfusion, losartan mitigated neutrophil activity and resulted in lower levels of intestinal inflammation.⁴² In addition, murine bone marrow chimeras established myeloid lineage cells as the key drivers for a model of an IgG-mediated colitis.⁴³ It is possible that AT1R-AA activate neutrophil AT1R within blood vessels, and these activated neutrophils home to existing areas of inflammation and exacerbate the damage

initiated in GVHD. The potential interaction between neutrophils, AT1R-AA, and intestinal inflammation may explain the presence of diarrhea in the latter 2 cases, while our first patient, who lacked functional intestinal NADPH oxidase, did not have this presentation. Alternatively, AT1R-AA interactions with AT1R on other immune cells, such as macrophages and T lymphocytes,⁴⁴ may play a role in intestinal-GVHD. Further work will be needed to determine a deeper understanding of an interaction between AT1R-AA and intestinal pathology in the post-HSCT patient population.

In addition, the clinical features of TA-TMA share significant overlap with those of intestinal GVHD as well as those of AT1R activation. TA-TMA, a classic endotheliopathy, is a multiorgan pathology characterized by microangiopathic hemolytic anemia, elevated serum lactate dehydrogenase, and thrombocytopenia. This condition has become increasingly recognized in both adult and pediatric post-HSCT cases, and while much of the pathology has been described in the kidney, there has been recent attention to intestinal TA-TMA.^{45,46} Notably, prior work has also implicated disordered RAS signaling in the pathogenesis of TA-TMA, and clinical response to ARB use for this indication has been reported.⁴⁷ Cases 2 and 3 both demonstrated high levels of regenerating islet-derived 3-alpha, which has been recognized as a highly specific biomarker of intestinal GVHD,⁴⁸ and their high volume diarrhea met the clinical criteria for intestinal GVHD. In addition, they both had histopathologic biopsies of colonic tissue during the course of their work up for high volume diarrhea demonstrative of acute GVHD changes. Case 2 developed a superimposed TA-TMA, though the timing of this development was unclear given the protracted history of diarrhea and transfusion-dependent thrombocytopenia. Her acute course was predominantly characterized by her renal and pulmonary manifestations, though preceding intestinal manifestations may have also been partly attributable to her evolving TA-TMA. In addition, with the re-initiation of her losartan, she initially had a worsening of her hypokalemia, though this self-corrected, and urine studies were not available from this time to discern renal versus intestinal-driven losses. Further investigation into the frequency of elevated AT1R-AA levels in the post-HSCT population, the rates of intestinal GVHD and/or TA-TMA in these patients, and the correlation of symptoms with antibody titer are all needed to better disentangle the potential role of AT1R-AA in exacerbating or driving pathology due to these post-HSCT complications.

Increased screening of post-HSCT patients with HTN for AT1R-AA will better clarify the frequency of this complication and can permit targeted therapy through initiation of an ARB. Further work may also better clarify the role of AT1R-AA in acute and chronic intestinal-GVHD in addition to an association with other organs involved in GVHD as well as TA-TMA. Screening of the AT1R-AA levels in the post-HSCT population may elucidate the fraction of patients with elevated AT1R-AA levels that have clinical manifestations, provide a better understanding of the timing of the development of these autoantibodies, and identify the time course from elevated AT1R-AA level development until clinical manifestations. Furthermore, the frequency and clinical significance of incidentally detected AT1R-AA in the pre-HSCT population in the early engraftment period post-HSCT could be determined through pre-HSCT screening. It is notable that the presented cases had distinct indications for stem cell transplant, received varied conditioning regimens, had different graft sources, and received vastly different post-transplant immune suppression. Our experience has

demonstrated good BP responses to losartan, although other ARBs could have therapeutic benefit. Also, β -blockers, in addition to blocking the β -adrenergic receptors, have been reported to blunt AT1R signaling through receptor–G protein uncoupling, and as shown in Case 2, there may be a role for this therapy in a setting in which the use of an ARB is contraindicated.⁴⁹ Our two patients with intestinal GVHD also showed rapid improvement of their stool output with losartan initiation and were able to tolerate weaning of their immunosuppression without relapse. Taken together, we suggest that testing for AT1R-AA may have clinical utility for some HSCT patients, and the presence of AT1R-AA may be a valid consideration in therapeutic decision-making in this population.

Acknowledgements

This work was supported by a T32 training grant in Developmental Hematology through the National Institutes of Health (K.L.B.).

Abbreviations

ARB	angiotensin receptor blocker
AT1R-AA	angiotensin II type 1 receptor activating autoantibodies
ACE2	angiotensin converting enzyme 2
ACE-I	angiotensin converting enzyme inhibitor
BP	blood pressure
CCB	calcium channel blocker
CGD	chronic granulomatous disease
ELISA	enzyme-linked immunosorbent based assay
GI	gastrointestinal
GT	gene therapy
GVHD	graft versus host disease
HSCT	hematopoietic stem cell transplant
HTN	hypertension
Ig	immunoglobulin
IVIg	intravenous immunoglobulin
NADPH	nicotinamide adenine dinucleotide phosphate
PBSC	peripheral blood stem cells
RAS	renin-angiotensin system
TA-TMA	transplant associated-thrombotic microangiopathy

References

1. Khalil A, Zaidman I, Bergman R, Elhasid R, Ben-Arush MW. Autoimmune complications after hematopoietic stem cell transplantation in children with nonmalignant disorders. *TheScientificWorldJournal*. 2014;2014:581657–581657.
2. Daikeler T, Tyndall A. Autoimmunity following haematopoietic stem-cell transplantation. *Best Practice & Research Clinical Haematology*. 2007;20(2):349–360. [PubMed: 17448966]
3. Wechalekar A, Cranfield T, Sinclair D, Ganzckowski M. Occurrence of autoantibodies in chronic graft vs. host disease after allogeneic stem cell transplantation. *Clinical and Laboratory Haematology*. 2005;27(4):247–249. [PubMed: 16048492]
4. Xia Y, Kellems RE. Angiotensin Receptor Agonistic Autoantibodies and Hypertension. *Circulation Research*. 2013;113(1):78–87. [PubMed: 23788505]
5. Garrido AM, Griendling KK. NADPH oxidases and angiotensin II receptor signaling. *Molecular and cellular endocrinology*. 2009;302(2):148–158. [PubMed: 19059306]
6. Lymperopoulos A, Aukszi B. Angiotensin receptor blocker drugs and inhibition of adrenal beta-arrestin-1-dependent aldosterone production: Implications for heart failure therapy. *World journal of cardiology*. 2017;9(3):200–206. [PubMed: 28400916]
7. Nguyen Dinh Cat A, Montezano AC, Burger D, Touyz RM. Angiotensin II, NADPH oxidase, and redox signaling in the vasculature. *Antioxidants & redox signaling*. 2013;19(10):1110–1120. [PubMed: 22530599]
8. Nehme A, Zouein FA, Zayeri ZD, Zibara K. An Update on the Tissue Renin Angiotensin System and Its Role in Physiology and Pathology. *Journal of cardiovascular development and disease*. 2019;6(2):14.
9. Bian J, Lei J, Yin X, et al. Limited AT1 Receptor Internalization Is a Novel Mechanism Underlying Sustained Vasoconstriction Induced by AT1 Receptor Autoantibody From Preeclampsia. *Journal of the American Heart Association*. 2019;8(6).
10. Xia Y, Kellems RE. Receptor-activating autoantibodies and disease: preeclampsia and beyond. *Expert Review of Clinical Immunology*. 2011;7(5):659–674. [PubMed: 21895478]
11. Yang X, Wang F, Lau WB, et al. Autoantibodies Isolated from Preeclamptic Patients Induce Endothelial Dysfunction via Interaction with the Angiotensin II AT1 Receptor. *Cardiovascular Toxicology*. 2013;14(1):21–29.
12. Er LK, Chen L, Tsai Y-C, et al. Risk of new-onset autoimmune diseases in primary aldosteronism. *Journal of Hypertension*. 2019;1. [PubMed: 30499914]
13. Li H, Yu X, Cicala MV, et al. Prevalence of angiotensin II type 1 receptor (AT1R)-activating autoantibodies in primary aldosteronism. *Journal of the American Society of Hypertension*. 2015;9(1):15–20. [PubMed: 25537460]
14. Becker MO, Kill A, Kutsche M, et al. Vascular Receptor Autoantibodies in Pulmonary Arterial Hypertension Associated with Systemic Sclerosis. *American Journal of Respiratory and Critical Care Medicine*. 2014;190(7):808–817. [PubMed: 25181620]
15. Kill A, Tabeling C, Undeutsch R, et al. Autoantibodies to angiotensin and endothelin receptors in systemic sclerosis induce cellular and systemic events associated with disease pathogenesis. *Arthritis Research & Therapy*. 2014;16(1):R29. [PubMed: 24472528]
16. Senécal J-L, Hoa S, Yang R, Koenig M. Pathogenic roles of autoantibodies in systemic sclerosis: Current understandings in pathogenesis. *Journal of Scleroderma and Related Disorders*. 2019;239719831987066.
17. Lefaucheur C, Viglietti D, Bouatou Y, et al. Non-HLA agonistic anti-angiotensin II type 1 receptor antibodies induce a distinctive phenotype of antibody-mediated rejection in kidney transplant recipients. *Kidney International*. 2019;96(1):189–201. [PubMed: 31005275]
18. Xu Q, McAlister VC, Leckie S, House AA, Skaro A, Marotta P. Angiotensin II type I receptor agonistic autoantibodies are associated with poor allograft survival in liver retransplantation. *American Journal of Transplantation*. 2019;20(1):282–288. [PubMed: 31419065]
19. Hiemann NE, Meyer R, Wellnhofer E, et al. Non-HLA Antibodies Targeting Vascular Receptors Enhance Alloimmune Response and Microvasculopathy After Heart Transplantation. *Transplantation Journal*. 2012;94(9):919–924.

20. Reinsmoen NL, Mirocha J, Ensor CR, et al. A 3-Center Study Reveals New Insights Into the Impact of Non-HLA Antibodies on Lung Transplantation Outcome. *Transplantation*. 2017;101(6):1215–1221. [PubMed: 27973391]
21. Dragun D, Muller DN, Brasen JH, et al. Angiotensin II type 1-receptor activating antibodies in renal-allograft rejection. *The New England journal of medicine*. 2005;352(6):558–569. [PubMed: 15703421]
22. Taniguchi M, Rebellato LM, Cai J, et al. Higher risk of kidney graft failure in the presence of anti-angiotensin II type-1 receptor antibodies. *Am J Transplant*. 2013;13(10):2577–2589. [PubMed: 23941128]
23. Pearl MH, Zhang Q, Palma Diaz MF, et al. Angiotensin II Type 1 receptor antibodies are associated with inflammatory cytokines and poor clinical outcomes in pediatric kidney transplantation. *Kidney international*. 2018;93(1):260–269. [PubMed: 28927645]
24. Pearl MH, Grotts J, Rossetti M, et al. Cytokine Profiles Associated With Angiotensin II Type 1 Receptor Antibodies. *Kidney Int Rep*. 2019;4(4):541–550. [PubMed: 30997435]
25. Gerlach UA, Lachmann N, Ranucci G, et al. Non-HLA Antibodies May Accelerate Immune Responses After Intestinal and Multivisceral Transplantation. *Transplantation*. 2017;101(1):141–149. [PubMed: 27495766]
26. Fichtner A, Süsal C, Schröder C, et al. Association of angiotensin II type 1 receptor antibodies with graft histology, function and survival in paediatric renal transplant recipients. *Nephrol Dial Transplant*. 2018.
27. Henrickson SE, Jongco AM, Thomsen KF, Garabedian EK, Thomsen IP. Noninfectious Manifestations and Complications of Chronic Granulomatous Disease. *Journal of the Pediatric Infectious Diseases Society*. 2018;7(suppl_1):S18–S24. [PubMed: 29746679]
28. Montezano AC, Touyz RM. Reactive Oxygen Species, Vascular Nox, and Hypertension: Focus on Translational and Clinical Research. *Antioxidants & Redox Signaling*. 2014;20(1):164–182. [PubMed: 23600794]
29. Kikuchi H, Hikage M, Miyashita H, Fukumoto M. NADPH oxidase subunit, gp91phox homologue, preferentially expressed in human colon epithelial cells. *Gene*. 2000;254(1–2):237–243. [PubMed: 10974555]
30. Morton J, Coles B, Wright K, et al. Circulating neutrophils maintain physiological blood pressure by suppressing bacteria and IFN γ -dependent iNOS expression in the vasculature of healthy mice. *Blood*. 2008;111(10):5187–5194. [PubMed: 18281503]
31. Wu Y, Li Y, Zhang C, et al. S100a8/a9 Released by CD11b+Gr1+ Neutrophils Activates Cardiac Fibroblasts to Initiate Angiotensin II-Induced Cardiac Inflammation and Injury. *Hypertension*. 2014;63(6):1241–1250. [PubMed: 24711518]
32. Chiron A, Bouaziz J-D, Carmagnat M, et al. Anti-Angiotensin Type 1 Receptor Antibodies in Chronic Graft-Versus-Host Disease. *Transplantation*. 2014;98(4):470–474. [PubMed: 24873781]
33. Yaguchi S, Ogawa Y, Shimmura S, et al. Angiotensin II Type 1 Receptor Antagonist Attenuates Lacrimal Gland, Lung, and Liver Fibrosis in a Murine Model of Chronic Graft-Versus-Host Disease. *PLoS ONE*. 2013;8(6):e64724. [PubMed: 23762250]
34. Yaguchi S, Ogawa Y, Kawakita T, Shimmura S, Tsubota K. Tissue Renin-Angiotensin System in Lacrimal Gland Fibrosis in a Murine Model of Chronic Graft-Versus-Host Disease. *Cornea*. 2015;34:S142–S152. [PubMed: 26448172]
35. Saardi KM, Rosenstein RK, Anadkat MJ, et al. Calcinosis Cutis in the Setting of Chronic Skin Graft-Versus-Host Disease. *JAMA Dermatology*. 2020.
36. Rossier BC. Epithelial sodium channel (ENaC) and the control of blood pressure. *Current Opinion in Pharmacology*. 2014;15:33–46. [PubMed: 24721652]
37. Castro-Dopico T, Clatworthy MR. IgG and Fc γ Receptors in Intestinal Immunity and Inflammation. *Frontiers in Immunology*. 2019;10. [PubMed: 30723470]
38. Jin X-H, Wang Z-Q, Siragy HM, Guerrant RL, Carey RM. Regulation of jejunal sodium and water absorption by angiotensin subtype receptors. *American Journal of Physiology-Regulatory, Integrative and Comparative Physiology*. 1998;275(2):R515–R523.

39. Garg M, Angus PW, Burrell LM, Herath C, Gibson PR, Lubel JS. Review article: the pathophysiological roles of the renin–angiotensin system in the gastrointestinal tract. *Alimentary Pharmacology & Therapeutics*. 2012;35(4):414–428. [PubMed: 22221317]
40. Hülsdünker J, Ottmüller KJ, Neeff HP, et al. Neutrophils provide cellular communication between ileum and mesenteric lymph nodes at graft-versus-host disease onset. *Blood*. 2018;131(16):1858–1869. [PubMed: 29463561]
41. Rasini E, Cosentino M, Marino F, et al. Angiotensin II type 1 receptor expression on human leukocyte subsets: A flow cytometric and RT-PCR study. *Regulatory Peptides*. 2006;134(2–3):69–74. [PubMed: 16530863]
42. Chen J, Yang S, Hu S, Choudhry MA, Bland KI, Chaudry IH. Estrogen prevents intestinal inflammation after trauma-hemorrhage via downregulation of angiotensin II and angiotensin II subtype I receptor. *American Journal of Physiology-Gastrointestinal and Liver Physiology*. 2008;295(5):G1131–G1137. [PubMed: 18832446]
43. Kobayashi K, Qiao SW, Yoshida M, Baker K, Lencer WI, Blumberg RS. An FcRn-Dependent Role for Anti-flagellin Immunoglobulin G in Pathogenesis of Colitis in Mice. *Gastroenterology*. 2009;137(5):1746–1756.e1741. [PubMed: 19664634]
44. Crowley SD, Rudemiller NP. Immunologic Effects of the Renin-Angiotensin System. *Journal of the American Society of Nephrology*. 2017;28(5):1350–1361. [PubMed: 28151411]
45. Yamada R, Nemoto T, Ohashi K, et al. Distribution of Transplantation-Associated Thrombotic Microangiopathy (TA-TMA) and Comparison between Renal TA-TMA and Intestinal TA-TMA: Autopsy Study. *Biology of Blood and Marrow Transplantation*. 2020;26(1):178–188. [PubMed: 31491486]
46. El-Bietar J, Warren M, Dandoy C, et al. Histologic Features of Intestinal Thrombotic Microangiopathy in Pediatric and Young Adult Patients after Hematopoietic Stem Cell Transplantation. *Biology of Blood and Marrow Transplantation*. 2015;21(11):1994–2001. [PubMed: 26150023]
47. Jodele S, Laskin BL, Dandoy CE, et al. A new paradigm: Diagnosis and management of HSCT-associated thrombotic microangiopathy as multi-system endothelial injury. *Blood reviews*. 2015;29(3):191–204. [PubMed: 25483393]
48. Ferrara JLM, Harris AC, Greenson JK, et al. Regenerating islet-derived 3-alpha is a biomarker of gastrointestinal graft-versus-host disease. *Blood*. 2011;118(25):6702–6708. [PubMed: 21979939]
49. Barki-Harrington L, Luttrell Louis M, Rockman Howard A. Dual Inhibition of β -Adrenergic and Angiotensin II Receptors by a Single Antagonist. *Circulation*. 2003;108(13):1611–1618. [PubMed: 12963634]

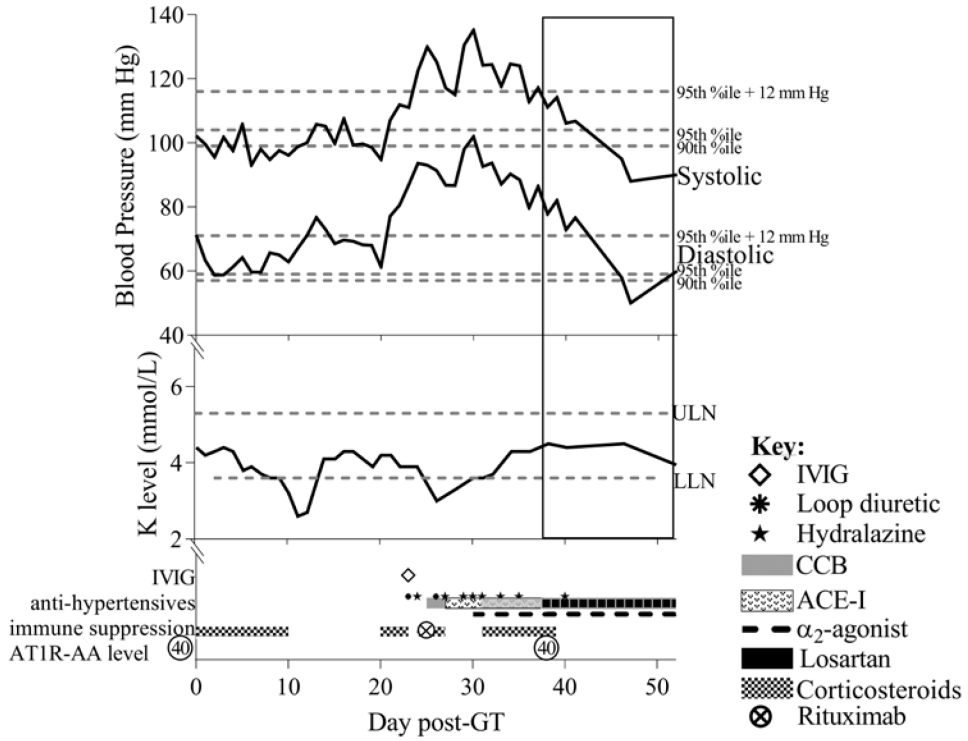
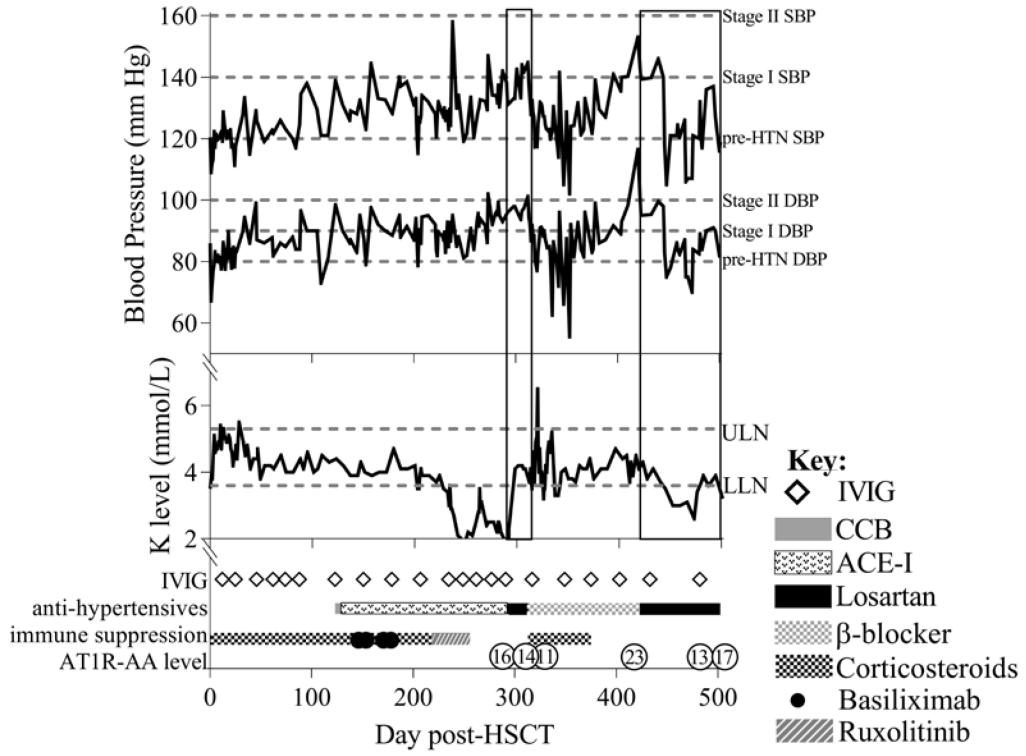


Figure 1. Case 1.

Following gene therapy (GT), serial blood pressure and potassium levels were trended, and day +23, which corresponded to neutrophil engraftment, was also associated with **(Top)** Stage II hypertension, and **(Middle)** minimal changes in potassium (K). **(Bottom)** Use of various medications over time as well as the AT1R-AA levels are displayed with losartan therapy projected onto the BP and K graphs (vertical rectangle). **Note:** Dashed lines in **(Top)** reflect the lower limits for Stage II hypertension, Stage I hypertension, and pre-hypertension (from top to bottom) as defined for age and height, and **(Middle)** reflect the upper limit of normal (ULN) and lower limit of normal (LLN) for the measured potassium.



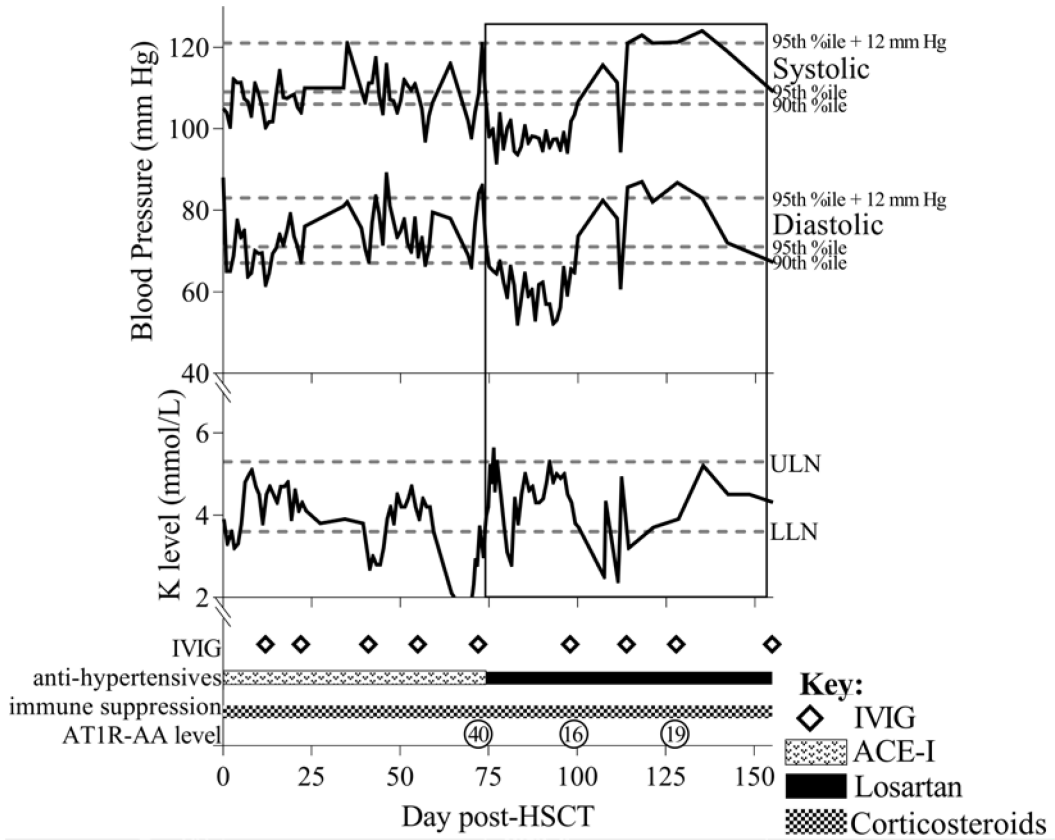


Figure 3. Case 3.

Following hematopoietic stem cell transplant (HSCT), the patient developed severe intestinal GVHD on day +39. **(Top)** Serial blood pressure was notable for frequent Stage I-II hypertension, and **(Middle)** potassium (K) levels demonstrated the development of marked hypokalemia. **(Bottom)** Use of various medications over time as well as the AT1R-AA levels are displayed with losartan therapy projected onto the BP and K graphs (vertical rectangle). **Note:** Dashed lines in **(Top)** reflect the lower limits for Stage II hypertension, Stage I hypertension, and pre-hypertension (from top to bottom) as defined for age and height, and **(Middle)** reflect the upper limit of normal (ULN) and lower limit of normal (LLN) for the measured K.

Table 1.

Characteristics of Three HSCT Cases with Severe Hypertension and AT1R-AA

Case	Age (year), Sex	Primary Indication for Stem Cell Therapy	Conditioning	Transplant Type	GVHD Prophylactic Regimen	Neutrophil Engraftment +	Post-transplant Complications (Interventions)
1	3.5,M	Chronic Granulomatous Disease	Busulfan	Autologous Lentiviral Gene Therapy (PBSC)	n/a	Day +23	Transfusion refractory thrombocytopenia, Day +21 (IVIg Day +23, Romiplostim Day +24)
2	20,F	DLBCL with idiopathic aplastic anemia and rising PNH clone	TBI, Cyclophosphamide	10/10 Unrelated Bone Marrow Transplant	Tacrolimus, Methotrexate, Corticosteroids	Day +17	Severe intestinal GVHD (Corticosteroids, Basiliximab, Ruxolitinib)
3	6,M	B-cell Acute Lymphoblastic Leukemia with near haploidy	TBI, Cytarabine, Cyclophosphamide	10/10 Unrelated PBSC Transplant	Tacrolimus, Methotrexate, Corticosteroids	Day +17	Resolved grade I skin GVHD, Severe intestinal GVHD (Corticosteroids)

⁺ Defined as the post-transplant day with three days of absolute neutrophil count > 500/mm³

Abbreviations: DLBCL = Diffuse large B-cell lymphoma, PNH = Paroxysmal Nocturnal Hemoglobinuria, TBI = total body irradiation, PBSC = Peripheral blood stem cells, GVHD = Graft versus host disease