

UCLA

UCLA Previously Published Works

Title

Microaxial Flow Left Ventricular Assist Device as a Bridge to Transplantation after LVAD Malfunction.

Permalink

<https://escholarship.org/uc/item/6qp21787>

Journal

Texas Heart Institute Journal, 42(6)

Authors

Reich, Heidi

Shah, Aamir

Azarbal, Babak

et al.

Publication Date

2015-12-01

DOI

10.14503/THIJ-14-4654

Peer reviewed

Microaxial Flow Left Ventricular Assist Device

as a Bridge to Transplantation after LVAD Malfunction

Heidi J. Reich, MD
Aamir Shah, MD
Babak Azarbal, MD
Jon Kobashigawa, MD
Jaime Moriguchi, MD
Lawrence Czer, MD
Fardad Esmailian, MD

Evolving technology and improvements in the design of modern, continuous-flow left ventricular assist devices have substantially reduced the rate of device malfunction. As the number of implanted devices increases and as survival prospects for patients with a device continue to improve, device malfunction is an increasingly common clinical challenge. Here, we present our initial experience with an endovascular microaxial flow left ventricular assist device as a successful bridge to transplantation in a 54-year-old man who experienced left ventricular assist device malfunction. (Tex Heart Inst J 2015;42(6):572-4)

Heat failure remains the leading cause of death in the United States and worldwide, and the prevalence of heart failure in the U.S. continues to rise.¹ For patients with refractory heart failure, cardiac function deteriorates despite maximal medical therapy, warranting consideration of mechanical circulatory support or heart transplantation. Because of the improvements in overall survival rates and in survival to transplantation imparted by newer, continuous-flow assist devices, the number of patients sustained by mechanical circulatory support as a bridge to transplantation is growing rapidly.² Malfunction of continuous-flow devices is rare but remains a considerable challenge. Treatment options for patients with device malfunction include sternotomy or thoracotomy with left ventricular assist device (LVAD) exchange, extracorporeal membrane oxygenation, microaxial LVAD placement, intra-aortic balloon counterpulsation, or inotropic support alone. The new-generation microaxial LVADs afford full support (generating flow rates of up to 5 L/min) and are inserted endovascularly, without a need to open the chest or to use cardiopulmonary bypass (CPB). Here, we describe the novel and successful use of the Impella® 5.0 (Abiomed, Inc.; Danvers, Mass) as a bridge to transplantation in a patient with LVAD malfunction.

Key words: Heart-assist devices; heart transplantation; ventricle-assist devices

From: Cedars-Sinai Heart Institute (Drs. Azarbal, Czer, Esmailian, Kobashigawa, Moriguchi, Reich, and Shah) and Department of Surgery (Dr. Reich), Cedars-Sinai Medical Center, Los Angeles, California 90048

Address for reprints:
Fardad Esmailian, MD,
Cedars-Sinai Heart Institute,
127 S. San Vicente Blvd.,
A-3600, Los Angeles, CA
90048

E-mail:
fardad.esmailian@cshs.org

© 2015 by the Texas Heart®
Institute, Houston

Case Report

A 54-year-old man with ischemic cardiomyopathy underwent placement of a HeartMate II® LVAD (Thoratec Corporation; Pleasanton, Calif) as a bridge to heart transplantation in December of 2010, 3 years before his presentation at our center. Because of his prolonged time on the transplant list, he was referred to our center for dual listing.

While waiting for a suitable donor heart to become available, he developed frequent device malfunction due to malposition of the inflow cannula (Fig. 1). The LVAD malfunctions included intermittent low speeds and transient pump stops. Although poor cannula position is usually apparent early after implantation, our patient might have developed cannula malposition in a delayed manner because of left ventricular (LV) remodeling. We admitted him and listed him for heart transplantation as status 1A. Despite our reductions in pump speed, withholding of diuretics, aggressive fluid administration, and empiric heparinization for possible pump thrombosis, the LVAD alarms persisted. The frequency of alarms increased, and the device was no longer able to generate adequate flows. An echocardiogram showed an LV ejection fraction of 0.15 to 0.25 and no flow in the inflow cannula. The device was turned off to prevent emboli, and the patient was maintained on inotropic support.

Despite maximal medical therapy, his cardiac function progressively deteriorated. We considered the risks and benefits of various mechanical circulatory support devices, including repeat sternotomy with LVAD exchange or total artificial heart implan-

tation, versus placement of an Impella 5.0 or intra-aortic balloon pump. For device exchange necessitated by pump thrombosis or intrinsic device failure, thoracotomy is an option that avoids CPB. However, in the pres-

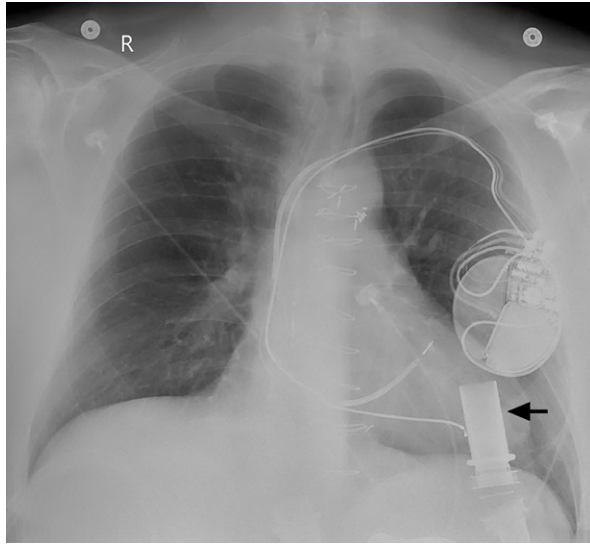


Fig. 1 Chest radiograph shows malposition of the left ventricular assist device inflow cannula (arrow). In correct position, the inflow cannula would be directed toward the mitral valve; here, it faces the anterolateral wall of the left ventricle, causing device malfunction.

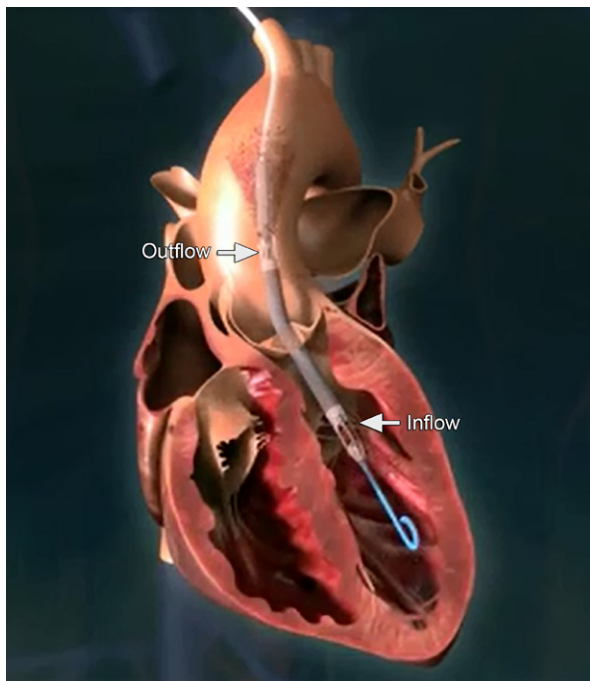


Fig. 2 Illustration of an Impella 5.0 traversing the ascending aorta, the aortic valve, and the cavity of the left ventricle. Left ventricular blood enters the device (inflow) and is ejected into the ascending aorta (outflow), at a flow rate up to 5 L/min. This is a stock image courtesy of AbioMed, Inc.

ence of inlet cannula malposition, repeat sternotomy and CPB are necessary because myomectomy or other maneuvers might well be required to optimize the new inflow cannula position. Ultimately, in an attempt to spare the patient the morbidity of an additional repeat sternotomy, we used a novel approach: insertion of the Impella 5.0 as a bridge to transplantation after LVAD malfunction.

An Impella 5.0 was placed via the right subclavian artery. Using an infraclavicular approach, we anastomosed a 10-mm Vascutek® Gelweave™ graft conduit (Vascutek, a Terumo company; Renfrewshire, Scotland) to the right subclavian artery in an end-to-side manner and tunneled it subcutaneously. Then, under fluoro-

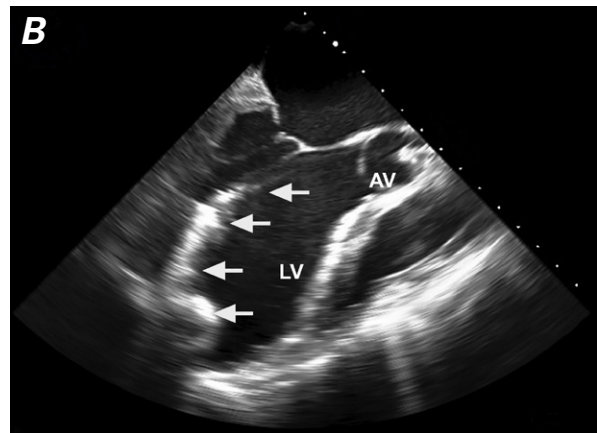
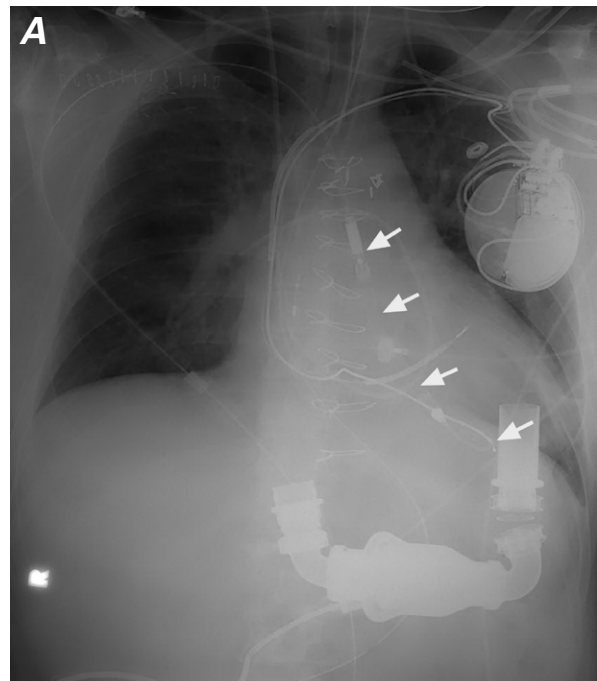


Fig. 3 The Impella 5.0 (arrows) inserted in our patient is shown on **A**) a chest radiograph and **B**) a transesophageal echocardiogram.

AV = aortic valve; LV = left ventricle

scopic guidance, the Impella 5.0 (Fig. 2) was advanced through the graft and into the LV. A chest radiograph (Fig. 3A) and an echocardiogram (Fig. 3B) confirmed that the device was in appropriate position, with the tip of the device in the cavity of the LV. The device maintained excellent flow at a rate of 4.8 L/min, and the patient's hemodynamic status improved. Inotropic support was reduced over the next several days. After 9 days of support with the Impella 5.0, an appropriate organ became available and the patient underwent repeat sternotomy and orthotopic heart transplantation with removal of the Impella 5.0 and the HeartMate II LVAD. On postoperative day 1, the patient experienced weakness and diminished pulses in the right upper extremity, which resolved after right subclavian exploration and thrombectomy. The patient recovered well from these operations, was discharged from the hospital in excellent condition 17 days after his transplant, and was alive and well 13 months after transplantation.

Discussion

In 2013, the Interagency Registry for Mechanically Assisted Circulatory Support reported an all-time high of 590 devices implanted as bridges to transplantation, along with an additional 838 devices implanted as bridges to candidacy.³ The reduced rates of device malfunction experienced with continuous-flow (as opposed to pulsatile-flow) devices are encouraging, but device malfunction leading to device exchange or death remains a relatively common challenge: the incidence is approximately 15% at 36 months.²

The emergence of smaller, temporary ventricular flow pumps adds a treatment option for the management of device malfunction. As a microaxial, endovascular device designed to provide temporary support for acute or decompensated LV dysfunction, the Impella 5.0 can be inserted via femoral or subclavian arteries; subclavian access is generally preferred because it enables the patient to walk with the device in place. Previous investigators have reported favorable outcomes when using the Impella 5.0 for postcardiotomy shock,⁴ acute cardiogenic shock,⁵ acute rejection after heart transplantation,⁶ and bridging to durable mechanical circulatory support.^{7,8}

Avoidance of repeat sternotomy for device exchange has important implications for the patient who is listed for heart transplantation. Prior cardiac surgery not only creates technical challenges during heart transplantation but is associated with increased morbidity and mortality rates after transplantation. A recent review of the United Network for Organ Sharing database found that prior sternotomy was associated with reduced survival rates and an increased incidence of cardiac reoperation, dialysis, stroke, and infection during the first 60 days after heart transplantation.⁹

The placement of any support device is not without risk. This case highlights the importance of close monitoring for vascular complications, such as the development of thrombus, when using (and after removing) microaxial LVADs. Fortunately for our patient, the thrombus that developed after device removal was recognized and treated promptly, and he recovered without long-term sequelae.

To the best of our knowledge, this is the first report of an Impella 5.0's use as a bridge to transplantation in a patient with LVAD malfunction. Temporary support with microaxial LVADs adds a valuable treatment option for device malfunction and can successfully support the patient until a suitable organ becomes available in regions where donor hearts are more accessible.

References

1. Go AS, Mozaffarian D, Roger VL, Benjamin EJ, Berry JD, Blaha MJ, et al. Heart disease and stroke statistics--2014 update: a report from the American Heart Association. *Circulation* 2014;129(3):e28-e292.
2. Kirklin JK, Naftel DC, Kormos RL, Stevenson LW, Pagani FD, Miller MA, et al. Fifth INTERMACS annual report: risk factor analysis from more than 6,000 mechanical circulatory support patients. *J Heart Lung Transplant* 2013;32(2):141-56.
3. Interagency Registry for Mechanically Assisted Circulatory Support [Internet]. Available at: <http://www.uab.edu/intermacs> [cited 2014 Apr 4].
4. Griffith BP, Anderson MB, Samuels LE, Pae WE Jr, Naka Y, Frazier OH. The RECOVER I: a multicenter prospective study of Impella 5.0/LD for postcardiotomy circulatory support. *J Thorac Cardiovasc Surg* 2013;145(2):548-54.
5. Lemaire A, Anderson MB, Lee LY, Scholz P, Prendergast T, Goodman A, et al. The Impella device for acute mechanical circulatory support in patients in cardiogenic shock. *Ann Thorac Surg* 2014;97(1):133-8.
6. Chandola R, Cusimano R, Osten M, Horlick E. Use of Impella 5L for acute allograft rejection postcardiac transplant. *Thorac Cardiovasc Surg* 2012;60(4):302-4.
7. Rajagopalan N, Yanagida R, Hoopes CW. Insertion of Impella 5.0 to improve candidacy for HeartMate II left ventricular assist device placement. *J Invasive Cardiol* 2014;26(4):E40-1.
8. Pozzi M, Quessard A, Nguyen A, Mastroianni C, Niculescu M, Pavie A, Leprince P. Using the Impella 5.0 with a right axillary artery approach as bridge to long-term mechanical circulatory assistance. *Int J Artif Organs* 2013;36(9):605-11.
9. Kansara P, Czer L, Awad M, Arabia F, Mirocha J, De Robertis M, et al. Heart transplantation with and without prior sternotomy: analysis of the United Network for Organ Sharing database. *Transplant Proc* 2014;46(1):249-55.