

# UC Davis

## UC Davis Previously Published Works

### Title

Equine idiopathic hemorrhagic cystitis: Clinical features and comparison with bladder neoplasia

### Permalink

<https://escholarship.org/uc/item/6rr031g1>

### Journal

Journal of Veterinary Internal Medicine, 32(3)

### ISSN

0891-6640

### Authors

Smith, Fauna L  
Magdesian, K Gary  
Michel, Adam O  
[et al.](#)

### Publication Date

2018-05-01

### DOI

10.1111/jvim.15121

Peer reviewed

# Equine idiopathic hemorrhagic cystitis: Clinical features and comparison with bladder neoplasia

Fauna L. Smith<sup>2</sup>  | K. Gary Magdesian<sup>1</sup>  | Adam O. Michel<sup>2</sup> | Betsy Vaughan<sup>3</sup> | Christopher M. Reilly<sup>4</sup>

<sup>1</sup>Department of Medicine and Epidemiology, School of Veterinary Medicine, University of California, Davis, California

<sup>2</sup>William R. Pritchard Veterinary Medical Teaching Hospital, University of California Davis, Davis, California

<sup>3</sup>Department of Surgical and Radiological Sciences, University of California Davis, Davis, California

<sup>4</sup>Department of Pathology, Microbiology and Immunology, University of California, Davis, California

## Correspondence

K. Gary Magdesian, Department of Medicine and Epidemiology, School of Veterinary Medicine, University of California, Davis, CA 95616.  
Email: kmagdesian@ucdavis.edu

## Present address

Christopher M. Reilly, Insight Veterinary Specialty Pathology, Austin, TX 78752

**Background:** A new syndrome of hematuria in horses has been documented.

**Hypothesis/Objectives:** Hemorrhagic cystitis is a novel cause of stranguria and hematuria in horses. This syndrome may be difficult to differentiate from bladder neoplasia because they share several clinical features.

**Animals:** Eleven horses with idiopathic hemorrhagic cystitis and 7 horses with bladder neoplasia.

**Methods:** Retrospective cohort study.

**Results:** Hemorrhagic cystitis was detected on cystoscopy of affected horses, with hemorrhagic and thickened apical bladder mucosa. Clinical signs and endoscopic appearance of the bladder resolved within 3-8 weeks. Histopathology of bladder mucosal biopsy specimens featured neutrophilic and hemorrhagic cystitis. Histopathology was suggestive of dysplasia or neoplasia in 3 horses with hemorrhagic cystitis, yet the horses experienced complete resolution, suggesting that small biopsy specimens obtained by endoscopy can be difficult to interpret. Horses with bladder neoplasia had lower hematocrits, were older, more likely to be female, and more likely to have a mass detected on ultrasonographic examination of the bladder than horses with hemorrhagic cystitis syndrome.

**Conclusions and Clinical Importance:** Hemorrhagic cystitis represents a novel differential diagnosis for horses with hematuria, and is associated with a favorable prognosis. Although histopathology may suggest a neoplastic process, affected horses should be monitored cystoscopically, because complete resolution of hemorrhagic cystitis occurs. The cause of this disease is unknown, and warrants investigation.

## KEYWORDS

bladder neoplasia, cystoscopy, hematuria

## 1 | INTRODUCTION

Primary cystitis appears to be rare in horses,<sup>1</sup> although the true incidence is unknown. Cystitis in horses most commonly is reported secondary to physiologic or anatomical disorders that result in abnormal

**Abbreviations:** CBC, complete blood count; CFU, colony forming units; NSAIDs, nonsteroidal anti-inflammatory drugs; OR, odds ratio; PCR, polymerase chain reaction; WBC, white blood cell count.

This is an open access article under the terms of the Creative Commons Attribution-NonCommercial License, which permits use, distribution and reproduction in any medium, provided the original work is properly cited and is not used for commercial purposes. © 2018 The Authors. Journal of Veterinary Internal Medicine published by Wiley Periodicals, Inc. on behalf of the American College of Veterinary Internal Medicine.

emptying of the bladder such as spinal cord disease, congenital abnormalities or injury,<sup>2-4</sup> but can also occur secondary to cystic calculi, sabulous urolithiasis, and cyclophosphamide or phenylbutazone administration.<sup>5-8</sup> Primary hemorrhagic cystitis occurs in other species including cats, humans, Grant's gazelles, and cattle. These syndromes have been associated with environmental stressors, viral pathogens, and toxin ingestion, although the exact pathogenesis remains unclear in many cases.<sup>9-15</sup> Causes of hematuria and dysuria in adult horses

reported in the literature include cystic calculi and bladder neoplasia.<sup>8,16</sup> Cystic calculi often are readily diagnosed on rectal palpation, but also can be detected by ultrasonography and cystoscopy.<sup>8</sup> Rectal examination is likely to yield a mass effect in horses with bladder neoplasia.<sup>16</sup>

Our objective was to describe the clinicopathologic features, treatment, and outcome of a novel clinical syndrome in horses, termed idiopathic hemorrhagic cystitis. A secondary objective was to compare features of idiopathic hemorrhagic cystitis to clinical findings in horses with bladder neoplasia because difficulty may occur in distinguishing the 2 disorders. The hypothesis tested was that there are no significant differences in clinical or clinicopathologic data that would clearly differentiate between horses with idiopathic hemorrhagic cystitis and those with bladder neoplasia.

## 2 | MATERIALS AND METHODS

A computer search of the medical record database of horses examined at the William R. Pritchard Veterinary Medical Teaching Hospital (VMTH), University of California at Davis, between January 2004 and July 2016 was undertaken to identify horses with hematuria and hemorrhagic mucosal lesions noted on cystoscopy. Data extracted from the medical records included signalment, presenting complaint, duration of clinical signs, physical examination findings, clinicopathologic results (CBC, serum biochemistry, urinalysis, and urine culture), cystoscopic and ultrasonographic findings, biopsy results, treatment, and outcome.

Additionally, the medical records database was searched for horses diagnosed with bladder neoplasia over the same time period to provide a comparison group for which history, presenting complaints and clinical signs would be similar. The control population for breed and sex was considered to be all horses admitted to the VMTH during the same time period, excluding those in the 2 groups.

### 2.1 | Statistical analysis

Data were evaluated for normality using a Kolmogorov-Smirnov test. Hematologic and biochemical findings were compared between the hemorrhagic cystitis and neoplasia groups using a Mann-Whitney *U* test. Age was compared using an unpaired Student's *t* test. Categorical variables, including presence of pyuria, sex, presence of mass appearance on ultrasound examination, breed and survival were compared using Fisher's exact test, with calculation of odds ratios (OR) and 95% confidence intervals (CI). A *P* value <.05 was considered significant.

## 3 | RESULTS

### 3.1 | Hemorrhagic cystitis

Eleven horses met the inclusion criteria for hemorrhagic cystitis. The median age was 16 years (range, 9–30 years). Several breeds were represented, including Quarter Horse (3), Warmblood (3), Morgan (1), Welsh (1), Paint (1), Connemara (1), and Rocky Mountain (1). Rocky Mountain horses (*P* = .0022), Connemaras (*P* = .0003), and Welsh

ponies (*P* = .043) were over represented as compared with the control population. Ten horses were male (9 geldings and 1 stallion) and 1 was female.

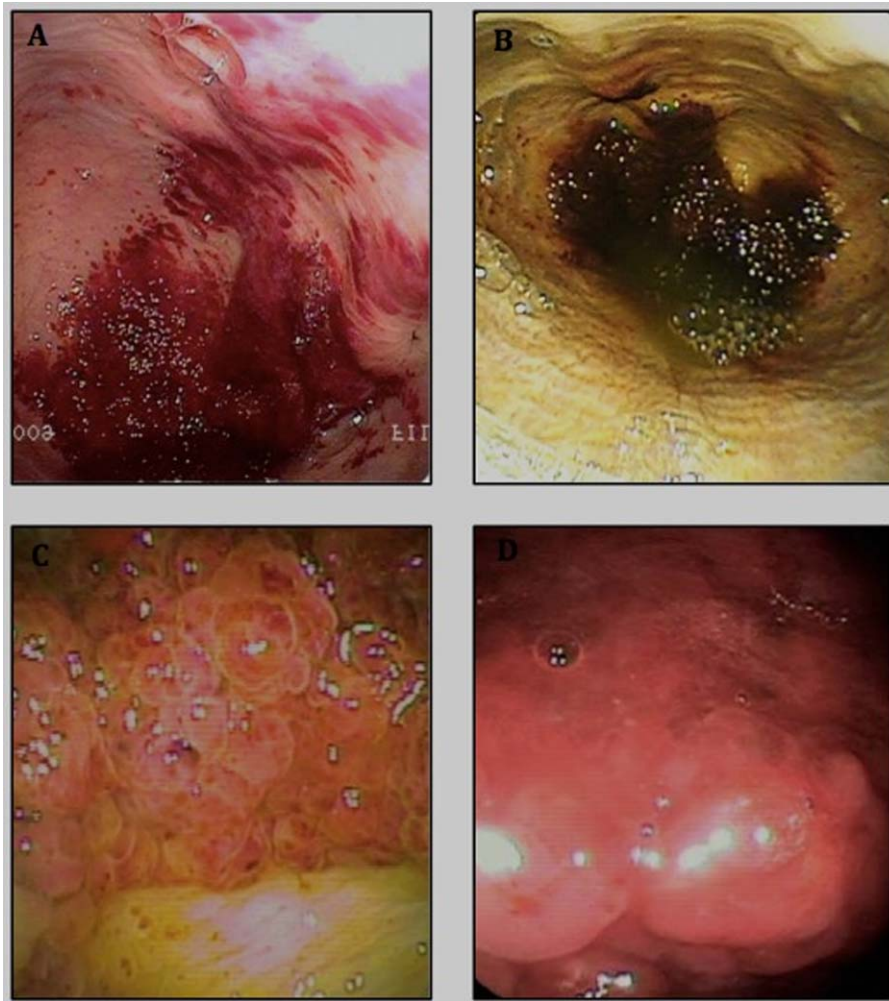
All patients had a history of passing grossly red-colored urine, with other abnormalities consisting of pollakiuria (7), stranguria (7), and abnormal posturing to urinate (1). Duration of clinical signs ranged from 1 to 30 days (median, 3 days). Before presentation, a veterinarian had examined and initiated treatment in 4 horses, whereas 7 horses had not been evaluated by a veterinarian. Prescribed therapies in the 4 horses included nonsteroidal anti-inflammatory drugs (NSAIDs; 3), and antimicrobials (1). Four horses had preexisting conditions for which they were being treated or had been treated for in the recent past: orthopedic disease—phenylbutazone (1); firocoxib and isoxsuprine (1); gastric ulcers—omeprazole (1); pars pituitary intermedia dysfunction—pergolide (1); and, equine metabolic syndrome—levothyroxine (1). Housing management was recorded for 9 of the horses: 8 horses were housed in a stall and paddock with pasture turn-out ranging from 2 to 12 hours/day, the ninth horse was housed in a large box stall. Two horses previously had been seen for abnormal behaviors: 1 was diagnosed with trigeminal-mediated head shaking and the other had erratic episodic behavior of unknown etiology.

Seven horses were observed to urinate during hospitalization. Three had no abnormalities noted during the witnessed urination. Abnormalities noted in the other 4 horses included sheath or ventral edema (2), red color of urine (4), pollakiuria (1), and stranguria (1). Four horses were not observed to urinate during hospitalization. All horses were afebrile with normal respiratory rates and normal to mildly increased heart rates. Five horses had manual rectal examination performed: No abnormalities were detected in 3 horses, a thickened urethra was noted in 1 horse, and a thickened bladder wall was noted craniodorsally in 1 horse.

Urinalyses, CBC and serum biochemistry were available for 11 horses. Common findings on urinalysis were hematuria (11), proteinuria (10), pyuria (7), and presence of transitional cells (7). Mild anemia (hematocrit [HCT] < 30.0%) was present in 5 horses. The median HCT of the group was 30.6 (range, 28.6%–38.8%; reference range, 30%–46%). Five patients had mild lymphopenia. The median lymphocyte count was 1482 cells/ $\mu$ L (range 1240–2560/ $\mu$ L; reference range, 1600–5800  $\mu$ L). Less common CBC abnormalities included hyperfibrinogenemia (2), neutrophilia (1), and neutropenia (1). Biochemistry results were unremarkable in all cases, except for 1 horse, which had hyperglobulinemia.

Quantitative urine cultures were performed on all 11 horses using catheterized samples. No growth was the most common finding (10), and 1 horse had  $>4 \times 10^3$  colony-forming units (cfu)/mL of mixed bacterial growth, considered a contaminant. Bladder mucosa from 2 horses was submitted for culture, with both samples being negative for bacterial growth.

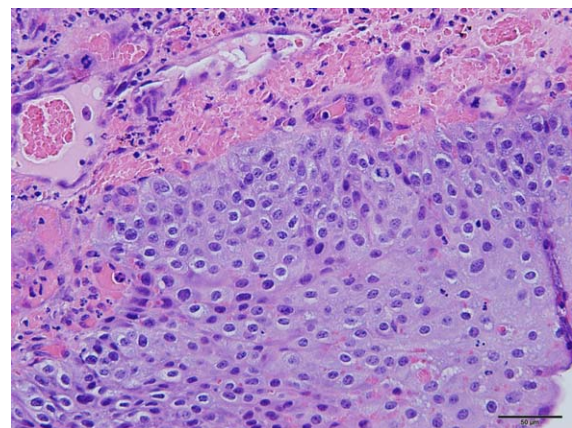
Cystoscopic findings included hemorrhagic and thickened bladder mucosa, with the most severely affected region being the cranioventral or apical region of the bladder (Figure 1). In some cases, mucosal hemorrhage radiated out to the remainder of the bladder with the apex remaining the most severely affected region. The bladder mucosa



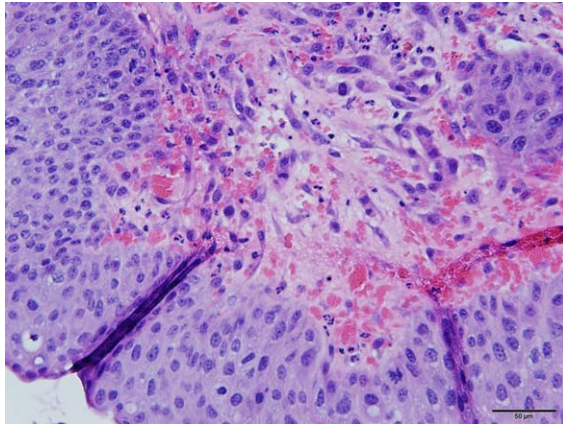
**FIGURE 1** A, Cystoscopic view of the bladder in a 16-year-old Morgan Gelding with hemorrhagic cystitis. B, Cystoscopic view of bladder apex in a 19-year-old Rocky Mountain Gelding with hemorrhagic cystitis. C, Close-up view of inflamed tissue in B, showing proliferative appearance of lesion. D, Inflamed, hemorrhagic, proliferative appearance of hemorrhagic lesions in a 12-year-old Welsh Pony

appeared markedly thickened with proliferative mass lesions on close inspection (Figure 1C,D). Biopsies of the bladder mucosa were obtained using an endoscopic biopsy instrument (Endoscopy Support Services Reusable Long Ellipsoid Cup biopsy forceps; SKU QFC-1027, ESS, Inc 3, Fallsview Lane, Brewster, New York 10509) by cystoscopy in 6 horses.

The most common histopathologic diagnosis was neutrophilic or suppurative cystitis with hemorrhage (4; Figure 2); others were transitional cell dysplasia (1), hyperplasia, dysplasia and fibrinosuppurative cystitis (1), and presumed transitional cell carcinoma (1; Figure 3). All tissue samples had evidence of neutrophilic infiltration and hyperplasia of the urinary epithelium, as well as expansive submucosal hemorrhage and stromal cell reactivity. The severity of these histopathologic changes varied among patients. Less consistent features included mitotic figures (2), lymphoplasmacytic inflammation (2), and fibrin thrombi (2). In the 2 cases with mitotic figures, there were 2/10  $\times 400$  fields in 1 case and 20/10  $\times 400$  fields in the second case. Two others were noted to have no mitotic figures. Because of the small size of the endoscopic biopsy instrument, tissue samples often were small and



**FIGURE 2** H&E Stain of a bladder biopsy from a 22-year-old warmblood horse with hemorrhagic cystitis ( $\times 200$  magnification). The histopathological diagnosis was neutrophilic hemorrhagic cystitis. Submucosal hemorrhage, neutrophilic inflammation, mitoses, stromal reactivity, and epithelial hyperplasia are present



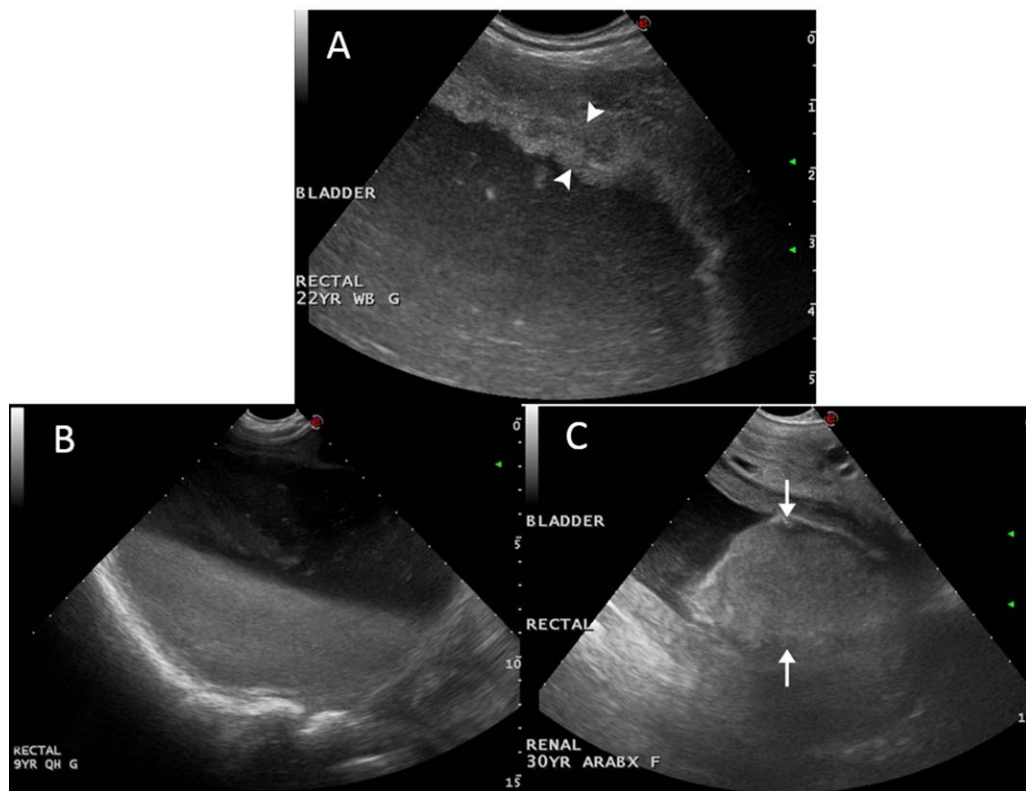
**FIGURE 3** H&E Stain of a bladder biopsy from a 19-year-old Rocky Mountain horse with hemorrhagic cystitis ( $\times 200$  magnification). The histopathological diagnosis was “presumptive transitional cell carcinoma,” which completely resolved. Submucosal hemorrhage, neutrophilic inflammation, mitoses, stromal reactivity, and epithelial hyperplasia are present

sometimes had crush or sectioning artifact, making it difficult to conclude whether the lesions were definitively neoplastic. Pathologists used expressions such as presumed transitional cell carcinoma, hyperplasia, dysplasia, possibility of neoplasia, and transitional cell dysplasia.

Ultrasonographic examination of the urinary tract, including trans-abdominal evaluation of the kidneys, as well as per rectum evaluation of the left kidney, both ureters and bladder wall, was performed in 7 horses. Abnormal findings included thickening of the bladder wall (3), suspected renal hematoma or abscess (2), increased urine echogenicity or sludge (3), mass-like lesion on the bladder wall ( $< 2$  cm; 1), and thickened ureteral wall (1; Figure 4A,B).

All horses were treated with antimicrobials: trimethoprim-sulfamethoxazole or trimethoprim-sulfadiazine ( $n = 11$ ; 24–30 mg/kg PO q12h) and ceftiofur ( $n = 1$ ; 2.2 mg/kg IV q12h). The horse treated with ceftiofur was switched to trimethoprim-sulfamethoxazole at the time of discharge. Other common treatments included NSAIDs: flunixin meglumine ( $n = 5$ ; 0.5–1.0 mg/kg IV PO q12–24h), firocoxib ( $n = 2$ ; 0.1 mg/kg PO q24h), as well as the mucosal analgesic phenazopyridine ( $n = 7$ ; 4 mg/kg PO q12h). One horse with a history of prolonged phenylbutazone administration before presentation for cystitis was treated with misoprostol ( $n = 1$ ; 5  $\mu$ g/kg PO q12h).

Short-term follow-up was available for all 11 horses. Nine horses were presented for repeat endoscopy within 3–8 weeks of discharge, with hematuria and stranguria having been resolved in all horses. Abnormal cystoscopic findings had completely resolved in 8 and had largely resolved in the ninth horse at follow-up cystoscopy 3 weeks later. Owners reported resolution of clinical signs in the other 2 horses



**FIGURE 4** A, Transrectal ultrasonographic image of a thickened urinary bladder (arrowheads) in a 22-year-old warm blood gelding diagnosed with hemorrhagic cystitis. Image was obtained at 7.5 MHz with a microconvex curvilinear transducer at a depth of 5.4 cm. B, Transrectal ultrasonographic image of a urinary bladder in a 9-year-old QH gelding diagnosed with hemorrhagic cystitis. Echogenic swirling consistent with hemorrhage was seen within the urinary bladder dorsal to the settled sediment. Image was obtained at 5.0 MHz with a microconvex curvilinear transducer at a depth of 15.7 cm. C, Transrectal ultrasonographic image of a 30-year-old Arabian-cross mare with transitional cell carcinoma (arrows) of the urinary bladder. Image was obtained at 5.0 MHz with a microconvex curvilinear transducer at a depth of 12.9 cm

that were not returned to the hospital for repeat endoscopy. Ten horses with long-term follow-up (range; 4–144 months) had no further occurrences of hematuria. One horse had a bout of pollakiuria and was treated with another course of trimethoprim-sulfamethoxazole by the owner and on cystoscopy 5 days after discontinuing the antibiotics, the bladder mucosa appeared normal. Twelve years later, that horse remains normal. The 2 horses suspected to have renal masses on ultrasonographic imaging were evaluated 1 and 2 months after diagnosis, respectively. The suspected mass was no longer visible in the first horse and the small mass-like lesion in the second horse was unchanged and assumed to be an incidental finding. Nine horses returned to their previous level of performance, and 1 horse was rehomed as a lesson horse because of orthopedic issues. Bladder tissue from 1 horse was submitted for PCR analysis for equine herpes virus-5, bovine papilloma virus 1 and 2, and equine adenovirus 1 and 2, all of which yielded negative results.

### 3.2 | Bladder neoplasia

Seven horses had a diagnosis of urinary bladder neoplasia during the same time period. The median age was 24 years (range, 16–30 years). Several breeds were affected, including Arabian or Arabian cross (3), Shire (2), Appaloosa (1), and Quarter Horse X Thoroughbred cross (1). All 7 horses were female, 1 of which was pregnant. Females were significantly overrepresented as compared to the overall hospital population ( $P = .0076$ ; OR, 19.97; 95% CI, 1.14–349.86). Shires and Arabians or Arabian-crosses were overrepresented as compared with the overall hospital population ( $P < .0001$ ; OR, 254.10; 95% CI, 48.80–1322.90 and  $P = .03$ ; OR, 6.20; 95% CI, 1.38–27.53, respectively). The presenting complaints all related to the urinary tract: hematuria (6), pollakiuria (2) and stranguria (1). Five horses had presumptive diagnoses by the referring veterinarians: cystic calculi (2), bladder neoplasia (2) and cystic calculus or bladder neoplasia (1). Duration of clinical signs before presentation ranged from 1 to 120 days (median, 6 days). Results of rectal palpation performed by the referring veterinarians were recorded for 2 horses, both of which had a bladder mass palpated. One horse had a manual vaginal examination performed by the referring veterinarian and was thought to have a urethral mass. The horse with the suspected urethral mass and 3 additional horses had manual rectal examinations performed at the time of presentation to the hospital and all were considered to be normal.

Hematology and serum biochemistry analyses were performed in 4 horses. All 4 horses were anemic (median HCT, 26.6%; range, 23.3%–26.9%). Other common findings were lymphopenia (2) and hyperglobulinemia (2). Urinalysis was performed on 4 horses with common abnormalities consisting of hematuria (3), proteinuria (3), pyuria (3), and transitional cells (3). Urine culture was performed on catheterized samples from 2 horses and both samples grew bacteria: *Actinobacillus* spp. ( $>10^5$  cfu/mL; 1) and *E. coli* ( $>10^5$  cfu/mL; 1).

The diagnosis of bladder neoplasia was confirmed by histopathology in all 7 horses: transitional cell carcinoma (3) and squamous cell carcinoma (4). Other histologic features included neutrophilic infiltration (6), mitotic figures (6), lymphoplasmacytic inflammation (4), and transitional cell dysplasia (1). The number of mitotic figures ranged from 1/

10 to 46/10  $\times$ 400 fields (median, 7/10  $\times$ 400 fields). Histologic samples submitted (some horses had premortem and postmortem samples) included surgically resected tissue (2), necropsy tissues (3), large biopsy specimens ( $\geq 5$  mm) obtained from the bladder (2), and small biopsy specimen ( $< 5$  mm) obtained during cystoscopy (1). All biopsy specimens were larger than those obtained by cystoscopic biopsy in the hemorrhagic cystitis cases, enabling more definitive histopathologic diagnoses. Six horses had cystoscopy performed. The most common findings were irregular, hemorrhagic bladder wall (6), and mass effect in the apex or ventral bladder (4). Cystoscopic images of horses with transitional cell carcinoma are shown in Figure 5.

Ultrasonographic examination of the urinary tract was performed on 5 horses (Figure 4C). All 5 had a bladder mass diagnosed on ultrasound examination, with urinary tract abnormalities: small right kidney (1), cortical cyst (1), mass or altered echogenicity of renal parenchyma of the right kidney (1), sludge or increased urine echogenicity (2), thickened ureter with hyperechoic luminal contents (1), and thickened bladder wall (1). Two horses were considered to have ultrasonographic findings consistent with metastasis, 1 on the initial examination (mass in the kidney) and the other on follow-up examination months after surgical resection (multiple abdominal masses).

Follow-up information was available for 6 horses. Five ultimately were euthanized because of ongoing clinical signs referable to neoplasia, and 1 died 1.5 months after surgical resection of the tumor, but with no information in the medical record as to the cause of death.

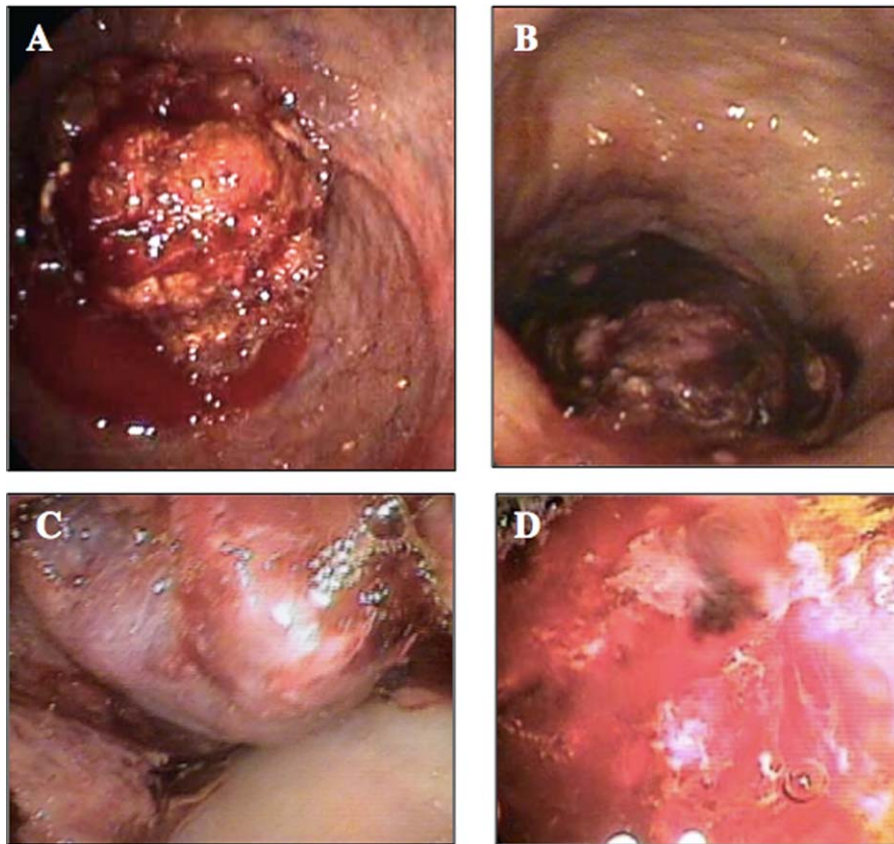
#### 3.2.1 | Comparison of the two groups

Horses with hemorrhagic cystitis were significantly more likely to survive than were horses with bladder neoplasia (OR, 345; 95% CI, 6.15–19 360;  $P < .0001$ ; Table 1). Horses with hemorrhagic cystitis were more likely to be male than horses with neoplasia (OR, 105.00; 95% CI, 3.74–2950.50;  $P = .0003$ ; Table 1). Horses with hemorrhagic cystitis also were younger than horses with neoplasia ( $P = .018$ ). The presenting complaints, history, and physical examination findings were similar between horses with hemorrhagic cystitis and those with bladder neoplasia. There was no significant difference in rectal palpation of a mass effect between the 2 groups ( $P = .62$ ).

Horses with hemorrhagic cystitis had a higher HCT than did horses with neoplasia ( $P = .0015$ ). The cystitis group was less likely to have a mass on bladder ultrasonographic examination (OR, 0.021; 95% CI, 0.0007–0.63;  $P = .02$ ; Table 1). Histologic evidence of neoplasia or dysplasia in the tissue samples was not different between the 2 groups ( $P = .07$ ). There was no difference in the number of mitotic figures between groups ( $P = .24$ ).

## 4 | DISCUSSION

Idiopathic hemorrhagic cystitis is a newly described cause of hematuria and stranguria in horses. Although horses with neoplasia had lower HCT, older age, were more likely to be female, and were more likely to have a mass detected on ultrasonographic examination than those with hemorrhagic cystitis, there were no specific laboratory or clinical findings that clearly distinguished the between 2 syndromes. Welsh ponies,



**FIGURE 5** A, Cystoscopic view of the bladder in a 26-year-old Arabian mare with transitional cell carcinoma. B, Cystoscopic view of bladder apex in a 30-year-old Arabian-cross mare with transitional cell carcinoma. C, Close-up view of neoplastic tissue in B, showing proliferative appearance. D, Inflamed, hemorrhagic, proliferative appearance of a transitional cell carcinoma in a 23-year-old Arabian/Mustang cross mare

Connemaras, and Rocky Mountain horses were overrepresented in the cystitis group. These breed overrepresentations should be interpreted with caution however because of the presence of only 1 of each, and these breeds are uncommon in the hospital population. Shires were overrepresented in the bladder neoplasia group. The prognosis for horses with hemorrhagic cystitis was favorable, with complete resolution achieved in all horses.

Hemorrhagic cystitis cases were compared with horses diagnosed with bladder neoplasia because horses with both of these problems often are presented with hematuria or stranguria. In 1 cystitis case, histopathology yielded a presumptive diagnosis of transitional cell neoplasia, and transitional dysplasia in 2 others. The rapid resolution of signs and lesions, without reoccurrence, however indicated that these lesions were not neoplastic. In other species, dysplastic and metaplastic changes along with hemorrhage are relatively common in patients with chronic cystitis, and this also appears to be true in horses.<sup>17-19</sup>

Ultrasonographic examination may be useful in differentiating hemorrhagic cystitis from bladder neoplasia. Ultrasonography showed a mass effect in the bladder in all neoplasia cases, despite manual rectal examinations being normal in the majority of cases. One horse with cystitis also had a small mass-like effect, but the mass was much smaller than those noted in the neoplastic cases. Manual palpation was not found to be as useful in our study as has previously been reported.<sup>16</sup> This observation may reflect earlier detection of disease in

our population of horses. Ultrasonography was able to identify likely metastasis in 2 horses further aiding in the differentiation of cystitis and bladder neoplasia. Cystoscopy identified a mass in the bladder of 4 of the neoplasia cases, but in 2 cases ultrasonographic examination identified masses that were not seen on cystoscopy.

Based on our findings, horses presenting with hematuria and grossly abnormal, thickened, and hemorrhagic bladder mucosa observed on cystoscopy should not necessarily be assumed to have bladder neoplasia, even when histopathology from cystoscopically obtained biopsy specimens is presumptive (as in 1/6 horses) or

**TABLE 1** Summary of non-numerical clinical data comparing horses with hemorrhagic cystitis and bladder neoplasia horses

		Hemorrhagic cystitis	Bladder neoplasia	P value
Sex	Male	10	0	.0003*
	Female	1	7	
Bladder Mass on Ultrasound	Yes	1	6	.015*
	No	5	0	
Survival	Recovered	11	0	<.0001*
	Died/euthanized	0	7	

\*Significance set at  $P < .05$ .

indicates dysplasia (as in 2/6 cases). Rather, these horses should be reevaluated in a few weeks by cystoscopy, because horses with hemorrhagic cystitis have an excellent prognosis. In cases in which a large mass is detected by ultrasonographic examination, cystoscopy, rectal palpation, or some combination of these procedures, every effort should be made to pursue a definitive diagnosis at the time of the initial evaluation because more aggressive therapeutic intervention such as surgical resection may be warranted.

All horses affected with hemorrhagic cystitis in our study were treated with trimethoprim-sulfa drugs. However, bacterial culture of urine and bladder tissue most often was negative or failed to yield clinically relevant growth. Histology also did not identify any bacterial microorganisms. It is impossible to determine whether the horses improved because of the trimethoprim-sulfa, or if its use was coincidental to recovery. Further investigation is needed to determine if such treatment is useful.

Hemorrhagic cystitis is recognized in cats, humans, Grant's gazelles and cattle with the inciting cause being environmental or behavioral (cats), viral or drug-induced (human), idiopathic (Grant's gazelles), and a combination of viral and toxic (cattle).<sup>9-15</sup> Additional risk factors for idiopathic cystitis in cats include male sex, middle age, and being overweight.<sup>20</sup> Interestingly, male sex and middle age also appear to be common findings in horses with hemorrhagic cystitis. Husbandry risk factors in cats include indoor housing, use of a litter box, and stress.<sup>14,20</sup> In the horses of our study, there was no historical evidence to suggest that the housing environment contributed to altered urination habits, although all horses had some stall-confinement. Housing and potential behavioral stressors warrant closer study in horses with hemorrhagic cystitis. None of the horses had any common history to suggest the potential for exposure to toxins. One published study found a weak association between *Bartonella* infection and feline interstitial cystitis.<sup>21</sup> In horses, *Bartonella* spp. have been implicated in hepatitis, vasculitis, and arthropathies.<sup>22-24</sup> *Bartonella* may warrant further investigation in horses with hemorrhagic cystitis.

In cattle, chronic enzootic hematuria is associated with bracken fern toxicity, which can progress to bladder neoplasia. Infection with bovine papilloma virus-2 may play a role in progression to bladder cancer in affected cattle.<sup>10,25</sup> Further evaluation for possible links to viruses is warranted in horses. In humans, hemorrhagic cystitis has been associated with bacteria, pelvic irradiation, and chemotherapy.<sup>13</sup> Adenovirus and BK virus have been associated with the syndrome in humans.<sup>26</sup> Further evaluation for a possible role of viruses in equine idiopathic cystitis is warranted.

In conclusion, idiopathic hemorrhagic cystitis is a newly described cause of hematuria and stranguria in horses, associated with the presence of proliferative, hemorrhagic bladder mucosa on cystoscopy. Affected horses should be reevaluated in 2-4 weeks, because they have an excellent prognosis.

## ACKNOWLEDGMENTS

This study was not supported by any grant or funding. This article was presented at the 2016 Conference of the American Association of Equine Practitioners in research abstract form.

## CONFLICT OF INTEREST DECLARATION

The authors declare that they have no conflict of interest with the contents of this article.

## OFF-LABEL ANTIMICROBIAL DECLARATION

Ceftiofur was administered IV rather than IM to one horse. This is extralabel in route of administration, but this route has been studied and published in the peer-reviewed literature.

## INSTITUTIONAL ANIMAL CARE AND USE COMMITTEE (IACUC) OR OTHER APPROVAL DECLARATION

Authors declare no IACUC or other approval was needed.

## ORCID

Fauna L. Smith  <http://orcid.org/0000-0001-5535-7726>

K. Gary Magdesian  <http://orcid.org/0000-0001-9988-3381>

## REFERENCES

- [1] Schumacher J. Hematuria and pigmenturia of horses. *Vet Clin North Am Equine Pract.* 2007;23:655-675.
- [2] Goehring LS, Landolt GA, Morley PS. Detection and management of an outbreak of equine herpesvirus type 1 infection and associated neurological disease in a veterinary teaching hospital. *J Vet Intern Med.* 2010;24:1176-1183.
- [3] Knight PR. Equine cystitis and ataxia associated with grazing of pastures dominated by sorghum species. *Aust Vet J.* 1968;44:257.
- [4] Morgan SE, Johnson B, Brewer B, Walker J. Sorghum cystitis ataxia syndrome in horses. *Vet Hum Toxicol.* 1990;32:582.
- [5] Aleman M, Nieto JE, Higgins JK. Ulcerative cystitis associated with phenylbutazone administration in two horses. *J Am Vet Med Assoc.* 2011;239:499-503.
- [6] Rendle DI, Durham AE, Hughes KJ, Lloyd D, Summerhays GE. Long-term management of sabulous cystitis in five horses. *Vet Rec.* 2008;162:783-787.
- [7] Saulez MN, Cebra CK, Heidel JR, Walker RD, Singh R, Bird KE. Encrusted cystitis secondary to *Corynebacterium matruchotii* infection in a horse. *J Am Vet Med Assoc.* 2005;226:246-248.
- [8] Duesterdieck-Zellmer KF. Equine urolithiasis. *Vet Clin North Am Equine Pract.* 2007;23:613-629.
- [9] Decker DB, Karam JA, Wilcox DT. Pediatric hemorrhagic cystitis. *J Pediatr Urol.* 2009;5:254-264.
- [10] Carvalho T, Pinto C, Peleteiro MC. Urinary bladder lesions in bovine enzootic haematuria. *J Comp Pathol.* 2006;134:336-346.
- [11] Georoff TA, Garner MM, Hoover JP, Backues KA. Retrospective evaluation of idiopathic hematuria and associated pathology in Grant's gazelles (*Gazella granti*): 10 cases. *J Zoo Wildl Med.* 2009;40:639-651.
- [12] West NJ. Prevention and treatment of hemorrhagic cystitis. *Pharmacotherapy.* 1997;17:696-706.
- [13] Traxer O, Desgrandchamps F, Sebe P, et al. [Hemorrhagic cystitis: etiology and treatment]. *Prog Urol.* 2001;11:591-601.
- [14] Forrester SD, Towell TL. Feline idiopathic cystitis. *Vet Clin North Am Small Anim Pract.* 2015;45:783-806.
- [15] Herenda D, Dukes TW, Feltmate TE. An abattoir survey of urinary bladder lesions in cattle. *Can Vet J.* 1990;31:515-518.



- [16] Fischer AT Jr, Spier S, Carlson GP, Hackett RP. Neoplasia of the equine urinary bladder as a cause of hematuria. *J Am Vet Med Assoc.* 1985;186:1294–1296.
- [17] Kryvenko ON, Epstein JI. Pseudocarcinomatous urothelial hyperplasia of the bladder: clinical findings and followup of 70 patients. *J Urol.* 2013;189:2083–2086.
- [18] Clouston D, Lawrentschuk N. Metaplastic conditions of the bladder. *BJU Int.* 2013;112Suppl 2:27–31.
- [19] Lopez-Beltran A, Marques RC, Montironi R, Reymundo C, Fonseca J, Cheng L. Dysplasia and carcinoma in situ of the urinary bladder. *Anal Quant Cytopathol Histpathol.* 2015;37:29–38.
- [20] Defauw PA, Van de Maele I, Duchateau L, Polis IE, Saunders JH, Daminet S. Risk factors and clinical presentation of cats with feline idiopathic cystitis. *J Feline Med Surg.* 2011;13:967–975.
- [21] Sykes JE, Westropp JL, Kasten RW, Chomel BB. Association between Bartonella species infection and disease in pet cats as determined using serology and culture. *J Feline Med Surg.* 2010;12:631–636.
- [22] Setlakwe EL, Sweeney R, Engiles JB, Johnson AL. Identification of Bartonella henselae in the liver of a thoroughbred foal with severe suppurative cholangiohepatitis. *J Vet Intern Med.* 2014;28:1341–1345.
- [23] Jones SL, Maggi R, Shuler J, Alward A, Breitschwerdt EB. Detection of Bartonella henselae in the blood of 2 adult horses. *J Vet Intern Med.* 2008;22:495–498.
- [24] Cherry NA, Jones SL, Maggi RG, Davis JL, Breitschwerdt EB. Bartonella spp. infection in healthy and sick horses and foals from the southeastern United States. *J Vet Intern Med.* 2012;26:1408–1412.
- [25] Cota JB, Peleteiro MC, Petti L, Tavares L, Duarte A. Detection and quantification of bovine papillomavirus type 2 in urinary bladders and lymph nodes in cases of Bovine Enzootic Hematuria from the endemic region of Azores. *Vet Microbiol.* 2015;178:138–143.
- [26] Shakiba E, Yaghobi R, Ramzi M. Prevalence of viral infections and hemorrhagic cystitis in hematopoietic stem cell transplant recipients. *Exp Clin Transplant.* 2011;9:405–412.

**How to cite this article:** Smith FL, Magdesian KG, Michel AO, Vaughan B, Reilly CM. Equine idiopathic hemorrhagic cystitis: Clinical features and comparison with bladder neoplasia. *J Vet Intern Med.* 2018;32:1202–1209. <https://doi.org/10.1111/jvim.15121>