

# UC Irvine

## UC Irvine Previously Published Works

### Title

Therapeutic response of facial papules and inflammation in frontal fibrosing alopecia to low-dose oral isotretinoin

### Permalink

<https://escholarship.org/uc/item/6st9x0bb>

### Journal

JAAD Case Reports, 6(5)

### ISSN

2352-5126

### Authors

Pham, Christine T  
Hosking, Anna-Marie  
Cox, Surget  
[et al.](#)

### Publication Date

2020-05-01

### DOI

10.1016/j.jdcr.2020.01.030

### Copyright Information

This work is made available under the terms of a Creative Commons Attribution License, available at <https://creativecommons.org/licenses/by/4.0/>

Peer reviewed

# Therapeutic response of facial papules and inflammation in frontal fibrosing alopecia to low-dose oral isotretinoin



Christine T. Pham, BS, Anna-Marie Hosking, MD, Surget Cox, MD, and  
Natasha Atanaskova Mesinkovska, MD, PhD  
*Irvine, California*

**Key words:** facial papules; frontal fibrosing alopecia; inflammation; isotretinoin.

## INTRODUCTION

First described in 1994 by Kossard,<sup>1</sup> frontal fibrosing alopecia is characterized by scarring alopecia with gradual progressive recession of the frontotemporal portion of the hairline, occurring anywhere from 0.4 to 1.7 mm per month.<sup>2</sup> This variant of lichen planopilaris is most commonly found in postmenopausal women and is increasing in prevalence. In addition to hair loss, other features associated with this condition include a band of thin, scarred skin with distinguished vessels, sparse lone vellus hairs, and perifollicular erythema with surrounding fibrosis. Facial papules are a synchronous finding present in 14% of patients with frontal fibrosing alopecia, with profound effects on appearance.<sup>3</sup> The pathogenesis of these lesions is not fully understood and there are currently no established treatments; however, theories involve inflammation of hair follicles, dilated or enlarged sebaceous glands, or a combination of the 2.

Herein, we present 3 patients with frontal fibrosing alopecia with progressive hair loss and concomitant facial papules who experienced hair loss stability and significant improvement of facial papules with the use of oral isotretinoin. Severity of scalp disease was graded 0 to 3 for presence and intensity of perifollicular scale, erythema, and folliculitis.

## CASE SERIES

### Case 1

A 28-year-old woman presented with a 4-year history of biopsy-proven, progressive frontal

fibrosing alopecia with severe facial papule eruptions. Physical examination revealed alopecia on the frontoparietal scalp and lateral eyebrows, with perifollicular erythema, scale, and skin-colored papules on her forehead (Fig 1, A). The scalp condition was scored as perifollicular scale 2+, erythema 2+, and folliculitis 2+. The patient had previously failed a 6-month course of oral doxycycline and intralesional triamcinolone, and at presentation had been receiving minocycline 100 mg by mouth twice daily for 6 months, without improvement. She began receiving oral isotretinoin 20 mg twice daily in addition to her current hair treatment regimen: minoxidil 5% topically twice daily, ketoconazole shampoo 2% topically 3 times per week, fluocinonide 0.05% solution topically twice daily, and intralesional triamcinolone 5 mg/mL every 6 to 8 weeks. At 1-month follow-up, she displayed decreased shedding and improvement in scalp scores, with perifollicular scale 1+, erythema 1+, and folliculitis 1+. A significant decrease in the number and size of her facial papules was also observed, along with hairline stability, with continued remarkable improvement by month 6, when the dose was decreased (Fig 1, B). The patient continued receiving therapy with isotretinoin 20 mg once a day and currently has good control of disease and regrowth of eyebrows.

### Case 2

A 42-year-old man presented with a 5-year history of progressive frontal fibrosing alopecia and lichen

From the Department of Dermatology, University of California—Irvine.

Funding sources: None.

Conflicts of interest: None disclosed.

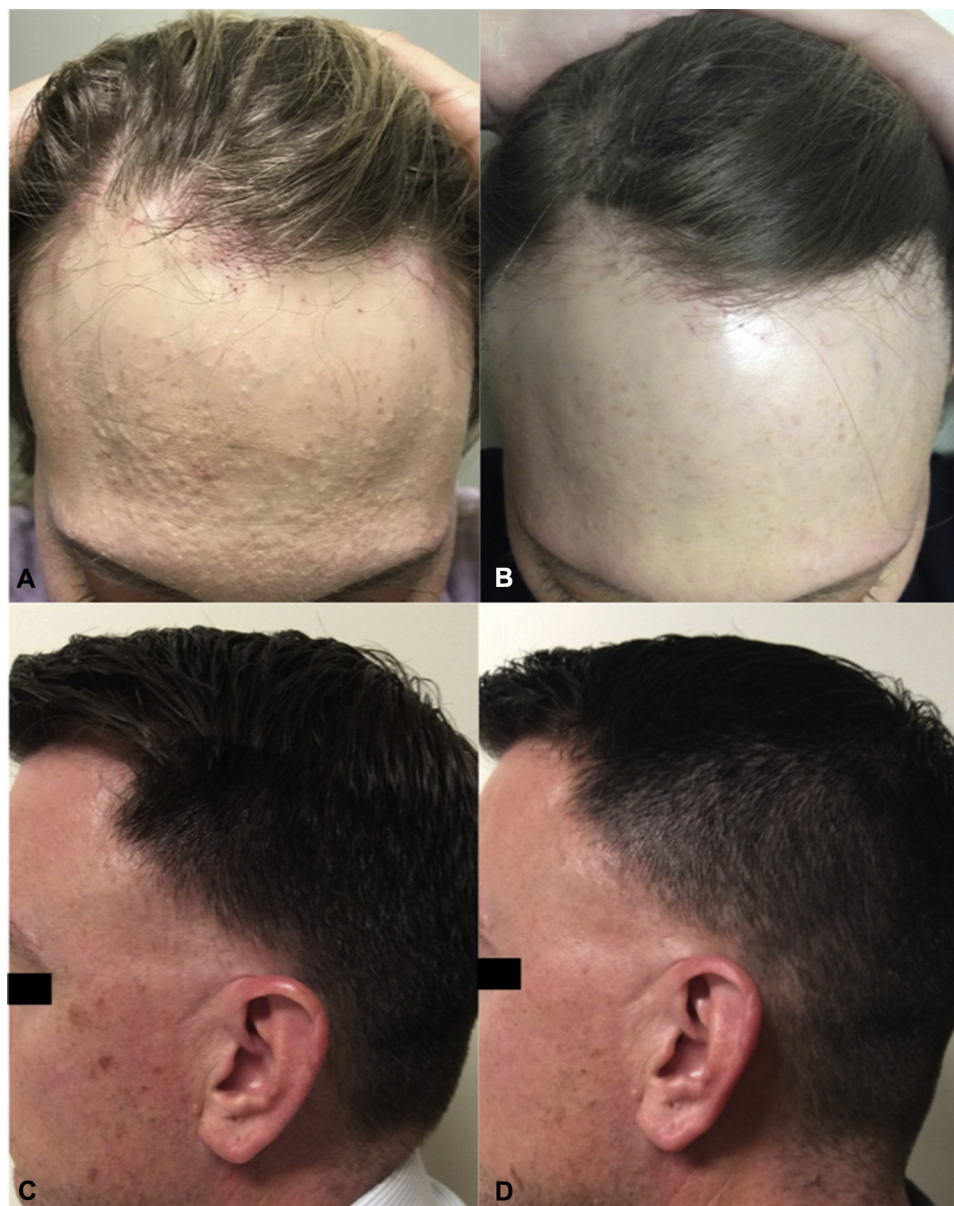
Correspondence to: Christine T. Pham, BS, Department of Dermatology, University of California—Irvine, 843 Health Sciences Rd, Irvine, CA 92697. E-mail: [christinethpham@gmail.com](mailto:christinethpham@gmail.com).

JAAD Case Reports 2020;6:453-6.

2352-5126

© 2020 by the American Academy of Dermatology, Inc. Published by Elsevier, Inc. This is an open access article under the CC BY-NC-ND license (<http://creativecommons.org/licenses/by-nc-nd/4.0/>).

<https://doi.org/10.1016/j.jidcr.2020.01.030>



**Fig 1.** **A** and **B**, Facial papules in a female patient with frontal fibrosing alopecia before isotretinoin treatment and with significant reduction after 6 months of treatment. **C** and **D**, A male patient with frontal fibrosing alopecia before isotretinoin treatment and with stabilization and decreased inflammation after 3 months of treatment.

planopilaris as part of Graham-Little-Piccardi-Lasseur syndrome, and with moderate to severe papules on the forehead, chest, neck, and back. The patient also had a history of oral lichen planus and hypothyroidism currently treated with a supplement. His previous treatments included topical and intralesional triamcinolone and hydroxychloroquine, with continued progression of disease. He had also received oral finasteride 1.25 mg daily, but reported sexual dysfunction after 2 weeks and ceased treatment. Physical examination showed

progressive hair loss on the frontal portion of the hairline and 1- to 3-mm skin-colored papules present on the forehead and face (Fig 1, C). Scalp examination scores were perifollicular scale 1+, erythema 1+, and folliculitis 1+, with medial thinning of eyebrows. Tacrolimus 0.1% topical ointment was prescribed for the hairline and eyebrows. The patient began receiving oral isotretinoin 30 mg daily, and in addition, he continued to receive intralesional triamcinolone 5 mg/mL every 6 to 8 weeks. At 1-month follow-up, examination showed reduction of scalp

scores to erythema perifollicular scale 0, erythema 0/1+, and folliculitis 0/1+. At 3-month follow-up, examination showed hair loss stability, less inflammation and redness on the scalp and eyebrows, and decreased hair shedding (Fig 1, D). Improvement of papules was observed by month 6, with minor adverse effects including xerosis cutis of the face and lips. The dose was then decreased to 30 mg every other day, and he has not needed intralesional triamcinolone injections since. An 18-month follow-up showed near-complete regrowth of eyebrows.

### Case 3

A 65-year-old postmenopausal woman with a 2-year history of frontal fibrosing alopecia and lichen planopilaris presented with facial papules, frontal hair loss, and evidence of scalp inflammation with reported pruritus. Physical examination revealed frontal and vertex scalp hair loss with significant perifollicular erythema and scale, and numerous red and skin-colored papules on the frontotemporal portion of the forehead. Scalp scores were recorded as perifollicular scale 2+, erythema 3+, and folliculitis 2+. The patient's eyelashes and eyebrows were scant. She began receiving isotretinoin 20 mg by mouth daily and continued with intralesional triamcinolone 5 mg/mL every 6 to 8 weeks and topical clobetasol 0.05% solution daily on the scalp. At 4- and 8-month follow-up, the patient exhibited decreased hair shedding on the scalp, perifollicular scale, erythema, folliculitis, and facial papules, whereas no eyebrow changes were observed. Results were maintained at the 12-month follow-up, with self-reported eyelash thickening at 2-year follow-up. The patient tolerated the medication well, with minor adverse effects including xerosis of the lips.

### DISCUSSION

Isotretinoin is a vitamin A derivative traditionally used to treat moderate to severe acne. In our case series of 3 patients, low-dose isotretinoin was effective for the treatment of inflammation and facial papules associated with frontal fibrosing alopecia. The mechanism of action of isotretinoin in stabilizing hair loss and decreasing inflammation in frontal fibrosing alopecia is not clearly understood, but it has been proposed that it normalizes follicular keratinocyte antigen expression and reduces inflammatory cellular infiltrate. One retrospective study reported stabilization of the frontal hairline with isotretinoin 20 mg by mouth daily for a mean treatment duration of 13.5 months (range 12-16 months) in 76% of patients with frontal fibrosing alopecia (n = 23/29), and 72% of those patients

(n = 21/29) had no further progression of disease after discontinuation of treatment when evaluated at 24 months.<sup>4</sup> In addition, a few studies have reported the use of isotretinoin for lichen planopilaris.<sup>5,6</sup> In 1 study, isotretinoin 1 mg/kg by mouth was given to 15 patients with treatment-resistant lichen planopilaris. Resolution of inflammation was observed in 66.66% of patients after 4 months of therapy.<sup>6</sup> Spano and Donovan<sup>5</sup> reported that 24% of patients (n = 5/21) with treatment-resistant lichen planopilaris had at least 1 of the following after receiving a course of retinoids: improvement in erythema, scaling, or hyperkeratosis; cessation of hair loss; and conversion from positive to negative pull test result, with approximately 2 to 4 months until clinical improvement. Twelve patients had received acitretin 25 to 50 mg, 8 had received isotretinoin 1 mg/kg, and 1 received both at different periods.

Facial papules and rosacea-like eruptions are present in a subset of patients with frontal fibrosing alopecia.<sup>3</sup> These papules most commonly are keratotic, presenting as skin roughness on the forehead and frontotemporal portion of the scalp; however, they have also been reported on the chest, back, and extremities.<sup>7</sup> The pathogenesis of facial papules in frontal fibrosing alopecia remains unclear.<sup>3,8,9</sup> Histologic examination demonstrates mild follicular hyperkeratosis and lichenoid dermatitis involving the infundibulum and isthmus of vellus hair follicles with or without fibrosis, similar to findings observed in lichen planopilaris.<sup>10,11</sup>

However, other reports dispute the involvement of vellus hairs and show abundant sebaceous glands and dilated ducts, with reduction of overlying elastic fibers, but no vellus hair that contributes to formation of papules.<sup>12</sup> These various histologic findings raise the possibility of different types of papules involved in frontal fibrosing alopecia, or different stages of evolution of the same inflammatory process. It is possible that vellus hair follicles were present and destroyed by the inflammation, leaving only hypertrophic sebaceous glands that became raised because of an overlying atrophic epidermis.<sup>9,13</sup>

One proposed mechanism of action of isotretinoin therapy in treating facial papules is through the reduction of sebum production, sebaceous gland size, and colonization of propionibacterium acnes. The rapid response of facial papules after the use of low-dose isotretinoin in these 3 patients corroborates this theory. Clinical reduction of facial papules was observed as early as 2 weeks, with excellent responses observed after 1 to 4 months of isotretinoin use. The duration of therapy remains to be

established because these patients are being carefully tapered off their dose.

## CONCLUSION

A subset of patients with frontal fibrosing alopecia has concomitant facial papules in addition to progressive hair loss. Low-dose isotretinoin can be used as a treatment to control facial papules and scalp inflammation associated with frontal fibrosing alopecia. Further large-scale studies with long-term follow-up are necessary to confirm efficacy and determine dosing guidelines.

## REFERENCES

1. Kossard S. Postmenopausal frontal fibrosing alopecia. Scarring alopecia in a pattern distribution. *Arch Dermatol*. 1994;130(6):770-774.
2. Tan KT, Messenger AG. Frontal fibrosing alopecia: clinical presentations and prognosis. *Br J Dermatol*. 2009;160(1):75-79.
3. Pirmez R, Duque-Estrada B, Barreto T, Quintella DC, Cuzzi T. Successful treatment of facial papules in frontal fibrosing alopecia with oral isotretinoin. *Skin Appendage Disord*. 2017;3(2):111-113.
4. Rakowska A, Gradzinska A, Olszewska M, Rudnicka L. Efficacy of isotretinoin and acitretin in treatment of frontal fibrosing alopecia: retrospective analysis of 54 cases. *J Drugs Dermatol*. 2017;16(10):988-992.
5. Spano F, Donovan JC. Efficacy of oral retinoids in treatment-resistant lichen planopilaris. *J Am Acad Dermatol*. 2014;71(5):1016-1018.
6. Tan E, Martinka M, Ball N, Shapiro J. Primary cicatricial alopecias: clinicopathology of 112 cases. *J Am Acad Dermatol*. 2004;50(1):25-32.
7. Moreno-Ramirez D, Camacho Martinez F. Frontal fibrosing alopecia: a survey in 16 patients. *J Eur Acad Dermatol Venereol*. 2005;19(6):700-705.
8. Lopez-Pestana A, Tuneu A, Lobo C, et al. Facial lesions in frontal fibrosing alopecia (FFA): clinicopathological features in a series of 12 cases. *J Am Acad Dermatol*. 2015;73(6):987.e1-987.e6.
9. Pedrosa AF, Duarte AF, Haneke E, Correia O. Yellow facial papules associated with frontal fibrosing alopecia: a distinct histologic pattern and response to isotretinoin. *J Am Acad Dermatol*. 2017;77(4):764-766.
10. Abbas O, Chedraoui A, Ghosn S. Frontal fibrosing alopecia presenting with components of Piccardi-Lassueur-Graham-Little syndrome. *J Am Acad Dermatol*. 2007;57(2 suppl):S15-S18.
11. Donati A, Molina L, Doche I, Valente NS, Romiti R. Facial papules in frontal fibrosing alopecia: evidence of vellus follicle involvement. *Arch Dermatol*. 2011;147(12):1424-1427.
12. Pirmez R, Barreto T, Duque-Estrada B, Quintella DC, Cuzzi T. Histopathology of facial papules in frontal fibrosing alopecia and therapeutic response to oral isotretinoin. *J Am Acad Dermatol*. 2018;78(2):e45.
13. Pedrosa AF, Duarte AF, Haneke E, Correia O. Reply to: "histopathology of facial papules in frontal fibrosing alopecia and therapeutic response to oral isotretinoin". *J Am Acad Dermatol*. 2018;78(2):e47-e48.