

# UCLA

## UCLA Previously Published Works

### Title

Stem cell treatments for oropharyngeal dysphagia: Rationale, benefits, and challenges

### Permalink

<https://escholarship.org/uc/item/6t62b2kh>

### Journal

World Journal of Stem Cells, 12(9)

### ISSN

1948-0210

### Authors

Tran, Eric K

Juarez, Kevin O

Long, Jennifer L

### Publication Date

2020-09-26

### DOI

10.4252/wjsc.v12.i9.1001

Peer reviewed

## Stem cell treatments for oropharyngeal dysphagia: Rationale, benefits, and challenges

Eric K Tran, Kevin O Juarez, Jennifer L Long

**ORCID number:** Eric K Tran 0000-0003-4506-9266; Kevin O Juarez 0000-0002-5104-6047; Jennifer L Long 0000-0002-4185-2328.

**Author contributions:** All authors contributed to literature review, drafting, and revising manuscript.

**Conflict-of-interest statement:** No potential conflicts of interest.

**Open-Access:** This article is an open-access article that was selected by an in-house editor and fully peer-reviewed by external reviewers. It is distributed in accordance with the Creative Commons Attribution NonCommercial (CC BY-NC 4.0) license, which permits others to distribute, remix, adapt, build upon this work non-commercially, and license their derivative works on different terms, provided the original work is properly cited and the use is non-commercial. See: <http://creativecommons.org/licenses/by-nc/4.0/>

**Manuscript source:** Invited manuscript

**Received:** February 28, 2020

**Peer-review started:** February 28, 2020

**First decision:** July 5, 2020

**Revised:** July 28, 2020

**Accepted:** September 1, 2020

**Eric K Tran**, David Geffen School of Medicine, University of California-Los Angeles, Los Angeles, CA 90095, United States

**Kevin O Juarez**, Department of Otolaryngology, Yale School of Medicine, New Haven, CT 06511, United States

**Jennifer L Long**, Department of Head and Neck Surgery, David Geffen School of Medicine, University of California-Los Angeles, Los Angeles, CA 90095, United States

**Jennifer L Long**, Greater Los Angeles VA Healthcare System, Los Angeles, CA 90073, United States

**Corresponding author:** Jennifer L Long, MD, PhD, Associate Professor, Department of Head and Neck Surgery, David Geffen School of Medicine, University of California-Los Angeles, 650 Charles Young Dr, CHS Room 62-150, Los Angeles, CA 90095, United States.  
[jlong@mednet.ucla.edu](mailto:jlong@mednet.ucla.edu)

### Abstract

Dysphagia, defined as difficulty swallowing, is a common symptom negatively impacting millions of adults annually. Estimated prevalence ranges from 14 to 33 percent in those over age 65 to over 70 percent in a nursing home setting. The elderly, those with neurodegenerative diseases, head and neck cancer patients, and those with autoimmune conditions such as Sjögren's syndrome are disproportionately affected. Oropharyngeal dysphagia refers specifically to difficulty in initiating a swallow due to dysfunction at or above the upper esophageal sphincter, and represents a large proportion of dysphagia cases. Current treatments are limited and are often ineffective. Stem cell therapy is a new and novel advancement that may fill a much-needed role in our treatment regimen. Here, we review the current literature regarding stem cell treatments for oropharyngeal dysphagia. Topics discussed include tissue regeneration advancements as a whole and translation of these principles into research surrounding tongue dysfunction, xerostomia, cricopharyngeal dysfunction, and finally an overview of the challenges and future directions for investigation. Although this field of study remains in its early stages, initial promising results show potential for the use of stem cell-based therapies to treat oropharyngeal dysphagia and warrant further research.

**Key Words:** Dysphagia; Xerostomia; Hemiglossectomy; Stem cells; Myoblasts;

**Article in press:** September 1, 2020

**Published online:** September 26, 2020

**P-Reviewer:** Lo Furno D, Yang RL

**S-Editor:** Huang P

**L-Editor:** A

**P-Editor:** Xing YX



Mesenchymal stem cells

©The Author(s) 2020. Published by Baishideng Publishing Group Inc. All rights reserved.

**Core Tip:** Oropharyngeal dysphagia, despite its widespread prevalence, is a difficult condition to treat, particularly in those who have undergone irradiation or resection in the head and neck. This challenge stems from the lack of native functional tissue upon which current therapies such as physical rehabilitation rely. There have been several studies examining the use of stem cell therapy as a potential new treatment option for these patients. Our objective is to review and consolidate the current literature regarding this topic and discuss the recent advancements, challenges, and future directions for research in this field.

**Citation:** Tran EK, Juarez KO, Long JL. Stem cell treatments for oropharyngeal dysphagia: Rationale, benefits, and challenges. *World J Stem Cells* 2020; 12(9): 1001-1012

**URL:** <https://www.wjgnet.com/1948-0210/full/v12/i9/1001.htm>

**DOI:** <https://dx.doi.org/10.4252/wjsc.v12.i9.1001>

## INTRODUCTION

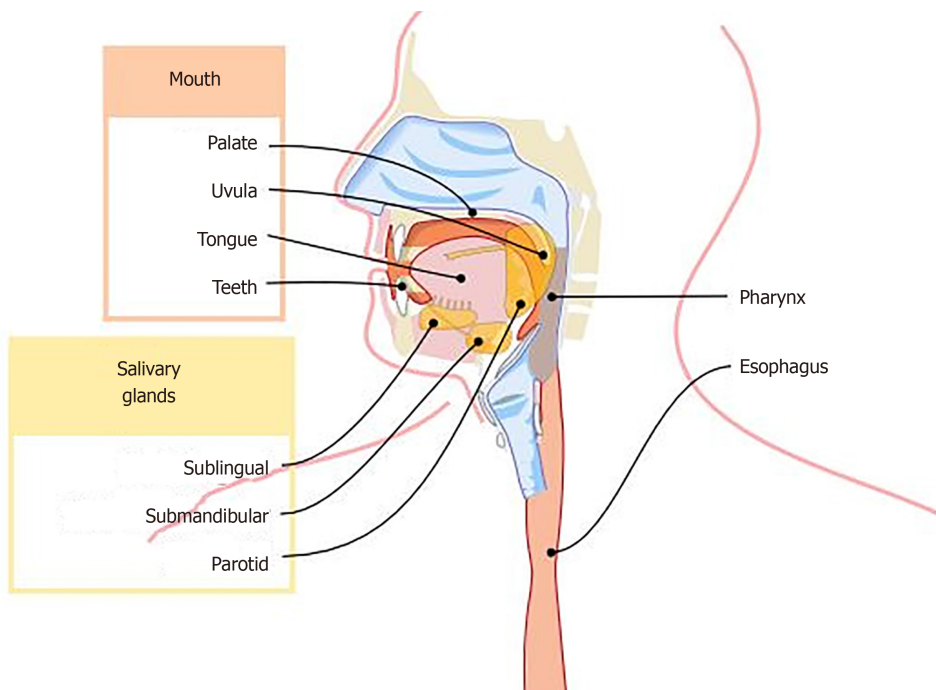
Dysphagia is an extremely common yet morbid condition affecting over 9 million or over 1 in 25 adults in the United States annually<sup>[1]</sup>. Of those reporting swallowing problems, 32% report their condition to be moderate while 25% perceive it as a large problem greatly impacting their quality of life. Stroke is the most common etiology followed by other neurologic diseases such as Parkinson's disease, amyotrophic lateral sclerosis, and muscular dystrophy<sup>[2]</sup>. Head and neck cancer and its associated treatments, including resection and irradiation, often cause oropharyngeal dysphagia as well.

Given the oropharyngeal structures' location and vital function in promoting a patent airway, speech articulation, and deglutition, damage to these structures and resulting dysphagia leads to significantly increased risk for malnutrition, aspiration pneumonia, and death. Despite the significant morbidity associated with this condition however, there exists few reliable treatments that have proven to dramatically improve outcomes. Current therapies are limited and often heavily rely on physical rehabilitation of oral cavity and oropharynx swallowing function. These include isometric and resistance lingual strengthening exercises in cases of impaired tongue functioning or muscles intended to strengthen oral cavity and pharyngeal muscles<sup>[3,4]</sup>. A study conducted by Robbins *et al*<sup>[5]</sup> showed that among ten stroke patients who underwent isometric lingual exercise program, all subjects showed significantly increased isometric and swallowing pressures, reduction in airway invasion, and even increased lingual volume. Still, although improvement has been found in young and older healthy adults and those suffering from stroke, this success has not reliably translated toward head and neck cancer patients, who may have had extensive resection or irradiation in tumor removal. In these patients, the lack of normal oropharyngeal tissue impedes the efficacy and feasibility of swallowing rehabilitation exercises. Thus, these patients may benefit from newer, more innovative therapies.

Stem cell therapy has, in recent years, generated much interest in regards to its therapeutic potential to replace damaged tissue, guide wound healing, and restore function. Current research on this topic is extremely limited and primarily in investigational stages of study, although a few have advanced to clinical trials<sup>[6]</sup>. We aim to describe the current literature regarding the promising results of stem cell administration to restore swallowing function.

## PHYSIOLOGY OF SWALLOWING

To understand dysphagia, we must first appreciate the mechanisms and anatomy underlying normal physiologic swallowing (Figure 1). Typically, swallowing consists of three stages: An oral stage, pharyngeal stage, and esophageal stage. The oral stage is



**Figure 1 Anatomy of upper gastrointestinal tract.** Depiction of upper gastrointestinal tract which clearly delineates the anatomically correlated oral, pharyngeal, and esophageal stages of swallowing. Complex interactions between numerous components facilitates this process and dysfunction in any may lead to dysphagia. This depiction also illustrates potential target areas for stem cell intervention.

further subdivided into an oral preparatory stage where a bolus of food or liquid is taken into the mouth and held in the anterior portion of the oral cavity, and an oral propulsive stage where this bolus is propelled posteriorly by the tongue into the oropharynx. Variations exist between swallowing liquids and solids. Solid food swallowing requires mastication and allows food to reside in the posterior oral cavity during bolus preparation. Liquids transit much more rapidly and are more difficult to control. Following the oral phase, the pharyngeal phase consists of two vital functions: Propulsion of the food downwards and through the upper esophageal sphincter (UES), and protection of the airway to prevent aspiration. First, the soft palate elevates and forms a seal with the posterior pharynx, preventing food from traveling upwards into the nasopharynx. The pharyngeal constrictor muscles then contract rhythmically, squeezing the bolus downwards towards the UES. Opening of the UES to allow passage into the esophagus is dependent on relaxation of the cricopharyngeus muscle, pressure from the bolus to expand the sphincter, and mechanical forces exerted by the thyrohyoid and suprahyoid muscles which lift the larynx and pull open the UES. Concurrently, the vocal folds close to seal the glottis and as the entire larynx is lifted by the thyrohyoid and suprahyoid muscles, the epiglottis is pressed against the laryngeal inlet and the oblique interarytenoid muscles contract to complete the seal. This serves to protect the airway. Finally in the esophageal stage, the bolus is propelled downwards *via* a peristaltic wave. The upper 1/3 of the esophagus is comprised primarily of skeletal muscle while the lower 2/3 is largely smooth muscle. The lower esophageal sphincter opens to allow passage into the stomach<sup>[7,8]</sup>. The entire process requires precise timing to transfer from one phase to the next. Given the enormous complexity and coordination required in swallowing, it is unsurprising that dysfunction of involved structures along any of these steps can result in dysphagia. Stem cell-based replacement therapy, thus, attempts to restore normal tissue or function in each of these structures.

## STEM CELL THERAPIES FOR LARYNGEAL MUSCLE

Within the field of skeletal muscle regeneration, laryngeal muscles are of particular interest with regards to dysphagia given the function of the larynx in protecting the airway during deglutition. Vocal fold adduction is an important mechanism in preventing aspiration and facilitating coughing should particles enter the airway, as may often occur among patients suffering from dysphagia<sup>[9]</sup>. Denervation models of

the laryngeal muscles mimic iatrogenic injuries to the recurrent laryngeal nerves or neurodegenerative diseases that commonly cause problems with swallowing. Additionally, findings regarding regeneration of bulbar muscle (innervated by cranial nerves) may differ from somatic skeletal muscles, and thus be more directly applicable to the bulbar muscles of swallowing.

Halum *et al*<sup>[10]</sup> described a denervation model of vocal fold paralysis with subsequent autologous muscle-derived stem cell (MDSC) injection. 16 male rats underwent unilateral denervation of the recurrent laryngeal nerve (RLN). Myoblasts were isolated from sternocleidomastoid muscle biopsy and cultured at subconfluency to avoid myotube formation. One month post injury, autologous MDSCs labeled with a fluorescent marker were injected into the laryngeal thyroarytenoid (TA) muscle of half the animals while the remaining half received saline alone. MDSC persistence was found at both two weeks and two months post-treatment, with evidence of fusion with native muscle fibers at two months. TA muscle volume was increased in the myoblast injection group at both time points, and muscle fiber diameter increased within the myoblast injection group by two months. Upon laryngoscopy visualization, two animals achieved weak adductor motion of the vocal folds at two months, while no adduction was observed among the control group. Researchers did not find significant differences in reinnervation between the groups indicating that the improvements were due to muscle enhancements rather than neurologic signals<sup>[10]</sup>. As a follow up, the same group studied the use of trophic factors to enhance MDSC survival following injection. They found co-administration with insulin-like growth factor (IGF-1) and ciliary neurotrophic factor (CNTF) significantly increased survival, and cell persistence correlated with decreased myofiber atrophy<sup>[11]</sup>. Furthermore, CNTF was found to enhance neuron outgrowth and branching within vagus nerve motor neuron cultures *in vitro*<sup>[12]</sup>. When these findings were translated to a larger model utilizing canines, increased laryngeal adductor force was observed in a small group of MDSC-injected larynges. Three dogs underwent RLN injury and were separated into non-injection control, MDSC injection, and MDSC-enhanced injection as defined by use of acetylcholine chloride to increase motor end plate conduction. Compared to pre-injury, the non-injected control demonstrated adduction force measurements 60% of baseline, while the MDSC-injected group and MDSC-enhanced injection group demonstrated 98% and 128% adductor force measurements respectively<sup>[13]</sup>. While swallowing function was not directly measured in any of these studies, clinical experience links laryngeal adductor function with prevention of aspiration during swallowing in a subset of patients.

---

## STEM CELL THERAPIES FOR TONGUE DYSFUNCTION

---

Several groups have attempted stem cell therapies in the tongue intended to improve swallowing following treatment for head and neck cancer. Current treatments have not reliably improved swallow function in patients who have undergone partial and total glossectomy, which remain mainstay for treatment of cancer of the tongue. Post-surgical outcomes have revealed higher incidence of inadequate tongue control, inadequate chewing, delayed oral transit time, aspiration or penetration, residue within the vallecula and piriform recesses, and inadequate laryngeal elevation after surgery<sup>[14]</sup>, leading to varying degrees of dysphagia. The base of tongue is particularly critical for swallow function, with resection of only a quarter of the tongue base resulting in impaired ability to trigger the pharyngeal swallow<sup>[15,16]</sup>. Current treatment consists of reconstructive options including myocutaneous, pedicled, and free flaps to restore bulk to the tissue, albeit typically without innervation. The field lacks clear guidelines and research into optimal reconstructive strategies, and long-term functional outcomes are poor. In a multicenter retrospective study comparing long-term functional outcomes of total glossectomy patients with or without laryngectomy, Lin *et al*<sup>[17]</sup> report 55% gastrostomy tube dependence at last follow-up, similar to the 50% dependence found by Dziegielewski *et al*<sup>[18]</sup> and 71% dependence by Rihani *et al*<sup>[19]</sup>. Clearly, newer approaches are needed which can more closely imitate native, normal tissue.

Among the first to investigate the use of muscle stem cell tissue engineering for tongue defects was Kim *et al*<sup>[20]</sup> in 2003, who described the use of a collagen-rich hydrogel populated with neonatal rat myoblasts for a partial glossectomy defect. Thirty rats underwent unilateral mucosal-sparing glossectomy, producing pockets which were then filled with either saline, collagen-rich hydrogel alone, or collagen-rich hydrogel with myoblasts. After six weeks, the group receiving the cell-containing



hydrogel demonstrated a statistically significant increase in tongue weight of the operated side compared with the control side. In contrast, the saline and hydrogel groups demonstrated loss of tongue weight. Histologically, this corresponded to islands of desmin-stain positive cells signaling presence and persistence of skeletal muscle with evidence of neovascularization and preliminary neurotization. Comparatively, the control group which received only isotonic sodium chloride demonstrated diffuse fibrosis and disorganized myofibril architecture, while the hydrogel group showed no evidence of new tissue formation.

Bunaprasert *et al.*<sup>[21]</sup> in the same laboratory explored this hemiglossectomy-pocket approach further and reported similar findings. Sixty rats were separated into five groups: Hemiglossectomy alone, collagen gel implant alone, collagen gel implant with suspended myoblasts, myoblasts cultured for 7 d in a pre-molded collagen gel, and myoblasts cultured for 7 d in a collagen gel with 2% horse serum to promote muscle differentiation. All groups gained weight appropriately without statistically significant difference between them, up to 16 wk. However, those groups containing gel alone or scar alone resulted in significant scar formation and lack of new muscle formation, whereas myoblast-containing gel contained interdigitating new muscle fibers, as confirmed by desmin, and neuroma-like fibers as well. A semi-quantitative histology score was applied to rate scar tissue and muscle formation, with best results occurring for both the undifferentiated myoblast groups irrespective of collagen culture method. Differentiated myoblasts scored better than controls but worse than their undifferentiated counterparts, suggesting either a benefit to multipotency or a detriment of the differentiation medium containing horse serum.

The same laboratory then assessed the cellular persistence in the collagen-filled pockets by implanting myoblasts that were pre-labeled with membrane dyes<sup>[22]</sup>. At six weeks, myoblasts were identified in all 12 rats studied. Cells primarily remained within their treatment pocket, with limited migration into normal tissue. Treatment group tongues showed significantly less scar contracture, increased muscle diameter, and similar architecture to normal tongue compared to control. Markedly increased desmin positivity was also observed within the treatment group as opposed to control, and microscopy revealed myoblast proliferation and fusion into viable myotubes. Note that cells alone were not tested in this series of reports.

More recently, human cells have been investigated in immune-deficient rodents, taking a step closer to human translation. Kuhn *et al.*<sup>[23]</sup> demonstrated persistence of human MDSCs injections in immune deficient mice. MDSC survival was assessed using *in vivo* imaging to visualize luciferase-transduced MDSCs. At 12 wk, the human MDSC group exhibited greater bioluminescence than immediately following injection, and increased weight gain compared to mice receiving saline injections only. Separately, Vahabzadeh *et al.*<sup>[24]</sup> performed partial glossectomy in 18 athymic rats. After two weeks for scar formation to mimic a tumor resection scenario, animals were treated with either low- or high-dose mesenchymal stem cell (MSC) or saline control. Three weeks post-injection, researchers found significantly reduced cross sectional scar burden and pathologic score for inflammation and fibrosis in the high-dose MSC group (250000 cells injected) relative to controls. Low-dose MSC (70000 cells injected) did not differ from controls. These recent studies support human stem cell persistence and efficacy in xenograft cell injection models within immunosuppressed animals, supporting the concept of autologous human stem cell injection to avoid immune rejection.

In addition to studies looking at structural improvement using stem cells, one study evaluated functional improvement in one animal. Plowman *et al.*<sup>[25]</sup> utilized a partially denervated ovine tongue model to study tongue force following injury and treatment. Two animals were denervated and injected, but only one could undergo eventual tongue force testing. A very high dose of 500 million GFP-labelled autologous MDSCs were injected into the tongues one month after bilateral hypoglossal nerve crush; histology and tongue force recordings were collected 2 mo post injection. Researchers found GFP+ muscle fibers in both tongues, indicating MDSC survival at 2 mo. They also noted increased muscle fiber diameter in GFP+ fibers suggesting reduced atrophy and even increased diameter compared to pre-injury, suggesting new muscle growth. Regarding functional improvement, the authors reported a 27% increase in maximal tongue force and a 54% increase in base of tongue pressure compared to pre-injection in the one animal tested<sup>[25]</sup>. Clearly, such a small sample size warrants further investigation to obtain more robust results. Nevertheless, this novel denervation model and functional analysis indicating not only anatomical but also improvement in force generation shows promise for further research. Whether reduced tongue atrophy and increased forced production translates into improved swallowing function, remains to be seen.

## STEM CELL THERAPIES FOR XEROSTOMIA

Dysfunctional salivary glands prove to be another major etiology of dysphagia. Saliva plays an important role in swallowing, serving to solubilize food substance, form a solid bolus by mixing with food particles, add moisture, and facilitate lubrication of the mucosa during bolus propulsion, among its other vital functions<sup>[26]</sup>. Patients with dry mouth, also known as xerostomia, due to insufficient saliva production, often report extreme difficulty in swallowing. Causes of dysfunctional salivary glands are numerous and include but are not limited to: Medications, radiation therapy for head and neck cancers, resection of salivary glands, Sjögren's syndrome, and other autoimmune disease. Regardless of cause, the symptom impacts many Americans, with a prevalence ranging from 5.5% to 46%<sup>[27]</sup>. Current therapies consist of sialogogues such as pilocarpine or cevimeline which stimulate secretion of saliva *via* binding of muscarinic receptors, although these carry their respective side effect profiles and more importantly, depend on intact functional glandular tissue to be effective. Other remedies include intraoral electrostimulation and acupuncture. However, there has not been sufficient research to confirm these as viable treatment options<sup>[27]</sup>.

A number of groups have explored the use of stem cells for xerostomia, although these are still in early stages of investigation. Lombaert *et al*<sup>[28]</sup> described an approach towards the restoration of salivary gland function by using salivary gland stem cells cultured *in vitro* then transplanted into irradiated glands. Cells isolated from murine submandibular glands and cultured *in vitro* were injected in low numbers into irradiated glands. Researchers found close to 20% more surface area of acinar cells per gland compared to the untreated irradiated group. Functionally, they observed a 42% increase in saliva production in the cell injection group compared to untreated irradiated glands<sup>[28]</sup>.

Likewise, Nanduri *et al*<sup>[29]</sup> found improved saliva production (54.59% *vs* 21.5%) in intra-glandularly injected cells *vs* irradiated control in addition to improved tissue healing, as indicated by persistence of ductal stem cell markers and revascularization. These novel studies demonstrated much promise into the therapeutic potential of regenerative medicine for restoration of salivary gland function, but knowledge regarding salivary gland stem cell behavior and characteristics was still lacking. Notably, only general stem cell markers such Sca-1, c-Kit, and Musashi-1 were used to identify the cells of interest, but a specific salivary gland stem cell marker was unable to be identified, making it difficult to track activity and persistence over time<sup>[30,31]</sup>. Furthermore, these studies were unable to maintain cells in prolonged culture, showing limited self-renewal capacity *in vitro* that serves as an additional barrier for further research.

To this end, Ikeura *et al*<sup>[32]</sup> successfully cultured cells derived from wild type murine submandibular glands for over 80 passages while maintaining their proliferative ability and morphology. Cells were isolated and cultured in low calcium, serum-free growth media with the addition of cholera toxin and epithelial growth factor to inhibit fibroblast growth and stimulate an epithelial phenotype. Notably, at passages 20, 50 and even 80, their cells did not form aggregates and salivary spheres, implying lack of cellular transformation and maintenance of a basal ductal cell phenotype which expressed keratin 14, 18 and p63, markers for basal, ductal and basal duct cells respectively<sup>[32]</sup>. This opens up exciting new avenues for research into stem cell regeneration of damaged salivary gland tissue, as researchers are now more capable of closely mimicking *in vivo* salivary gland cellular phenotypes for further study rather than relying on immortalized tumor-derived cell lines which may not behave similarly to normal cells.

Dai *et al*<sup>[33]</sup> described a different approach, whereby they demonstrated the potential for adipose tissue-derived stem cells (ADSCs) to differentiate into acinar-like epithelium capable of secreting  $\alpha$ -amylase and expressing AQP-5. ADSCs are multipotent and may provide the advantage of differentiation into different components of salivary gland epithelium, both secretory and ductal, in addition to providing local trophic effects to improve tissue healing response following injury<sup>[34]</sup>. Platelet-rich fibrin was co-administered to promote transdifferentiating into an acinar-like phenotype and was found to increase levels of both  $\alpha$ -amylase and AQP-5. Still, a unique and reliable marker for salivary gland stem cells remains to be identified and continues to be an active area of research.

Clinically, these promising initial results have been translated into a landmark randomized, placebo-controlled trial in Denmark (MESRIX trial). Grønhoj *et al*<sup>[35]</sup> randomized 30 patients to receive either ultrasound-guided injection of autologous ADSCs or placebo in submandibular glands after radiation therapy for HPV-positive

squamous cell carcinoma of the oropharynx. Cell doses administered were not clearly noted, although a planned dose of 2.8 million cells per volumetric milliliter of the gland was stated; total cell numbers harvested were between 13 and 82 million cells. No adverse events were reported. At both one and four months, patients within the ADSC arm displayed significantly increased unstimulated salivary flow rates compared to placebo, with 33% improvement over baseline at one month and 50% improvement at four months. In the placebo arm, salivary flow rates decreased remained largely unchanged. Patient-centered questionnaires revealed markedly decreased symptom reports from the ADSC group compared to placebo, reporting less difficulty within the domains of thirst and eating solid foods. Biopsies revealed increases in serous gland tissue and decrease in fibrosis and fatty deposits within the ADSC arm compared to placebo<sup>[35]</sup>. While long-term follow up is required and ongoing<sup>[36]</sup>, the findings of this initial trial are exciting. Meanwhile, a clinical trial of allogeneic mesenchymal stem cell transplantation, MESRIX-SAFE<sup>[37]</sup>, is currently recruiting participants.

---

## STEM CELL TREATMENT FOR CRICOPHARYNGEAL DYSFUNCTION

---

Further along the alimentary canal, food must travel past the UES to enter the esophagus. As mentioned before, relaxation of the UES to allow food passage largely depends upon cricopharyngeus muscle (CP) relaxation. Several disorders impair this function, leading to oropharyngeal dysphagia and food trapped upstream. The pressure buildup may eventually lead to complications such as outpouching of the mucosa, known as Zenker's diverticulum. One common etiology of CP dysfunction includes stroke, one of the leading causes of dysphagia. A study by Yang *et al.*<sup>[38]</sup> utilizing videofluoroscopic imaging to assess swallowing function in patients suffering from dysphagia due to stroke found an incidence of CP dysfunction to be 5.7% among first-time ischemic stroke patients. This incidence increased to 14.3% among those with infratentorial lesions and decreased to 2.8% among those with supratentorial lesions, suggesting focal lesions, primarily to the dorsal motor nucleus of the vagus, to be the primary culprit<sup>[38]</sup>. These lesions are typical of lateral medullary syndrome. Other causes include radiation for head and neck cancer, iatrogenic nerve injury, and oculopharyngeal muscular dystrophy (OPMD); many patients have idiopathic dysfunction. Current treatment consists of swallowing therapy, balloon dilatation, botulinum toxin injection, and surgical CP myotomy<sup>[39,40]</sup>. However, although effective, these are often temporary measures and have high rates of recurrence.

Current literature surrounding the use of muscle stem cells to repair cricopharyngeal dysfunction is sparse. A study published in 2014 by Périé *et al.*<sup>[41]</sup> described a clinical pilot study, whereby 12 patients with OPMD and indication for CP myotomy were injected with a median of 178 million myoblasts at various sites of pharyngeal constrictors following CP myotomy. Pharyngeal propulsion, as measured by videoendoscopy and videofluoroscopy remained largely unchanged at both 12 mo and 24 mo. UES function, defined by quality of UES opening and closure and pooling within the hypopharynx, improved in 6/12 patients at 24 mo using videoendoscopy but only in 2/12 patients at 24 mo using the more sensitive videofluoroscopy. Of note, investigators did not elaborate on the discrepancy between endoscopy *vs* fluoroscopy results and specify scoring mechanisms for assessing function *via* these two visualization modalities. Swallowing function as assessed using the Salassa score and McHorney score improved at both time points. Finally, average time to swallow 80 mL of water decreased from 23.7 s to 10.2 s<sup>[41]</sup>. It is important to highlight the lack of a control group within the study, since all 12 patients received myoblast injection following CP myotomy, making it difficult to compare to improvement had patients received CP myotomy alone. Furthermore, small scarifications were induced with a scalpel during surgery to induce muscle regeneration. The effects of these small injuries may or may not have affected the end outcomes of pharyngeal function. Lastly, the discrepancy between videoendoscopy and videofluoroscopy scores weaken the overall body of evidence. Further study with larger sample size would improve statistical power and warrants investigation following this proof of principle research.

---

## STEM CELL THERAPIES FOR DYSPHAGIA IN THE SETTING OF STROKE

---

Post-stroke dysphagia is a very common morbidity affecting up to 50% of cerebrovascular accident patients at 6 mo after the initial insult<sup>[42]</sup>. Etiology is multi-



factorial including deficits in mastication, oropharyngeal bolus propulsion due to muscle atrophy<sup>[43]</sup>, cricopharyngeal dysfunction, and perhaps most importantly, neurologic coordination of the precisely-timed swallow cascade. With the global neurologic function in mind, SC treatment for ischemic brain injury could have significant benefits on post-stroke swallowing. This is an active area of research and has primarily focused on neuron regeneration and structural improvement within the cortex. Multiple human clinical trials of SC transplantation have been conducted that provide evidence of safety, however the evidence of efficacy in these trials remains lacking<sup>[44-48]</sup>. Stem cell transplantation methods include direct injection into infarcted brain parenchyma, infusion through intravenous and intra-arterial vasculature, and infusion into cerebrospinal fluid through lumbar puncture. Implanted neural stem cells migrate to ischemic cortex and impart benefits including stimulating endogenous neurogenesis<sup>[49,50]</sup>, differentiating into functional neurons and astrocytes, inhibiting inflammation and glial scar formation<sup>[51,52]</sup>, and becoming neuroprotective if injected during acute ischemic injury<sup>[53]</sup>. Functional improvement has been limited to memory tests and improvement in skeletal muscle coordination within animals<sup>[54]</sup> and NIH Stroke Scale in humans, neither of which directly test dysphagia outcomes following neural stem cell transplantation<sup>[44-47]</sup>. While improvement of coordination is encouraging, extrapolation of gross movements of the extremities cannot be reliably transferred to improvements of fine deglutition muscle coordination and functional improvement.

---

## STEM CELL TREATMENT FOR ESOPHAGEAL REPAIR

---

Esophageal disorders represent a large proportion of cases underlying dysphagia. Etiologies are numerous, ranging from obstructive lesions such as strictures, webs, and tumors, to gastroesophageal reflux disease (GERD), eosinophilic esophagitis, achalasia, autoimmune causes such as Sjögren's syndrome, systemic lupus erythematosus, and systemic sclerosis as part of the CREST syndrome, medications, and neurological diseases<sup>[55,56]</sup>. As such, management is extremely varied based upon underlying pathophysiology and is beyond the scope of this review. It is worth noting the use of stem cells to manage esophageal dysphagia has not been studied extensively, perhaps due to difficulty in isolating targeted points of intervention given the broad range of conditions which can lead to esophageal dysfunction. In cases of autoimmune or neurologic etiologies for example, management of the primary disease likely represents a more effective strategy than stem cell-based therapies. For more primary causes of esophageal dysphagia, however, such as inherent dysmotility, achalasia, or even treatment refractory GERD, stem cell therapy may fill a niche yet to be occupied. Given the lack of literature surrounding this topic and the substantial decrease in quality of life for patients suffering from esophageal motility disorders, this may represent a highly beneficial avenue of study in the future.

---

## CHALLENGES

---

It is important to realize that despite many of these recent advancements in stem cell therapy for treatment of dysphagia (Table 1), the overwhelming majority of research remains in the basic and translational stage. The behavior of multipotent cells following injection into native tissue continues to be a point of discussion for researchers studying regenerative medicine. Although many of the above studies correlate persistence of cells as evidence of successful engraftment, studies in other organ systems such as cardiac tissue have found benefit despite cell elimination. Davani *et al*<sup>[57]</sup> and Iso *et al*<sup>[58]</sup> both demonstrated *in vivo* improvements in cardiac function following MSC injection, even without long-term engraftment and differentiation. When compared to injection with pure cardiac progenitor cells (CPCs), combination CPCs with MSCs actually improved cardiac ejection fraction more than CPC injection alone<sup>[59]</sup>. Particularly for the case of multipotent mesenchymal stem cells, it is thought apoptosis of these cells actually plays an important immunomodulatory role during tissue repair, exhibiting paracrine immunomodulation to promote tissue regeneration<sup>[60]</sup>. Our lack of understanding regarding the direct mechanisms whereby stem cells promote tissue healing represents a significant roadblock towards widespread stem cell therapy in the near future.

Moreover, it is difficult to translate structural outcome measurements such as increased tongue mass and reinnervation into actual functional improvement in

**Table 1** Recent advances in targeted stem cell therapy for oropharyngeal dysphagia

Ref.	Sample, n	Main findings
<b>Tongue dysfunction</b>		
Kim <i>et al</i> <sup>[20]</sup> (2003)	30 rats	Myoblast-containing collagen hydrogel group demonstrated statistically significant increase in tongue weight and desmin-positive cells at the surgery site
Bunaprasert <i>et al</i> <sup>[21]</sup> (2003)	60 rats	Myoblast-containing gel group showed interdigitating new muscle and neuroma-like fibers, with less scar tissue formation
Luxameechanporn <i>et al</i> <sup>[22]</sup> (2006)	12 rats	Six weeks post surgery, myoblasts persisted in all 12 rats, had limited migration, showed less scar contracture, and had increased muscle diameter
Kuhn <i>et al</i> <sup>[23]</sup> (2017)	16 mice	Human MDSCs injected into a hemiglossectomy model survived to the endpoint demonstrating 132% bioluminescence compared to 15% in control groups, and exhibited the greatest weight gain among all groups
Vahabzadeh <i>et al</i> <sup>[24]</sup> (2018)	18 athymic rats	Three weeks post MSC injection following partial glossectomy, rats which received MSC treatment were found to have reduced x-sectional scar burden and pathologic scores for inflammation and fibrosis
Plowman <i>et al</i> <sup>[25]</sup> (2014)	1 ovine	MDSCs survived 2 mo following bilateral hypoglossal nerve crush, and demonstrated increased muscle fiber diameter, 27% increase in maximal tongue force, and 54% increase in base of tongue pressure compared to pre cell injection
<b>Xerostomia</b>		
Lombaert <i>et al</i> <sup>[26]</sup> (2008)	13 mice	Salivary glands cultured <i>in vitro</i> then injected into irradiated glands demonstrated increased surface area of acinar cells and 42% increase in saliva production compared to untreated irradiated group
Nanduri <i>et al</i> <sup>[29]</sup> (2013)	15 mice	54.59% increase in salivary gland function following intraglandular injection of salisphere-derived c-kit positive cells in irradiated mice, compared to 21.5% in untreated mice
Ikeura <i>et al</i> <sup>[32]</sup> (2016)		Salivary gland basal and ductal cells isolated from submandibular glands were successfully cultured for over 80 passages while maintaining their proliferative ability and morphology
Dai <i>et al</i> <sup>[33]</sup> (2019)		ADSCs demonstrated the ability to differentiate into acinar-like epithelium capable of secreting $\alpha$ -amylase and expressing AQP-5
Grønhøj <i>et al</i> <sup>[35]</sup> (2018)	30 patients	Patients who received ADSC injection in submandibular glands demonstrated 50% improved unstimulated salivary flow rates at four months, markedly decreased symptom reports, increase in serous glands, and decreased fibrosis and fatty deposit on biopsies
<b>Cricopharyngeal dysfunction</b>		
Périé <i>et al</i> <sup>[41]</sup> (2014)	12 patients	6/12 patients by videoendoscopy but only 2/12 patients by videofluoroscopy demonstrated improved UES function following myoblast injection and CP myotomy. Swallowing function improved in all patients subjectively and mean swallowing time decreased in all patients from 23.7 s to 10.2 s

MDSC: Muscle-derived stem cell; MSC: Mesenchymal stem cell; ADSC: Adipose tissue-derived stem cells; UES: Upper esophageal sphincter; CP: Cricopharyngeus muscle.

swallowing. The few studies that do attempt to assess functional measurements, such as videofluoroscopy analysis, are limited by small sample sizes. A large portion of this challenge stems from the incredible complexity and coordination needed for swallowing. The interplay between different components of a swallow may mean recovery of one structure does not translate into recovery of swallowing function as a whole. It is reasonable to infer, particularly in cases of denervation injury, that physical therapy will remain an essential component of therapy to relearn swallowing and achieve coordination between a regenerated tissue and native tissue.

## CONCLUSION

Dysphagia is a highly prevalent yet challenging disorder to treat, particularly among patients who lack native, functional tissue upon which many conventional treatments exert their effects. In these patients, more novel therapies in the form of stem cell implantation may represent a new avenue to pursue to improve swallowing function. Initial research targeting different domains of swallowing have shown promise in restoring both structure and function. Large strides have been made in animal studies involving tongue dysfunction and xerostomia, with comparatively fewer studies about pharyngeal, esophageal, and neuromuscular etiologies of dysphagia. It is important to realize this field of research is still relatively young and far from becoming a part of standard clinical practice, with very few studies progressing into human clinical trials. Nevertheless, it represents an exciting new area of study with promising initial results

and is worth pursuing for its large potential to improve dysphagia in difficult to treat patients.

## REFERENCES

- 1 **Bhattacharyya N.** The prevalence of dysphagia among adults in the United States. *Otolaryngol Head Neck Surg* 2014; **151**: 765-769 [PMID: [25193514](#) DOI: [10.1177/0194599814549156](#)]
- 2 **Steele CM,** Greenwood C, Ens I, Robertson C, Seidman-Carlson R. Mealtime difficulties in a home for the aged: not just dysphagia. *Dysphagia* 1997; **12**: 43-50; discussion 51 [PMID: [8997832](#) DOI: [10.1007/pl00009517](#)]
- 3 **Langmore SE.** Efficacy of behavioral treatment for oropharyngeal dysphagia. *Dysphagia* 1995; **10**: 259-262 [PMID: [7493507](#) DOI: [10.1007/bf00431419](#)]
- 4 **Logemann JA.** Oropharyngeal dysphagia and nutritional management. *Curr Opin Clin Nutr Metab Care* 2007; **10**: 611-614 [PMID: [17693745](#) DOI: [10.1097/MCO.0b013e328285d872](#)]
- 5 **Robbins J,** Kays SA, Gangnon RE, Hind JA, Hewitt AL, Gentry LR, Taylor AJ. The effects of lingual exercise in stroke patients with dysphagia. *Arch Phys Med Rehabil* 2007; **88**: 150-158 [PMID: [17270511](#) DOI: [10.1016/j.apmr.2006.11.002](#)]
- 6 **Chhetri D,** Dewan K. *Dysphagia Evaluation and Management in Otolaryngology.* Elsevier; 2019 [DOI: [10.1016/C2017-0-01118-7](#)]
- 7 **Matsuo K,** Palmer JB. Anatomy and physiology of feeding and swallowing: normal and abnormal. *Phys Med Rehabil Clin N Am* 2008; **19**: 691-707, vii [PMID: [18940636](#) DOI: [10.1016/j.pmr.2008.06.001](#)]
- 8 **Speyer R,** Bajjens L, Heijnen M, Zwijnenberg I. Effects of therapy in oropharyngeal dysphagia by speech and language therapists: a systematic review. *Dysphagia* 2010; **25**: 40-65 [PMID: [19760458](#) DOI: [10.1007/s00455-009-9239-7](#)]
- 9 **Pitts T.** Airway protective mechanisms. *Lung* 2014; **192**: 27-31 [PMID: [24297325](#) DOI: [10.1007/s00408-013-9540-y](#)]
- 10 **Halum SL,** Naidu M, Delo DM, Atala A, Hingtgen CM. Injection of autologous muscle stem cells (myoblasts) for the treatment of vocal fold paralysis: a pilot study. *Laryngoscope* 2007; **117**: 917-922 [PMID: [17473696](#) DOI: [10.1097/MLG.0b013e31803e8c8d](#)]
- 11 **Halum SL,** Hiatt KK, Naidu M, Sufyan AS, Clapp DW. Optimization of autologous muscle stem cell survival in the denervated hemilarynx. *Laryngoscope* 2008; **118**: 1308-1312 [PMID: [18401272](#) DOI: [10.1097/MLG.0b013e31816c438e](#)]
- 12 **Halum SL,** McRae B, Bijangi-Vishehsaraei K, Hiatt K. Neurotrophic factor-secreting autologous muscle stem cell therapy for the treatment of laryngeal denervation injury. *Laryngoscope* 2012; **122**: 2482-2496 [PMID: [22965802](#) DOI: [10.1002/lary.23519](#)]
- 13 **Paniello RC,** Brookes S, Bhatt NK, Bijangi-Vishehsaraei K, Zhang H, Halum S. Improved adductor function after canine recurrent laryngeal nerve injury and repair using muscle progenitor cells. *Laryngoscope* 2018; **128**: E241-E246 [PMID: [29219186](#) DOI: [10.1002/lary.26992](#)]
- 14 **Son YR,** Choi KH, Kim TG. Dysphagia in tongue cancer patients. *Ann Rehabil Med* 2015; **39**: 210-217 [PMID: [25932417](#) DOI: [10.5535/arm.2015.39.2.210](#)]
- 15 **Pauloski BR,** Logemann JA, Rademaker AW, McConnel FM, Heiser MA, Cardinale S, Shedd D, Lewin J, Baker SR, Graner D. Speech and swallowing function after anterior tongue and floor of mouth resection with distal flap reconstruction. *J Speech Hear Res* 1993; **36**: 267-276 [PMID: [8487519](#) DOI: [10.1044/jshr.3602.267](#)]
- 16 **Zuydam AC,** Lowe D, Brown JS, Vaughan ED, Rogers SN. Predictors of speech and swallowing function following primary surgery for oral and oropharyngeal cancer. *Clin Otolaryngol* 2005; **30**: 428-437 [PMID: [16232247](#) DOI: [10.1111/j.1365-2273.2005.01061.x](#)]
- 17 **Lin DT,** Yarlagadda BB, Sethi RK, Feng AL, Shnyder Y, Ledgerwood LG, Diaz JA, Sinha P, Hanasono MM, Yu P, Skoracki RJ, Lian TS, Patel UA, Leibowitz J, Purdy N, Starmer H, Richmon JD. Long-term Functional Outcomes of Total Glossectomy With or Without Total Laryngectomy. *JAMA Otolaryngol Head Neck Surg* 2015; **141**: 797-803 [PMID: [26291031](#) DOI: [10.1001/jamaoto.2015.1463](#)]
- 18 **Dziegielewski PT,** Ho ML, Rieger J, Singh P, Langille M, Harris JR, Seikaly H. Total glossectomy with laryngeal preservation and free flap reconstruction: objective functional outcomes and systematic review of the literature. *Laryngoscope* 2013; **123**: 140-145 [PMID: [22952109](#) DOI: [10.1002/lary.23505](#)]
- 19 **Rihani J,** Lee MR, Lee T, Ducic Y. Flap selection and functional outcomes in total glossectomy with laryngeal preservation. *Otolaryngol Head Neck Surg* 2013; **149**: 547-553 [PMID: [23884285](#) DOI: [10.1177/0194599813498063](#)]
- 20 **Kim J,** Hadlock T, Cheney M, Varvares M, Marler J. Muscle tissue engineering for partial glossectomy defects. *Arch Facial Plast Surg* 2003; **5**: 403-407 [PMID: [12975138](#) DOI: [10.1001/archfaci.5.5.403](#)]
- 21 **Bunaprasert T,** Hadlock T, Marler J, Kobler J, Cowan D, Faquin W, Varvares M. Tissue engineered muscle implantation for tongue reconstruction: a preliminary report. *Laryngoscope* 2003; **113**: 1792-1797 [PMID: [14520108](#) DOI: [10.1097/00005537-200310000-00025](#)]
- 22 **Luxamechanporn T,** Hadlock T, Shyu J, Cowan D, Faquin W, Varvares M. Successful myoblast transplantation in rat tongue reconstruction. *Head Neck* 2006; **28**: 517-524 [PMID: [16619280](#) DOI: [10.1002/hed.20325](#)]
- 23 **Kuhn MA,** Black AB, Siddiqui MT, Nolta JA, Belafsky PC. Novel murine xenograft model for the evaluation of stem cell therapy for profound dysphagia. *Laryngoscope* 2017; **127**: E359-E363 [PMID: [28543406](#) DOI: [10.1002/lary.26666](#)]
- 24 **Vahabzadeh-Hagh AM,** Goel AN, Frederick JW, Berke GS, Long JL. Transplanted human multipotent stromal cells reduce acute tongue fibrosis in rats. *Laryngoscope Investig Otolaryngol* 2018; **3**: 450-456 [PMID: [30599029](#) DOI: [10.1002/lio2.202](#)]
- 25 **Plowman EK,** Bijangi-Vishehsaraei K, Halum S, Cates D, Hanenberg H, Domer AS, Nolta JA, Belafsky PC.

- Autologous myoblasts attenuate atrophy and improve tongue force in a denervated tongue model: a pilot study. *Laryngoscope* 2014; **124**: E20-E26 [PMID: 23929623 DOI: 10.1002/lary.24352]
- 26 **Pedersen AM**, Bardow A, Jensen SB, Nauntofte B. Saliva and gastrointestinal functions of taste, mastication, swallowing and digestion. *Oral Dis* 2002; **8**: 117-129 [PMID: 12108756 DOI: 10.1034/j.1601-0825.2002.02851.x]
- 27 **Villa A**, Connell CL, Abati S. Diagnosis and management of xerostomia and hyposalivation. *Ther Clin Risk Manag* 2015; **11**: 45-51 [PMID: 25653532 DOI: 10.2147/TCRM.S76282]
- 28 **Lombaert IM**, Brunsting JF, Wierenga PK, Faber H, Stokman MA, Kok T, Visser WH, Kampinga HH, de Haan G, Coppes RP. Rescue of salivary gland function after stem cell transplantation in irradiated glands. *PLoS One* 2008; **3**: e2063 [PMID: 18446241 DOI: 10.1371/journal.pone.0002063]
- 29 **Nanduri LS**, Lombaert IM, van der Zwaag M, Faber H, Brunsting JF, van Os RP, Coppes RP. Salisphere derived c-Kit+ cell transplantation restores tissue homeostasis in irradiated salivary gland. *Radiother Oncol* 2013; **108**: 458-463 [PMID: 23769181 DOI: 10.1016/j.radonc.2013.05.020]
- 30 **Min S**, Song EC, Oyelakin A, Gluck C, Smalley K, Romano RA. Functional characterization and genomic studies of a novel murine submandibular gland epithelial cell line. *PLoS One* 2018; **13**: e0192775 [PMID: 29462154 DOI: 10.1371/journal.pone.0192775]
- 31 **Coppes RP**, Stokman MA. Stem cells and the repair of radiation-induced salivary gland damage. *Oral Dis* 2011; **17**: 143-153 [PMID: 20796229 DOI: 10.1111/j.1601-0825.2010.01723.x]
- 32 **Ikeura K**, Kawakita T, Tsunoda K, Nakagawa T, Tsubota K. Characterization of Long-Term Cultured Murine Submandibular Gland Epithelial Cells. *PLoS One* 2016; **11**: e0147407 [PMID: 26800086 DOI: 10.1371/journal.pone.0147407]
- 33 **Dai TQ**, Zhang LL, An Y, Xu FF, An R, Xu HY, Liu YP, Liu B. In vitro transdifferentiation of adipose tissue-derived stem cells into salivary gland acinar-like cells. *Am J Transl Res* 2019; **11**: 2908-2924 [PMID: 31217863]
- 34 **Fu Y**, Karbaat L, Wu L, Leijten J, Both SK, Karperien M. Trophic Effects of Mesenchymal Stem Cells in Tissue Regeneration. *Tissue Eng Part B Rev* 2017; **23**: 515-528 [PMID: 28490258 DOI: 10.1089/ten.TEB.2016.0365]
- 35 **Grønhoj C**, Jensen DH, Vester-Glowinski P, Jensen SB, Bardow A, Oliveri RS, Fog LM, Specht L, Thomsen C, Darkner S, Jensen M, Müller V, Kiss K, Agander T, Andersen E, Fischer-Nielsen A, von Buchwald C. Safety and Efficacy of Mesenchymal Stem Cells for Radiation-Induced Xerostomia: A Randomized, Placebo-Controlled Phase 1/2 Trial (MESRIX). *Int J Radiat Oncol Biol Phys* 2018; **101**: 581-592 [PMID: 29678523 DOI: 10.1016/j.ijrobp.2018.02.034]
- 36 **Rigshospitalet, Denmark**. Long-term Follow-up Study of Mesenchymal Stem Cells for Radiation-induced Xerostomia (MESRIX). In: ClinicalTrials.gov [Internet]. Bethesda (MD): National Library of Medicine (US). Available from: <https://ClinicalTrials.gov/show/NCT03876197> NLM Identifier: NCT03876197
- 37 **Rigshospitalet, Denmark**. Allogeneic Mesenchymal Stem Cells for Radiation-induced Hyposalivation and Xerostomia/Dry Mouth. In: ClinicalTrials.gov [Internet]. Bethesda (MD): National Library of Medicine (US). Available from: <https://ClinicalTrials.gov/show/NCT03874572> NLM Identifier: NCT03874572
- 38 **Yang H**, Yi Y, Han Y, Kim HJ. Characteristics of Cricopharyngeal Dysphagia After Ischemic Stroke. *Ann Rehabil Med* 2018; **42**: 204-212 [PMID: 29765873 DOI: 10.5535/arm.2018.42.2.204]
- 39 **Bergeron JL**, Chhetri DK. Indications and outcomes of endoscopic CO2 laser cricopharyngeal myotomy. *Laryngoscope* 2014; **124**: 950-954 [PMID: 24114581 DOI: 10.1002/lary.24415]
- 40 **Coiffier L**, Périé S, Laforêt P, Eymard B, St Guily JL. Long-term results of cricopharyngeal myotomy in oculopharyngeal muscular dystrophy. *Otolaryngol Head Neck Surg* 2006; **135**: 218-222 [PMID: 16890071 DOI: 10.1016/j.otohns.2006.03.015]
- 41 **Périé S**, Trollet C, Mouly V, Vanneaux V, Mamchaoui K, Bouazza B, Marolleau JP, Laforêt P, Chapon F, Eymard B, Butler-Browne G, Larghero J, St Guily JL. Autologous myoblast transplantation for oculopharyngeal muscular dystrophy: a phase I/IIa clinical study. *Mol Ther* 2014; **22**: 219-225 [PMID: 23831596 DOI: 10.1038/mt.2013.155]
- 42 **Mann G**, Hankey GJ, Cameron D. Swallowing function after stroke: prognosis and prognostic factors at 6 months. *Stroke* 1999; **30**: 744-748 [PMID: 10187872 DOI: 10.1161/01.str.30.4.744]
- 43 **Schimmel M**, Ono T, Lam OL, Müller F. Oro-facial impairment in stroke patients. *J Oral Rehabil* 2017; **44**: 313-326 [PMID: 28128465 DOI: 10.1111/joor.12486]
- 44 **Steinberg GK**, Kondziolka D, Wechsler LR, Lunsford LD, Coburn ML, Billigen JB, Kim AS, Johnson JN, Bates D, King B, Case C, McGrogan M, Yankee EW, Schwartz NE. Clinical Outcomes of Transplanted Modified Bone Marrow-Derived Mesenchymal Stem Cells in Stroke: A Phase 1/2a Study. *Stroke* 2016; **47**: 1817-1824 [PMID: 27256670 DOI: 10.1161/STROKEAHA.116.012995]
- 45 **Kalladka D**, Sinden J, Pollock K, Haig C, McLean J, Smith W, McConnachie A, Santosh C, Bath PM, Dunn L, Muir KW. Human neural stem cells in patients with chronic ischaemic stroke (PISCES): a phase 1, first-in-man study. *Lancet* 2016; **388**: 787-796 [PMID: 27497862 DOI: 10.1016/S0140-6736(16)30513-X]
- 46 **Prasad K**, Sharma A, Garg A, Mohanty S, Bhatnagar S, Johri S, Singh KK, Nair V, Sarkar RS, Gorthi SP, Hassan KM, Prabhakar S, Marwaha N, Khandelwal N, Misra UK, Kalita J, Nityanand S; InveST Study Group. Intravenous autologous bone marrow mononuclear stem cell therapy for ischemic stroke: a multicentric, randomized trial. *Stroke* 2014; **45**: 3618-3624 [PMID: 25378424 DOI: 10.1161/STROKEAHA.114.007028]
- 47 **Hess DC**, Wechsler LR, Clark WM, Savitz SI, Ford GA, Chiu D, Yavagal DR, Uchino K, Liebeskind DS, Auchus AP, Sen S, Sila CA, Vest JD, Mays RW. Safety and efficacy of multipotent adult progenitor cells in acute ischaemic stroke (MASTERS): a randomised, double-blind, placebo-controlled, phase 2 trial. *Lancet Neurol* 2017; **16**: 360-368 [PMID: 28320635 DOI: 10.1016/S1474-4422(17)30046-7]
- 48 **Nagpal A**, Choy FC, Howell S, Hillier S, Chan F, Hamilton-Bruce MA, Koblar SA. Safety and effectiveness of stem cell therapies in early-phase clinical trials in stroke: a systematic review and meta-analysis. *Stem Cell Res Ther* 2017; **8**: 191 [PMID: 28854961 DOI: 10.1186/s13287-017-0643-x]
- 49 **Cheng Y**, Zhang J, Deng L, Johnson NR, Yu X, Zhang N, Lou T, Zhang Y, Wei X, Chen Z, He S, Li X, Xiao J. Intravenously delivered neural stem cells migrate into ischemic brain, differentiate and improve functional recovery after transient ischemic stroke in adult rats. *Int J Clin Exp Pathol* 2015; **8**: 2928-2936

- [PMID: 26045801]
- 50 **Bernstock JD**, Peruzzotti-Jametti L, Ye D, Gessler FA, Maric D, Vicario N, Lee YJ, Pluchino S, Hallenbeck JM. Neural stem cell transplantation in ischemic stroke: A role for preconditioning and cellular engineering. *J Cereb Blood Flow Metab* 2017; **37**: 2314-2319 [PMID: 28303738 DOI: 10.1177/0271678X17700432]
  - 51 **Bacigaluppi M**, Russo GL, Peruzzotti-Jametti L, Rossi S, Sandrone S, Butti E, De Ceglia R, Bergamaschi A, Motta C, Gallizioli M, Studer V, Colombo E, Farina C, Comi G, Politi LS, Muzio L, Villani C, Invernizzi RW, Hermann DM, Centonze D, Martino G. Neural Stem Cell Transplantation Induces Stroke Recovery by Upregulating Glutamate Transporter GLT-1 in Astrocytes. *J Neurosci* 2016; **36**: 10529-10544 [PMID: 27733606 DOI: 10.1523/JNEUROSCI.1643-16.2016]
  - 52 **Hou B**, Ma J, Guo X, Ju F, Gao J, Wang D, Liu J, Li X, Zhang S, Ren H. Exogenous Neural Stem Cells Transplantation as a Potential Therapy for Photothrombotic Ischemia Stroke in Kunming Mice Model. *Mol Neurobiol* 2017; **54**: 1254-1262 [PMID: 26820680 DOI: 10.1007/s12035-016-9740-6]
  - 53 **Watanabe M**, Yavagal DR. Intra-arterial delivery of mesenchymal stem cells. *Brain Circ* 2016; **2**: 114-117 [PMID: 30276284 DOI: 10.4103/2394-8108.192522]
  - 54 **Hosseini SM**, Farahmandnia M, Razi Z, Delavari S, Shakibajahromi B, Sarvestani FS, Kazemi S, Semsar M. Combination cell therapy with mesenchymal stem cells and neural stem cells for brain stroke in rats. *Int J Stem Cells* 2015; **8**: 99-105 [PMID: 26019759 DOI: 10.15283/ijsc.2015.8.1.99]
  - 55 **Koch KL**, Bitar KN, Fortunato JE. Tissue engineering for neuromuscular disorders of the gastrointestinal tract. *World J Gastroenterol* 2012; **18**: 6918-6925 [PMID: 23322989 DOI: 10.3748/wjg.v18.i47.6918]
  - 56 **Philpott H**, Garg M, Tomic D, Balasubramanian S, Sweis R. Dysphagia: Thinking outside the box. *World J Gastroenterol* 2017; **23**: 6942-6951 [PMID: 29097867 DOI: 10.3748/wjg.v23.i38.6942]
  - 57 **Davani S**, Marandin A, Mersin N, Royer B, Kantelip B, Hervé P, Etievent JP, Kantelip JP. Mesenchymal progenitor cells differentiate into an endothelial phenotype, enhance vascular density, and improve heart function in a rat cellular cardiomyoplasty model. *Circulation* 2003; **108** Suppl 1: II253-II258 [PMID: 12970242 DOI: 10.1161/01.cir.0000089186.09692.fa]
  - 58 **Iso Y**, Spees JL, Serrano C, Bakondi B, Pochampally R, Song YH, Sobel BE, Delafontaine P, Prockop DJ. Multipotent human stromal cells improve cardiac function after myocardial infarction in mice without long-term engraftment. *Biochem Biophys Res Commun* 2007; **354**: 700-706 [PMID: 17257581 DOI: 10.1016/j.bbrc.2007.01.045]
  - 59 **Marbán E**, Malliaras K. Boot camp for mesenchymal stem cells. *J Am Coll Cardiol* 2010; **56**: 735-737 [PMID: 20723803 DOI: 10.1016/j.jacc.2010.02.064]
  - 60 **Galleu A**, Riffo-Vasquez Y, Trento C, Lomas C, Dolcetti L, Cheung TS, von Bonin M, Barbieri L, Halai K, Ward S, Weng L, Chakraverty R, Lombardi G, Watt FM, Orchard K, Marks DI, Apperley J, Bornhauser M, Walczak H, Bennett C, Dazzi F. Apoptosis in mesenchymal stromal cells induces *in vivo* recipient-mediated immunomodulation. *Sci Transl Med* 2017; **9** [PMID: 29141887 DOI: 10.1126/scitranslmed.aam7828]





Published by **Baishideng Publishing Group Inc**  
7041 Koll Center Parkway, Suite 160, Pleasanton, CA 94566, USA  
**Telephone:** +1-925-3991568  
**E-mail:** [bpgoffice@wjgnet.com](mailto:bpgoffice@wjgnet.com)  
**Help Desk:** <https://www.f6publishing.com/helpdesk>  
<https://www.wjgnet.com>

