

UCLA

UCLA Previously Published Works

Title

New devices and technology in interventional cardiology

Permalink

<https://escholarship.org/uc/item/6z06k7md>

Journal

Journal of Cardiology, 65(1)

ISSN

0914-5087

Authors

Tobis, Jonathan Marvin

Abudayyeh, Islam

Publication Date

2015

DOI

10.1016/j.jjcc.2014.08.001

Copyright Information

This work is made available under the terms of a Creative Commons Attribution License, available at <https://creativecommons.org/licenses/by/4.0/>

Peer reviewed



Review

New devices and technology in interventional cardiology

Jonathan Marvin Tobis (MD)^{a,*}, Islam Abudayyeh (MD, MPH)^b^a UCLA David Geffen School of Medicine, Division of Cardiology, Los Angeles, CA, USA^b Division of Cardiology, Interventional Cardiology, Loma Linda University Health, Loma Linda, CA, USA

ARTICLE INFO

Article history:

Received 6 August 2014

Accepted 7 August 2014

Available online 16 September 2014

Keywords:

Interventional cardiology

Catheter-based therapy

Update in cardiology

ABSTRACT

There have been substantial improvements made in the tools and techniques used since the advent of percutaneous coronary intervention. What was primarily developed as a treatment of coronary artery disease is now used to address a variety of structural heart disease problems. The outcomes have been remarkably successful with relatively low complication rates that rival the results of open-heart surgery.

This article will review some of the new devices available for management of structural cardiac conditions including congenital defects and acquired valvular abnormalities. Transcatheter treatment offers advantages over surgical intervention in recovery time, improved patient satisfaction, lower procedural risk, and avoidance of cardio-pulmonary bypass especially in high-risk patients. We will discuss different medical conditions and introduce the devices used to treat these conditions. Each device or technique has benefits and risks, and familiarity with the devices along with patient selection will best optimize the outcome.

© 2014 Japanese College of Cardiology. Published by Elsevier Ltd. All rights reserved.

Contents

Introduction	5
Atrial septal defects	6
Patent foramen ovale	6
Patent ductus arteriosus	7
Ventricular septal defects	7
Aortic stenosis	8
Mitral stenosis	10
Mitral regurgitation	11
Pulmonic valve stenosis and regurgitation	12
Paravalvular leaks	12
Coarctation of the aorta	13
Peripheral arteriovenous fistula	13
Coronary artery fistula	13
Left atrial appendage occlusion	14
Stem cell therapy	14
References	15

Introduction

Significant improvements have been made in the tools and techniques used since the advent of percutaneous coronary intervention. What was primarily developed as a treatment of

coronary artery disease has become adapted to address the problems associated with structural heart disease. The outcomes have been remarkably successful with relatively low complication rates that rival the results of open-heart surgery [1]. There has been a continuous trend to use endovascular techniques for management of most cardiac conditions while simultaneously minimizing open surgical interventions.

This article will review some of the new devices available for management of a variety of structural cardiac conditions such as

* Corresponding author at: 10833 Le Conte Avenue, Factor Building, Room B-976, Los Angeles, CA 90095, USA. Tel.: +1 310 794 4797; fax: +1 310 267 0384.
E-mail address: jtobis@mednet.ucla.edu (J.M. Tobis).

adults with congenital defects as well as acquired valvular abnormalities. Transcatheter treatment offers advantages over surgical intervention in recovery time, improved patient satisfaction, lower procedural risk, and avoidance of cardio-pulmonary bypass especially in high-risk patients.

Atrial septal defects

An atrial septal defect (ASD) is the second most common congenital heart defect occurring in 8 of 1000 live births. Small defects less than 1 cm may be discovered without any clinical symptoms since they do not produce significant shunting of blood and thus do not require closure. Larger defects with a Qp:Qs ratio greater than 1:1.4 may produce hemodynamic consequences consisting of atrial arrhythmias or right heart failure and should be closed. Only a secundum ASD may be closed by transcatheter devices rather than open-chest surgery, provided the anatomy is amenable with sufficient rims to hold a device. The most common device is the Amplatzer septal occluder (ASO, St. Jude Medical, St. Paul, MN, USA) (Fig. 1). The device is composed of a self-expanding double disk with a short connecting waist that acts to center the device within the defect. The device is made from 0.004 to 0.008-inch nitinol wire mesh that covers a polyester material to reduce blood flow through the device. Fibrous tissue ingrowth occurs in a few months to provide a biologic seal. The size of the device is selected by measuring the diameter of the septal defect, usually with an inflated sizing balloon. The Amplatzer device is available in sizes of 4 mm to 38 mm in the USA and up to 40 mm in the rest of the world. Depending on the size of the device chosen, the overhang for the atrial disks ranges from 6 to 8 mm. The device is easy to deploy except for large ASDs and has proven to be reliable with a low risk of complications or failure of implantation [2]. It is estimated that there have been over 200,000 percutaneous ASD implants worldwide. An ASD may also exhibit multiple fenestrations in the inter-atrial septum, which are too small to accommodate an ASO waist. These may require the use of the Amplatzer Multi-Fenestrated Septal Occluder or cribriform device (Fig. 2). Unlike the ASO, this device has matched atrial disk sizes to ensure maximal coverage of surrounding fenestrations, and a narrow waist to pass through the smaller defects. Two or three devices can be implanted close to each other to cover a wider area or an aneurysmal fenestrated septum. Long-term outcomes and facility of deployment is similar to the ASO. Complications related to the ASO range from 0.6 to 1%, with the worst complication, erosion, occurring in approximately 0.1% [3]. Although rare, allergy to nickel may cause complications including chest pain due to inflammation that requires surgical extraction of the device in about 0.2% [4].

A second device commonly used to close ASDs is the Gore-Helix septal occluder (Gore & Associates, Inc., Flagstaff, AZ, USA) (Fig. 3). The device is composed of a nitinol wire on an ePTFE (expanded




Fig. 1. Amplatzer septal occluder and delivery cable.



Fig. 2. Amplatzer cribriform device.

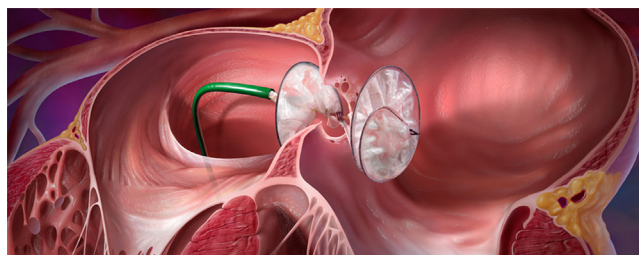


Fig. 3. Gore-Helix device.

polytetrafluoroethylene) patch creating a helix with 1.5 turns in the left atrium and 1.5 turns on the right side. The device is not self-centering so a device to defect diameter size of 2:1 is required so that an edge cannot prolapse through the ASD. The Gore-Helix occluder is a good option for smaller defects less than 13 mm in diameter. No erosions or allergic reactions to nickel have been documented with this device. There is a higher likelihood of wire fracture but this has not translated to an adverse clinical outcome or displacement. The CardioSeal and STARflex devices (NMT Medical, Inc., Boston, MA, USA) were previously available for ASD closures. Due to a high frequency of residual shunts, and lower procedural success rates of 85%, the devices are no longer available on the market worldwide [5].

Gore & Associates is currently evaluating a new septal occluder (Fig. 4). This device is composed of a 5-wire support frame covered with ePTFE. The device is intended to conform better to septal anatomy while maintaining stronger radial compression and reduced shunting compared with their previous design. All of the ASD devices are retrievable before release.

Patent foramen ovale

A patent foramen ovale (PFO) is a congenital inter-atrial pathway that persists in 20–30% of the population. In utero, the foramen ovale permits shunting of oxygenated placental blood to



Fig. 4. Gore septal occluder (not yet approved).

bypass the non-functional fetal lungs, enter the left cardiac side and perfuse the critical organs [6]. Placental blood only has an oxygen saturation of 67% and would not be sufficient to sustain organogenesis if it lost more oxygen passing through the non-aerated fetal lung. This mechanism is so important that it is preserved throughout evolution in all mammals. After birth, venous return no longer provides oxygenated blood and the septum primum and septum secundum fuse to become the foramen ovale. Should fusion not occur, the foramen ovale remains patent but is typically asymptomatic. In a minority of patients, symptoms do occur as there is an association of PFO with cryptogenic stroke, migraines with aura, orthodeoxia platypnea, decompression illness, high altitude pulmonary edema, and exacerbation of obstructive sleep apnea [7]. The ASO and Gore-Helex devices discussed above for closure of an ASD are also used for PFOs with similar success and low complication rates. These devices, however, are not approved by the US Food and Drug Administration (FDA) for treatment of PFOs and their use is considered off-label in the USA. An Amplatzer device designed specifically for PFO anatomy is available in the rest of the world.

Patent ductus arteriosus

The patent ductus arteriosus (PDA) is a second fetal shunt that carries oxygenated placental blood from the pulmonary artery to the aorta, bypassing the lungs in utero. A PDA is less likely to be present in adults since most PDA shunts are diagnosed in childhood and treated. A delay in diagnosis can have significant hemodynamic implications including pulmonary hypertension and Eisenmenger's syndrome with reversal of left to right shunting. If pulmonary artery pressure is sufficiently high, closure of a large PDA later in life may be contra-indicated since it acts as a pop-off valve to prevent right heart failure. Other possible sequelae of a PDA include endocarditis, high output heart failure, and arrhythmias. Prior to closure of a PDA, a full hemodynamic study should be performed to judge suitability of closure and to measure the duct length and diameter by bi-plane angiography during opacification of the duct. A calcified PDA can be difficult to close surgically as the calcified vessel may fracture causing catastrophic bleeding. Transcatheter closure can be accomplished using embolization coils such as Gianturco coils (Fig. 5), the Amplatzer duct occluder (Fig. 6), or more recently, the Nit-Occlud device (Fig. 7) (pfm medical ag, Köln, Germany). To deliver the device to the appropriate location in the ductus, the operator advances a wire from the arterial side and enters the PDA through the aorta. The wire is then snared in the pulmonary artery and externalized creating a rail. The chosen device is then advanced across the PDA from the pulmonary artery side over the wire to deploy the occluder device. Multiple coils are available on the market including detachable ones that allow the operator to assess position and stability before releasing the coil from the delivery



Fig. 5. Embolization coils (expanded).




Fig. 6. Amplatzer duct occluder.




Fig. 7. The Nit-Occlud device in deployed configuration.

cable. Two versions of the Amplatzer duct occluder (ADO) exist. The ADO-I has a conical shape with a retention skirt on the arterial side to secure the device. It has a relatively simple deployment technique and high success rate with over 95% of treated patients achieving ductal closure at 6 months [8]. Sizing selection requires that the smaller end of the device be at least 2 mm larger than the narrowest portion of the PDA measured by angiography. The ADO-II device is a compliant dual articulating disc device with a symmetrical design. It allows the operator to achieve closure from either the aortic or pulmonary artery side as both sides have a retention disc. More attention has to be paid to the waist length on this device compared to the duct to allow the distal disc to expand appropriately. The Nit-Occlud PDA occlusion device is a relatively new device with an atraumatic biconical configuration and variable stiffness. The larger more stiff conical component conforms to the aortic side forming a plug with the rest of the coil winding inside the ductal tunnel. A small coil on the pulmonary side anchors the device in place.

Ventricular septal defects

A ventricular septal defect (VSD) is an incomplete fusion of the inter-ventricular wall. It can exist in the muscular ventricular septum, the membranous portion close to the atrioventricular node, sub-arterial or supracristal, or as an inlet type VSD [9]. The most common is the muscular VSD, which, if small, may close spontaneously in early childhood. Membranous VSDs are more common in older children and adults since they do not typically close spontaneously. The defects that may be managed by transcatheter techniques are the perimembranous and muscular VSDs. VSDs that occur post-myocardial infarct with rupture of the ventricular septum are a special category associated with a high



Fig. 8. Amplatzer muscular VSD occluder.




Fig. 9. Amplatzer muscular VSD post-infarct occluder.



Fig. 10. Amplatzer membranous VSD occluder. The device is eccentric with a shorter disc overhang on the valve side and longer ventricular side. The device is sized according to the waist (A). The right ventricular disc (B) is symmetric. A marker at the distal or lower part of image of the left sided disc (C) identifies the orientation angiographically.

mortality but may be amenable to percutaneous closure in selected patients. VSDs can be associated with significant sequelae including heart failure, pulmonary hypertension, conduction abnormalities, and valvular dysfunction [10]. Transcatheter closure of a VSD can be technically challenging but may produce satisfactory long-term outcomes similar to surgery [11,12].

Options for closure include using the Amplatzer series of VSD devices and the Nit-Occlud device. The Amplatzer muscular VSD occluder is a double-disk nitinol wire mesh with polyester patch design similar to the ASD occluder, except that it is designed to fit the thicker muscular septum. There is a thinner membranous VSD device and a post-myocardial infarction device with a longer waist to accommodate damaged muscular tissue. The muscular occluder has symmetric right and left ventricular disks 8 mm larger than the waist. The size of the device is determined by using a sizing balloon to measure the width of the VSD (Fig. 8). The post-infarct version of the device has a 10-mm long waist to accommodate infarcted

myocardial tissue at the rims (Fig. 9). The membranous VSD occluder is also a self-expanding, self-centering retrievable double-disk device with a shorter waist. The device is eccentric with a left-side aortic overhang of 0.5 mm and a left side ventricular overhang of 5.5 mm. The ventricular end has a radio-opaque marker to help orient the longer component of the disk towards the ventricular apex. This allows the device to be implanted without impinging on the left heart valves (Fig. 10). To deploy the device, the flat part of the pusher catheter is aligned with the flat part of the delivery catheter end-screw. A plastic vice is attached to the end of the delivery catheter to maintain the orientation of the device before delivery. Care must be taken when implanting a device across a perimembranous VSD to not cause disruption of a nearby valve or atrioventricular block. A version of the Nit-Occlud device is available for perimembranous VSD closure. This device contains polyester fibers to improve closure. The device is well suited for aneurysmal perimembranous VSDs, and there are no reports of permanent atrioventricular-block [13]. To size the Nit-Occlud, a coil with a distal diameter at least twice the minimal diameter of the VSD on the right ventricular side and 1 to 2 mm greater than the diameter of the VSD at the left ventricular side should be selected.

Aortic stenosis

Transcatheter aortic valve replacement (TAVR) is rapidly gaining in popularity. Degenerative aortic stenosis is a progressive disease with high-mortality (Chart 1). Repair of the condition either by surgical aortic valve replacement (SAVR) or TAVR changes the natural course substantially with 5 implants needed to prevent 1 death in a high-risk population [14]. TAVR has

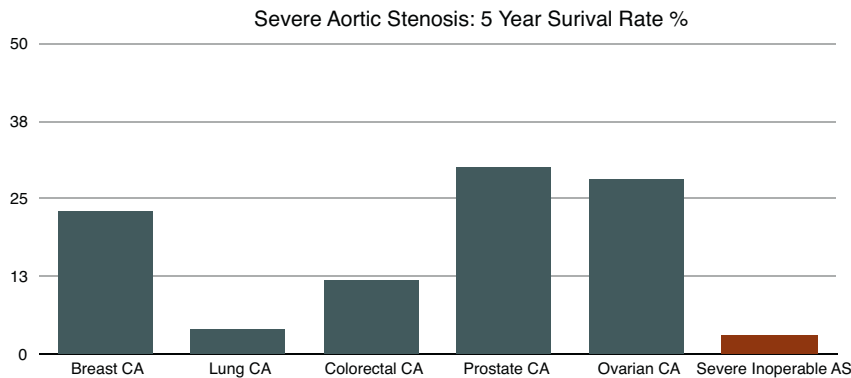


Chart 1. Average adjusted 5 year survival using constant hazard ratio. National Institute of Health 2010. CA: Metastatic Cancer Incidence. No permission necessary (public domain data). Source: National Institute of Health. National Cancer Institute. Surveillance Epidemiology and End Results. Cancer Stat Fact Sheets. 2010. Edwards Lifesciences LLC – Data on file.

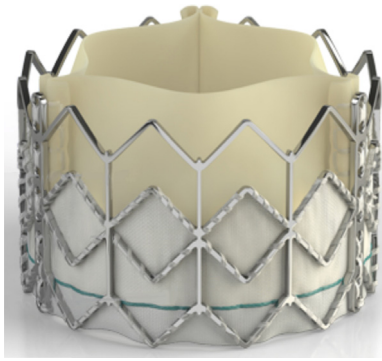


Fig. 11. Edwards Sapien valve.

substantially changed the landscape for high-risk patients or those who do not qualify for SAVR and will likely become more prevalent as the indications for the procedure expand. Currently, there are 4 series of devices available commercially or in active trials. The Edwards Sapien valve (Edwards Lifesciences, Irvine, CA, USA) was studied in the PARTNER trial. This randomized trial demonstrated significant improvement in New York Heart Association (NYHA) scores and 2-year survival (70%) compared to medical therapy (50%) in non-surgical patients (cohort B). In patients who were at high-risk but were acceptable surgical candidates, there were equivalent long-term outcomes to open surgical intervention at 1 year (cohort A). The original Sapien valve was composed of three leaflets made from bovine pericardial tissue sutured together to a polyethylene terephthalate (PET) skirt on a balloon expandable stainless steel stent frame (Fig. 11). It was available in one of 2 diameter sizes: 23 mm or 26 mm. The valve was crimped on a balloon delivery catheter and advanced retrograde through the femoral artery (Fig. 12). Alternatively, the valve could be delivered

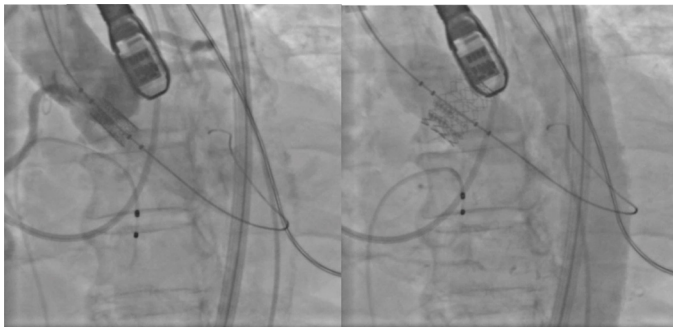

Fig. 12. Edwards Sapien valve crimped on the delivery catheter on left and post-balloon deployment with rapid pacing on the right.

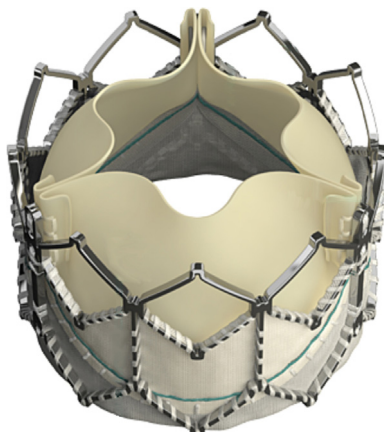


Fig. 13. Edwards Sapien XT valve.

via a trans-apical access through a mini-thoracotomy in the lateral chest or through the distal ascending aorta via a midline mini-thoracotomy.

The second generation Edwards valve, the Sapien XT, is a bovine pericardial tissue valve as well, but is sutured on a cobalt chromium stent scaffold (Fig. 13). This stent construction allows the valve to be crimped to a lower profile while maintaining structural and radial support once expanded. The NovaFlex+ delivery catheter (Edwards Lifesciences) is stretchable, which allows for a lower vascular access profile. To diminish the arteriotomy size, the valve is not crimped on the balloon directly during preparation, but is crimped proximal to the balloon. Once the delivery catheter is in the ascending aorta, the balloon is pulled into the valve and is then advanced to the correct position. In addition, the Sapien XT is available in three diameter sizes: 23 mm, 26 mm, and 29 mm accommodating aortic annulus areas greater than 490 mm². These modifications allowed a reduction in the delivery sheath sizes to 16, 18, and 20Fr requiring iliac artery diameters of 6, 6.5, and 7 mm respectively. This resulted in lowered vascular complication rates compared to the first-generation valves. The first-generation Sapien valve required a 24Fr delivery sheath and was associated with a 15.5% incidence of vascular complications whereas the new generation Sapien valves have a 9.6% incidence of vascular complications. The incidence of conduction injury remained low at 6% [14].

The newest generation of transcatheter valves from Edwards is the Sapien 3 (Fig. 14). This valve is being evaluated in clinical trials in the USA currently, but is in use elsewhere. It is also a bovine pericardial leaflet valve mounted on a modified lower profile cobalt chromium stent frame. An outer skirt helps reduce para-valvular leaks. The redesigned Edwards Commander delivery catheter provides additional dual articulation to help better position the valve coaxially in the outflow tract. Improvements in the design of the catheter and sheath have resulted in a delivery profile of 14 French for the 23 and 26 mm valves, and 16 French for the 29 mm valves. These require vessel sizes of 5.5 mm and 6 mm, respectively.

Medtronic (Minneapolis, MN, USA) acquired the Corevalve in 2009. The valve gained FDA approval in 2014 for patients with severe symptomatic aortic stenosis who are at high risk for surgical intervention. The SurTAVI trial demonstrated the efficacy of the Corevalve compared to surgical intervention with improved one-year survival (86%) compared to SAVR (81%). The stroke rates were equivalent at 5.8% and 7% respectively ($p = 0.6$). The risk of needing a permanent pacemaker was significantly higher, however, at 25–30% compared to the Sapien series of 5%. The Corevalve is made from porcine pericardium on a self-expanding nitinol frame (Fig. 15). The thinner tissue thickness of porcine pericardium as well as the self-expanding design allowed for a smaller delivery

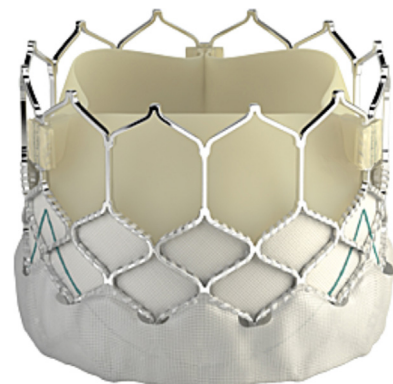


Fig. 14. Edwards Sapien 3 valve.

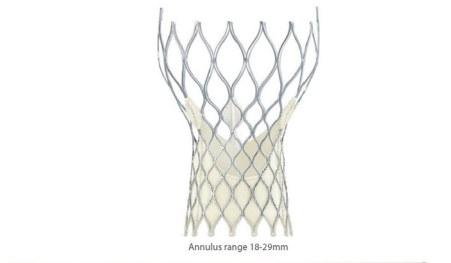


Fig. 15. Medtronic Corevalve and delivery sheath.

catheter profile of 18 French. Furthermore, the valve is available in sizes ranging from 23 to 31 mm in diameter which is useful in patients with a larger aortic annulus. The higher incidence of conduction block was due to the longer stent design (55 mm) reaching further down the left ventricular outflow tract and the self-expanding nature of the valve which exerts pressure on the conducting tissue within the septal wall. Careful valve positioning and better deployment techniques, such as using a smaller predilation balloon <23 mm, have resulted in a lower need for permanent pacemaker implantation of 15% [15]. Additionally, the persistent radial pressure of the valve scaffold on the aortic wall decreases para-valvular leaks over time. The Corevalve does not require rapid pacing to be deployed, but moderate pacing of 90–120 bpm may better stabilize the valve in patients with severe regurgitation or ectopy.

St. Jude Medical has been evaluating a trans-catheter valve, the Portico valve, in the TF CE Trial. This valve consists of bovine pericardial tissue on a self-expanding nitinol stent structure. The stent is shorter than the Corevalve reducing the risk for conduction injury, and like the Corevalve, the self-expanding design obviates the need for rapid pacing during deployment. The Portico valve is deployed through an 18 French delivery sheath. Currently, only a 23 mm valve is available but a 25 mm valve is being developed (Fig. 16).

The Direct Flow valve (Direct Flow Medical, Santa Rosa, CA, USA) is a non-metallic valve made of bovine pericardium, and a conformable expandable cuff (Fig. 17). Once the valve is in position across the annulus, the cuff is inflated with a liquid plastic polymer that hardens keeping the cuff in place. This creates an atraumatic seal. The system is introduced using an 18Fr sheath and is both repositionable and retrievable. Smaller trials were conducted in the USA and the larger SALUS trial was initiated in May 2014.

Currently in the USA, only patients with severe symptomatic degenerative aortic stenosis qualify for TAVR. Interventions for aortic regurgitation or bicuspid valves have been performed but have not gained FDA approval in the USA. Valve-in-valve procedures are also off-label but have been performed in cases where a previously implanted bio-prosthetic valve has degenerated in a high



Fig. 16. St. Jude Portico valve.




Fig. 17. The Direct Flow valve made of treated bovine pericardium and a non-metallic inflatable cuff.

surgical risk patient. Trans-catheter valves have been used to correct valvular dysfunction in the mitral, pulmonic and tricuspid positions.

Mitral stenosis

Mitral stenosis has decreased in incidence in developed countries but continues to be prevalent in much of the world. The primary cause is rheumatic mitral disease. Other less common causes include infective endocarditis, severe mitral calcification, lupus erythematosus, infiltrative disease, and advanced carcinoid. As the mitral valve area decreases, filling of the left ventricle is impaired and, with higher heart rates, the diastolic filling time is reduced. This produces increased left atrial pressure and pulmonary congestion [16]. The left atrium becomes dilated, which predisposes to atrial fibrillation and thromboemboli. Until the early 1980s, the only option was surgical valve replacement as the scarred rheumatic mitral valves are not typically amenable to repair. Percutaneous balloon commissurotomy can be performed using a double balloon technique, which is rarely used, or the single Inoue balloon. The Inoue balloon has made mitral commissurotomy a more stable and straightforward minimally invasive procedure (Fig. 18). The balloon is made of a polyester micromesh between two latex layers. The balloon is self-centering due to the creation of a waist in the middle. It is available in three sizes that cover a range of 24–30 mm in diameter. Careful review of the mitral valve anatomy is required to assess suitability; heavily calcified commissures are unlikely to yield and may rupture. A calibrated syringe helps fill the balloon to the desired diameter in a progressive fashion. A balloon stretching tube is used with the inner tube to stretch the Inoue balloon as it is introduced into the body and across the septum to slenderize it, giving it a lower profile. A dilator and guide wire are included to dilate both the venous entry point and the septum, and then maintain access across the atrial septum. A curved stylet directs the balloon at the

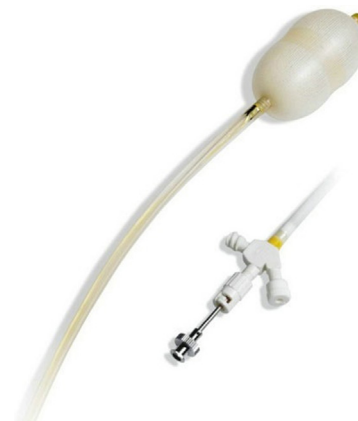

Fig. 18. Inoue balloon and hub.

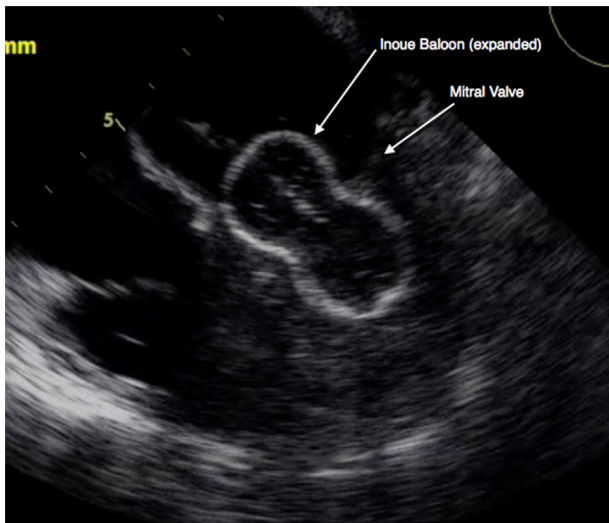


Fig. 19. Transesophageal echocardiography image of the Inoue balloon expanded across a stenotic mitral valve.

appropriate angle to help cross the stenotic mitral valve (Fig. 19). When performed by experienced operators, the procedure has a high technical success rate of 99%. Complications include a 1.5% risk for embolic events, 23% risk for increase in mitral regurgitation (MR), 4% risk for MR requiring repair, and a 1% risk of death.

Mitral regurgitation

MR is more common than mitral stenosis and is categorized depending on whether there is a structural abnormality of the valve leaflets or chordae or if the regurgitation is due to valve dysfunction created by LV dilatation. The most common cause of structural MR is valve prolapse due to myxomatous degeneration and chordal stretching. Dilated cardiomyopathy of any etiology is the most common cause of functional MR [17]. There are several devices that have been developed for percutaneous repair of mitral regurgitation including the MitraClip (Abbott Laboratories, Abbott Park, IL, USA), Carillon (Cardiac Dimensions Inc., Kirkland, WA, USA), Cardioband (Valtech, Boston, MA, USA), MONARC (Edwards Lifesciences, Irvine, CA, USA), Mitralign (Mitralign, Tewksbury, MA, USA), and trans-catheter mitral valve replacement.

The MitraClip was developed to percutaneously recreate the Alfieri stitch described in 1991 to treat mitral regurgitation by creating a double orifice for the mitral valve by clipping the middle edges of the anterior and posterior mitral leaflets together. The Everest II trial demonstrated efficacy of the device in high-risk surgical patients and MitraClip has gained widespread use outside the USA with expanding indications (Fig. 20). The device is



Fig. 21. The Carillon mitral contour system.

composed of a steerable 24Fr guide-catheter that is placed from the inferior vena cava (IVC) across the atrial septum. The MitraClip device is made of cobalt chromium with a polyester cover. The delivery system controls two separate MitraClip arms to stabilize then grasp the mitral leaflets. Once an appropriate position is attained, the clip is closed and the leaflets are secured. The EVEREST II trial demonstrated improved safety in the transcatheter treated group primarily due to lower bleeding rates compared with surgery. High-risk patients (Society of Thoracic Surgeons' risk model (STS) score > 12) with functional MR demonstrated procedural success of 76% that was sustained at 12 months. The need for mitral valve surgery at one year was low at under 6% with maintenance of NYHA functional class I/II for 75% of surviving patients [18].

A second approach to treating functional MR is to use the proximity of the great cardiac vein to the mitral annulus. A device is delivered from the right internal jugular vein through the coronary sinus just proximal to the takeoff of the anterior interventricular vein. A distal anchor is secured and then the atrial tissue is plicated by pulling tension on the device, which simultaneously pulls on the tissue around the mitral annulus. The plication of tissue approximates the anterior and posterior mitral leaflets to decrease the regurgitant flow. There is a risk of circumflex coronary artery compression as branches of this vessel may pass under the great cardiac vein in 27% of hearts. As the device is delivered via the right heart and through the coronary sinus, the procedural risk is low.

The Carillon mitral contour system is a coronary sinus implant that consists of a proximal and distal anchor connected by a nitinol shaping ribbon (Fig. 21). The distal anchor is delivered in the great cardiac vein and after tension is applied, the proximal anchor is delivered near the ostium of the coronary sinus. The immediate effect on MR is assessed by transesophageal echocardiography (TEE) and coronary compression is evaluated before release. The tension can then be adjusted or the device retrieved as necessary.

The Mitralign is a direct mitral annuloplasty device. It is implanted directly on the mitral annulus to avoid the risk of coronary compression seen with coronary sinus approaches. This device delivers two pledgette sutures near the P1 and P3 leaflets. The sutures are then plicated, tightening the posterior leaflet and

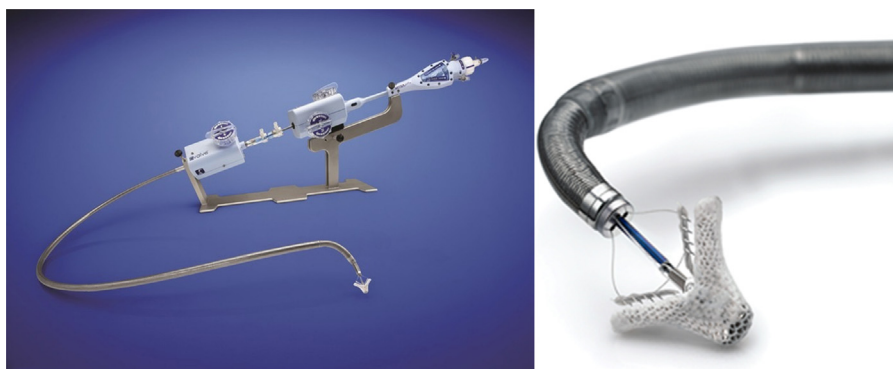

Fig. 20. The MitraClip deployment system on left, and the clip on the right.

reducing the mitral annulus diameter. The Guided Delivery Systems device (Guided Delivery Systems, Santa Clara, CA, USA) introduces a catheter into the left ventricle retrograde from the aorta. The catheter is then used to deliver several anchors on the ventricular aspect of the posterior leaflet. The anchors are “cinched” together reducing the valve annular diameter. The Cardioband device attempts to reproduce the effects of a surgical annuloplasty in that it delivers a flexible ring onto the atrial side of the valve to “cinch” the posterior leaflet closer. There have been about 25 cases performed with effective reduction in the degree of mitral regurgitation.

Due to the more complex anatomy of the mitral valve and surrounding structures, a trans-catheter solution for mitral valve replacement is still not mature at this time. Several valves are being developed to overcome challenges such as increased wall stress, pressure, and asymmetric chamber geometry. If the patient already has a surgically implanted bio-prosthetic valve, however, the option exists for implanting a currently available device such as the Edwards Sapien valve as a “valve-in-valve” procedure. The previously implanted prosthesis acts as an anchoring ring for the valve stent with good procedural success rates and improvement in outcomes and function [19].

Pulmonic valve stenosis and regurgitation

Improvement in the management of congenital heart disease patients at an early stage has increased survival which reveals subsequent problems as these patients grow older. Pulmonic valve stenosis may be congenital, acquired, or associated with more complex congenital heart diseases. Balloon valvuloplasty can be used in isolated stenosis with good long-term outcomes [20]. Valve regurgitation often occurs in the same population, especially after prior congenital repair such as the Ross procedure or tetralogy of Fallot repair. Trans-catheter valves are increasingly used in these cases or where the valve or conduit has degenerated to produce severe pulmonic insufficiency.

The Melody valve (Medtronic) is commercially available with indications for pulmonic regurgitation or stenosis and a dysfunctional right ventricle with a conduit size greater than 16 mm. It is a bovine jugular valve on a platinum-iridium stent crimped on a 22Fr Ensemble catheter delivery system (Fig. 22). The delivery catheter is a balloon-in-balloon system with outer diameters of 18, 20, and 22 mm introduced via the femoral vein. Alternatively, Edwards Lifesciences is investigating the Sapien pulmonic heart valve. It is a bovine pericardial tissue valve on a stainless steel frame similar to the Edwards aortic Sapien valve. In positioning these valves, computed tomography or magnetic resonance imaging overlay and bi-plane fluoroscopy can be useful. Many of these patients have complex anatomy or unusual cardiac orientations so precise positioning is important. This avoids placing the valves in dilated or deformed conduits, or possible compression of coronary arteries or impinging other structures.



Fig. 22. The Medtronic Melody valve (expanded).

Paravalvular leaks

Paravalvular leaks occur when the annulus of an implanted valve does not fully oppose the annulus around it, which may occur due to disruption of ring sutures or annulus dilation. The leaks may be hemodynamically significant or can be associated with significant hemolysis. Moderate regurgitation results in worse patient outcomes [21]. No device is currently approved in the USA and catheter-based interventions are performed off-label. Vascular plugs are most often used for closure. The most common of these are the Amplatzer family of plugs (St. Jude Medical). These plugs are made of a nitinol mesh delivered by a cable through a catheter system. The Amplatzer Vascular Plug (AVP) is a cylinder shaped self-expanding plug available in diameters from 4 to 16 mm (Fig. 23). The AVP-II is multi-segmented with discs on both ends. These stabilize the device in larger leaks and limit flow through the defect reducing time to occlusion (Fig. 24). It is available in sizes from 3 to 22 mm. The AVP-4 is a low-profile bi-lobed device on a flexible delivery wire that allows for easier maneuverability (Fig. 25). This device can be delivered through a 0.035 inch ID (4Fr) catheter and is available in sizes from 4 to 8 mm. It is also possible




Fig. 23. The Amplatzer vascular plug.



Fig. 24. The Amplatzer vascular plug II.



Fig. 25. The Amplatzer vascular plug 4.

to use the ADO-II ductal occluder, described previously, for larger paravalvular leaks. Careful assessment of the defect orientation and size is necessary before and during the procedure. TEE with 3D imaging has made these complex procedures much easier to perform since the operator can visualize the orientation of the leak relative to the catheter. For crescentic defects, more than one device may be needed to cover a large area [22]. The AVP-III device is oval and is beneficial in these types of paravalvular leaks, but it is only available outside the USA.

Coarctation of the aorta

Coarctation of the aorta is a congenital condition producing a discrete narrowing of the aorta typically at the ligamentum arteriosum just distal to the left subclavian artery. This condition is associated with bicuspid aortic valves in about 50% and aortopathy (where the aorta dilates in a fusiform aneurysm) in 56–88% of those aged 30 and 80 years respectively [23].

Early repair of the stenosis with an expandable stent improves long-term outcomes [24]. The procedure has potential risks as expanding a stent may tear the tunica intima. Covered stents are preferable and surgical backup should be available when performing this procedure in case of wall injury and aortic rupture. The aorta exerts recoil force after balloon expansion so a device with high radial strength is necessary. The procedure is usually performed on children and young adults under general anesthesia. A 14–16Fr access is obtained in the femoral artery and a long sheath is introduced to the aortic arch past the narrowing. Stents are mounted on a balloon-in-balloon system (BIB, NuMed, Hopkinton, KY, USA and pfm medical) that allows for a more precise and controlled stent expansion in the coarctation (Fig. 26). The outer balloons range in size from 8 to 24 mm. Once the stent is in position, the sheath is withdrawn to unsheath the stent before deployment. Many stents are available for younger children, but as patients grow, the stents will need to be expanded to a larger diameter of around 20–30 mm [25]. The most commonly used stents are the Palmaz XL stent (Johnson & Johnson, New Brunswick, NJ, USA), the Palmaz Genesis (Johnson & Johnson), Cheatham-Platinum (CP) stent (NuMed), the IntraStent (Covidien, ev3, Plymouth, MN, USA), and the Atrium Advanta stent (Atrium Medical, Hudson, NH, USA).

The Palmaz XL is a laser-cut closed-cell stainless steel stent with high radial strength. It is available in lengths of 31, 40, and 50 mm and must be expanded to a minimum diameter of 10 mm limiting



Fig. 26. Balloon-in-balloon (BIB).




Fig. 27. The Atrium Advanta covered stent.

its use in smaller children. The Palmaz Genesis stent is similarly a stainless steel closed-cell stent with curved segments allowing for improved conformability. This stent is available in lengths of 19, 25, 29, 39, and 59 mm. As this stent is limited at full expansion to 19 mm, it is not optimal for patients who are expected to grow to a normal sized aorta. The CP stent is a 0.013-inch platinum-iridium frame welded at each joint and over braided with gold. The stent may be expanded from 12.0 to 24.0 mm. A covered version of the stent has an expandable sleeve of ePTFE.

The IntraStent LD is an open-cell stainless steel stent with less radial strength but greater flexibility and conformability. The IntraStent LD may be dilated up to 26 mm, and is delivered via a smaller 8 French sheath.

The Atrium Advanta series is an encapsulated covered stent where the ePTFE is on both the inside and outside of the stent. It may be dilated up to 22 mm and is available with 12-, 14-, and 16-mm balloons (Fig. 27).

Peripheral arteriovenous fistula

Arteriovenous (AV) fistulae are abnormal communications between arteries and veins. They occur congenitally as a consequence of a pathologic process, such as hereditary hemorrhagic telangiectasia (HHT) due to lack of inhibition of endothelial growth factors, injury, or after surgery such as the Fontan repair. Hemodynamic studies may show persistent elevation of right heart pressures, or reduced peripheral vascular resistance. These AV fistulae tend to be fragile with risk of rupture. Pulmonary AV fistulae bypass the lungs delivering de-oxygenated blood to the left circulation [26]. If possible, decompression of the pressure causing the AV fistula will resolve peripheral AV fistula but, along with surgery, percutaneous options are available. Coil embolization is usually successful and relatively safe. For pulmonary AV fistula the operator introduces a Berman catheter; and angiograms of the pulmonary artery and veins in the Levo-phase are obtained. Once the AV fistula is identified, a catheter is advanced over a wire to the vessel and the AV fistula is engaged. Coils of the appropriate diameter and length are then introduced to block the abnormal flow. AV fistulae outside of the pulmonary circulation may be closed in much the same fashion. For peripheral AV fistulae, alcohol sclerotherapy has been used, but there is an increased risk of peripheral nerve injury, especially in fistulae with high flow.

Coronary artery fistula

Coronary artery fistulae bypass the myocardial capillary bed and attach to the pulmonary or venous circulation. If the coronary artery communicates with a cardiac chamber, it is called a coronary-cameral fistula. Sizable fistulae of greater than three times the size of a coronary may cause angina due to a steal syndrome and increased chamber pressures. Deploying embolization coils from the venous side has the advantage of reducing the likelihood of occluding the coronary circulation. It may be challenging to enter the AV fistula from the venous side, especially if the connection is through a chamber. A coronary wire can be advanced across the AV fistula and snared from the venous side. It is then carefully externalized through a guide catheter taking care

not to “floss” the tissue by pulling too hard. A venous soft-tip catheter is then advanced over the wire into the AV fistula to deliver the appropriate coils. In larger fistulae, vascular plug devices may be used.

Left atrial appendage occlusion

Atrial fibrillation affects more than 10% of people over the age of 80 years and increases in prevalence with age. The lifetime risk of having atrial fibrillation is 25% [27]. Atrial fibrillation increases the risk for developing cerebral and non-cerebral embolic events. The CHA2DS2-VASc score helps predict the risk of developing emboli for patients with atrial fibrillation who do not have associated mitral stenosis. Approximately 90% of emboli develop in the left atrial appendage due to stagnation of blood flow during atrial fibrillation [28]. Trans-catheter devices that occlude the left atrial appendage are attractive as an option to reduce the risk of emboli especially in patients intolerant of anticoagulation therapy or at an increased risk of bleeding with a high HAS-BLED score.

The Watchman device (Atritech, Inc., Minneapolis, MN, USA) is a self-expanding nitinol frame with fixation barbs and a permeable polyester fabric that covers the atrial side of the device (Fig. 28). The device is available in diameters from 21 to 33 mm. Left atrial appendage anatomy varies among patients so careful assessment by imaging and angiography should guide selection of the device size. After a trans-septal puncture, the device is delivered via a 12Fr catheter into the left atrial appendage. Trans-esophageal imaging is used during the procedure to ensure adequate fixation while covering the entire opening of the appendage.

The Amplatzer cardiac plug (St. Jude Medical) is also a left atrial appendage-occluding device that is made from a flexible nitinol wire mesh. The device is softer and more flexible than the ASD occluder series. The device has a self-orienting disk on an articulating neck (Fig. 29). This allows the distal part of the device

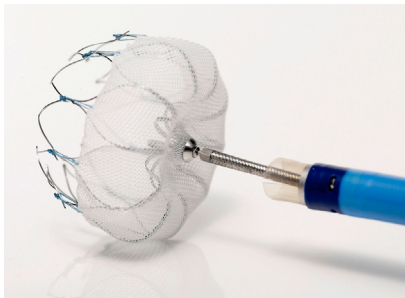


Fig. 28. The Watchman left atrial appendage occluder.



Fig. 29. The Amplatzer cardiac plug.

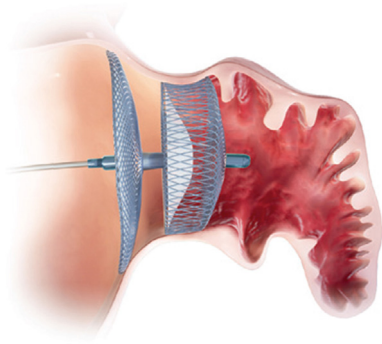


Fig. 30. The Amplatzer cardiac plug positioning in the left atrial appendage.

to occupy the left atrial appendage lobe for anchoring. The proximal articulating disk then achieves full coverage of the appendage opening and is metaphorically termed the “garbage can cover” to the LAA (Fig. 30). Device sizing depends on the distal inner-wall lobe and ranges from 16 to 30 mm. The outer disk is 4 mm larger for lobes smaller than 24 mm and 6 mm for larger appendages. The device is available internationally but not yet approved in the USA.

A third device in use is the Lariat suture delivery system (SentreHeart, Redwood, CA, USA). The device delivers a 40 mm pre-tied suture loop around the appendage to occlude it from the outside. A wire and catheter is advanced up the IVC and across the septum into the left atrial appendage. The wire contains a magnet at the tip. A dry pericardial tap is done under the left para-xiphoid area and a second wire with a tip-magnet is advanced along the lateral border of the heart until it meets the first magnet. The suture loop is then advanced along the pericardial wire and manipulated over the appendage until it surrounds the opening of the left atrial appendage. To help in positioning, a balloon is inflated in the appendage. The loop is then tightened to attain adequate appendage occlusion. Complications of this procedure include a moderate amount of pain and residual pericarditis which may be modulated by pre-treatment with colchicine.

Stem cell therapy

Stem cell therapy for a multitude of medical problems has gained widespread interest since 2000. The extension of stem cell therapy for cardiac conditions is taking many approaches. Positive results have been obtained in animal studies, and early human trials suggest mild benefits. The greatest promise of the therapy is in the treatment of heart failure after infarct for recovery of cardiac function. The concept of stem cell therapy is to use multi-potent progenitor cells to take over diseased or infarcted cardiac muscle tissue. These cells are active during neonatal and early infant life but are reduced substantially in the adult and enter a quiescent stage. Work is being done to understand the signaling mechanisms to both reactivate and attract the multi-potent cells to the site of injury [29]. The ideal cell type for this therapy is being evaluated. Multiple cell lines are being tested, including myoblast cells from skeletal cells, CD35 cells from bone marrow or from apheresis. Other agents used include hormones and signaling molecules to attract and activate progenitor cells. Another variable is the delivery technique that will demonstrate the best clinical efficacy.

To target the cells to the injured myocardium and encourage engraftment, several techniques are being studied. One technique involves infusing the cells after they are isolated and proliferate in vitro, via an intra-coronary catheter directly into a

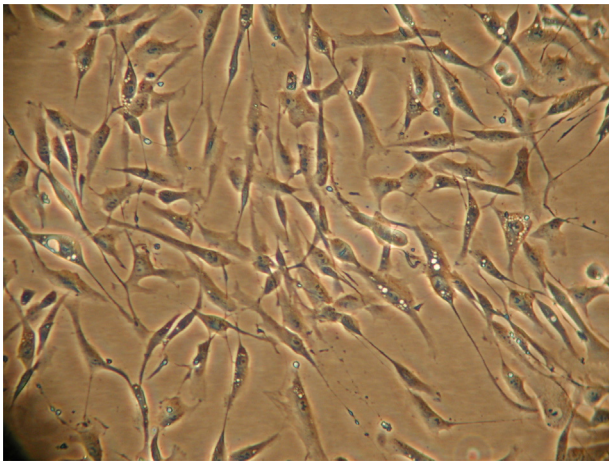


Fig. 31. Skeletal myoblasts in cell culture.

coronary artery supplying the injured myocardium post-infarct. Another approach is to infuse signaling chemicals intravenously to activate a paracrine mechanism and stimulate resident cardiac stem cells [30]. These techniques depend on margination and adherence of the biologic agent to the site of prior injury (Fig. 31).

A more direct technique involves injecting the harvested cells into the targeted myocardium by use of a needle-tipped catheter and a mapping system. Several needle catheters have been developed including the BioCardia (San Carlos, CA, USA), and Myostar (Biosense Webster Inc., Diamond Bar, CA, USA). These catheters share similar characteristics in that they are deflectable and deliver the cells via a needle directly into the muscle (Fig. 32). To target areas of injury, the NOGA mapping system (Biosense Webster Inc.) is used to create an electric map with the assumption that low residual activity corresponds to an area of injured myocytes (Fig. 33). It is important to recognize that the choice of the agent and delivery method are dependent variables influencing the efficacy of each other and affecting clinical success. At this time, there is no consensus as to which cells or method of delivery is preferable for cardiac applications, but there is a wealth of preclinical and early clinical data showing safety, feasibility, and mild efficacy of adult cell-based therapy. It is hoped that this new field will have future benefit for the treatment of conditions such as severe angina or heart failure.

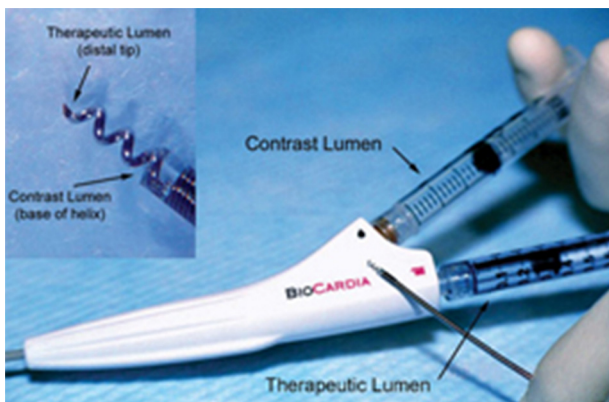


Fig. 32. Deflectable intra-cardiac biologic agent delivery catheter.

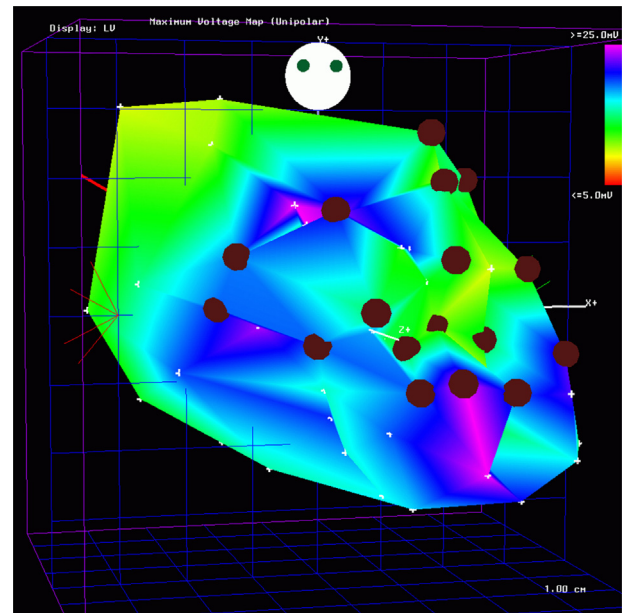


Fig. 33. NOGA mapping of the left ventricle. Color represents regional voltage map from blue (highest) to red (lowest) voltage potential.

References

- [1] Steinberg DH, Staubach S, Franke J, Sievert H. Defining structural heart disease in the adult patient: current scope, inherent challenges and future directions. *Eur Heart J* 2010;12(Suppl. E):E2–9.
- [2] Masura J, Gavora P, Podnar T. Long-term outcome of transcatheter secundum-type atrial septal defect closure using Amplatzer septal occluders. *J Am Coll Cardiol* 2005;45:505–7.
- [3] Peirone AR, Pedra SF, Cardoso Pedra CA. Outcomes after transcatheter ASD closure. *Intervent Cardiol Clin* 2013;2:39–49.
- [4] Wertman B, Azarbal B, Riedl M, Tobis J. Adverse events associated with nickel allergy in patients undergoing percutaneous atrial septal defect or patent foramen ovale closure. *J Am Coll Cardiol* 2006;47:1226–7.
- [5] Law MA, Josey J, Justino H, Mullins CE, Ing FF, Nugent AW. Long-term follow-up of the STARFlex device for closure of secundum atrial septal defect. *Catheter Cardiovasc Interv* 2009;73:190–5.
- [6] Hagen PT, Scholz DG, Edwards WD. Incidence and size of patent foramen ovale during the first 10 decades of life: an autopsy study of 965 normal hearts. *Mayo Clin Proc* 1984;59:17–20.
- [7] Tobis J, Shenoda M. Percutaneous treatment of patent foramen ovale and atrial septal defects. *J Am Coll Cardiol* 2012;60:1722–32.
- [8] Boehm W, Emmel M, Sreeram N. The Amplatzer duct occluder for PDA closure: indications, technique of implantation and clinical outcome. *Images Paediatr Cardiol* 2007;9:16–26.
- [9] Horlick EM, Benson LN, Osten MD. Structural heart disease interventions. Philadelphia, PA: University of Toronto, Division of Cardiology. Lippincott Williams & Wilkins; 2012. p. 197–206.
- [10] Hoffman JI, Kaplan S. The incidence of congenital heart disease. *J Am Coll Cardiol* 2002;39:1890–900.
- [11] Gabriel HM, Heger M, Innerhofer P. Long-term outcome of patients with ventricular septal defect considered not to require surgical closure during childhood. *J Am Coll Cardiol* 2002;39:1066–71.
- [12] Thanopoulos BD, Tsaousis GS, Konstadopoulou ZN, Zarayelyan AG. Transcatheter closure of muscular septal ventricular defects with the Amplatzer septal ventricular occluder: initial clinical application in children. *J Am Coll Cardiol* 1999;33:1395–9.
- [13] International Multicentre Clinical Device Investigation on Safety and Effectiveness of the Nit-Occlud[®] LèVSD Spiral Coil System for VSD Occlusion (clinicaltrials.gov identifier NCT00390702).
- [14] Généreux P, Webb JG, Svensson LG, Kodali SK, Satler LF, Fearon WF, Davidson CJ, Eisenhauer AC, Makkar RR, Bergman GW, Babaliaros V, Bavaria JE, Velazquez OC, Williams MR, Hueter I, et al. Vascular complications after transcatheter aortic valve replacement: insights from the PARTNER (Placement of AoRTicTraNscatheterER Valve) trial. *J Am Coll Cardiol* 2012;60:1043–52.
- [15] Lange P, Greif M, Vogel A, Thaumann A, Helbig S, Schwarz F, Schmitz C, Becker C, D'Anastasi M, Boekstegers P, Pohl T, Laubender RP, Steinbeck G, Kupatt C. Reduction of pacemaker implantation rates after CoreValve implantation by moderate predilatation. *EuroIntervention* 2014;9:1151–7.
- [16] Carabello BA. Modern management of mitral stenosis. *Circulation* 2005;112:432–7.

- [17] Trichon BH, O'Connor CM. Secondary mitral and tricuspid regurgitation accompanying left ventricular systolic dysfunction: is it important, and how is it treated? *Am Heart J* 2002;144:373.
- [18] Feldman T, Young A. Percutaneous approaches to valve repair for mitral regurgitation. *J Am Coll Cardiol* 2014;63:2057–68.
- [19] Webb JG, Wood DA, Ye J, Gurvitch R, Masson JB, Rodés-Cabau J, Osten M, Horlick E, Wendler O, Dumont E, Carere RG, Wijesinghe N, Nietlispach F, Johnson M, Thompson CR, et al. Trans-catheter valve-in-valve implantation for failed bioprosthetic heart valves. *Circulation* 2010;121:1848–57.
- [20] McCrindle B, Kan JS. Long-term results after balloon pulmonary valvuloplasty. *Circulation* 1991;83:1915–22.
- [21] Krishnaswamy A, Tuzcu EM, Kapadia SR. Percutaneous paravalvular leak closure. *Intervent Cardiol Rev* 2013;9(1):44–8.
- [22] Rihal CS, Sorajja P, Booker JD, Hagler DJ, Cabalka AK. Principles of percutaneous paravalvular leak closure. *JACC Cardiovasc Interv* 2012;5:121–30.
- [23] Tadros TM, Klein MD, Shapira MM. Ascending aortic dilatation associated with bicuspid aortic valve pathophysiology, molecular biology, and clinical implications. *Circulation* 2009;119:880–90.
- [24] Presbitero P, Demarie D, Villani M, Perinotto EA, Riva G, Orzan F, Bobbio M, Morea M, Brusca A. Long term results (15–30 years) of surgical repair of aortic coarctation. *Br Heart J* 1987;57:462–7.
- [25] Garcier JM, Petitcolin V, Filaire M, Mofid R, Azarnouch K, Ravel A, Vanneville G, Boyer L. Normal diameter of the thoracic aorta in adults: a magnetic resonance imaging study. *Surg Radiol Anat* 2003;25:322–9.
- [26] Kraemer N, Krombach GA. Pulmonary arteriovenous fistula. *N Engl J Med* 2009;360:1769.
- [27] Estes 3rd NA, Halperin JL, Calkins H, Ezekowitz MD, Gitman P, Go AS, McNamara RL, Messer JV, Ritchie JL, Romeo SJ, Waldo AL, Wyse DG, Bonow RO, DeLong E, Goff Jr DC, et al. ACC physicians consortium 2008 Clinical performance measure for adults with non-valvular atrial fibrillation and atrial flutter. A report of the American College of Cardiology/American Heart Association Task Force on Performance Measures and the Physician Consortium for Performance Improvement (Writing Committee to Develop Clinical Performance Measures for Atrial Fibrillation) Developed in Collaboration with the Heart Rhythm Society. *J Am Coll Cardiol* 2008;51:865–84.
- [28] Abudayyeh I, Passen E, Nicholson D. Fractional shortening of the left atrial appendage by multi-detector computed tomography. In: Poster Presentation. SCCT national meeting; 2011.
- [29] Garbern JC, Lee RT. Cardiac stem cell therapy and the promise of heart regeneration. *Cell Stem Cell* 2013;12:689–98.
- [30] Gnechi M, Zhang Z, Ni A, Dzau VJ. Paracrine mechanisms in adult stem cell signaling and therapy. *Circ Res* 2008;103:1204–19.