

# UC Davis

## Dermatology Online Journal

### Title

Cutaneous congenital candidiasis in a full-term newborn from an asymptomatic mother

### Permalink

<https://escholarship.org/uc/item/6z85x878>

### Journal

Dermatology Online Journal, 19(7)

### Authors

Torres-Alvarez, Bertha  
Hernandez-Blanco, Diana  
Ehnis-Perez, Adriana  
et al.

### Publication Date

2013

### DOI

10.5070/D3197018967

### Copyright Information

Copyright 2013 by the author(s). This work is made available under the terms of a Creative Commons Attribution-NonCommercial-NoDerivatives License, available at <https://creativecommons.org/licenses/by-nc-nd/4.0/>

Peer reviewed

Photo Vignette

Cutaneous congenital candidiasis in a full-term newborn from an asymptomatic mother

Bertha Torres-Alvarez, Diana Hernández-Blanco, Adriana Ehnis-Pérez, Juan Pablo Castanedo-Cazares

Dermatology Online Journal 19 (7): 13

Dermatology Department. Hospital Central. Universidad Autónoma de San Luis Potosí, México.

Correspondence:

Juan Pablo Castanedo-Cazares, MD, MSc  
Hospital Central "Dr. Ignacio Morones Prieto".  
Universidad Autónoma de San Luis Potosí  
San Luis Potosí, San Luis Potosí, México  
castanju@yahoo.com

## Case Report

A male infant of 2,900 g was born at term to a 19-year-old primigravida woman who had adequate prenatal care and no major complications detected during the pregnancy. The only reported medical event was an episode of urinary tract infection by *E. coli* one month before delivering, which resolved without complications using nitrofurantoin. There was no history of maternal herpes simplex infection and her serologic screening was negative for syphilis.

The baby was born by spontaneous vaginal breech delivery at 37-weeks of gestation. The membranes ruptured at the hospital and there was no history of vaginal secretions or leakages prior to the onset of labor. The infant was well developed and obtained a 5-minute Apgar score of 9. On physical exam, he presented with macular and papular skin lesions covering the trunk, extremities, diaper area, and skin folds. Some lesions rapidly evolved into vesicles or pustules, sparing the oral cavity, nostrils, palms, and soles (Figure 1 and 2). The examination of the placental and umbilical cord showed no gross abnormalities. Routine blood tests and chest radiograph was normal. Tzanck smear from vesicles did not show multinucleated cells, but a potassium hydroxide preparation of the scaly lesions revealed numerous budding yeasts and pseudohyphae (Figure 3). After this finding, the infant was started on topical treatment with 100,000 units/g nystatin cream and observed closely. *Candida albicans* was identified later in a culture of skin scales, which confirmed the diagnosis (Figure 4). Skin lesions cleared promptly following a 10-day course of treatment. The newborn was discharged without developing sepsis or *Candida* infection elsewhere on his body. The outpatient visit one month later confirmed the complete resolution of this condition.

## Discussion

*Candida albicans* is a frequent pathogen of the female genital tract, especially during pregnancy. Neonatal candidiasis can either be acquired at birth, by delivery through an infected canal, or postnatally from nursery contacts [1]. It usually appears after the fifth day of life and commonly manifests as oral thrush or diaper dermatitis. However, cutaneous congenital candidiasis (CCC) is frequently secondary to *Candida* chorioamnionitis, which is considered the mechanism of fetal infection [2,3].

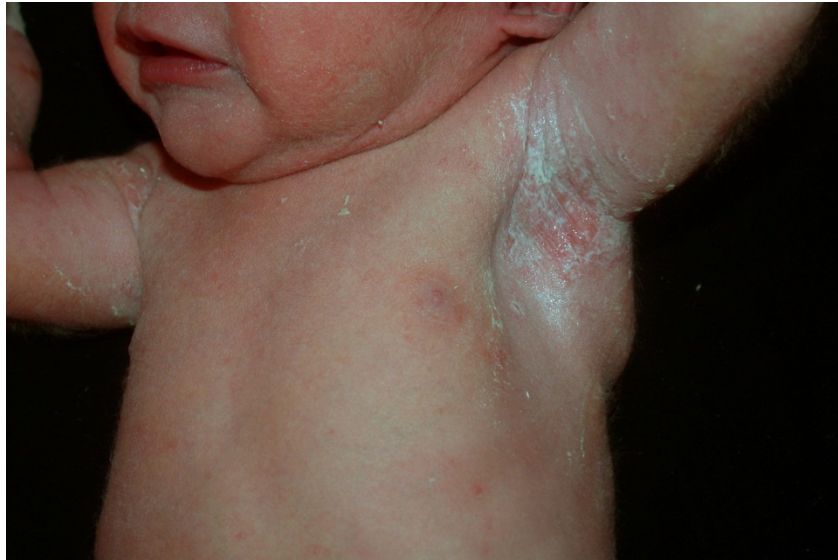The incidence of an ascending infection in cases of vaginal infection is less than 1% and rarely causes chorioamnionitis [2,4]. Foreign intrauterine bodies such as intrauterine devices and cervical cerclage, as well as preterm birth have been considered as the main risk factors [5]. CCC can occur as an asymptomatic infection or as a disseminated infection with respiratory distress, hepato-splenomegaly, sepsis, or even death [6,7,8]. However, the most common presentation is a cutaneous generalized eruption of erythematous macules, papules, and/or pustules, with a benign outcome [5,9]. As described, this infant showed an eruption covering the trunk, extremities, diaper area, and skin folds. It has been reported that the presence of white microabscesses on the surface of the placenta and umbilical cord is virtually pathognomonic for the diagnosis [2]. However, the visual inspection of the placenta and umbilical cord was normal in our case.

CCC is an infrequent condition with fewer than 100 cases reported in the literature over the past 40 years [10]. However it may occur more frequently than is indicated by the literature because the condition may remain unrecognized related to the commonly self-limited course [5,9,10]. We acknowledge that clinical features, as well as an appropriate potassium hydroxide exam and culture, are useful to differentiate these lesions from other conditions. The differential diagnosis includes erythema toxicum, transient neonatal pustular melanosis, drug eruptions, and infections such as syphilis, listeriosis, malaria, staphylococcal infection, or herpes simplex [2,3,4,10,11].

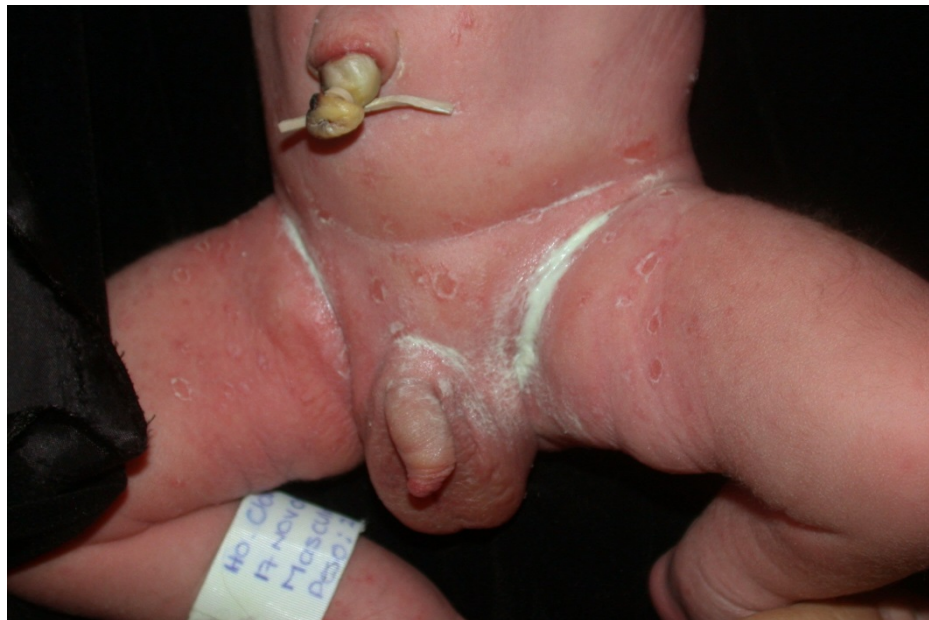Nearly one-fourth of pregnant women are colonized by *Candida albicans* in their vaginal flora. However in our case prenatal care visits showed no evidence of fungal disease. In this case, the mother was apparently healthy and had only been affected by a urinary tract infection during the last month of pregnancy.

Approximately half of the newborns with CCC respond to topical therapy alone [10,11]. There are no clinical trials to determine the optimal length of therapy, but topical antifungal treatment should be applied until the lesions resolve [10]. We did not prescribe systemic therapy because the patient was healthy without risk factors. The use of systemic antifungals could be indicated if there are respiratory distress, signs of sepsis, low birth weight, broad spectrum antibiotic use, aggressive instrumentation during delivery, or positive systemic cultures [11].

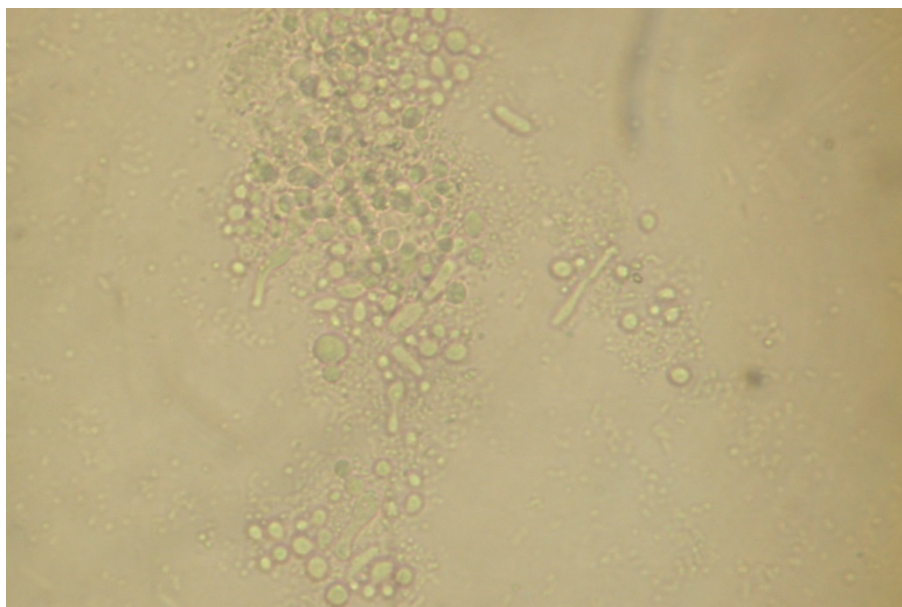
Our case raises awareness that a CCC infection can be transmitted from an apparently healthy mother without risk factors. Our patient's mother showed no evidence of abnormal vaginal discharge or presence of candida in her cytological exam. Although the reason for developing this infection is unknown, it is suggested that CCC may be facilitated by subclinical rupture of membranes before delivery [5]. If this condition is recognized early, unnecessary testing and overtreatment of newborns who present with these symptoms can be avoided.



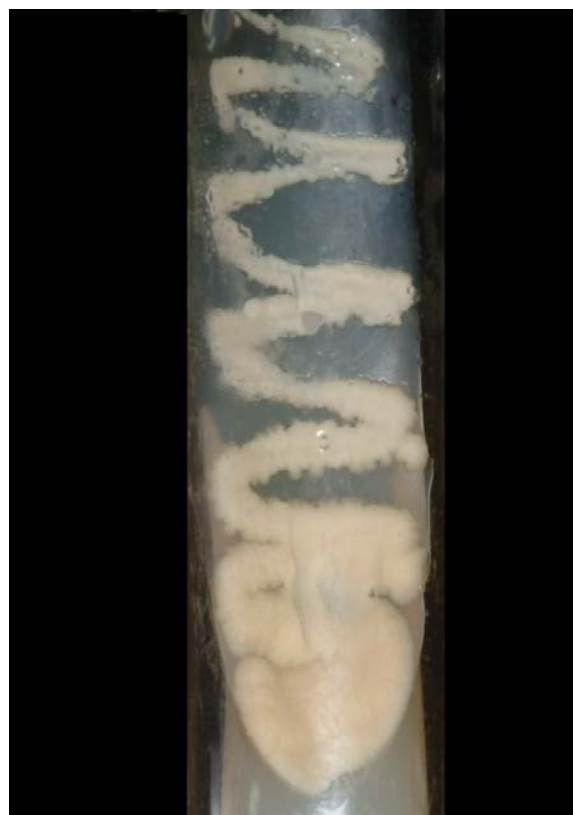**Figure 1:** Macular and papular skin lesions covering trunk and extremities.



**Figure 2:** Macular and papulo-vesicular skin lesions on diaper area and skin folds, leaving scales and erosions.



**Figure 3:** Budding yeast and pseudohyphae on direct examination with potassium hydroxide (Magnification 400x).



**Figure 4:** Isolation of *Candida albicans* on Sabouraud agar with cycloheximide.

## REFERENCES

1. Lane AT. Cutaneous candidiasis. *Pediatr Dermatol* 1995;12:369.
2. Diana A, Epiney M, Ecoffey M, Pfister RE. White dots on the placenta and red dots on the baby: congenital cutaneous candidiasis –a rare disease of the neonate. *Acta Paediatrica* 2004;93:996-99. [PMID:15303819]
3. Roque H, Abdelhak Y, Young BK. Intra amniotic candidiasis. Case report and meta-analysis of 54 cases. *J Perinat Med* 1999;27:253-62.
4. Blaschke-Hellmessen R. Vertical transmission of *Candida* and its consequences. *Mycoses* 1998;41 Suppl 2:31-36.
5. Darmstadt GL, Dinulos JG, Miller Z. Congenital cutaneous candidiasis: clinical presentation, pathogenesis and management guidelines. *Pediatrics* 2000;105:438-44.
6. Almeida-Santos L, Beceiro J, Hernandez R, et al Congenital cutaneous candidiasis: report of four cases and review of the literature. *Eur J Pediatr* 1991;150:336-38
7. Waguespack-LaBiche J, Chen SH, Yen A. Disseminated congenital candidiasis in a premature infant. *Arch Dermatol* 1999;135:510-12.
8. Gibney MD, Siegfried EC. Cutaneous congenital candidiasis: a case report. *Pediatr Dermatol* 1995;12:359-63.
9. Broberg A, Thiringer K. Congenital cutaneous candidiasis. *Int J Dermatol* 1989;28:464-65.

- 
10. Jagtap SA, Saple PP, Dhaliat SB. Congenital cutaneous candidiasis: a rare and unpredictable disease. *Indian J Dermatol.* 2011 Jan;56(1):92-3. PMID:21572803
  11. Johnson DE, Thompson TR, Ferrieri P. Congenital candidiasis. *Am J Dis Child.* 1981 Mar;135(3):273-5. PMID:7211787