

UCSF

UC San Francisco Previously Published Works

Title

Metastatic Donor-derived Malignancies Following Simultaneous Pancreas-kidney Transplant: Three Case Reports and Management Strategies.

Permalink

<https://escholarship.org/uc/item/6zd5c3pc>

Journal

Transplantation direct, 7(1)

ISSN

2373-8731

Authors

Amara, Dominic
Wisel, Steven A
Braun, Hillary J
[et al.](#)

Publication Date

2021

DOI

10.1097/txd.0000000000001090

Peer reviewed

OPEN

Metastatic Donor-derived Malignancies Following Simultaneous Pancreas-kidney Transplant: Three Case Reports and Management Strategies

Dominic Amara, BA,¹ Steven A. Wisel, MD,² Hillary J. Braun, MD,² Eric A. Collisson, MD,³ Terence Friedlander, MD,³ Giulia Worner, NP,² Garret R. Roll, MD,² Ryutaro Hirose, MD,² and Peter G. Stock, MD, PhD²

Background. Stopping immunosuppression in a transplant patient with donor-derived malignancy offers the theoretical benefit that reconstitution of the patient's immune system will allow "rejection" of the malignancy, as the malignancy also originates from allogeneic tissue. However, this option exists with the caveat that the patient's allograft(s) will likely be rejected too. In simultaneous pancreas-kidney (SPK) recipients, the normal continued functioning and possible absence of malignancy in either the unaffected kidney or pancreas further complicate this decision. **Methods.** The charts of 3 patients with donor-derived metastatic malignancies after SPK were retrospectively reviewed in detail. We provide treatment and management recommendations based on successful outcomes and a review of the existing literature. **Results.** Consistent with a broad review of the literature, in all 3 cases, complete immunosuppression cessation, removal of both grafts, and in 1 case treatment with an immune checkpoint inhibitor to augment the immune response was successful. One patient is doing well 1 year after successfully undergoing kidney retransplantation, while a second patient is active on the waitlist for SPK retransplantation after no evidence of metastatic disease for 2 years. **Conclusion.** The successful management of metastatic donor-derived malignancies requires allograft removal, immunosuppression cessation, and adjuvant therapy that includes occasional use of checkpoint inhibitors to augment the immune response.

(*Transplantation Direct* 2021;7: e636; doi: 10.1097/TXD.0000000000001090. Published online 8 December, 2020.)

Received 18 September 2020.

Accepted 6 October 2020.

¹ School of Medicine, University of California, San Francisco, San Francisco, CA.

² Department of Surgery, University of California, San Francisco, San Francisco, CA.

³ Helen Diller Family Comprehensive Cancer Center, University of California, San Francisco, San Francisco, CA.

D.A. and P.G.S. did conception and design. D.A., S.W., and G.W. did acquisition of data. D.A., E.A.C., T.F., G.R.R., R.H., and P.G.S. did analysis and interpretation of data. D.A. and P.G.S. drafted the article. S.W., H.J.B., E.A.C., T.F., G.R.R., R.H., and P.G.S. critically revised the article.

H.J.B. was funded by the National Institutes of Health Grant Number T32AI125222.

The authors declare no conflicts of interest.

Correspondence: Peter G. Stock, MD, PhD, Division of Transplant Surgery, University of California, San Francisco, 505 Parnassus Ave, M-884, San Francisco, CA 94143. (Peter.Stock@ucsf.edu).

Copyright © 2020 The Author(s). *Transplantation Direct*. Published by Wolters Kluwer Health, Inc. This is an open-access article distributed under the terms of the Creative Commons Attribution-Non Commercial-No Derivatives License 4.0 (CCBY-NC-ND), where it is permissible to download and share the work provided it is properly cited. The work cannot be changed in any way or used commercially without permission from the journal.

ISSN: 2373-8731

DOI: 10.1097/TXD.0000000000001090

INTRODUCTION

Simultaneous pancreas-kidney (SPK) recipients require aggressive immunosuppression to temporize the allo-immune response and the recurrence of autoimmunity. SPK programs generally use lymphocyte-depleting induction regimens, followed by a relatively significant burden of maintenance immunosuppression compared with regimens typically used after solitary kidney transplant.¹ Consequently, immunosuppression modification when recipients develop a new malignancy is challenging. For donor-derived malignancies, the option of reducing or stopping immunosuppression to "reject" the tumor presents a unique therapeutic option with the caveat that the allograft will likely be rejected.² This approach's theoretical basis is that the host immune system's reconstitution will trigger an alloimmune response against the malignancy, as the malignancy originates from donor tissue. However, an algorithm for stopping immunosuppression, allograft removal, and implementing medical measures such as chemotherapy is not well defined. Decision-making can be challenging in the setting of a well-functioning kidney or pancreas allograft, which may be uninvolved in the metastatic cancer, as allograft removal needs to be strongly

considered to allow immunosuppression withdrawal. Given the paucity of literature on this subject and accompanying decisions, the purpose of this study is to present 3 cases of donor-derived metastatic malignancies after SPK and provide management recommendations based on successful outcomes and a review of the existing literature.

MATERIALS AND METHODS

Three charts of SPK recipients with donor-derived malignancy were retrospectively reviewed. Our institution does not require IRB review for clinical case study reports on up to 3 clinical experiences identified during clinical care. For privacy, all Health Insurance Portability and Accountability Act identifiers have been removed. All 3 patients underwent donor pancreas implantation into the right iliac vessels (systemic endocrine drainage) with enteric exocrine drainage (donor duodenum to recipient ileum) and donor kidney implantation into the left iliac vessels with a ureteroneocystostomy.

CASE SUMMARIES

Case No. 1: Donor-transmitted Pancreatic Adenocarcinoma Detected 6 Months Post SPK

Clinical History

At the time of her SPK, patient 1 was a 42-year-old woman with a history of end-stage renal disease (ESRD) secondary to type 1 diabetes (DM1) with a calculated panel reactive antibodies (cPRA) of 91. She underwent thymoglobulin induction and transitioned to a maintenance immunosuppression of tacrolimus (trough goal 5–15 µg/L), everolimus (trough goal 5–7 µg/L), mycophenolate 540 mg BID, and prednisone 5 mg daily. In the 6 months following transplant, she was seen >10 times at multiple hospitals for recurrent abdominal pain. She received steroids and thymoglobulin for possible rejection. Two months post SPK, a computerized tomography (CT) abdomen-pelvis showed stranding around the pancreas allograft suggestive of possible pancreatitis but with normal lipase. At 6-month posttransplant, it became known that the patient's donor had transmitted an adenocarcinoma to 3 other recipients who received organs from the same donor. At that time, a positron emission tomography (PET) scan revealed diffuse nodal uptake within the left supraclavicular, mediastinal, mesenteric, and right external iliac nodal regions.

Management and Outcome

Three days after the PET scan, given the concern for donor-derived malignancy, the patient underwent removal of both grafts, followed by immunosuppression cessation. Based on the concern for metastatic disease and the confirmed transmission of aggressive malignancy to the other recipients of organs from the same donor, no preoperative biopsy was attempted as the transplants were going to be removed regardless of any biopsy findings. The PET-avid lymph nodes were also not biopsied at the time of surgery. Explant pathology confirmed widespread adenocarcinoma in the pancreas most consistent with a pancreatic primary with extensive lymphovascular invasion and periovarian and fallopian tube involvement. Tumor genotyping identified mutations that would potentially allow serial monitoring via cell-free DNA (cf-DNA) testing. By 6 months following the allograft removals, the previously

seen PET-avid lesions had resolved. The patient continued to have no evidence of cancer for the following year and a half, by both cross-sectional imaging and cf-DNA testing. When being considered for repeat kidney transplant, she was noted to have several new donor-specific antibodies (DSA). Two years after her graft removals, given the substantial time period without evidence of malignancy, the patient underwent a second kidney transplant and restarted immunosuppression. The patient was also listed for a pancreas transplant but received a kidney-only offer, which was accepted given lower immunosuppression requirements and concern over an extended delay with waiting for a compatible pancreas as she had a cPRA of 100% at the time. Six months later, she underwent treatment for an antibody-mediated rejection episode, and 11 months after her second kidney transplant had a PET scan that found no evidence of cancer. The patient is now 3½ years from her original SPK, 3 years from her graft removals, and 1 year from her kidney retransplant. She has been considered for pancreas transplant but is not currently thought to be a candidate due to her recent rejection treatment and a continued cPRA of 100%.

Case No. 2: Donor-derived Pancreatic Adenocarcinoma Detected ≥10 Years Post SPK

Clinical History

At the time of her SPK, patient 2 was a 28-year-old woman with a history of DM1 and ESRD since age 12 with a cPRA of 0%. She underwent thymoglobulin induction and was transitioned to a maintenance regimen of tacrolimus (trough goal 5–15 µg/L), mycophenolate 540 mg BID, and everolimus (trough goal 2–3 µg/L). She had an uneventful course with excellent function of both grafts for 10 years, when she developed chronic abdominal pain. Initial imaging and endoscopies did not identify an etiology for the pain. Twelve years after her SPK, the patient was treated with thymoglobulin for suspected rejection due to an elevated lipase, but no biopsy was done at that time. The lipase returned to normal, but imaging showed fullness in the donor duodenum wall. A subsequent fine-needle aspiration showed adenocarcinoma (Figure 1). The patient underwent PET-CT scan, which showed mediastinal, left supraclavicular, and retroperitoneal lymphadenopathy in addition to marked hypermetabolism of the transplanted pancreas's head and duodenal cuff.

Management and Outcome

The patient had her tacrolimus trough goal lowered to 3–5 µg/L, mycophenolate lowered to 180 mg BID, and everolimus continued with troughs of 2–3 µg/L. The plan was made to discontinue immunosuppression entirely if the cancer was confirmed to be donor-derived. Short-tandem repeat-based identity mapping was performed on the tumor, which confirmed donor-derived malignancy. After this result, the patient underwent removal of both grafts so that immunosuppression could be discontinued to treat the metastatic donor-derived pancreatic adenocarcinoma. Final pathology confirmed a 6.5-cm poorly differentiated adenocarcinoma involving the pancreatic head with invasion into the duodenum, ampulla, and peripancreatic soft tissue and metastatic adenocarcinoma in 5 of 16 lymph nodes. Three months after her graft removals, repeat PET scan showed no hypermetabolic lesions to suggest malignancy, and her CA 19-9 decreased from elevated at 85 before her graft removals to within the normal range. PET

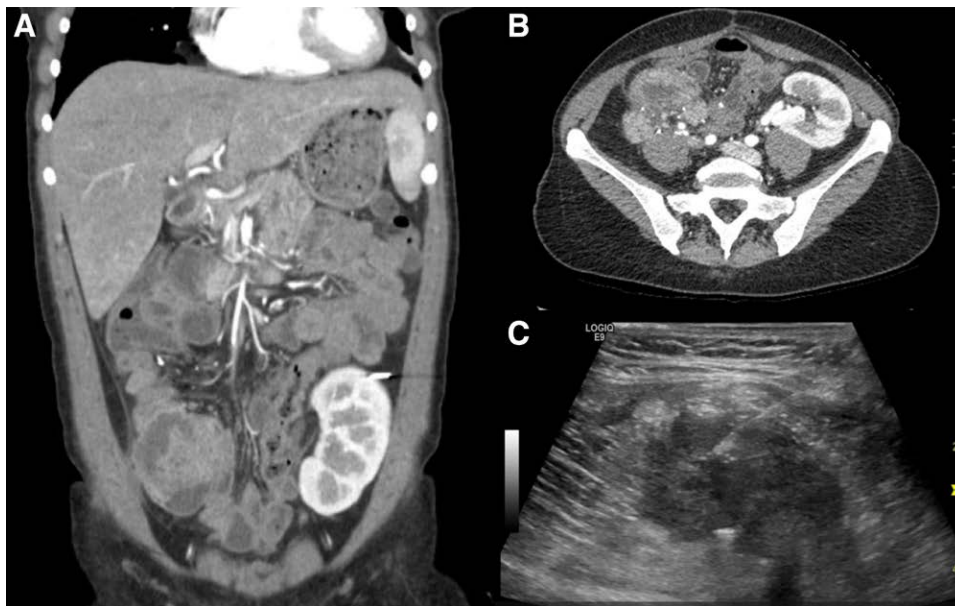


FIGURE 1. Images of the lesion associated with the allograft pancreas in the right lower quadrant in case 2. A, Coronal CT scan. B, Axial CT scan. C, Successful ultrasound-guided fine-needle aspiration of the lesion in the transplanted duodenum associated with the allograft pancreas. CT, computed tomography.

scans in the 11 months after pancreatectomy and nephrectomy continued to display no evidence of cancer, and her CA 19-9 has remained normal. Her cPRA is currently 99%, and she was also noted to have a new HLA class 1 DSA. The patient is now 14 years from her original SPK, 2 years from her graft pancreatectomy and nephrectomy, and is now listed for another SPK. The oncology service will continue to monitor her on the waitlist with PET scans and serum CA-19-9.

Case No. 3: Donor-derived Renal Cell Carcinoma Detected 13 Years Post SPK

Clinical History

At the time of her SPK, patient 3 was a 33-year-old woman with a history of DM1 and ESRD with a cPRA of 24%. She underwent thymoglobulin induction and transitioned to an immunosuppression regimen of tacrolimus (trough goal 5–15 $\mu\text{g/L}$), mycophenolate 360mg BID, and prednisone 5mg daily. She had excellent graft function and an uncomplicated course for 7 years. She developed biopsy-proven chronic allograft nephropathy 7 years after transplant and returned to dialysis but remained insulin independent. Thirteen years after her SPK, a CT scan performed to evaluate nondescript abdominal pain showed a new 3-cm mass in the transplant kidney. Ultrasound surveillance imaging done 6 months later described this lesion as a vascular lesion in the transplant kidney's superior pole, which had grown to 4.7cm. Previously anuric, over the next month, the patient developed hematuria with increasing abdominal pain. A PET/CT scan done revealed a hypermetabolic lesion in the transplant kidney without evidence of metastatic disease.

Management and Outcome

Given the concern for donor-derived malignancy in the transplanted kidney, 2 days after the PET scan, the patient underwent transplant nephrectomy. Final pathology revealed a 5.8-cm, stage T1b renal cell carcinoma (RCC) of unclassified subtype. Given this diagnosis, the patient's immunosuppression

regimen was reduced to a tacrolimus trough goal of 3–5 $\mu\text{g/L}$ but otherwise maintained to preserve allograft pancreas function. Over the subsequent 6 months, surveillance CT scans showed no evidence of metastatic disease. However, 11 months following the transplant nephrectomy, a CT scan identified a 7-mm soft tissue nodule in the left lower quadrant deemed to be low likelihood for recurrence given the RCC's low stage. Serial imaging identified the lesion's slow growth to 1.6cm. She was referred to oncology, who elected to treat this lesion as local recurrence with stereotactic radiation therapy. The lesion showed slight interval growth over the subsequent 9 months without metastatic spread despite radiation therapy.

Two years after transplant nephrectomy, she was found to have new retroperitoneal, pulmonary, and hepatic nodules suspicious for metastatic disease. She was still insulin independent. Over the course of several multidisciplinary discussions, immunosuppression cessation was recommended, as was tyrosine kinase inhibition. She deferred these recommendations due to the dramatic improvement in quality of life her pancreas transplant had provided and challenges with blindness and insulin administration. Two months later, she was admitted with severe pain and was found to have a malignant pleural effusion and hepatic metastases. She then agreed to discontinue immunosuppression and initiate the checkpoint inhibitor nivolumab. She was still resistant to graft pancreatectomy, opting to wait to see if she might remain insulin independent. Four weeks after nivolumab initiation, she developed severe right lower quadrant pain with fever. CT scan showed dramatic improvement in hepatic and retroperitoneal metastatic disease burden, but her transplant pancreas was necrotic appearing. The patient underwent immediate transplant pancreatectomy, which was challenging due to profound local inflammation. A bovine pericardial patch was required to reconstruct the iliac vein. On the first day after pancreatectomy, the iliac vein thrombosed, necessitating thrombectomy and placement of a bare-metal stent across the narrowing. She was subsequently discharged with

continued CT scan surveillance showing resolution of her retroperitoneal lymphadenopathy and decrease in the size of her liver metastases (Figure 2). The patient is now 16 years from her original SPK, 2½ years from her transplant nephrectomy, and 3 months from her transplant pancreatectomy. For her donor-derived RCC, she will continue on monthly nivolumab for 1 year with regular follow-up with oncology.

DISCUSSION

This series reports the successful initial treatment of 3 SPK recipients with donor-derived metastatic malignancies. The literature on the treatment of metastatic donor-derived malignancy is limited overall and particularly limited in SPK recipients. In the larger kidney transplant literature, several systematic reviews have investigated the management of

donor transmitted malignancy. In 2013, Xiao et al identified 104 donor-transmitted cases and showed that 67% of patients underwent graft nephrectomy and withdrawal of immunosuppression, representing the most common approach pursued. The use of adjuvant chemotherapy, radiotherapy, and immunotherapy was highly variable ranging from 0% to 80% use depending on tumor tissue of origin.³ In 2020, Eccher et al presented a similar analysis of 234 recipients with cancer of donor origin and noted that metastatic disease marked the most significant predictor of death even in this population. Because of the option of return to dialysis, most kidney recipients were treated maximally with immunosuppression cessation, graft removal regardless of tumor tissue of origin, grade, or subtype. However, adjuvant medical treatments were pursued and individualized based on tumor tissue of origin, grade, and subtype.⁴ For instance, 2 recent case reports have

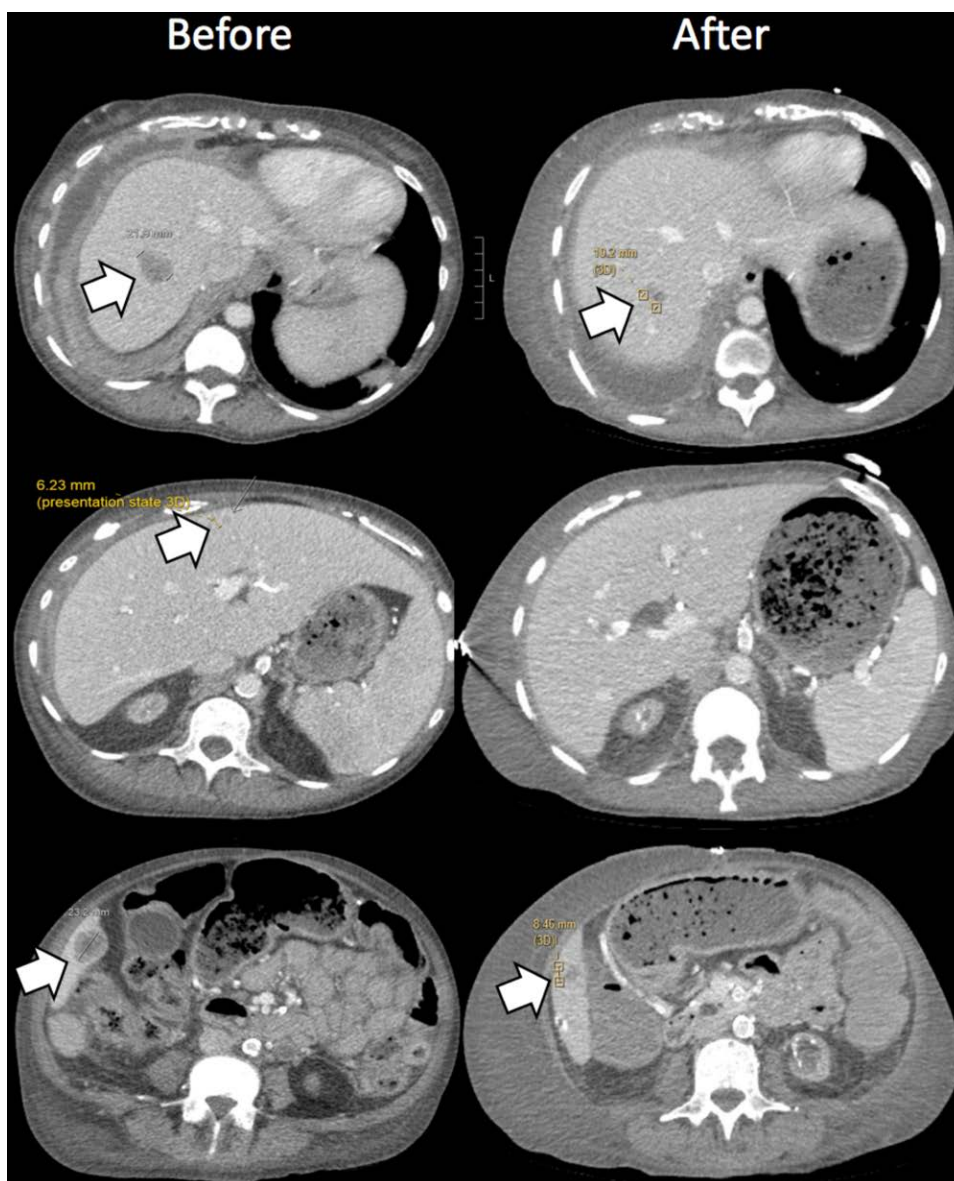


FIGURE 2. The left-sided panels show the metastatic liver lesions in case 3 before explantation of the allograft pancreas and cycle 2 of nivolumab. Multiple liver lesions can be seen measuring 2.2, 0.6, and 2.3 cm in the left-top, left-middle, and left-bottom panels, respectively. The right-sided panels show the liver after explantation of the allograft pancreas and multiple cycles of nivolumab. The liver lesion in the top panels has reduced from 2.2 to 1.0 cm in size, while the liver lesion in bottom panels has reduced from 2.3 to 0.85 cm in size. The liver lesion in the middle panel was resolved and was not seen on subsequent scans. Lesions are all indicated by white arrows.

described the successful treatment of metastatic melanoma in a kidney-only recipients through immunosuppression cessation, allograft explantation, and based on the relative success in general metastatic melanoma, adjuvant immune checkpoint therapy.^{5,6}

The literature in pancreas transplants alone (PTA) is limited to single case reports. The first donor-transmitted malignancy in a PTA was reported by Perosa et al in 2010. The malignancy was limited to the pancreas and treated successfully with graft pancreatectomy and immunosuppression cessation.⁷ Nagaraju et al reported a case of a soft tissue sarcoma arising in a pancreas allograft, which was not tested for donor origin but nevertheless successfully treated with graft pancreatectomy and immunosuppression cessation.⁸

Focusing on SPK patients, Roza et al reported the first donor-derived malignancy in a transplanted pancreas in an SPK recipient in 2001. However, this patient died of malignancy after transplant pancreatectomy, immunosuppression cessation, and 2 chemotherapy courses.⁹ In 2020, Meier et al reported the successful treatment of a widely metastatic BK virus-associated renal carcinoma in an SPK patient with graft nephrectomy and IL-2 immunotherapy. In their case, rejection of the pancreas resulted in a spontaneous rupture of a pseudoaneurysm of the pancreas arterial anastomosis requiring emergent surgery.¹⁰ To our knowledge, there is no other literature on the successful treatment of metastatic donor-derived malignancy in SPK recipients.

Our series adds to this literature by describing the successful initial treatment of 3 SPK patients with donor-derived metastatic malignancy. Patient 1 had donor-transmitted malignancy, meaning the malignancy was present in the donor at the time of donation, while patients 2 and 3 had malignancy that likely originated from donor tissue years after transplantation. Although the timing of the development of these donor-derived malignancies was disparate, in all 3 cases, the malignancy expanded under the surveillance of recipient immune systems that were suppressed to prevent rejection. The common strategy used in all 3 cases forms the basis for the algorithm outlined in Figure 3. The strategies and proposed algorithm are based on our experience and a comprehensive literature review, which demonstrate that successful treatment of metastatic malignancies in transplant recipients is dependent on early allograft removal once donor-derived malignancy is identified, which allows immune reconstitution via immunosuppression cessation. These steps also permit the additional option of treatment with a checkpoint inhibitor, which can cause vigorous rejection if a transplanted organ remains in place.

In the cases above, the methods for distinguishing donor from recipient tumor origin included analysis for differences in microsatellites, that is, short-tandem repeats or checking for a panel of specific gene mutations. These genomic techniques represent just a few options in a larger arsenal of techniques that can be applied to distinguish between donor and recipient tissue. These approaches also include HLA-typing or using fluorescence in situ hybridization for karyotyping.¹¹⁻¹⁵ Using genomic techniques allowed us to apply cell-free-DNA testing as an adjunct to support our determination of no tumor recurrence in case 1. Cell free-DNA testing for malignancy has been described as potentially useful in determining cancer recurrence. However, it remains an evolving, experimental diagnostic tool.¹⁶

Focusing on the management approach to each case, case 1 was clearly a tumor that was transmitted with the donor pancreas, as the heart and liver recipients had metastatic pancreatic adenocarcinoma with similar histopathology. In contrast to SPK cases, stopping immunosuppression or removing the transplants in the cases of the heart and liver recipients would have been fatal. As a result, the heart and liver recipient ultimately died from metastatic pancreatic adenocarcinoma. In our case, the kidney and pancreas could be immediately removed due to the options for dialysis and insulin, respectively. At the time of allograft pancreatectomy and nephrectomy (6 mo after transplant), the tumor had metastasized to the adjacent fallopian tube. Although there was no evidence of tumor in the explanted kidney, a PET scan at the time of pancreatectomy and nephrectomy revealed diffuse nodal uptake within the left supraclavicular, mediastinal, mesenteric, and right external iliac regions. Despite the tumor's locally aggressive nature with lymphovascular invasion, stopping all immunosuppression resulted in normalization of the PET scan within 6 months and no evidence of metastatic disease. In this case, simply restoring the immune response allowed "rejection" of the donor-derived tumor. It is difficult to determine how much of the tumor control is related to restoring immune-mediated tumor surveillance by stopping immunosuppression versus alloimmune rejection of tumor-bearing donor HLA. The fact that the alloimmune response likely provided a substantial contribution to eliminating the tumor is reflected by the dramatic increase in anti-HLA antibodies to a cPRA of 100%. Despite her high panel reactive antibodies, she received a 0-mismatched kidney transplant approximately 2 years after her explant and continues to do well with no evidence of tumor recurrence.

The malignancy in case 2 occurred in the transplanted pancreas of an SPK recipient 10 years after transplant. Following the confirmation of the tumor's donor origin, both the pancreas and kidney were explanted, and immunosuppression was stopped. Like case 1, removal of both organs allowed complete immunosuppression cessation and resulted in resolution of the systemic lymphadenopathy and hypermetabolism at the site of the pancreas transplant observed with sequential PET scans. The decision to remove the normally functioning kidney transplant with no evidence of disease was difficult, but since the tumor was donor-derived, we were concerned about occult disease. We also wanted to be prepared to use checkpoint inhibitors to augment the immune response if immunosuppression withdrawal was insufficient to clear the tumor cells. In case 2, like case 1, immunosuppression withdrawal was also associated with an increase of donor specific HLA antibody and a cPRA of nearly 100%, suggesting that the alloimmune response contributed to the control of the tumor. There has been no evidence of recurrence 2 years following the explants, and the patient is active for both kidney and pancreas retransplantation.

Case 3 is different than the others in that the donor-derived malignancy occurred in a nonfunctioning kidney allograft 13 years following SPK, and the pancreas transplant was functioning normally. At the time of nephrectomy, there was no evidence of metastatic disease, so immunosuppression was lowered but not stopped based on the pancreas's ongoing excellent function. Transplant pancreatectomy would have allowed immunosuppression cessation and would have been in line with the literature in single organ transplants where

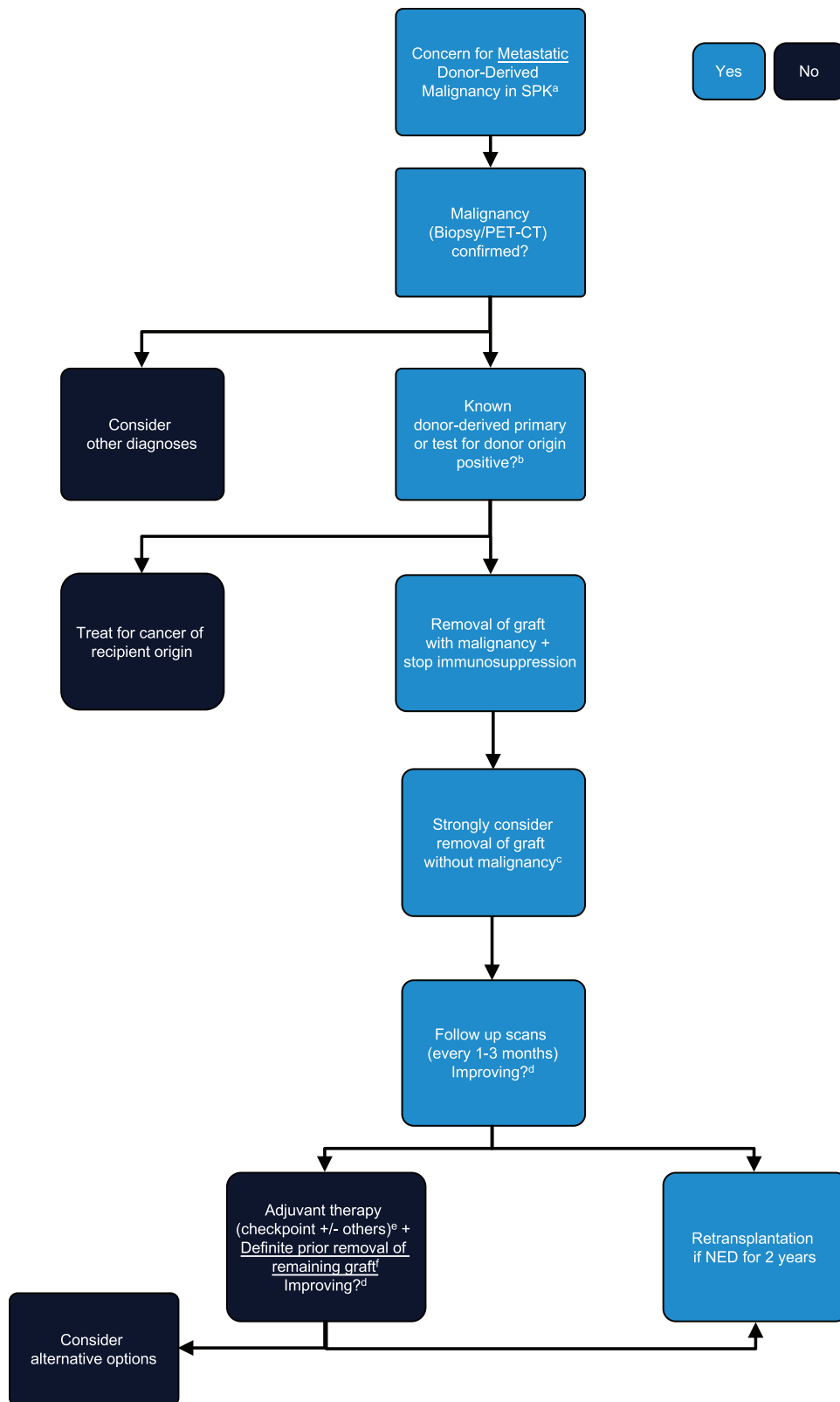


FIGURE 3. Algorithm outlining management strategy of metastatic donor-derived malignancy in SPK patients. ^aMalignancy not squamous, skin or lymphoma and <24 mo from transplant, or current/previous lesion noted in transplanted organ. ^bTesting options include FISH, HLA typing, and nucleic acid–based testing. ^cRecommendation to remove remaining graft arguably stronger for a remaining pancreas than a remaining kidney, due to a higher risk of rejection and complications with the pancreas in particular. ^dExperimental directions for assessing response to therapy may include cPRA retesting as a potential biomarker for “rejection” of donor antigens. Cell-free DNA may experimentally be used to comment on tumor burden and response. ^eAdjuvant chemo- or targeted-therapy may also be indicated based on the malignancy’s tissue of origin, subtype, and grade. Immunotherapy may be preferred on a theoretical basis. However, most adjuvant recommendations are based on the general oncology literature as there are no standard of care recommendations for adjuvant treatment of donor-derived malignancy. ^fRemoval of remaining grafts before initiation of immunotherapy due to the high risk of rejection and complications with immunotherapy. SPK, simultaneous pancreas-kidney; PET-CT, positron emission tomography-computerized tomography scan; NED, no evidence of disease.

graft removal and immunosuppression cessation are the standard approaches. However, the treatment of SPK patients remains more complex than the treatment of kidney or PTA transplants as providers must weigh the risks of removing a normally functioning transplant that may be tumor-free. Thus, this decision involved a risk-benefit assessment by the transplant team and a conversation with the patient regarding preferences. The recipient ultimately did not want to abandon immunosuppression and felt having a functioning pancreas's benefits outweighed the disease recurrence risks. When metastatic disease became apparent (pulmonary effusion, liver lesions), immunosuppression was stopped. She continued to have normal pancreas function but developed severe pain at the local recurrence site and required a chest tube for drainage of the malignant effusion. At this point, checkpoint inhibitors were initiated, but due to her frail condition and normal function (at the time), the pancreas allograft was not removed. However, within weeks of starting checkpoint inhibitors, her increasing insulin requirements and severe pain over the pancreas allograft prompted emergent transplant pancreatectomy. The checkpoint inhibitor therapy's potency was remarkable, and the aggressive rejection induced was almost immediate. In retrospect, pancreatectomy should have been performed before checkpoint inhibitor initiation, as removal of the markedly inflamed and vascular allograft was challenging. The complications of higher blood loss and posttransplant deep venous thrombosis might have been avoided. Therefore, removing the pancreas before the massive inflammatory response checkpoint inhibitors can induce may be safest. Despite the negative aspects of the rejection induced by checkpoint inhibitor therapy, the aggressive immune response was also associated with her metastatic disease's rapid improvement. Within 3 months of immunotherapy initiation, the pulmonary, liver, and lymph lesions have improved substantially based on imaging studies.

We elected to reactivate the patients for either kidney alone or SPK in cases 1 and 2 following 2 years of being cancer free. Although the decision to proceed with transplantation for all potential recipients with a history of treated cancers is dependent on disease-free survival estimates for each malignancy, these data are not available for the scenarios described here. We are optimistic that the immune memory for the donor HLA will be able to maintain adequate control of the original donor-derived tumor, but rigorous follow-up will be necessary to ensure that immunosuppression reinitiation has not compromised immune-mediated control of the tumor. The ongoing presence of DSA would suggest ongoing antitumor activity and could be monitored for future study purposes.

In summary, the finding of metastatic donor-derived malignancy following SPK should prompt immediate removal of the allograft with the primary lesion, immunosuppression cessation, and strong consideration for removal of the second allograft too. If the natural immune surveillance associated with stopping immunosuppression fails to control the

metastatic disease, checkpoint inhibition can augment the natural immune response and successfully control aggressive metastatic disease. This algorithm is only possible for kidney or SPK recipients since these patients have alternative medical therapies following allograft removal, unlike heart, lung, or liver recipients. This strategy is consistent with a broad literature review, demonstrating that successful management of metastatic donor-derived malignancies requires allograft removal, immunosuppression cessation, and adjuvant therapy dictated by tumor tissue of origin that can include occasional immunotherapy use to augment the immune response.

ACKNOWLEDGMENTS

The content is solely the responsibility of the authors and does not necessarily represent the official views of the National Institutes of Health.

REFERENCES

1. Redfield RR, Scalea JR, Odorico JS. Simultaneous pancreas and kidney transplantation: current trends and future directions. *Curr Opin Organ Transplant*. 2015;20:94–102.
2. Strauss DC, Thomas JM. Transmission of donor melanoma by organ transplantation. *Lancet Oncol*. 2010;11:790–796.
3. Xiao D, Craig JC, Chapman JR, et al. Donor cancer transmission in kidney transplantation: a systematic review. *Am J Transplant*. 2013;13:2645–2652.
4. Ecocher A, Girolami I, Motter JD, et al. Donor-transmitted cancer in kidney transplant recipients: a systematic review. *J Nephrol*. 2020.
5. Boyle SM, Ali N, Olszanski AJ, et al. Donor-derived metastatic melanoma and checkpoint inhibition. *Transplant Proc*. 2017;49:1551–1554.
6. Singh P, Pandey D, Rovin B, et al. Successful treatment and five years of disease-free survival in a donor transmitted metastatic melanoma with ipilimumab therapy. *Cureus*. 2019;11:e4658.
7. Perosa M, Crescentini F, Antunes I, et al. Donor-derived malignancy in a pancreas graft. *Transpl Int*. 2010;23:e5–e6.
8. Nagaraju S, Grethlein SJ, Vaishnav S, et al. Case report: primary de novo sarcoma in transplant pancreas allograft. *Transplant Proc*. 2017;49:2352–2354.
9. Roza AM, Johnson C, Juckett M, et al. Adenocarcinoma arising in a transplanted pancreas. *Transplantation*. 2001;72:1156–1157.
10. Meier RPH, Müller YD, Dietrich P-Y, et al. Immunologic clearance of a BK virus-associated metastatic renal allograft carcinoma. *Transplantation*. 2020.
11. Schmitt C, Ciré K, Schattenkirchner S, et al. Highly sensitive DNA typing for detecting tumors transmitted by transplantation. *Transpl Int*. 1998;11:382–386.
12. Robin AJ, Cohen EP, Chongkraitanakul T, et al. A single center's approach to discriminating donor versus host origin of renal neoplasia in the allograft kidney. *Ann Diagn Pathol*. 2016;23:32–34.
13. Milton CA, Barbara J, Cooper J, et al. The transmission of donor-derived malignant melanoma to a renal allograft recipient. *Clin Transplant*. 2006;20:547–550.
14. Palanisamy A, Persad P, Koty PP, et al. Donor-derived myeloid sarcoma in two kidney transplant recipients from a single donor. *Case Rep Nephrol*. 2015;2015:821346.
15. Kim JK, Carmody IC, Cohen AJ, et al. Donor transmission of malignant melanoma to a liver graft recipient: case report and literature review. *Clin Transplant*. 2009;23:571–574.
16. Corcoran RB, Chabner BA. Application of Cell-free DNA Analysis to Cancer Treatment. *N Engl J Med*. 2018;379:1754–1765.